

Case Report

Witkop Tooth and Nail Syndrome and Orthodontics

Ayşe T. Altug-Atac^a; Haluk Iseri^b

ABSTRACT

This case report presents the orthodontic treatment of a patient with Witkop syndrome, an autosomal dominant genetic disorder characterized by the absence of several teeth and abnormalities of the nails. The patient, a 6-year 4-month-old boy, was referred to our clinic for treatment of severe overjet and openbite. Radiographic and clinical evaluations showed peg-shaped maxillary lateral incisors and the congenital absence of three mandibular incisors as well as spoon-shaped fingernails. Treatment of openbite and overjet was initiated with functional appliances, and fixed orthodontic appliances were inserted at age 10 years 3 months. The edentulous spaces are being maintained for implants that will be provided once the patient's growth is complete. Evaluations of long-term treatment results to date have indicated improvements in both facial and dental esthetics.

KEY WORDS: Tooth and nail syndrome; Witkop syndrome; Ectodermal dysplasia

INTRODUCTION

Witkop tooth and nail syndrome (TNS) is a form of ectodermal dysplasia, a group of hereditary diseases characterized by the absence or impaired function of two or more structures (teeth, hair, nails, glands) originating from the ectoderm.¹

First described by Witkop in 1965,² Witkop TNS is characterized primarily by hypodontia and nail dysplasia, with little involvement of the hair and sweat glands.^{3,4} Teeth of individuals affected by Witkop TNS are often widely spaced, conical in shape and have narrow crowns. Nails may be spoon-shaped (koilonychia*), ridged, slow growing, and easily broken (onychorrhexis†).¹ In rare cases, nails may spontaneously separate from the nail beds or may be absent

at birth. Toenails are usually more severely affected than fingernails. Other symptoms include fine and sparse hair.

Witkop TNS has been estimated to affect one to two individuals in 10,000.⁵ It is an autosomal dominant trait, meaning that it is caused by a single copy of the responsible gene that is usually inherited from a parent who is also affected by the disease. Both males and females may develop Witkop TNS.

The gene responsible for Witkop TNS was identified in 2001 and is termed MSX1.⁶ This gene is recognized as important in tooth formation, and the mutation that results in Witkop TNS appears to encode a protein that is completely nonfunctional. Another mutation in the same gene has been associated with oral clefting.

CASE REPORT

Presentation and Diagnosis

A 6-year 4-month-old boy was referred to the Ankara University Department of Orthodontics for treatment of openbite and overjet. The patient was in early mixed dentition. Clinical examination identified a Class II, division 1 malocclusion associated with a mild openbite and lip incompetence resulting from a retrognathic mandible. The patient had widely spaced dentition; his maxillary lateral, mandibular central, and mandibular lateral incisors, and maxillary and mandibular deciduous canines were tapered. Plaster models and extra-oral photographs were obtained during the initial visit, and a tongue shield was inserted to rehabilitate tongue

^a Assistant Professor, Department of Orthodontics, School of Dentistry, University of Ankara, Ankara, Turkey.

^b Professor and Chairman, Department of Orthodontics, School of Dentistry, University of Ankara, Ankara, Turkey.

Corresponding author: Dr Ayşe Tuba Altug-Atac, Ankara Universitesi, Dis Hekimligi Fakultesi, Ortodonti Anabilim Dalı, 06500, Besevler, Ankara, Turkey (e-mail: aysealtug@yahoo.com)

Accepted: January 2007. Submitted: October 2006.

© 2007 by The EH Angle Education and Research Foundation, Inc.

**Koilonychia* is a dystrophy of the fingernails in which they are flattened and have concavities with raised edges; koilonychia is also called "spoon nails." The depression in the nail is usually large enough to hold a drop of liquid.

†*Onychorrhexis* is a brittleness of the fingernails or toenails, with splitting of the free edge of the nail. Onychorrhexis produces longitudinal lines or striations in the nail plate.

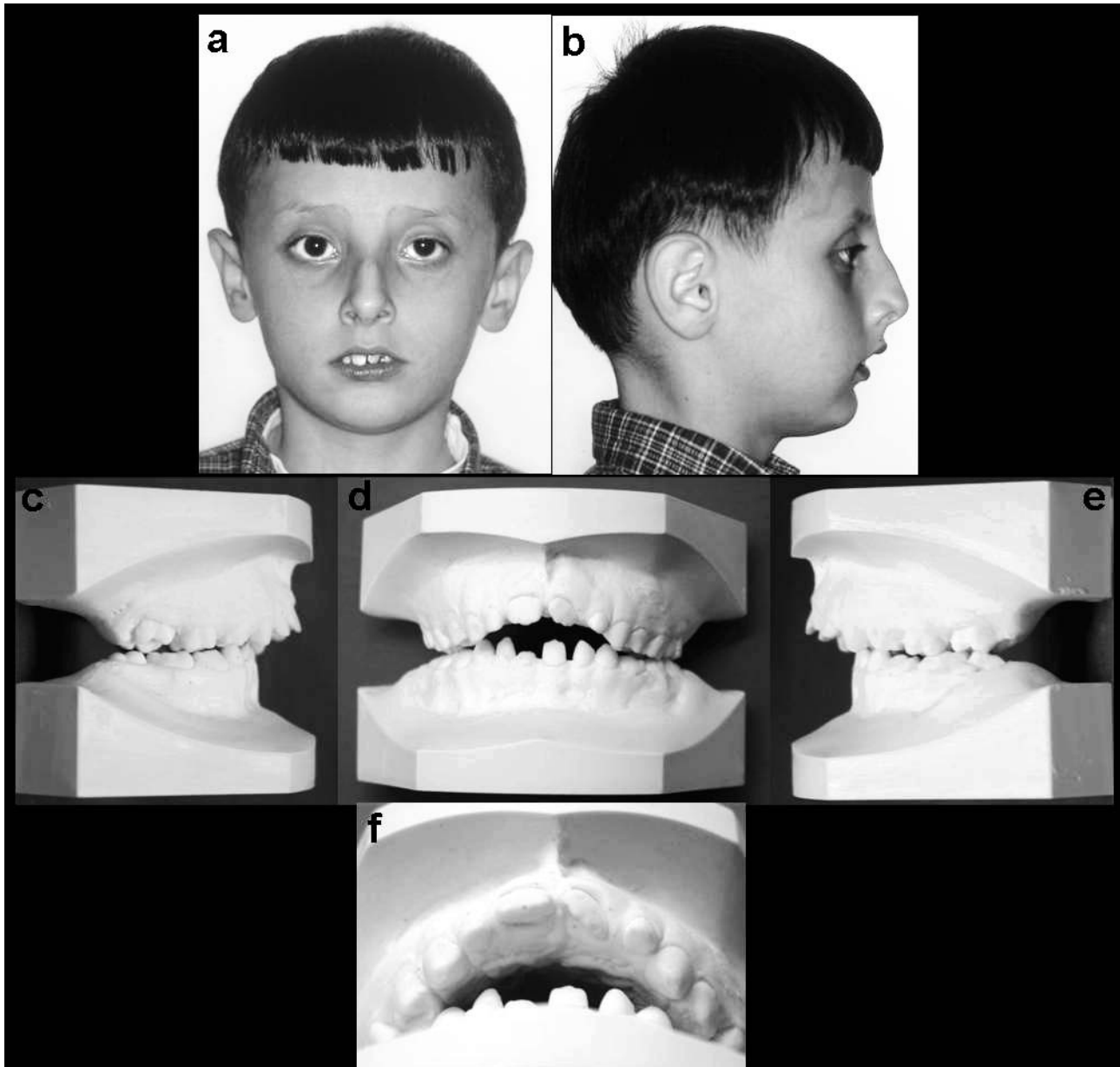


Figure 1. (a,b) Pretreatment extraoral facial and lateral photographs. (c,d,e) Pretreatment study models. (f) The overjet on the study model (documents before the insertion of the tongue shield; 6 months prior to T1 stage).

functioning and close an openbite of 3 mm (Figure 1a–e).

After 6 months of tongue shield therapy (at age 6 years 10 months), a full set of radiographs was taken from the patient. Radiographic examination revealed the congenital absence of the right central, right lateral and left lateral mandibular incisors (Figure 2). At that time, there was no sign of any third molar development, a finding confirmed by subsequent radiographs. Based on these findings, the patient's condition was diagnosed as Witkop syndrome,⁷ and the patient, his parents, and his younger brother were examined physically.

Physical examination showed that both the patient and his father had spoon-shaped fingernails (Figure 3). The patient was also found to have onychorrhexis and agenesis of the toenails, which were said to have been very small at birth (Figure 4). There were no abnormalities of the hair in either the patient or his father, but both had very sparse eyebrows. There was no history or findings of sweat gland dysfunction. Although atypical facial characteristics are not anticipated in Witkop patients,⁸ the skin of both the patient and his father were markedly dry, pale, and transparent (Figure 5). Examinations of the patient's mother and younger brother (still in deciduous dentition) showed both

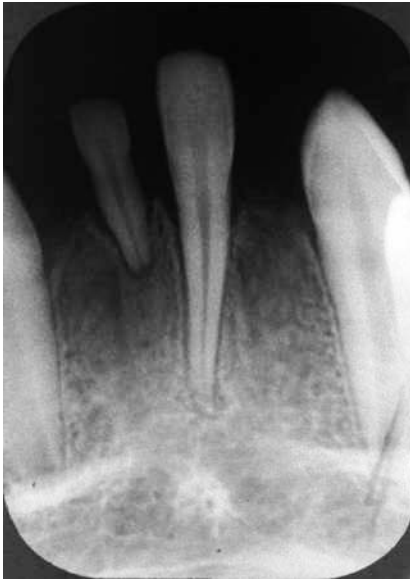

Figure 2. Periapical radiograph taken at the mandibular incisors region, showing the absence of three permanent incisors.

to have complete sets of normal teeth and no abnormalities of nail, scalp, hair, or eyebrows.

Another orthodontic evaluation was conducted at age 9 years 3 months. The patient was still in early mixed dentition, and the dentition was still widely spaced. He had developed a 12.5-mm overjet and a 2.1-mm overbite (Figure 6a–e), and was evaluated as skeletal Class II (ss-n-sm: 7.7°) with a severe hyperdivergent growth pattern (NSL/ML: 39.82°). The maxillary and mandibular incisor inclinations were considered to be acceptable (ILs/NL: 114.4° and ILi/ML: 92.4°).⁹

Treatment Objectives

The following treatment objectives were determined:

- Facial esthetics: Improvement of convex profile; correction of skeletal relationship.

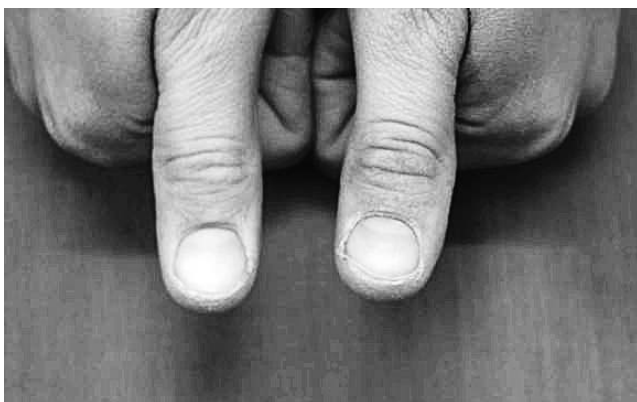

Figure 3. Koilonychia and onychorrhexis of the fingernails.

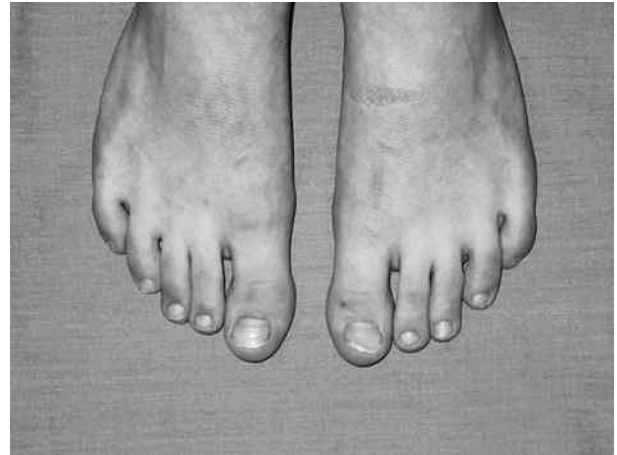

Figure 4. Koilonychia of the toenails.

- Dental structure: Elimination of increased overjet; alignment of existing teeth.
- Stability: Positioning and arrangement of teeth for maximum stability, maintaining spaces for future prosthetic appliances in place of congenitally missing teeth.

Treatment Methodology and Evaluation

A removable tongue shield was inserted when the patient was first referred to the clinic at age 6 years 4 months. Six months later, at age 6 years 10 months (before $PP_2 =$ less than 69.5% of mature height),¹⁰ the patient's status was recorded, and the decision was made to delay more involved orthodontic intervention until he reached an age at which he would likely be more cooperative for treatment. At age 9 years 3 months (before $PP_2 = 75.2\%$),¹⁰ a Class II activator was applied in order to stimulate mandibular growth



Figure 5. Father of the subject.

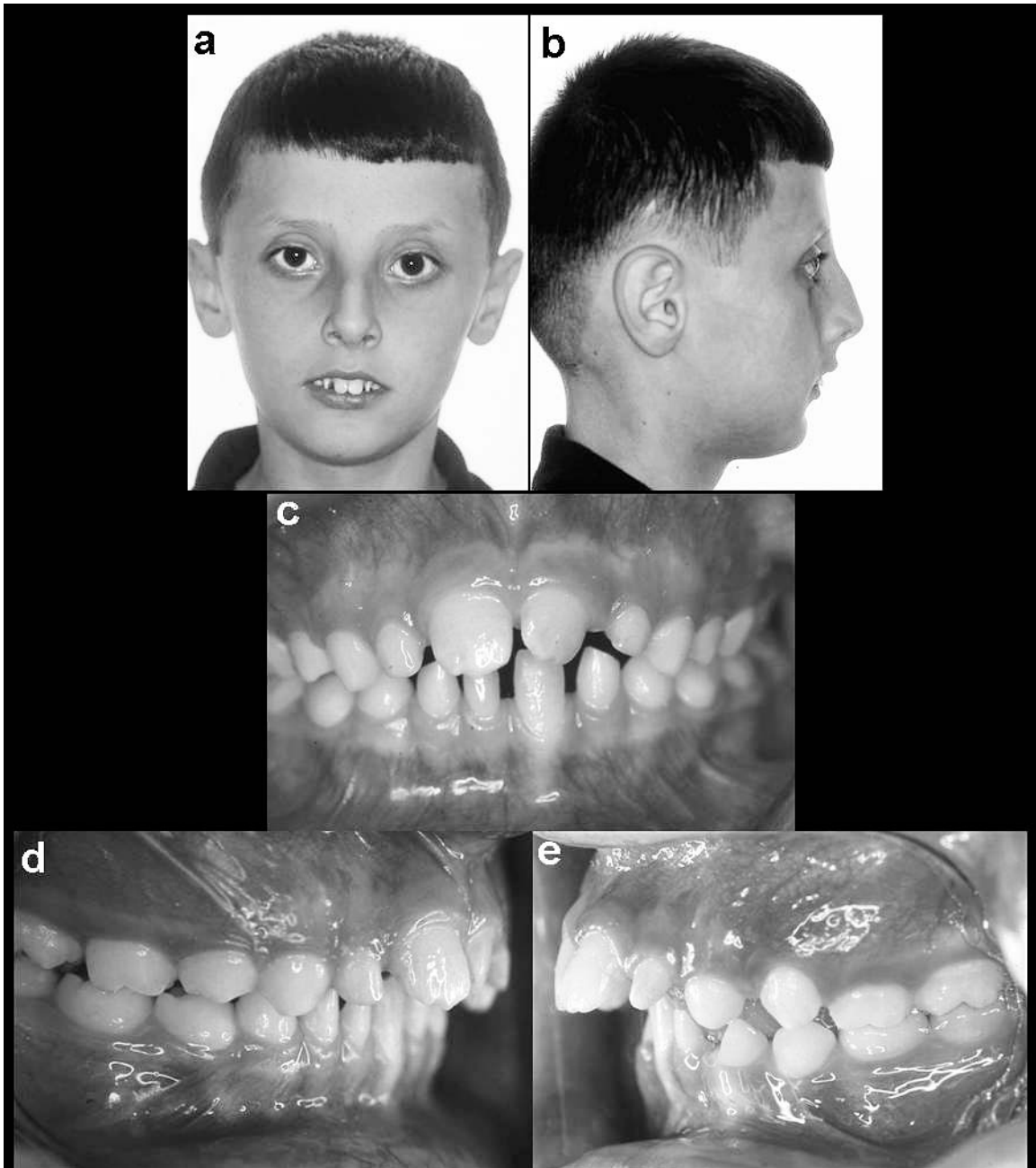


Figure 6. (a,b) Preactivator therapy, extraoral facial and lateral photographs. (c,d,e) Intraoral photographs (T2 stage).

and eliminate the overjet (Figure 6a–e). The patient's compliance was excellent, and a well-balanced skeletal relationship was achieved after 6 months of activator treatment. The patient continued to use the activator for an additional 6 months for retention, after which postactivator data were collected (Figure 7a–e).

At age 10 years 3 months ($PP_2 = 78.4\%$),¹⁰ dental alignment was initiated using fixed standard Edgewise mechanics. Intermaxillary Class II elastics were used in conjunction with the fixed appliance in order to improve the skeletal correction achieved to date and to

maintain the skeletal Class I relationship. The spaces of the congenitally missing mandibular incisors were reserved with closed coil springs (Figure 8a–e).

Fixed appliance therapy continued for 21 months until the patient reached 12 years of age ($MP_3 = 80.9\%$).¹⁰ At this time, the fixed appliances were removed, and a maxillary Essex plate and mandibular Hawley plate with artificial teeth were inserted to maintain the dental improvements achieved to date (Figure 9a–f). In the future, treatment is planned to improve the esthetics of the maxillary lateral incisors with lam-

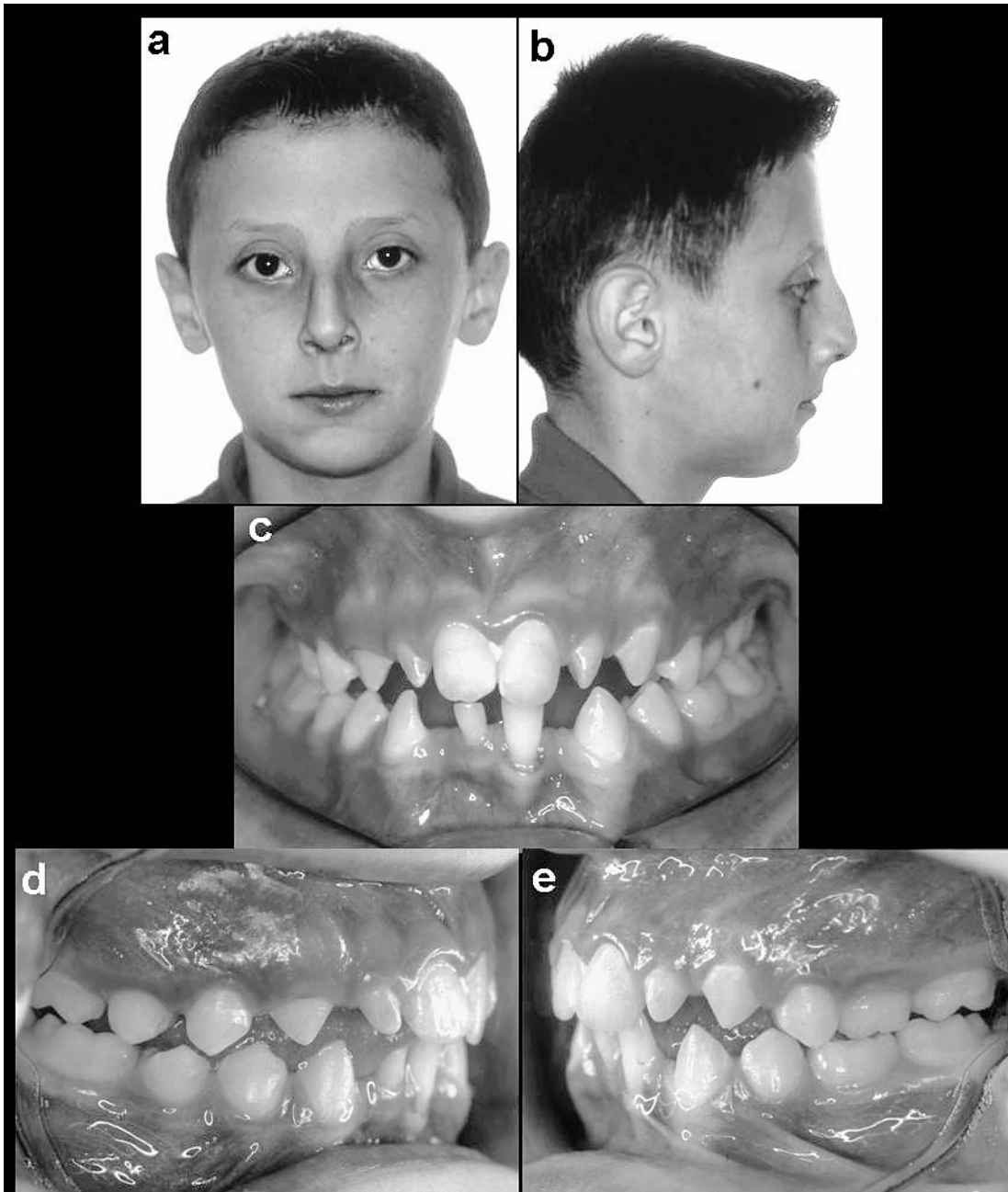


Figure 7. (a,b) Postactivator therapy extraoral facial and lateral photographs. (c,d,e) Intraoral photographs (T3 stage).

inate veneer and to insert implants in the spaces of the missing teeth once the patient's growth is complete.

Measurements and Treatment Results

Lateral cephalometric films were superimposed structurally (Figure 10a–c) using fiducial points to eliminate the effects of growth on cranio-dento-facial measurements. In total, 31 reference points and two fiducial points were marked on each lateral cephalometric film. Fiducial points designated as n and s were lo-

cated in the anterior cranial base on the initial films. By superimposing the second, third, and fourth films on the initial films,¹¹ these points were transferred to the later films and designated as n_t and s_t .^{12,13} All measurements on the lateral cephalometric films were taken with reference to the pairs of fiducials (Figure 11).

Table 1 shows the cephalometric evaluation of the patient throughout the course of treatment, as follows: T1: Completion of removable tongue-shield therapy (6 years 10 months); T2: Insertion of Class II, Division 1 activator (9 years 3 months); T3: Completion of activator therapy, initiation of fixed-appliance alignment

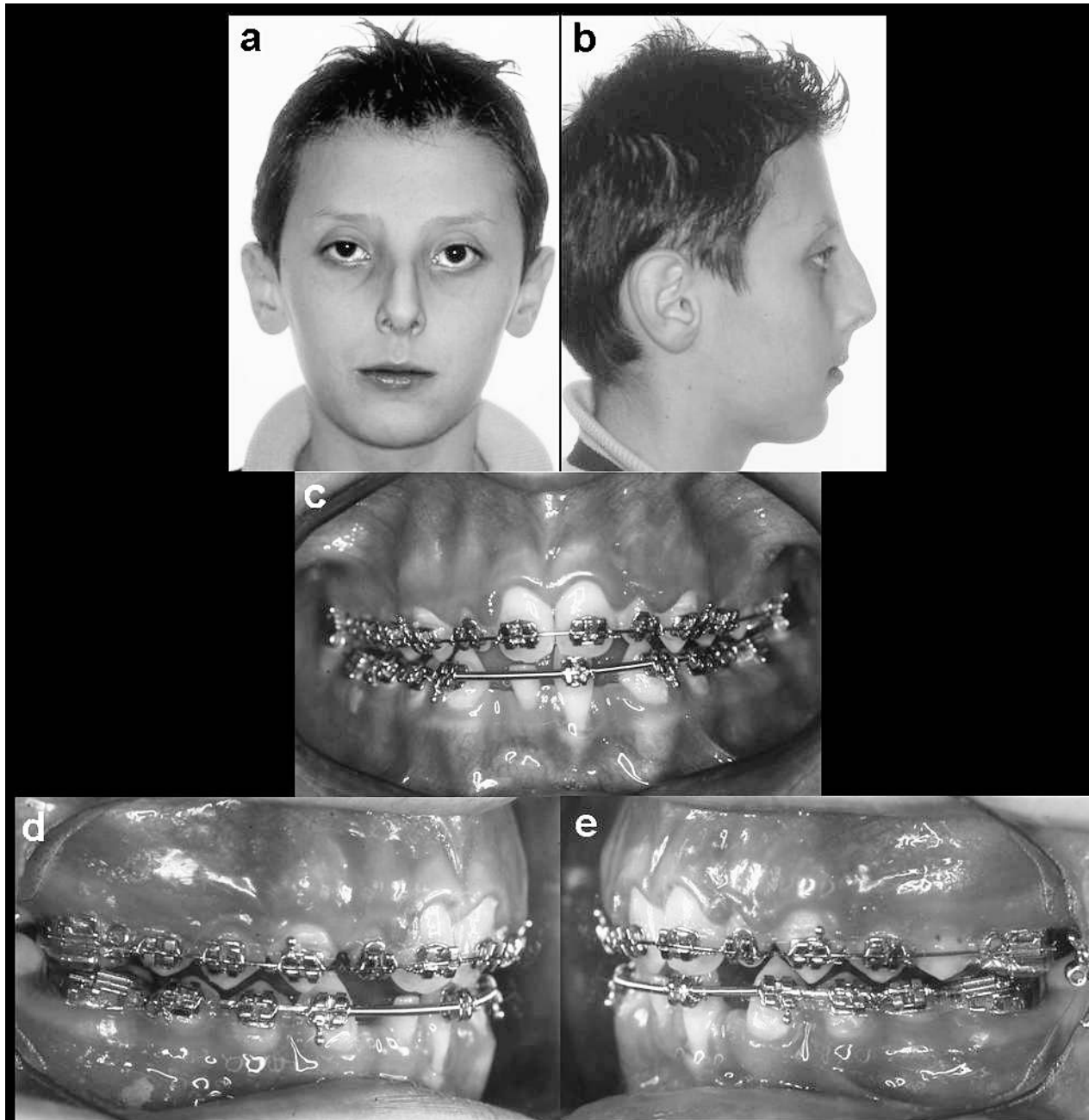


Figure 8. (a,b) Extraoral facial and lateral photographs taken during the fixed appliance treatment. (c,d,e) Intraoral photographs.

(10 years 3 months); T4: End of orthodontic treatment (12 years).

DISCUSSION

Witkop TNS is an autosomal dominant hereditary disorder characterized primarily by teeth and nail deformities deriving from the ectoderm. Other types of ectodermal dysplasia involving the teeth and nails are Fried TNS, deafness and onychoosteodystrophy with retardation (DOOR syndrome) and Curry-Hall syndrome. Of these, Fried TNS most closely resembles

Witkop TNS. However, Fried TNS, like anhydrotic ectodermal dysplasia, is autosomal recessive.⁷ Moreover, Fried TNS involves significant sparseness and thinness of hair and eyebrows as well as an everted lower lip.^{7,14} DOOR and Curry-Hall syndromes also extend well beyond teeth and nail deformities; whereas Curry-Hall syndrome involves polydactyly (presence of more than the normal number of fingers or toes),¹ DOOR involves deafness, other body anomalies, and learning difficulty.

The severity of hypodontia in Witkop TNS varies

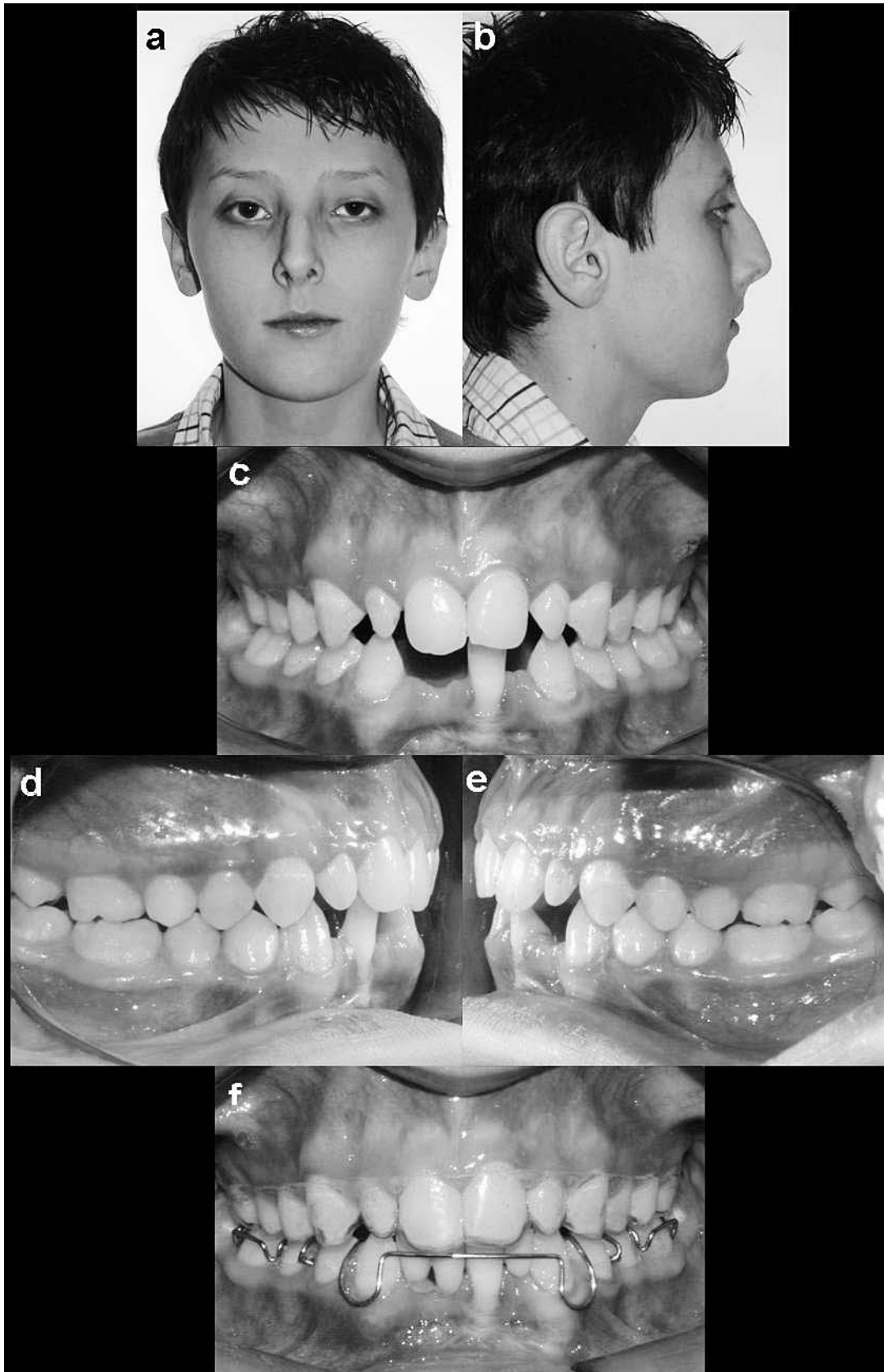


Figure 9. (a,b) Posttreatment extraoral facial and lateral photographs. (c,d,e) Intraoral photographs (T4 stage). (f) The retention appliances (maxillary Essix plate and mandibular Hawley plate with artificial teeth) used until the growth of the subject is completed.

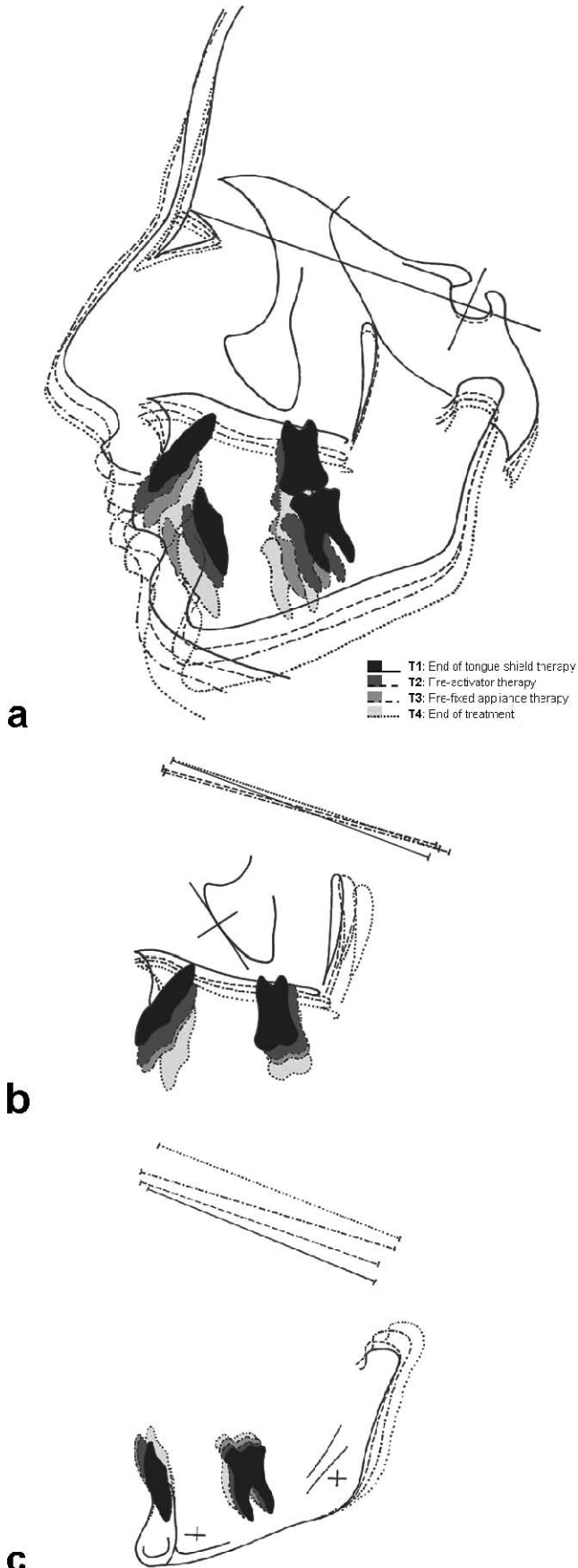


Figure 10. (a) Total. (b) Maxillary local and (c) Mandibular local structural superimpositions.

from mild to extreme.^{1,8,14} Giansanti et al¹⁵ have even reported a case of adontia associated with this disorder. The present case could be categorized as one of mild hypodontia.

It has been reported that nail dysplasia in Witkop TNS is often worse in childhood, becoming less severe with age. This may explain why signs of nail dysplasia are absent in most adult patients.³ While our patient had spoon-shaped nails, significant nail abnormalities were not observed in the father, although his nails were brittle. It is possible that because of his age, the father of the reported patient did not exhibit nail abnormalities, but it may be assumed that they were present at a younger age.

Some patients with Witkop TNS have been described as having sparse eyebrows and eyelashes, although this finding is not necessary for the diagnosis of the syndrome.⁸ Because the hair has been involved to a certain extent in many reported cases of Witkop TNS, Chitty et al consider the designation “tooth and nail syndrome” to be a misnomer.¹⁶ Both our patient and his father had significantly sparse eyebrows.

Hudson and Witkop³ reported an autosomal dominant pattern of inheritance in Witkop TNS, but isolated cases of the syndrome without a family history have also been reported.^{15,17,18} Both male and female children have been reported to inherit the disease from either parent.⁸ Akyuz and Atasu¹⁹ reported a case of Witkop TNS in a 5-year-old boy who was born after a consanguineous marriage. In the case reported here, both parents and the younger brother of the patient were examined. While neither the mother nor the brother were observed to have any symptoms of Witkop TNS, the father was observed to have slight nail deformities and sparse eyebrows; therefore, it was determined that the patient inherited the disease from his father.

Orthodontic Treatment

Tongue shield. Left untreated, tongue thrust becomes a disfiguring habit.²⁰ The best time for intervention in such cases is considered to be the period of early mixed dentition. In this case, a 6-month period of tongue-shield therapy resulted in rehabilitation of the tongue and the related elimination of a mild openbite.

Class II division 1 activator. The ss-n-sm angle was reduced and the maxillo-mandibular relationship was balanced during the activator phase (T2-T3). The maxillary incisors were mildly retroclined, and the mandibular incisors were retained in their initial positions. Stability of the mandibular incisors was of vital importance due to the congenital absence of three incisors, leaving the dentoalveolar bone supported by a single per-

Table 1. Lateral Cephalometric Evaluation of the Subject^a

	Male Norm Values (Ozbek and Işeri ⁹)	T1	T2	T3	T4
Cranial base					
s-n	73.3 ± 3.2 mm	71.37	71.88	71.76	71.54
s-ba	45.3 ± 3.9 mm	44.70	44.93	47.90	49.02
n-s-ba	129.7 ± 4.5 mm	122.47	122.56	122.72	124.56
Maxilla					
s-n-ss	81.6 ± 3.4 mm	75.12	75.31	74.83	74.68
NSL/NL	9.1 ± 2.9°	7.65	5.81	7.64	9.61
sp-pm	57.3 ± 2.4 mm	51.63	53.14	54.28	58.54
n-sp	58.5 ± 3.0 mm	52.99	55.34	57.90	60.99
Mandible					
s-n-sm	78.8 ± 3.2°	68.30	67.61	69.63	68.62
NSL/ML	30.9 ± 4.5°	40.13	39.82	41.36	43.36
n-me	129.1 ± 5.8 mm	112.55	118.13	122.27	129.13
s-go	91.3 ± 5.1 mm	64.78	68.19	71.01	75.25
ar-go	58.7 ± 4.3 mm	36.60	37.50	38.11	41.00
ar-gn	114.8 ± 3.8 mm	89.09	91.73	94.87	98.81
pg-go	89.8 ± 5.3 mm	64.50	66.00	69.50	70.15
ar-go-me	119.5 ± 6.2°	125.28	122.68	126.06	127.11
Maxillo-mandibular relations					
ss-n-sm	2.7 ± 1.4°	6.83	7.71	5.20	6.06
NL/ML	21.8 ± 4.2°	32.47	34.01	33.72	33.75
sp-me	72.7 ± 4.3 mm	63.09	66.19	67.51	72.49
sp me/n me	0.50	0.56	0.56	0.55	0.56
Overbite	2.1 ± 0.7 mm	0.58	2.10	2.03	2.74
Overjet	2.9 ± 0.5 mm	12.19	12.51	5.96	3.51
Dentoalveolar relations					
ILs/NL	110.7 ± 4.5°	114.37	114.37	107.94	92.71
ILi/ML	98.1 ± 5.3°	85.24	92.35	92.84	85.42
ILs/ILi	129.3 ± 6.5°	127.91	118.92	125.50	148.11
is-NL	30.8 ± 2.9 mm	24.42	27.45	28.85	29.56
ii-ML	43.4 ± 2.2 mm	35.35	37.55	38.35	40.16
ms-NL	26.3 ± 2.6 mm	17.90	18.98	19.77	22.40
mi-ML	35.3 ± 2.3 mm	26.45	28.04	29.40	31.47
Soft tissue²⁷					
G-Sn:Sn-Me	1 : 1	1.08	1.00	1.15	1.15
Sn-St	20 ± 2	15.31	15.81	18.85	19.96
Sn-St:St-Me	1 : 2	0.36	0.33	0.43	0.43
Sn-LLV:LLV-Me	1 : 0.9	1.12	1.12	0.85	0.84
Interlabial distance	0–3 mm	6.26	7.20	1.59	0.06
Upper lip	0 ± 2 mm	-0.36	-0.97	-5.87	6.18
Lower lip	-2 ± 2 mm	-11.26	-12.18	-9.06	-11.59
Chin	-4 ± 2 mm	-19.86	-22.23	-21.71	-23.12

T1: end of the removable tongue shield; T2: insertion of the Class II Division 1 activator; T3: end of activator, beginning of alignment with fixed appliance; T4: end of treatment.

manent tooth in that region. In order to ensure stability, the mandibular incisors (one permanent and one deciduous) were capped by the activator.

As expected, the mandibular plane angle (NSL/ML) increased slightly as a result of activator therapy (T2-T3) and continued during the fixed appliance phase (T3-T4). This persistent, undesirable posterior rotation of the mandible may be a reflection of the typical facial type of Witkop TNS.

Fixed appliances and intermaxillary Class II elastics.

Following activator therapy, fixed appliances were inserted. Since the patient was still growing, intermaxillary Class II elastics were utilized with fixed appliance therapy in an effort to support the mandibular growth achieved with the activator. Petrovic et al²¹ have reported that Class II elastics act as functional appliances capable of stimulating growth rate and increasing the amount of condylar cartilage, thus lengthening the mandible. Microscopic²² and cephalometric²³ studies have shown that intermaxillary Class II elastics can

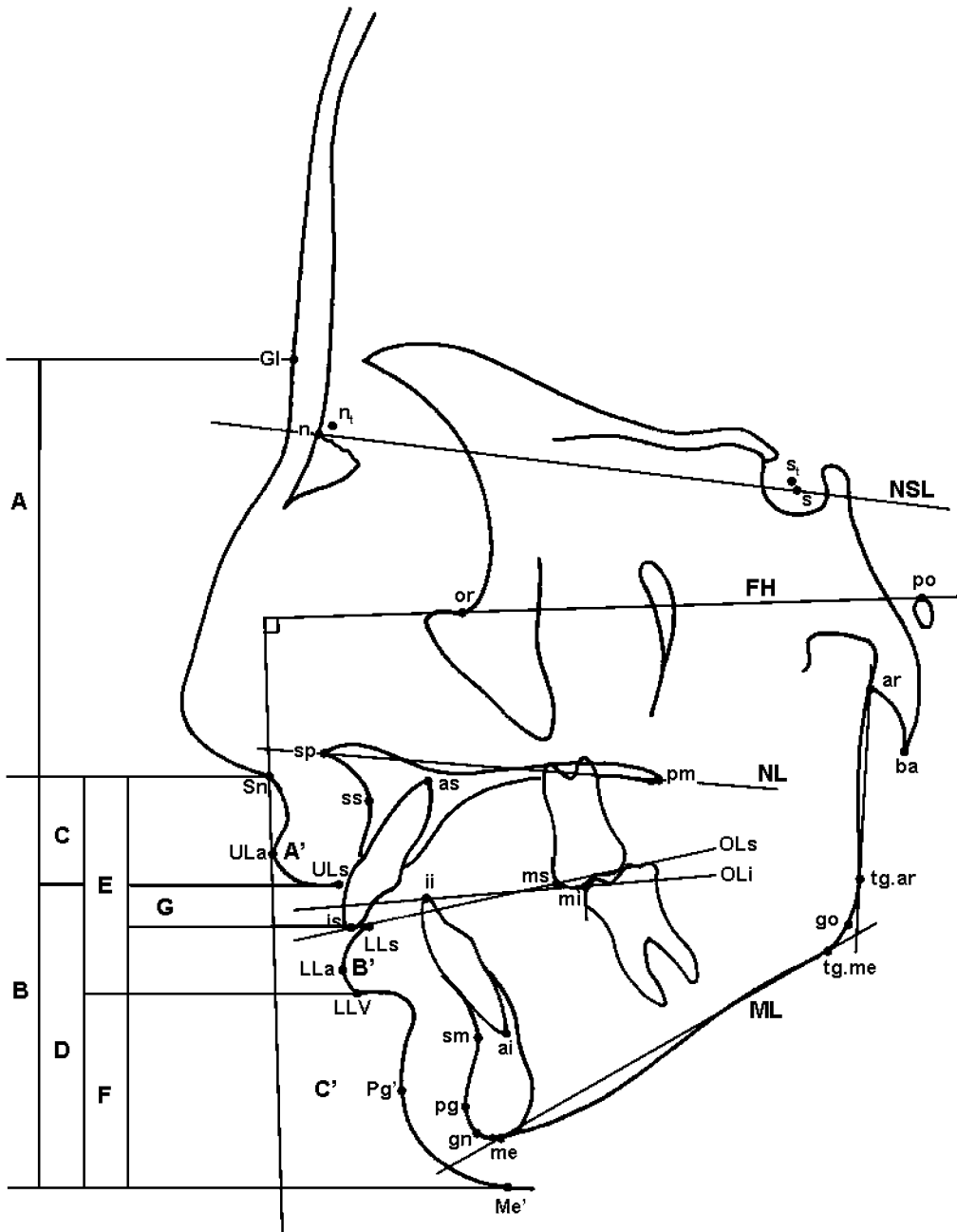


Figure 11. Reference points and lines on the lateral cephalometric radiographs. Reference points: s: sella; n: nasion; s₁: transferred sella; n₁: transferred nasion; po: porion; or: orbitale; ar: articulare; ba: basion; sp: anterior nasal spine; pm: posterior nasal spine; ss: point; as: apex of maxillary incisor; is: incisal edge of maxillary incisor; ms: maxillary molar; ii: incisal edge of mandibular incisor; ai: apex of mandibular incisor; mi: mandibular molar; sm: point B; pg: pogonion; gn: gnathion; me: menton; tg.me: tangent to menton; go: gonion; tg.ar: tangent to articulare. Reference lines: NSL: nasion-sella line; FH: Frankfort horizontal line; NL: nasal line; OLi: mandibular occlusal plane; ML: mandibular line; FH⊥Sn: subnasale perpendicular to Frankfort horizontal line. Soft tissue measurements: A: G-Sn: middle third face; B: lower third face; C: upper lip length; D: Sn-St: subnasale-upper lip stomion; D: St-Me: upper lip stomion-soft tissue menton; E: Sn-LLV: subnasale-lower lip vermillion; F: LLV-Me: lower lip vermillion-soft tissue menton; G: interlabial distance: upper lip stomion-lower lip stomion; A': subnasale perpendicular to upper lip; B': subnasale perpendicular to lower lip; C': subnasale perpendicular to soft tissue chin at the level of pogonion.

stimulate growth of the condyles, even in adult primates. McNamara²³ reported proliferation of the condylar cartilage in less than 2 weeks. Altug-Atac and Erdem²⁴ also reported significant growth of the con-

dyles in their clinical studies using intermaxillary Class II elastics.

Osseointegrated implants. The treatment plan in the case presented includes esthetic improvement of the

maxillary lateral incisors using laminate veneer and insertion of implants in the spaces left by the congenitally missing teeth; however, provision of these prosthetic devices will be delayed until the patient's growth is complete. Iseri and Solow²⁵ have drawn attention to the fact that osseointegrated implants with artificial teeth should not be applied in childhood or early adulthood due to the continued eruption of the natural teeth. Thilander et al²⁶ reported infraocclusion of implants due to the continuous eruption of adjacent teeth and craniofacial changes during postadolescence. When implants are applied before the appropriate time, later revision or replacement of the artificial teeth may be required.

CONCLUSION

Because of their ongoing use of radiographs during treatment, dentists and orthodontists can play a large role in diagnosing syndromes such as Witkop TNS. In this case report, the orthodontic treatment of a boy with Witkop TNS is presented. Treatment included tongue shield, Class II Division 1 activator and fixed appliances, respectively. The patient is currently using retention appliances until his growth is completed, at which time he will become a good candidate for laminate veneers and osseointegrated implants.

REFERENCES

- Zabawski EJ Jr, Cohen JB. Hereditary hypodontia and onychorrhexis of the fingernails and toenail koilonychia: Witkop's tooth and nail syndrome. *Dermatol Online J*. 1999;5:3.
- Hudson CD, Witkop CJ Jr. Autosomal dominant hypodontia with nail dysgenesis. *Oral Surg*. 1975;39:409–423. In: Zabawski EJ Jr, Cohen JB. Hereditary hypodontia and onychorrhexis of the fingernails and toenail koilonychia: Witkop's tooth and nail syndrome. *Dermatol Online J*. 1999;5:3.
- Stimson JM, Sivers JE, Hlava GL. Features of oligodontia in three generations. *J Clin Pediatr Dent*. 1997;21:269–276.
- Witkop CJ Jr. Genetic diseases of the oral cavity. In: Tietze RW Jr, ed. *Oral Pathology*. New York, NY: Blackiston Division, McGraw-Hill; 1965:810–814. In: Hodges SJ, Harley KE. Witkop tooth and nail syndrome: report of two cases in a family. *Int J Paediatr Dent*. 1999;9:207–211.
- Witkop CJ. Hypodontia-nail dysgenesis. In: Buyse ML, ed. *Birth Defects Encyclopedia: The Comprehensive, Systematic, Illustrated Reference Source for the Diagnosis, Delineation, Etiology, Biodynamics, Occurrence, Prevention, and Treatment of Human Anomalies of Clinical Relevance*. Dover, Mass: Center for Birth Defects Information Services; 1990:920.
- Jumlongras D, Bei M, Stimson JM, et al. A nonsense mutation in MSX1 causes Witkop syndrome. *Am J Hum Genet*. 2001;69:67–74.
- Gorlin RJ, Cohen MM Jr, Levin LS. Syndromes with unusual dental findings. In: Gorlin RJ, Cohen MM Jr, Levin LS, eds. *Syndromes of the Head and Neck*. 3rd ed. New York, NY: Oxford University Press; 1990:877.
- Hodges SJ, Harley KE. Witkop tooth and nail syndrome: report of two cases in a family. *Int J Paediatr Dent*. 1999;9:207–211.
- Ozbek M, Işeri H. A comparison of soft tissue profile configuration in deep overbite and normal occlusion cases. *Turkish J Orthod*. 1994;7:100–118.
- Greulich WW, Pyle SI. *Radiographic Atlas of Skeletal Development of Hand and Wrist*. 2nd ed. Stanford, Calif: Stanford University Press; 1959.
- Björk A, Skieller V. Normal and abnormal growth of the mandible. A synthesis of longitudinal cephalometric implant studies over a period of 25 years. *Eur J Orthod*. 1983;5:1–46.
- Solow B, Siersbaek-Nielsen S. Growth changes in head posture related to craniofacial development. *Am J Orthod*. 1986;89:132–140.
- Işeri H, Solow B. Growth displacement of the maxilla in girls studied by the implant method. *Eur J Orthod*. 1990;12:389–398.
- Devadas S, Varma B, Mungara J, Joseph T, Saraswathi TR. Witkop tooth and nail syndrome: a case report. *Int J Paediatr Dent*. 2005;15:364–369.
- Giansanti JS, Long SM, Rankin JL. The "tooth and nail" type of autosomal dominant ectodermal dysplasia. *Oral Surg Oral Med Oral Pathol*. 1974;37:576–582.
- Chitty LS, Dennis N, Baraitser M. Hidrotic ectodermal dysplasia of hair, teeth, and nails: case reports and review. *J Med Genet*. 1996;33:707–710.
- Murdoch-Kinch CA, Miles DA, Poon CK. Hypodontia and nail dysplasia syndrome. Report of a case. *Oral Surg Oral Med Oral Pathol*. 1993;75:403–406.
- Mielnik-Błaszczak M, Tomankiewicz M. A rare case of tooth-nail syndrome. *Ann Univ Mariae Curie Skłodowska [Med]*. 2003;58:306–310.
- Akyuz S, Atasu A. Tooth and nail syndrome: genetic, clinical and dermatoglyphic findings: case report. *J Clin Pediatr Dent*. 1993;17:105–108.
- Pedrazzi ME. Treating the open bite. *J Gen Orthod*. 1997;8:5–16.
- Petrovic AG, Stutzmann JJ, Gasson N. The length of the mandible: is it genetically predetermined? In: Carlson DS, ed. *Craniofacial Biology Monograph 10, Craniofacial Growth Series*. Ann Arbor, Mich: Center for Human Growth and Development, University of Michigan; 1981.
- Meikle MC. The effect of a Class II intermaxillary force on the dentofacial complex in the adult *Macaca mulatta* monkey. *Am J Orthod*. 1970;58:323–340.
- McNamara JA Jr. Functional determinants of craniofacial size and shape. *Eur J Orthod*. 1980;2:131–159.
- Altug-Atac AT, Erdem D. Effects of three dimensional bi-metric maxillary distalizing arches and cervical headgear on dentofacial structures. *Eur J Orthod*. 2007;29:52–59. Epub 2006 Aug 21.
- Işeri H, Solow B. Continued eruption of maxillary incisors and first molars in girls from 9 to 25 years, studied by the implant method. *Eur J Orthod*. 1996;18:245–256.
- Thilander B, Odman J, Lekholm U. Orthodontic aspects of the use of oral implants in adolescents: a 10-year follow-up study. *Eur J Orthod*. 2001;23:715–731.
- Epker BN, Fish LC, eds. Systematic evaluation of the patient with a dentofacial deformity. In: *Dentofacial Deformities: Integrated Orthodontic and Surgical Correction*. Vol 1. St Louis, Mo: Publisher; 1986:3–46.