

Case Report

## Presurgical treatment of cleft lip and palate in Aicardi syndrome: A case report

Tsutomu Iwamoto\*<sup>1</sup>, Satoshi Fukumoto\*<sup>2</sup>, Aya Yamada\*<sup>1</sup>,  
Makiko Arakaki\*<sup>1</sup> and Kazuaki Nonaka\*<sup>1</sup>

\*<sup>1</sup> Section of Pediatric Dentistry, Division of Oral Health, Growth and Development, Faculty of Dental Science, Graduate School of Dental Science, Kyushu University 3-1-1 Maidashi, Higashi-ku, Fukuoka 812-8582, JAPAN

\*<sup>2</sup> Division of Pediatric Dentistry, Department of Oral Health and Development Sciences, Tohoku University Graduate School of Dentistry 4-1 Seiryō-machi, Aoba-ku, Sendai 980-8575, JAPAN

**Abstract** Aicardi syndrome is a rare neurodevelopment disorder characterized by agenesis of the corpus callosum, other developmental brain abnormalities, chorioretinal lacunae, severe seizures, and cleft lip and palate (CLP). This syndrome has been observed only in female due to be caused by an X-linked dominant gene that is lethal in hemizygous males. There has not been reported about the presurgical nasopalveolar molding (PNAM) treatment for Aicardi syndrome patient with CLP, although the importance of PNAM treatment for cleft lip is widely recognized. The purpose of this report was to present PNAM treatment for the case of Aicardi syndrome with CLP, along with a pertinent review of the literature, comparison to similar case reports, and to describe for the process of PNAM treatment in this syndrome.

### Key words

Aicardi syndrome,  
Cleft lip and palate,  
Presurgical nasopalveolar molding

### Introduction

Aicardi syndrome is a relatively rare and devastating developmental disorder. It was firstly described in 1965, as a congenital abnormality with a classic triad of total or partial agenesis of the corpus callosum, severe infantile spasms and chorioretinal lacunae<sup>1</sup>. Aicardi syndrome is an X-linked dominant disorder. The genetic defect is presumably lethal in males. Because of this genetic background, Aicardi syndrome has been reported in girls except 2 cases, which were phenotypic boys with a 47, XXY karyotype<sup>1,2</sup>. Further, all cases are sporadic, although this syndrome is genetic origin. Although only 1 case in 2 sisters was reported, no familial occurrences have been described<sup>3</sup>. Other associated anomalies, including gyral aberrations, cortical and subependymal heterotopias and variable but severe

psychomotor retardation, have been described in patients with this syndrome<sup>4,5</sup>. The outcome of Aicardi syndrome is very severe in most cases deteriorate during the first 5–6 years of life. The estimated survival rate is 76% at 6 years and 40% at 14 years<sup>6</sup>.

Cleft lip and palate (CLP) is the most prevalent congenital craniofacial birth defect in humans, affecting in approximately 1 in every 500 to 1,000 births worldwide<sup>7</sup>. Approximately 70% of CLP cases are non-syndromic, occurring as an isolated condition unassociated with any other recognizable anomalies, while the remaining 30% of syndromic cases are associated with deficits or structural abnormalities occurring outside the region of the cleft<sup>8</sup>. The syndromic cases can be subdivided into chromosomal anomalies, more than 350 Mendelian disorders, teratogens and uncategorized syndromes<sup>7</sup>. In Aicardi syndrome patients, CLP has been reported only 6 cases<sup>4,9–13</sup>.

The first common problem often experienced in

---

Received on March 31, 2008

Accepted on June 27, 2008

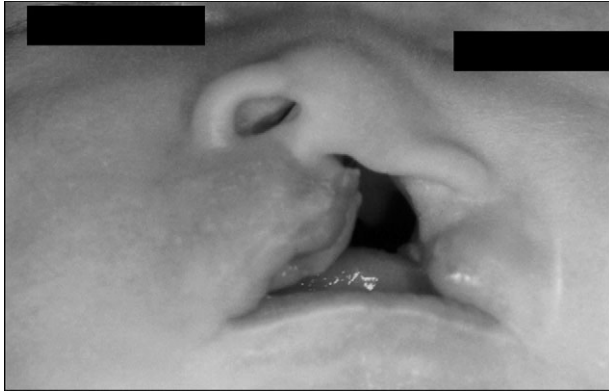


Fig. 1 Facial photograph at 5 days old

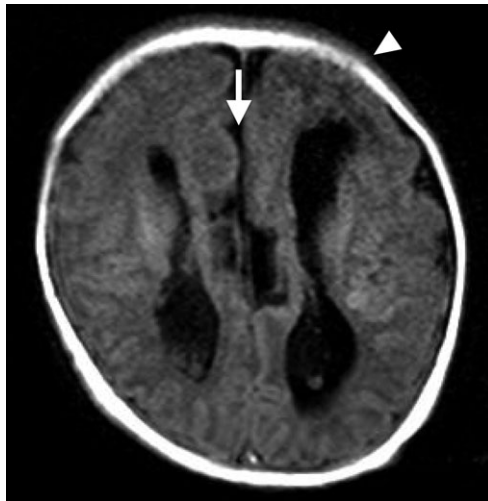

Fig. 2 Image of T1-weighted MRI  
Agenesis of corpus callosum (arrow) and polymicrogyria of the left frontal lobe (arrowhead) were observed.

CLP patients is difficulty of feeding. Therefore, management of the patients with CLP is carried out from birth. The Hotz-type plate has been used for a number of years in the early orthopedic treatment of cleft palate neonates<sup>14</sup>. The efficacy of the Hotz-type orthopedic plate in the improvement of feeding, normalizing of tongue position, and resulting presurgical reduction of cleft width in the alveolus and palate, has been described<sup>15</sup>. Recently, the presurgical treatment for cleft lip has been performed with presurgical nasoalveolar molding (PNAM). PNAM aimed to elevate the wing and the tip of the nose and subject to repositioning by developing the nasal cartilage before primary cheiloplasty<sup>16-19</sup>.

Aicardi syndrome with CLP has been reported

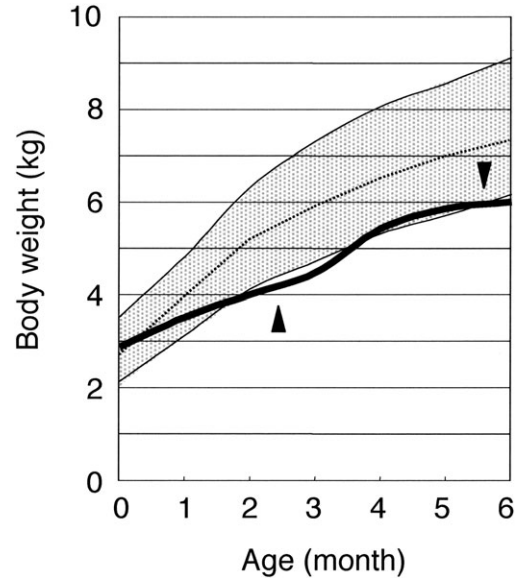


Fig. 3 Growth curve of this patient

Gray area demonstrates the body growth curve of normal Japanese infant, investigated by the Ministry of Health, Labor and Welfare in 2000. A dotted line shows average weight of the Japanese infants. Arrowheads show the time when she had a cold.

in the literature, however there have been no previous reports of presurgical treatment with the Hotz-type orthopedic plate and PNAM. In Aicardi syndrome, although the infantile spasms, one of the main symptoms, were considered to be difficult for presurgical treatment for CLP, we had performed almost same care for CLP patients without other symptoms.

### Case Report

The patient is the second female child born to non-consanguineous parents after a 40-week pregnancy. She was born to a 33-year-old woman after an uneventful delivery, with a birth weight of 2,862 g, length 49.5 cm and head circumference of 32.4 cm in the local maternity hospital. Apgar score was 10 after 1 and 5 minutes, respectively. The family history was negative for birth defect, genetic diseases or developmental delay. There was no history of maternal exposure to teratogens or toxins.

Unilateral cleft lip and cleft palate were observed (Fig. 1). Further, her left eye did not open from the neonatal. Therefore, she was consulted pediatrician and ophthalmologist for evaluation of morphologic aberration. Ophthalmologic examination revealed

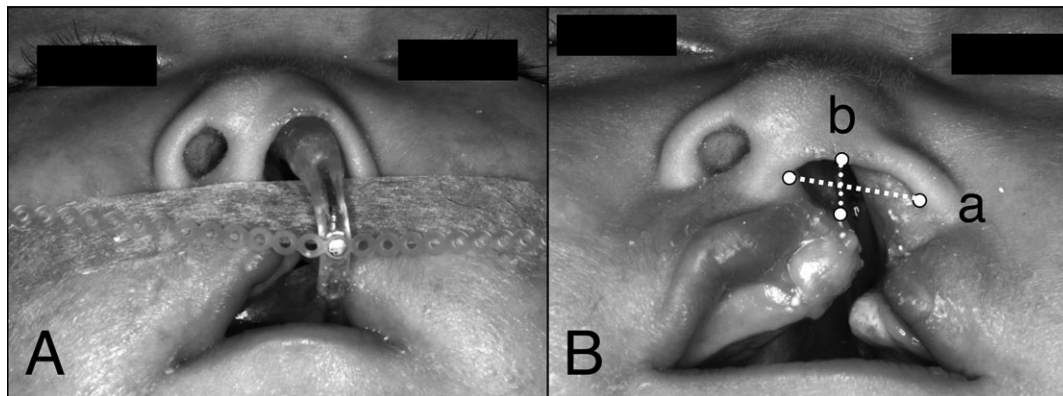


Fig. 4 Facial photographs with (A) or without PNAM (B) at 6 months old  
a: nostril width; b: nostril height

microcornea, hypoplastic optic nerve and chorio-retinal lacunae in her left eye. Brain MRI detected schizencephaly in the right frontoparietal lobe, polymicrogyria in the left frontal lobe and agenesis corpus callosum (Fig. 2). At 6 weeks of age, infantile spasm was presented. Specifically, these spasms consisted of tonic activity of the right leg with subsequent spread the other limbs. Spasms tend to begin soon after arousal from sleep. Individual spasms typically within 5 seconds and occur in clusters, ranging from 10 to 30 spasms at a time. She had dozens of clusters and about 100 spasms per day. From these findings, she was diagnosed as Aicardi syndrome. However, these spasms remain uncontrollable despite treatment with antispastic agents.

We visited to the local maternity hospital for a medical examination and preparation for the Hotz-type plate at birth. Five days after, she left that maternity hospital and visited our hospital. We prepared the Hotz-type plate using her oral impression at birth and inserted at the initial visit to our hospital. Although it had taken about 30 minutes to drink 40ml of milk before inserting the Hotz-type plate, it came to take same amount of milk in about 7 minutes after inserting it. Then, she came to drink milk well and also put on weight favorably (Fig. 3). Two weeks later, after checking nutrition, the Hotz-type plate was provided with a nasal stent for the early orthopedic treatment of nose (Fig. 4A). We have started the presurgical infant orthopedics with PNAM from the 3rd week of after the birth. There were not any problems of nursing even after providing PNAM. Further, even after the spasm

Table 1 Width and height of nostril at different time points

Age	5 days	6 months
Nostril width	15.6mm	11.5mm
Nostril height	1.1 mm	4.3mm

Nostril width: the horizontal distance between inner margins of nostril from transition from columella/upper lip to nasal wing/upper lip. Nostril height: the vertical distance between alveolar process and lower border of ala nasi (see Fig. 2)

occurred, the influence by PNAM was not observed.

At the end of presurgical treatment, the cleft of maxillary alveolus was narrowed, the nostril width was decreased, and the nostril height was elevated (Fig. 4B). Measurement of these width and height took during the first 6 months of life. The nostril width decreased by 4.1 mm, while elevation of the nostril height amounted to 3.2 mm (Table 1). Further, in intraoral measurement, alveolar cleft width (D-D') decreased by 5.1 mm. Both alveolar segment had growth to the cleft side was observed (Fig. 5).

### Discussion

Patients with Aicardi syndrome is often accompanied by various congenital anomalies in other organ systems, including pencephaly, cortical heterotopias, Arnold-Chiari malformation, papilloma of the choroids plexus, Dandy-Walker malformation, costovertebral anomalies, digital malformations and hypotonia, besides major symptoms that include total and partial agenesis of the corpus callosum,

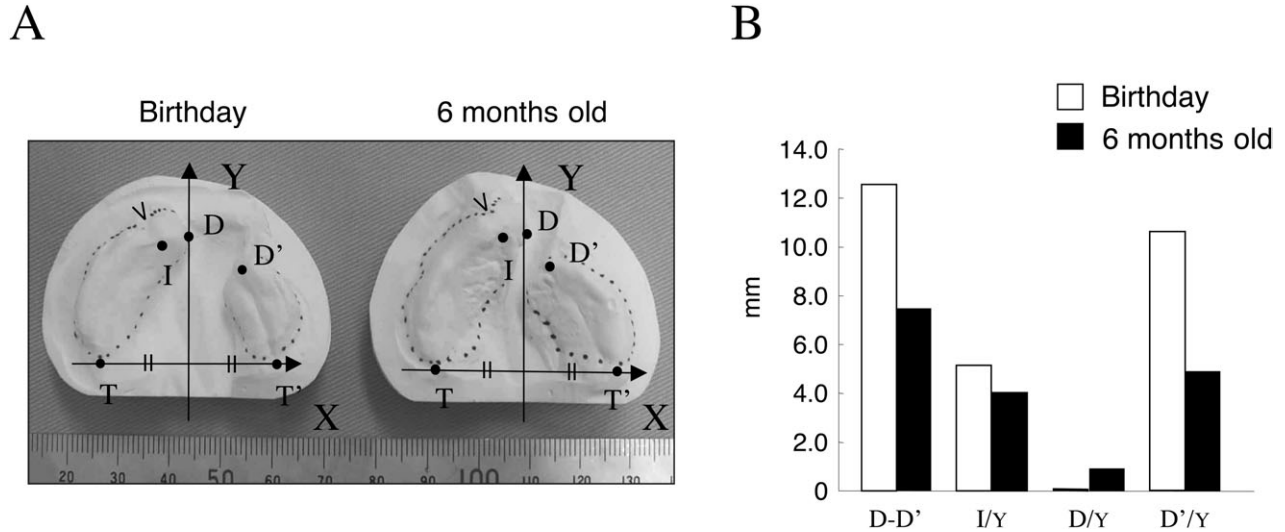


Fig. 5 Two study models and alveolar landmarks

Left model is at birthday and right is the day of cheiloplasty (A). Changes in morphology of alveolus after treatment with the Hotz-type plate (B). T: tuberosity point, the crossing point of the hamular sulcus and alveolar ridge. I: incisal point, the crossing point of the line from incisive papilla and alveolar ridge. D: edge point, the edge of alveolar ridge facing the cleft. D-D': distance between D and D'. I/Y: horizontal dimension from Y-axis to I. D/Y: horizontal dimension from Y-axis to D. D'/Y: horizontal dimension from Y-axis to D'

Table 2 Cleft lip and palate in Aicardi syndrome

Author	Age	Feature	Year
1 Robinow <i>et al.</i>	6 months	cleft lip and posterior palate	1984
2 Sato <i>et al.</i>	14 days	cleft lip and palate	1987
3 Donnenfeld <i>et al.</i>	3 years	cleft lip and palate	1989
4 McPherson <i>et al.</i>	15 months	cleft lip and palate	1990
5 Umansky <i>et al.</i>	10 months	cleft lip and palate	1994
6 Jensen <i>et al.</i>	2 days	cleft posterior palate	2004
7 Iwamoto <i>et al.</i> [this study]	6 months	cleft lip and palate	2008

chorioretinal lacunae and infant spasms<sup>1,13</sup>). This patient exhibits CLP in association with Aicardi syndrome.

Aicardi syndrome has been described in over 400 patients. In the PubMed search (NCBI) from 1963 to 2008, only 6 cases have been reported about Aicardi syndrome associated with CLP<sup>4,9-13</sup>). This patient is the 7th report of this type of Aicardi syndrome. Although the number of case reports is very few, CLP should be considered to be rare complication of Aicardi syndrome. Cleft types of 7 cases are 6 with cleft lip and palate (6/7, 85.7%) and 1 with isolated cleft palate (1/7, 14.3%) (Table 2). A case with cleft lip alone has not been reported.

There are 2 cases to have reported the plasty for CLP. McPherson *et al.*<sup>11</sup>) described that the patient, a 7 months old, had been repaired the left side unilateral cleft lip. Umansky *et al.*<sup>12</sup>) reported that they performed a cheiloplasty at 10 weeks of age by a modified rotation-advancement technique and repaired of the wide cleft palate at 10 months of age by a pushback technique. To our knowledge, the association of CLP with Aicardi syndrome has not been reported previously in the presurgical treatment. Therefore, this is the first report to describe about the presurgical treatment for Aicardi syndrome with CLP. At the start of treatment for CLP, we worried about whether the Hotz-type orthopedic plate or



PNAM may cause some problems such as unpredictable choke or wound, when the infant spasm occurred. However, while the spasm had occurred, there was no problem about Hotz-type plate and PNAM in particular. It would appear that despite ranging from 10 to 30 spasms at a time, the time of individual spasm is less than 5 seconds. However, we prescribed that the device of PNAM might be taken out from mouth, when a spasm occurred. In other point, the nursing in our case was good using Hotz-type plate. Although it was low levels as compared with the body growth curve of normal Japanese infant investigated by the Ministry of Health, Labor and Welfare in 2000, her weight increased favorably and exceeded 5 kg at late 3 months old (Fig. 3). When she had caught the cold at the time of 2 months and 5 months after birth, she had not gained much weight (Fig. 3). However, her weight was regained after that. Further, generally, a cheiloplasty is performed at the time for 3 months old in our hospital, but her cheiloplasty was performed at 6 months of age due to evaluation her best condition. Therefore, we performed presurgical treatment with PNAM for about 6 months. The result of PNAM treatment is consistent with similarly treated cases described in literature. The nostril height achieved 3.2 mm elevation, and the nostril width reduced 4.1 mm for 6 months in the present case. Liou *et al.*<sup>19)</sup> achieved the alar elevation to an average 2.7 mm and the reduction of alar width by 3.4 mm in their patients. Singh *et al.*<sup>18)</sup> arrived at 2.2 mm lifting of the alar after 3.5 months. Although there are still questions in PNAM treatment whether the those effect continue in long term observation or how nasal shape will be after the end of growth, it is sure that PNAM treatment might be a benefit treatment for CLP patients. Further, the Hotz-type plate is accepted to be useful not only feeding but also presurgical reduction of cleft width in the alveolus and palate<sup>15)</sup>. Actually, each alveolar segment had grown along the guidance of the Hotz-type orthopedic plate and toward the cleft side. As a result of our orthopedic treatment, the reduction of alveolar cleft width was observed. (Fig. 5) These results indicate that a design and adjustment of the Hotz-type plate are very important to raise curative effect.

In summary, Aicardi syndrome is one of the intractable diseases, but some hopeful cures may be found for the future, and it seems that the outcome will be improved. For the quality of life of patients

and patient's family, we have to try to give all the best medical care. The presurgical treatment with PNAM has been expected as an effective treatment for patients with CLP to elevate of the nasal wing of cleft side and to reduce of palatal and alveolar cleft wide. Although it seemed that poor control of the infant spasm, might be an obstacle for the presurgical treatments, we had performed almost normal presurgical treatments with PNAM. It would be believed that our findings help presurgical treatment in Aicardi syndrome patients with CLP.

## References

- 1) Aicardi, J.: Aicardi syndrome. *Brain Dev* **27**: 164–171, 2005.
- 2) Hopkins, I.J., Humphrey, I., Keith, C.G., Susman, M., Webb, G.C. and Turner, E.K.: The Aicardi syndrome in a 47, XXY male. *Aust Paediatr J* **15**: 278–280, 1979.
- 3) Molina, J.A., Mateos, F., Merino, M., Epifanio, J.L. and Gorrono, M.: Aicardi syndrome in two sisters. *J Pediatr* **115**: 282–283, 1989.
- 4) Donnenfeld, A.E., Packer, R.J., Zackai, E.H., Chee, C.M., Sellinger, B. and Emanuel, B.S.: Clinical, cytogenetic, and pedigree findings in 18 cases of Aicardi syndrome. *Am J Med Genet* **32**: 461–467, 1989.
- 5) Menezes, A.V., MacGregor, D.L. and Buncic, J.R.: Aicardi syndrome: natural history and possible predictors of severity. *Pediatr Neurol* **11**: 313–318, 1994.
- 6) Rosser, T.L., Acosta, M.T. and Packer, R.J.: Aicardi syndrome: spectrum of disease and long-term prognosis in 77 females. *Pediatr Neurol* **27**: 343–346, 2002.
- 7) Murray, J.C.: Gene/environment causes of cleft lip and/or palate. *Clin Genet* **61**: 248–256, 2002.
- 8) Schutte, B.C. and Murray, J.C.: The many faces and factors of orofacial clefts. *Hum Mol Genet* **8**: 1853–1859, 1999.
- 9) Robinow, M., Johnson, G.F. and Minella, P.A.: Aicardi syndrome, papilloma of the choroid plexus, cleft lip, and cleft of the posterior palate. *J Pediatr* **104**: 404–405, 1984.
- 10) Sato, N., Matsuishi, T., Utsunomiya, H., Yamashita, Y., Horikoshi, T., Okudera, T. and Hashimoto, T.: Aicardi syndrome with holoprosencephaly and cleft lip and palate. *Pediatr Neurol* **3**: 114–116, 1987.
- 11) McPherson, E. and Jones, S.M.: Cleft lip and palate in Aicardi syndrome. *Am J Med Genet* **37**: 318–319, 1990.
- 12) Umansky, W.S., Neidich, J.A. and Schendel, S.A.: The association of cleft lip and palate with Aicardi syndrome. *Plast Reconstr Surg* **93**: 595–597, 1994.
- 13) Jensen, A.A. and Christiansen, S.P.: Aicardi syndrome with Pierre Robin sequence. *J Aapos* **8**: 187–189, 2004.

- 14) Hotz, M. and Gnoinski, W.: Comprehensive care of cleft lip and palate children at Zurich university: a preliminary report. *Am J Orthod* **70**: 481–504, 1976.
- 15) Kozelj, V.: Changes produced by presurgical orthopedic treatment before cheiloplasty in cleft lip and palate patients. *Cleft Palate Craniofac J* **36**: 515–521, 1999.
- 16) Grayson, B.H., Santiago, P.E., Brecht, L.E. and Cutting, C.B.: Presurgical nasolabial molding in infants with cleft lip and palate. *Cleft Palate Craniofac J* **36**: 486–498, 1999.
- 17) Ezzat, C.F., Chavarria, C., Teichgraber, J.F., Chen, J.W., Stratmann, R.G., Gateno, J. and Xia, J.J.: Presurgical nasolabial molding therapy for the treatment of unilateral cleft lip and palate: a preliminary study. *Cleft Palate Craniofac J* **44**: 8–12, 2007.
- 18) Singh, G.D., Levy-Bercowski, D. and Santiago, P.E.: Three-dimensional nasal changes following nasolabial molding in patients with unilateral cleft lip and palate: geometric morphometrics. *Cleft Palate Craniofac J* **42**: 403–409, 2005.
- 19) Liou, E.J., Subramanian, M., Chen, P.K. and Huang, C.S.: The progressive changes of nasal symmetry and growth after nasolabial molding: a three-year follow-up study. *Plast Reconstr Surg* **114**: 858–864, 2004.