

# Root Resorption and Immune System Factors in the Japanese

Masato Nishioka<sup>a</sup>; Hideki Ioi<sup>b</sup>; Shunsuke Nakata<sup>c</sup>; Akihiko Nakasima<sup>d</sup>; Amy Counts<sup>e</sup>

**Abstract:** The objective of this study was to determine whether there is an association between excessive root resorption and immune system factors in a sample of Japanese orthodontic patients. The records of 60 orthodontic patients (18 males, age  $17.7 \pm 5.7$  years; 42 females, age  $16.4 \pm 6.0$  years) and 60 pair-matched controls (18 males, age  $15.9 \pm 4.5$  years; 42 females, age  $18.5 \pm 5.2$  years) based on age, sex, treatment duration, and the type of malocclusion were reviewed retrospectively. The validity of our hypothesis was tested using the logistic regression analysis. The pretreatment records revealed that the incidence of allergy and root morphology abnormality was significantly higher in the root resorption group ( $P = .030$  and  $.001$ ), with a mean odds ratio of 2.794 and 6.317 and 95% confidence interval of 1.107–7.053 and 2.043–19.537, respectively. The incidence of asthma also tended to be higher in the root resorption group. From these results, we concluded that allergy, root morphology abnormality, and asthma may be high-risk factors for the development of excessive root resorption during orthodontic tooth movement in Japanese patients. (*Angle Orthod* 2006;76:103–108.)

**Key Words:** Root resorption; Risk factors; Allergy; Asthma; Root morphology

## INTRODUCTION

Alveolar bone resorption is the basic mechanism of orthodontic tooth movement.<sup>1</sup> However, the development of excessive root resorption during orthodontic treatment is considered an adverse side effect of the mechanical force-induced movement of teeth. Inflammation is an integral part of the tissue response to orthodontic force.<sup>2</sup> In this process, immune cells migrate out of the capillaries in the periodontal ligament (PDL) and interact with locally residing cells by elaborating a large array of signal molecules.<sup>3,4</sup> The presence of primed leucocytes in the peripheral blood,

which originate in diseased organs such as lungs and joints, supports the notion of a possible association between excessive orthodontic root resorption and pathological conditions that affect or involve the immune system.

Davidovitch et al<sup>5</sup> hypothesized that individuals who have medical conditions that affect the immune system may be at a high level of risk for developing excessive root resorption during the course of orthodontic treatment. In reviewing orthodontic patient records at the University of Oklahoma, they discovered that the incidence of asthma, allergies, and signs indicative of psychological stress were significantly higher in patients who had experienced excessive root resorption during orthodontic treatment as compared with the group of orthodontic patients who had completed their course of treatment without suffering this unfortunate outcome.

McNab et al<sup>6</sup> reported that the incidence of external apical root resorption was elevated in an asthma group. However, both asthmatics and healthy patients exhibited similar amounts of moderate and severe resorption. Moreover, in healthy patients, the incidence of external apical root resorption was 2.30 times higher for Begg appliances compared with edgewise, and it was 3.72 times higher for patients for whom extractions were performed compared with those for whom no extractions were performed.<sup>7</sup>

<sup>a</sup> Graduate Resident, Department of Orthodontics, Kyushu University, Fukuoka, Japan.

<sup>b</sup> Lecturer, Department of Orthodontics, Kyushu University, Fukuoka, Japan.

<sup>c</sup> Associate Professor, Department of Orthodontics, Kyushu University, Fukuoka, Japan.

<sup>d</sup> Professor, Department of Orthodontics, Kyushu University, Fukuoka, Japan.

<sup>e</sup> Professor, Dental School of Orthodontics, Jacksonville University, Jacksonville, Fla.

Corresponding author: Hideki Ioi, DDS, PhD, Department of Orthodontics, Kyushu University, 3-1-1 Maidashi, Higashi-ku, Fukuoka 812-8582, Japan (e-mail: ioi@dent.kyushu-u.ac.jp).

Accepted: March 2005. Submitted: January 2005.

© 2006 by The EH Angle Education and Research Foundation, Inc.

The susceptibility to orthodontic root resorption may not be caused by the same risk factors in different populations. Therefore, it is important to test the above hypothesis in different ethnic groups. The objective of this study was to determine the degree of association between excessive orthodontic root resorption and immune system factors in a Japanese population.

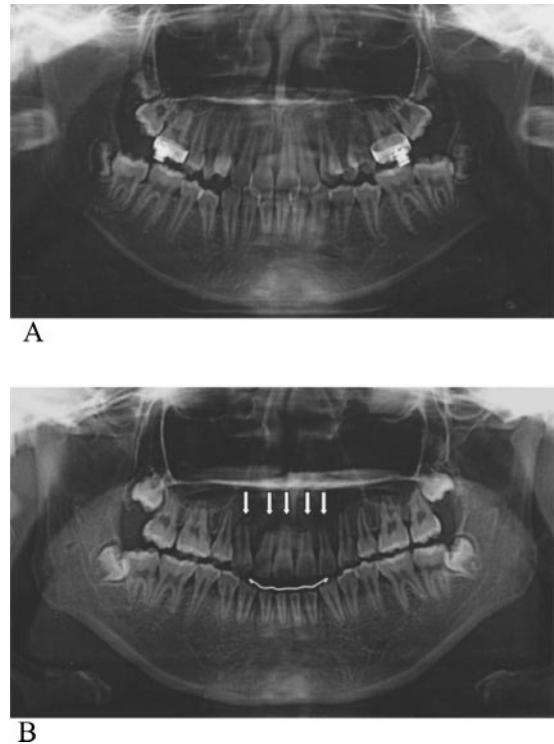
## MATERIALS AND METHODS

The sample was selected from the files of the Department of Orthodontics, Faculty of Dentistry, Kyushu University, Fukuoka, Japan, which included more than 1540 documented treated cases. The records of 581 patients who were treated with fixed edgewise appliance were collected. All patients had completed their course of orthodontic treatment. Their records contained a pretreatment questionnaire, pre- and post-treatment facial photographs, cephalograms, dental photographs, panoramic radiographs, dental casts, diagnosis, treatment plan, and descriptive summaries of treatment progression.

Determination of the root resorption status of each patient was established by comparing the dental panoramic radiographs that had been taken before and after treatment. Only teeth with complete root formation were measured. Apices that could not be observed accurately were excluded. Root lengths were measured to the nearest 0.1 mm directly from the radiographs using measuring calipers. All teeth were measured along the tooth's longitudinal axis for root length (defined as cemento-enamel junction to apex of root). This method was similar to that used by Linge and Linge.<sup>8</sup> We confirmed the reliability of comparing the radiographs before and after treatment by comparing the crown length before and after treatment. The teeth whose crown lengths (defined as cemento-enamel junction to incisal edge) were obviously different before and after treatment because of the distortion of the image were excluded from this study. Individuals were assigned to the root resorption group when it was determined that one or more of their dental roots had been shortened by at least 25% of the original length in the time that had elapsed between the two radiographs (Figure 1).

### Reliability

Method error was assessed by the random selection of 10 panoramic radiographs on three separate occasions. One-way analysis of variance, used to test the equality of means for the root-length measurements, suggested that this was done in a consistent manner. Mean scores for the root-length measurements ( $P = .97$ ) did not significantly differ for the three



**FIGURE 1.** (A) Dental panoramic radiograph before orthodontic treatment. (B) Dental panoramic radiograph after orthodontic treatment. Excessive root resorption is evident in all maxillary incisors (arrows).

measurements. The method error can thus be considered negligible.

In this sample and our criteria, 60 individuals were found to have developed excessive resorption of dental roots. This reduction in root substance can potentially jeopardize the longevity of the afflicted teeth, especially in cases where the PDL attachment is also reduced by shortening of the alveolar process because of periodontal disease.<sup>5</sup> In the root resorption group, 18 subjects were male (age  $17.7 \pm 5.7$  years) and 42 subjects were female (age  $16.4 \pm 6.0$  years).

A control group was selected from the remaining patients of this sample who did not display radiographic evidence of dental root resorption at the end of their orthodontic treatment. Each individual in the control group was pair matched to another in the root resorption group based on age, sex, treatment duration, and the type of malocclusion (Table 1). In the control group, 18 subjects were male (age  $15.9 \pm 4.5$  years) and 42 subjects were female (age  $18.5 \pm 5.2$  years). Student's *t*-tests were used to compare the mean differences in age and the treatment duration between the root resorption group and the control group. No significant differences in the mean age and the treatment duration were found between the two groups.

The types of malocclusion exhibited by individuals

**TABLE 1.** Comparison of Means and Standard Deviations of Age and Treatment Period in the Root Resorption and Control Groups

	Number	Age (y)	Treatment Period (y)
Root resorption group			
Male	18	17.7 ± 5.7	2.78 ± 0.81
Female	42	16.4 ± 6.0	3.24 ± 1.31
Total	60	16.8 ± 5.9	3.10 ± 1.19
Control group			
Male	18	15.9 ± 4.5	2.77 ± 0.53
Female	42	18.5 ± 5.2	3.04 ± 0.56
Total	60	17.7 ± 5.1	2.96 ± 0.56

in each group are shown in Table 2. The control group was composed of exactly the same number and type of malocclusion as their counterparts in the root resorption group. The numbers of extraction or nonextraction cases were also recorded for each group.

The root shape was recorded subjectively as normal or abnormal (shortened, blunt, eroded, pointed, bent, bottle shaped) by examining pretreatment dental panoramic radiographs that were taken before the onset of treatment.

Subjects or their legal guardians recorded answers to a questionnaire before the onset of treatment. The questionnaire sought information on personal demographics, medical history, dental history, and oral habits. Information on medical history included local or systemic diseases, details on medication type and use, and the presence of allergies and asthma. Dental history questions referred to details regarding previous dental treatment and information regarding past oral injuries. Habits listed in the questionnaire were thumb sucking, nail biting, tongue thrusting, and mouth breathing.

The pretreatment clinical examination did not include detailed probing of gingival sulci. Therefore, we determined the presence of healthy or inflamed gingiva by examining the appearance of the gingival tissues on the intraoral photographs. Determinations of

gingival health status were based on evaluation of gingival color and swelling.

**Statistical analysis**

The validity of our hypothesis was tested by the logistic regression analysis using the Stat View 5.0 program (SAS Institute Inc, Cary, NC). This analysis is a variation of ordinary regression, applicable when the observed outcome is restricted to two values, which represent the occurrence or nonoccurrence of an outcome event (root resorption). It produces a formula that predicts the probability of the occurrence as a function of the independent variables. Logistic regression also produces odds ratios associated with each predictor variables (root morphology abnormality, extraction, trauma, gingivitis, allergy, asthma, systemic disease, medication use, thumb sucking, nail biting, tongue thrusting, mouth breathing). The odds of an event are defined as the probability of the outcome event occurring divided by the probability of the event not occurring.

**RESULTS**

The prevalence of root resorption was 10.3%. The distribution of each risk factor in the root resorption and the control groups is shown in Table 3. The logistic regression analysis is shown in Table 4. The incidence of allergy and root morphology abnormality was significantly higher in the root resorption group ( $P = .030$  and  $.001$ ), with a mean odds ratio of 2.794 and 6.317 and 95% confidence interval of 1.107–7.053 and 2.043–19.537, respectively. The incidence of asthma also tended to be higher in the root resorption group ( $P = .063$ ), with a mean odds ratio of 4.388 and 95% confidence interval of 0.924–20.833. The incidences of the other factors were found to be insignificant between the two groups.

**TABLE 2.** Distribution of the Type of Malocclusion in the Root Resorption and Control Groups

	Class I (n)	Class II (n)	Class III (n)	Class I/II <sup>a</sup> (n)	Class I/III <sup>b</sup> (n)	Class II/III <sup>c</sup> (n)
Root resorption group						
Male	4	4	3	3	3	1
Female	6	15	8	7	6	0
Total	10	19	11	10	9	1
Control group						
Male	4	5	4	3	1	1
Female	6	14	7	7	8	0
Total	10	19	11	10	9	1

<sup>a</sup> One side is Class I and the other side is Class II malocclusion.  
<sup>b</sup> One side is Class I and the other side is Class III malocclusion.  
<sup>c</sup> One side is Class II and the other side is Class III malocclusion.

**TABLE 3.** Prevalence of Each Risk Factor in the Root Resorption and Control Groups

Variable	Root resorption group			Control group		
	Male (n)	Female (n)	Total (n)	Male (n)	Female (n)	Total (n)
Root morphology abnormality	5	17	22	4	2	6
Extraction	14	30	44	9	28	37
Trauma	1	4	5	2	1	3
Gingivitis	13	21	34	11	23	34
Allergy	9	15	24	3	10	13
Asthma	7	2	9	0	3	3
Systemic disease	1	5	6	3	0	3
Medication use	1	0	1	1	0	1
Thumb sucking	3	5	8	1	1	2
Nail biting	4	6	10	3	4	7
Tongue thrusting	1	0	1	0	1	1
Mouth breathing	0	6	6	2	7	9

**TABLE 4.** Logistic Regression Analysis of Each Risk Factor

Risk Factors	$\chi^2$	P Value	Odds Ratio	95% Confidence Interval
Root morphology abnormality	10.241	.001	6.317	2.043–19.537
Extraction	0.825	.364	1.500	0.625–3.596
Trauma	0.041	.840	1.194	0.214–6.676
Gingivitis	0.065	.799	0.898	0.393–2.054
Allergy	4.730	.030	2.794	1.107–7.053
Asthma	3.463	.063	4.388	0.924–20.833
Systemic disease	2.235	.135	3.651	0.668–19.951
Medication use	1.141	.285	0.187	0.009–4.050
Thumb sucking	2.355	.125	3.935	0.684–22.643
Nail biting	1.242	.265	1.974	0.597–6.533
Tongue thrusting	0.040	.841	1.341	0.077–23.392
Mouth breathing	0.121	.728	0.800	0.227–2.821

## DISCUSSION

Most investigators have reported that the presence of root resorption is common after orthodontic treatment.<sup>9</sup> The prevalence varies widely, depending on several factors, including the choice of criteria for root resorption and the type of appliance.<sup>9</sup> Moderate to severe apical root resorption (>2 mm <1/3 of the root length) has been found in 10–17% of orthodontically treated patients<sup>8,10,11</sup> and excessive root resorption (>1/3 of the root length) in 1–5%.<sup>12,13</sup> The prevalence of root resorption in this study was 10.3%. Considering that the criteria for root resorption in our study were approximately moderate to severe, the prevalence of 10.3% is regarded as average.

Orthodontic tooth movement is facilitated by resorption of the alveolar bone by osteoclasts. The role of these cells is to resorb alveolar bone in sites of mechanically compressed PDL, thus enabling dental roots in these locations to move in the direction of the applied orthodontic force.<sup>1</sup> In these sites of tissue compression, which frequently become necrotic, one also finds multinucleated odontoclasts engaged in resorbing the dental roots.<sup>14–16</sup> Osteoclasts originate in the immune system, and their mononucleated progenitors

are derived from the monocyte/macrophage lineage.<sup>17</sup> Odontoclasts are osteoclastlike, multinucleated, and are most likely also derived from the immune system. Therefore, it can be concluded that cells derived from the immune system are directly responsible for the resorption of alveolar bone that promotes tooth movement and the excessive root resorption that sometimes accompanies the force-induced tissue remodeling.<sup>3,18</sup>

In this study, it was found that allergy and asthma might be an etiological factor in excessive root resorption. The same association was found in earlier studies.<sup>5,19</sup> On the other hand, McNab et al<sup>6</sup> reported that the incidence of moderate and severe root resorption was similar in both asthmatics and healthy patients, although they found elevated incidence of overall root resorption in the asthma group. Owman-Moll and Kuroi<sup>19</sup> also described that there might be a link between allergy and the extent of root resorption, but no statistically significant difference was found. However, those studies were primarily performed on white subjects. Our finding, derived from an examination of the clinical records of Japanese subjects, strongly supports the hypothesis that allergy and asthma may be high-risk

factors for the development of excessive root resorption during the orthodontic treatment.

Synthetic steroids are used as anti-inflammatory and immunosuppressive agents in the treatment of a wide range of chronic medical conditions. Corticosteroids interfere with the coupling of resorption and deposition cycle in normal bone. Ong et al<sup>20</sup> stated that steroid treatment suppressed clastic activity in the rat. A low-dose systemic prednisolone reduced growth hormone receptor and insulinlike growth factor-I receptor immunoreactivity in dental and paradental tissues in the rat, although tooth movement was not inhibited with a low-dose prednisolone treatment.<sup>21</sup>

In this retrospective study, we could not find the association between the excessive root resorption and medication use. The weakness of this retrospective study design was that the predictor variables could not be controlled. Medical history was self-reported but was verified by a physician. Medication use information was self-reported in the questionnaire at the onset of the treatment. Further investigation in the form of a prospective study involving a much larger sample using a well-aimed investigative method would be necessary to determine a potential medication etiology.

Our results also indicated that abnormal root shape was associated with excessive root resorption ( $P = .001$ ). This finding is in agreement with the results of the previous studies.<sup>22-25</sup> We did not make any attempts to differentiate between the various types of abnormal root anatomy. If the same orthodontic force is applied to the dental crown, the root apex is exposed to increasing stress as the root becomes shorter. In addition, when the same orthodontic force is applied to the root apex, the distribution of the stress is different according to the types of root anatomy and the dental root with pointed or bent shape may be exposed to greater stress than roots with normal morphological features. These increased stresses may traumatize the apical PDL, followed by an inflammatory/repair process, which progresses to resorption of the root apex.

Patients with periodontal disease have circulating primed monocytes, and the sera of patients with periodontal disease contain high levels of proinflammatory cytokines.<sup>26</sup> However, in this study, gingival inflammation did not have a significant association with the orthodontic root resorption. This lack of an association is most likely because of the method used to detect the status of periodontal health, ie, examination of intraoral photographs. Because this was a retrospective study, we could not rectify this deficiency. In a future prospective study, we intend to include proper examinations of periodontal health.

In cases requiring tooth extraction, the remaining teeth are usually moved relatively greater distances,

particularly when maxillary incisors are retracted to reduce a large overjet.<sup>22,24,27</sup> In addition, tooth extraction and the ensuing wound healing attracts vast numbers of immune cells to the extraction site. These inflammatory cells may directly or indirectly spread from the wound site to tissues surrounding adjacent teeth. They produce large amounts of cytokines that enter the circulation and exit into the extravascular space in the PDL of neighboring mechanically stressed teeth, which regulates remodeling activities not only at the extraction site but also in tissues surrounding adjacent teeth. However, in this study, we did not find a significant association between extraction of permanent teeth and orthodontic root resorption. Therefore, we conclude that healing of extraction sites may be primarily a local event, which may not promote the resorption of adjacent teeth.

One limitation of this study was that determination of the root resorption status of each patient was established by comparing the dental panoramic radiographs that had been taken before and after treatment. This method of examination makes it possible to view the whole dentition. However, its main drawback is distortion of the tooth image, predominantly in the incisor region.<sup>5</sup> In contrast, lateral cephalograms permit the examination with very little distortion. However, in the latter film, it is difficult to distinguish between the left and right side. Clearly, periapical radiographs are the preferable means to determine the size and shape of dental roots, but these radiographs were not available to us this time.

## CONCLUSIONS

- Allergy, root morphology abnormalities, and asthma may be considered high-risk factors for the development of excessive root resorption during the course of orthodontic treatment in a Japanese population.
- A prospective study involving a much larger sample, using a well-aimed investigative method, would add much needed information that could be used in the quest to determine the etiology and possible treatment of orthodontic root resorption.

## REFERENCES

1. Reitan K. Tissue behavior during orthodontic tooth movement. *Am J Orthod.* 1960;46:881-890.
2. Storey E. The nature of tooth movement. *Am J Orthod.* 1973;63:292-314.
3. Davidovitch Z, Okamoto Y, Gogen H, Saito I, Vitouladitis I, Dobeck J, Shanfeld J. Orthodontic forces stimulate alveolar bone marrow cells. In: Davidovitch Z, Norton LA, eds. *Biological Mechanisms of Tooth Movement and Craniofacial Adaptation*. Boston, Mass: Harvard Society for the Advancement of Orthodontics; 1996:255-270.
4. Davidovitch Z, Okamoto Y, Gogen H, Shanfeld J. Biological

- response to tooth movement. In: Sachdeva RCL, Bantleon HP, White L, Johnson J, eds. *Orthodontics for the Next Millennium*. Glendora, Calif: Ormco; 1997:1–30.
5. Davidovitch Z, Lee YJ, Counts AL, Park YG, Bursac Z. The immune system possibly modulates orthodontic root resorption. In: Davidovitch Z, Mah J, eds. *Biological Mechanisms of Tooth Movement and Craniofacial Adaptation*. Boston, Mass: Harvard Society for the Advancement of Orthodontics; 2000:207–217.
  6. McNab S, Battistutta D, Taverne A, Symons AL. External apical root resorption of posterior teeth in asthmatics after orthodontic treatment. *Am J Orthod Dentofacial Orthop*. 1999;116:545–551.
  7. McNab S, Battistutta D, Taverne A, Symons AL. External apical root resorption following orthodontic treatment. *Angle Orthod*. 2000;70:227–232.
  8. Linge L, Linge BL. Patients characteristics and treatment variables associated with apical root resorption during orthodontic treatment. *Am J Orthod Dentofacial Orthop*. 1991;99:35–43.
  9. Thilander B, Rygh P, Reitan K. Tissue reactions in orthodontics. In: Graber TM, Vanarsdall RL, eds. *Orthodontics: Current Principles and Techniques*. 3rd ed. St Louis, Mo: Mosby; 2000:117–191.
  10. Hollender L, Rönnerman A, Thilander B. Root resorption, marginal bone support and clinical crown length in orthodontically treated patients. *Eur J Orthod*. 1980;2:197–205.
  11. Tagaya Y, Shimizu Y, Furuta T, Mitani H. A study of the risk diagnosis of root resorption during orthodontic treatment (part 1): an epidemiological survey of root resorption in orthodontic treatment at Tohoku University Dental Hospital [in Japanese]. *Orthod Waves*. 1998;57:359–368.
  12. Levander E, Malmgren O. Evaluation of the risk of root resorption during orthodontic treatment: a study of upper incisors. *Eur J Orthod*. 1988;10:30–38.
  13. Davidovitch Z. Etiologic factors in force-induced root resorption. In: Davidovitch Z, Norton LA, eds. *Biological Mechanisms of Tooth Movement and Craniofacial Adaptation*. Boston, Mass: Harvard Society for the Advancement of Orthodontics; 1996:349–355.
  14. Reitan K. Initial tissue behavior during apical root resorption. *Angle Orthod*. 1974;44:68–82.
  15. Brudvik P, Rygh P. The initial phase of orthodontic root resorption incident to local compression of the periodontal ligament. *Eur J Orthod*. 1993;15:249–263.
  16. Brudvik P, Rygh P. Transition and determinants of orthodontic root resorption-repair sequence. *Eur J Orthod*. 1995;17:177–188.
  17. Rossi M, Whitcomb S, Lindemann R. Interleukin-1 $\beta$  and tumor necrosis factor- $\alpha$  production by human monocytes cultured with L-thyroxine and thyrocalcitonin: Relation to severe root resorption. *Am J Orthod Dentofacial Orthop*. 1996;110:399–404.
  18. Davidovitch Z, Gogen MH, Okamoto Y, Slivka MW, Shanfeld JL. Inflammatory mediators in the mechanically stressed periodontal ligament *in vivo*. In: Davidovitch Z, ed. *Biological Mechanisms of Tooth Movement and Craniofacial Adaptation*. Columbus, Ohio: The Ohio State University College of Dentistry; 1992:391–400.
  19. Owman-Moll P, Kuroi J. Root resorption after orthodontic treatment in high- and low-risk patients: analysis of allergy as a possible predisposing factor. *Eur J Orthod*. 2000;22:657–663.
  20. Ong CKL, Walsh LJ, Harbrow D, Taverne AAR, Symons AL. Orthodontic tooth movement in the prednisolone-treated rat. *Angle Orthod*. 2000;70:118–125.
  21. Ong CKL, Joseph BK, Waters MJ, Symons AL. Growth hormone receptor and IGF-I receptor immunoreactivity during orthodontic tooth movement in the prednisolone-treated rat. *Angle Orthod*. 2001;71:486–493.
  22. Newman WG. Possible etiologic factors in external root resorption. *Am J Orthod*. 1975;67:522–539.
  23. Kjær I. Morphological characteristics of dentitions developing excessive root resorption during orthodontic treatment. *Eur J Orthod*. 1995;16:25–34.
  24. Mirabella AD, Årtun J. Risk factors apical root resorption of maxillary anterior teeth in adult orthodontic patients. *Am J Orthod Dentofacial Orthop*. 1995;108:48–55.
  25. Lee RY, Årtun J, Alonzo TA. Are dental anomalies risk factors for apical root resorption in orthodontic patients? *Am J Orthod Dentofacial Orthop*. 1999;116:187–195.
  26. Davidovitch Z. Etiologic factors in force-induced root resorption. In: Davidovitch Z, Norton LA, eds. *Biological Mechanisms of Tooth Movement and Craniofacial Adaptation*. Boston, Mass: Harvard Society for the Advancement of Orthodontics; 1996:349–355.
  27. Costopoulos G, Nanda R. An evaluation of root resorption incident to orthodontic intrusion. *Am J Orthod Dentofacial Orthop*. 1996;109:543–548.