

# New Generation Open-bite Treatment with Zygomatic Anchorage

Nejat Erverdi<sup>a</sup>; Serdar Usumez<sup>b</sup>; Alev Solak<sup>c</sup>

**Abstract:** This technical note aims to present the fabrication and application of a new generation of posterior intrusion appliances using zygomatic anchorage. The use of zygomatic anchorage enables en masse impaction of the posterior segment without any side effects such as labial flaring. A 14-year-old, female Class II patient with an anterior open bite was treated with a new generation posterior intrusion appliance. At the end of treatment, a Class I canine and molar relationship and a correction of the anterior open bite were achieved. The molars were impacted 3.6 mm, and this impaction was maintained throughout the treatment. The mandibular plane showed a counterclockwise autorotation of 4°. This case report demonstrates that zygomatic anchorage can be used effectively for molar intrusion and anchorage maintenance. However, further clinical studies with larger samples are required to confirm its effectiveness. (*Angle Orthod* 2006; 76:519–526.)

**Key Words:** Zygomatic anchorage; Implant anchorage; Open-bite treatment

## INTRODUCTION

Anterior open bite is one of the most difficult malocclusions to treat and maintain in orthodontics. The morphologic pattern usually demonstrates increased vertical dimensions and an increase in development of the maxillary posterior dentoalveolar structure.<sup>1–3</sup> The surgical correction of skeletal open bite often requires maxillary impaction to achieve reduction of anterior facial height.<sup>4</sup> The complexity, risks, and costs of surgical treatment have stimulated a search for alternative clinical procedures.

Previous efforts for open-bite correction included the use of bite blocks,<sup>5–8</sup> fixed mechanics with vertical elastics,<sup>9–11</sup> and new face mask designs.<sup>12</sup> These procedures have been effective in passive intrusion of the maxillary posterior segment,<sup>5–7,13</sup> but the correction of the malocclusion was achieved primarily through ex-

trusion of the incisors or by preventing passive eruption of posterior teeth.

Osseointegrated implants have recently gained great interest as anchorage units for orthodontic purposes.<sup>14–21</sup> These implants have been used for the active intrusion of lower<sup>22,23</sup> and upper<sup>24–28</sup> molars.

This technical note aims to present the fabrication and application of a new generation posterior intrusion appliance using zygomatic anchorage, which enables en masse impaction of the posterior segment without any side effects such as labial flaring.

## NEW GENERATION ZYGOMATIC IMPLANT SURGERY

Zygomatic implant surgery is conducted using local infiltration anesthesia delivered bilaterally to the zygomatic sites of the maxilla. The zygomatic buttress is palpated in the labial sulcus, and a 1- to 2-cm-high vertical incision is made starting at the mucogingival junction while maintaining contact with the bone (Figure 1). The lower aspect of the zygomatic process of the maxilla is totally exposed by blunt dissection. Care must be taken not to damage the buccal fat pad (Figure 2).

An I-shaped multipurpose implant (Tasarim Med, Istanbul, Turkey) is adjusted to fit the contour of the lower face of each zygomatic process and fixed by three bone screws (Figure 3).

The straight arm of the implant, which was previously bent in the opposite direction, is exposed in the

<sup>a</sup> Professor, Department of Orthodontics, Faculty of Dentistry, Marmara University, Istanbul, Turkey.

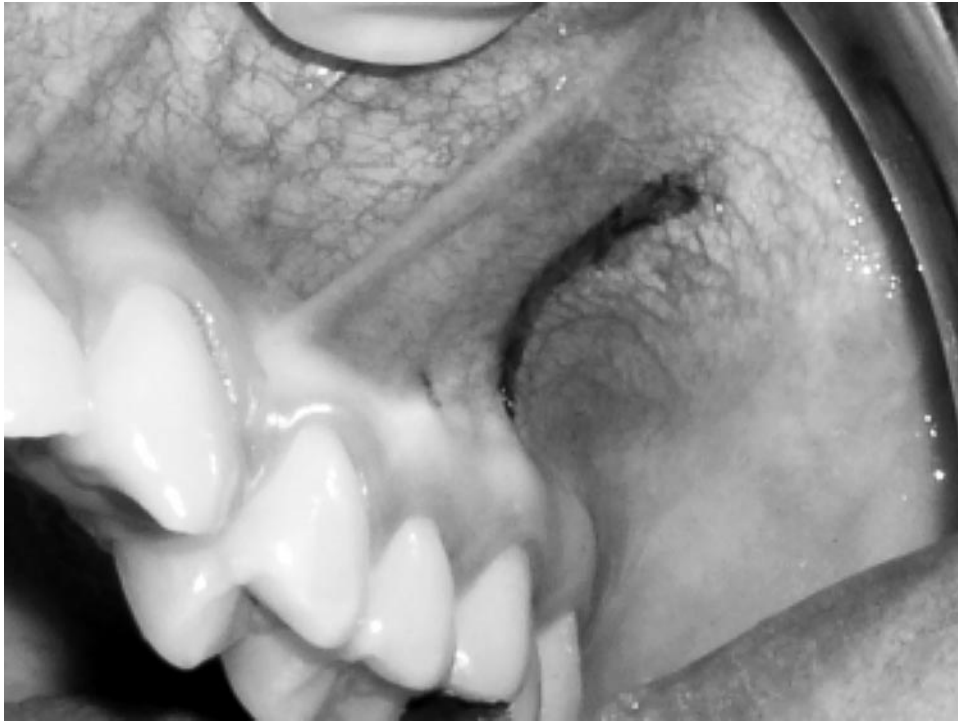<sup>b</sup> Associate Professor, Department of Orthodontics, Faculty of Dentistry, Marmara University, Istanbul, Turkey.

<sup>c</sup> Student—Graduate (PhD), Department of Orthodontics, Faculty of Dentistry, Marmara University, Istanbul, Turkey.

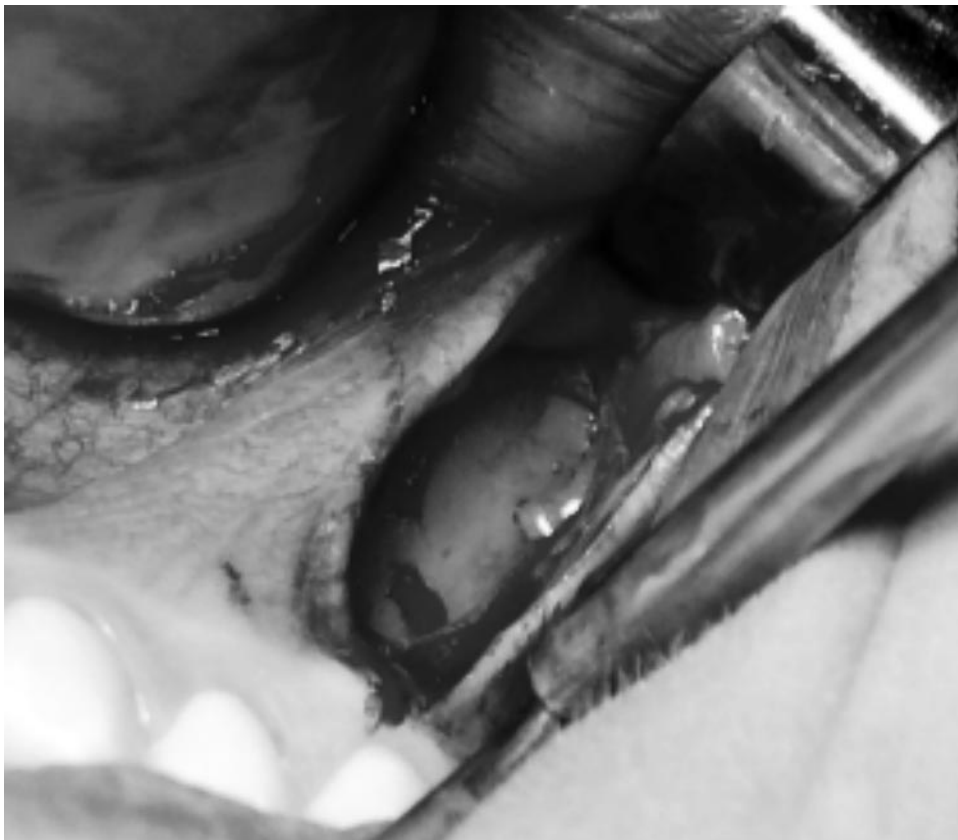Corresponding author: Dr. Serdar Usumez, Department of Orthodontics, Faculty of Dentistry, Marmara University, Guzelbahce Buyukciftlik Sok. No 6, Nisantasi 34346, Istanbul, Turkey (e-mail: susumez@hotmail.com)

Accepted: June 2005. Submitted: May 2005.

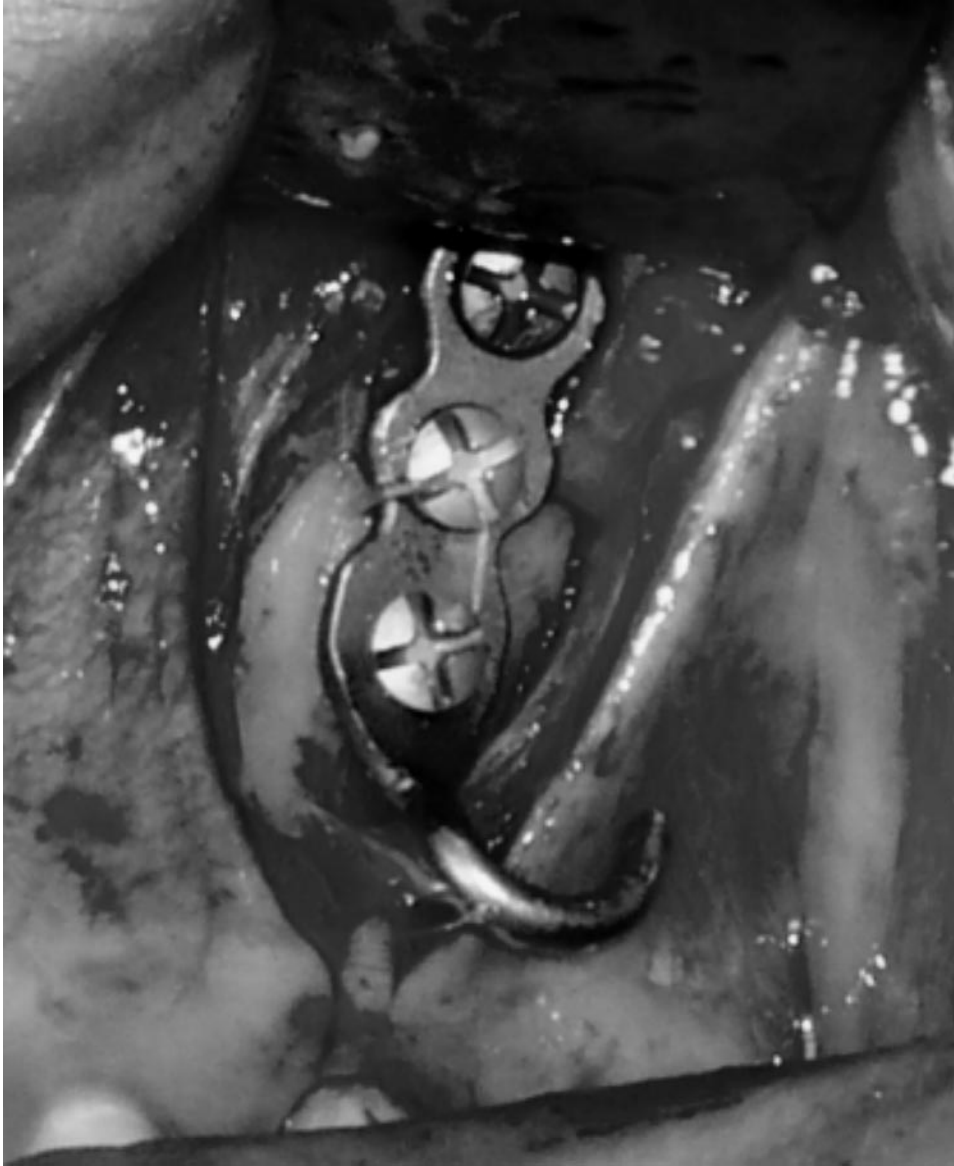© 2006 by The EH Angle Education and Research Foundation, Inc.



**FIGURE 1.** Vertical incision completed.



**FIGURE 2.** Zygomatic buttress area is exposed.



**FIGURE 3.** Implant is fixed with three screws.

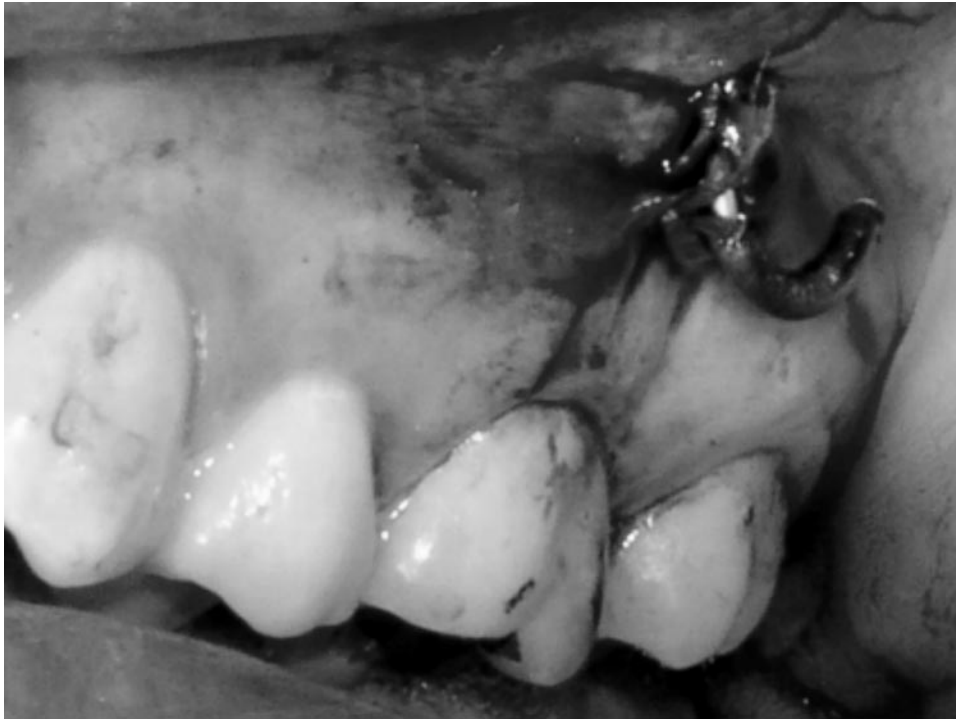oral cavity through the attached gingiva at the mucogingival junction. The location of the area where the implant is exposed is very critical for prevention of inflammation. The tip of the exposed plate is used to attach the coil springs for intrusion. After fixation, the incision site is closed and sutured (Figure 4).

The patient is advised to use antiseptic mouthwash for one week and to maintain proper oral hygiene during this healing period.

#### **APPLIANCE DESIGN AND FABRICATION**

On the basis of our previous experience with other designs, the following appliance design was developed to achieve the goals expected from intrusion therapy.

The appliance consists of two shallow acrylic bite blocks connected with two heavy palatal arches (1.4-mm round stainless steel) and wire attachments on each buccal side, which are used for force application (Figure 5). Palatal arches are bent over two layers of wax to avoid impingement on the palatal mucosa during intrusion. Bite blocks cover all of the teeth that need to be intruded, ie, generally all teeth distal to the upper canines. The outer wire attachments are made from 0.9-mm stainless steel wire, and two 200-g NiTi open-coil springs are attached before the ends of the wire are embedded in the acrylic resin. The offset of this wire is adjusted so that the vector of force application will be parallel to the long axis of the first molars when the NiTi coils are attached.



**FIGURE 4.** Surgery site is closed and sutured. Note the placement of the implant tip exposed at the mucogingival junction.

### PLACEMENT AND FORCE APPLICATION

After allowing 7 to 10 days for wound healing and after removal of the sutures, the appliance is first tried in the mouth to check for even occlusal contact. The cusp tips of the appliance segments are trimmed flat to control bite opening during expansion and generation of eccentric and unilateral contact points. Glass ionomer cement is used to bond the appliance. This material will usually remain interfaced on the teeth when the appliance is removed, and it may take more time to clean the teeth. However, a successful treatment requires a good retention of the appliance.

Two 9-mm NiTi coil springs (Masel, Bristol, Pa) were placed bilaterally between the tip of the implant and the outer wire creating an intrusive force of 400 g.

The anterior open bite is usually corrected in 5 to 6 months. Intrusion of the posterior segment is retained with wire ligation between the molar tube and the implant throughout the subsequent orthodontic treatment. The implants are removed about 1 month before debonding.

### CASE REPORT

#### Diagnosis

A 14-year-old female patient was referred to us with a chief complaint of anterior open bite. Clinical examination of the patient revealed a Class I molar relation on the left and a Class II on the right. The canine

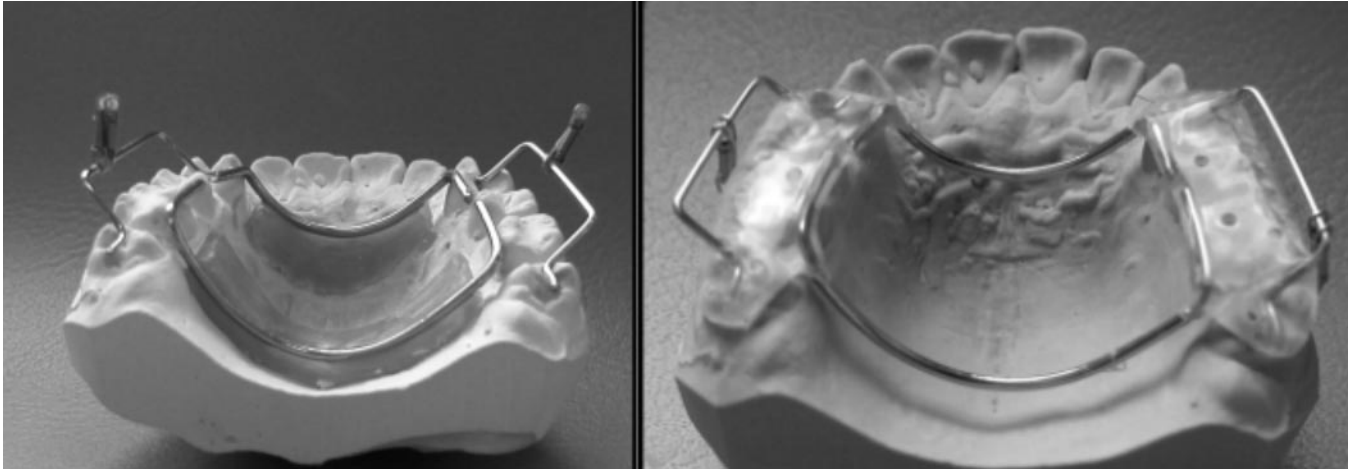
relationship was Class II on both sides. She had an 8-mm anterior open bite and a 5-mm overjet. The growth pattern was neutral. The upper and lower arches were generally well aligned with no apparent space deficiency (Figure 6; Table 1). The treatment plan included impaction of the maxillary posterior dentoalveolar segment using zygomatic anchorage followed by fixed-appliance therapy.

#### Treatment objectives

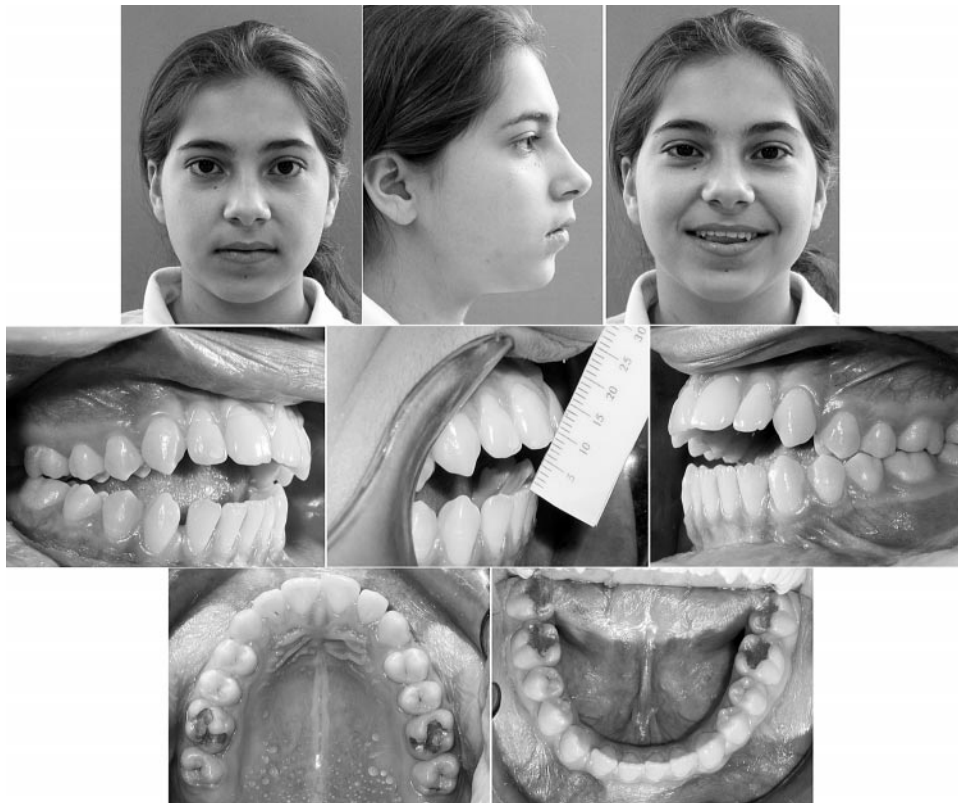
The objectives of orthodontic treatment were correction of the anterior open bite and molar/canine relation through autorotation of the mandible by impaction of the maxillary posterior dentoalveolar segment using zygomatic anchorage and alignment of the upper and lower arches with fixed mechanics.

#### Treatment progress

After implant placement surgery and suture removal at day 7, the appliance was cemented, and force application was initiated. The patient was observed at 4-week intervals, and progress was observed. No fixed appliances were placed until the completion of the posterior dentoalveolar intrusion in 7 months. After completion of the impaction, orthodontic therapy was started, and the impaction was maintained with wire ligation between the implant and the molar tubes throughout the treatment.



**FIGURE 5.** Fabrication of intraoral appliance for posterior intrusion.



**FIGURE 6.** Extraoral and intraoral photographs of the patient before treatment.

### Results achieved

At the end of treatment, a Class I canine and molar relationship and correction of the anterior open bite were achieved through the impaction of maxillary posterior dentoalveolar segment and eruption and uprighting of the upper incisors (Figures 7 and 8; Table 1). The incisors were erupted when the accentuated curve of Spee in the upper arch was aligned with straight wires. No other particular extrusion mechanics

were involved in the treatment. The molars were impacted 3.6 mm, and this impaction was maintained throughout the treatment. The mandibular plane showed 4° of counterclockwise autorotation (Table 1).

### DISCUSSION

Every aspect and detail of the treatment approach presented in this study represents an evolution based on our experience encountered with previous designs.

**TABLE 1.** Cephalometric Summary

Measurement	Initial	Progress	Final
SNA (°)	83	85	85
SNB (°)	77	79	79
ANB (°)	6	6	6
Overjet (mm)	8	5	3
Overbite (mm)	-8	0	1
Occlusal plane to SN (°)	14	22	21
U6 to palatal plane (mm)	20	17.5	16.4
SN to Go-Gn (°)	39	35	36.4
Interincisal angle (°)	110	125	133
Upper 1 to nasion-A (mm)	8	5	4
Upper 1 to nasion-A (°)	33	21	16
Lower 1 to nasion-B (mm)	8	8	8
Lower 1 to nasion-B (°)	31	27	25

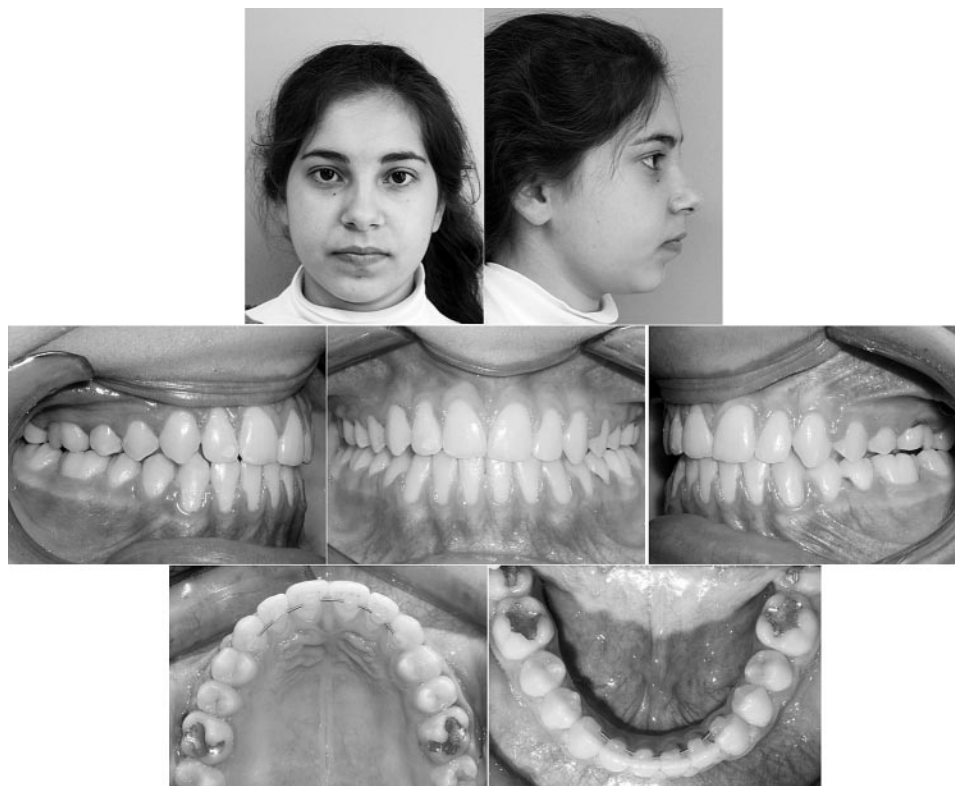
The heavy palatal bars are essential to avoid buccal tipping of the posterior segment, which otherwise is inevitable because of the location of the line of force in relation to the center of resistance of this segment. Tipping of the buccal segment not only impairs posterior occlusion but also impedes successful elimination of the open bite because of the interferences created between upper and lower teeth. If expansion of the maxillary arch is also required, these bars can be replaced by a hyrax screw, and rapid maxillary expansion can be performed simultaneously. The offset of

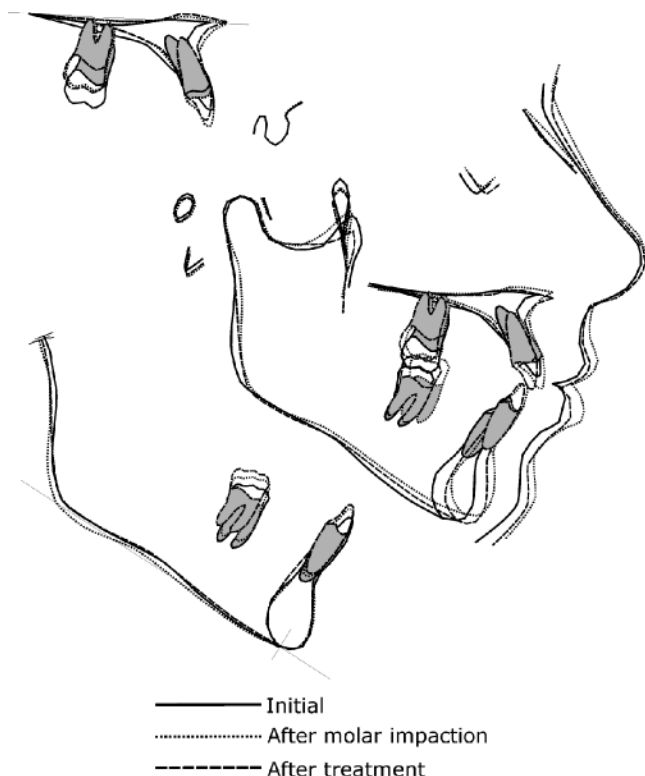
the buccal wire enables better location of the force direction and minimizes soft tissue impingement.

Once placed, successfully zygomatic implants provide an absolutely stable anchorage unit, which can be used for other purposes including single (canine distalization) or segmental tooth movement or anchorage reinforcement. Therefore, it is advisable to keep the implant in place until 1 month before the end of treatment.

The simple fixation techniques (limited incision, reduced flap area, drilling with a hand instrument) are well tolerated by the patient. Patient acceptance of this treatment modality as an alternative to the conventional Le Fort I surgery is positive, and postoperative pain and discomfort are negligible. The insertion technique for the implants in the zygomatic buttress required a short 1-cm flap opening to observe the operating field. The drilling and screwing were performed with hand instruments to provide minimum trauma to the bone and to avoid overheating of the bone. Postoperative conditions, such as edema and pain, are minimal. No compliance is required (no headgear, no anterior box elastics), with the exception of good oral hygiene. This noninvasive technique facilitates surgical procedures and reduces operation time.

One interesting finding of this case report is the relapse encountered in the mandibular plane angle after

**FIGURE 7.** Extraoral and intraoral photographs of the patient after treatment.



**FIGURE 8.** Cephalometric superimposition of the case at the beginning of treatment, after molar impaction, and after treatment.

the molar impaction period. Although a significant amount of counterclockwise rotation of mandible was achieved, some of this correction was lost during later stages of the treatment. This was caused mainly by the progressive extrusion of the lower molar teeth, which is clearly observed in the mandibular superimposition shown in Figure 8. A slight posterior open bite was observed when the intrusion appliance was first removed, and this was caused by the acrylic bite block of the appliance. Because the upper molars were fixed to the zygomatic implant and not free to extrude, this open bite was closed by the extrusion of the lower molars. This was reflected as a change in the occlusal plane to SN angle from  $14^\circ$  to  $21^\circ$  (Table 1).

Within the limitations of a single case report, this case demonstrates that zygomatic anchorage can be used effectively for molar intrusion and anchorage maintenance. However, further clinical studies with large samples are required to prove the technique's effectiveness.

## REFERENCES

1. Proffit W, Fields H. *Contemporary Orthodontics*. 2nd ed. St Louis, Mo: Mosby; 1993:128–446.
2. Sassouni V. A classification of skeletal facial types. *Am J Orthod*. 1969;55:109–123.
3. Schudy FF. The rotation of the mandible resulting from

- growth: its implication in orthodontic treatment. *Angle Orthod*. 1965;35:36–50.
4. Lawy DM, Heggie AA, Crawford EC, Ruljancich MK. A review of the management of anterior open bite malocclusion. *Aust Orthod J*. 1990;11:147–160.
5. Dellinger EL. A clinical assessment of the active vertical corrector. A nonsurgical alternative for skeletal open bite treatment. *Am J Orthod Dentofacial Orthop*. 1986;89:428–436.
6. Kalra V, Burstone CJ, Nanda R. Effects of a fixed magnetic appliance on the dentofacial complex. *Am J Orthod Dentofacial Orthop*. 1989;95:467–478.
7. Kiliaridis S, Egermark B, Thilander B. Anterior open bite treatment with magnets. *Eur J Orthod*. 1990;12:447–457.
8. Woodside DG, Aronson L. Progressive increase in lower anterior face height and the use of posterior occlusal bite-blocks in this management. In: Graber LW, ed. *Orthodontics: State of the Art, Essence of the Science*. St Louis, Mo: Mosby; 1997:200–221.
9. Rinchuse DJ. Vertical elastics for correction of anterior open bite. *J Clin Orthod*. 1994;28:284.
10. Kim YH. Anterior open bite and its treatment with multiloop edgewise archwire. *Angle Orthod*. 1997;57:171–178.
11. Kucukkeles N, Acar A, Demirkaya A, Evrenol B, Enacar A. Cephalometric evaluation of open bite treatment with NiTi archwires and anterior elastics. *Am J Orthod Dentofacial Orthop*. 1999;116:555–562.
12. Alcan T, Keles A, Erverdi N. The effects of a modified protraction headgear on maxilla. *Am J Orthod Dentofacial Orthop*. 2000;117:27–38.
13. Stellzig A, Steegmayer G, Basdra EK. Elastic activator for treatment of open bite. *Br J Orthod*. 1999;26:89–92.
14. Odman J, Lekholm U, Jemt T, Branemark P-I, Thilander B. Osseointegrated titanium implants—a new approach in orthodontic treatment. *Eur J Orthod*. 1988;10:98–105.
15. Roberts WE, Helm FR, Marshall KJ, Gonglof RK. Rigid endosseous implants for orthodontic and orthopedic anchorage. *Angle Orthod*. 1989;59:247–256.
16. Turley PK, Kean C, Sehur J, Stefanac J, Gray J, Hennes J, Poon LC. Orthodontic force application to titanium endosseous implants. *Angle Orthod*. 1988;58:151–162.
17. Van Roekel NB. The use of Branemark system implants for orthodontic anchorage: report of case. *Int J Oral Maxillofac Implants*. 1989;4:341–344.
18. Costa A, Raffaini M, Melsen B. Miniscrews as orthodontic anchorage: a preliminary report. *Int J Adult Orthodon Orthognath Surg*. 1998;13:201–209.
19. Wehrbein H, Glatzmaier J, Mundwiller U, Diedrich P. The orthosystem: a new implant system for orthodontic anchorage in the palate. *J Orofac Orthop*. 1996;57:142–153.
20. Tosun T, Keles A, Erverdi N. Method for the placement of palatal implants. *Int J Oral Maxillofac Implants*. 2002;17:95–100.
21. Freudenthaler JW, Haas R, Bantleon H-P. Bicortical titanium screws for critical orthodontic anchorage in the mandible: a preliminary report on clinical applications. *Clin Oral Implants Res*. 2001;12:358–363.
22. Ohmae M, Saito S, Morohashi T, et al. A clinical and histological evaluation of titanium mini-implants as anchors for orthodontic intrusion in the beagle dog. *Am J Orthod Dentofacial Orthop*. 2001;119:489–497.
23. Umemori M, Sugawara J, Mitani H, Nagasaka H, Kawamura H. Skeletal anchorage system for open bite correction. *Am J Orthod Dentofacial Orthop*. 1999;115:166–174.
24. Melsen B, Petersen JK, Costa A. Zygoma ligatures: an al-

- ternative form of maxillary anchorage. *J Clin Orthod.* 1998; 32:154–158.
25. De Clerck H, Geerinckx V, Siciliano S. The zygoma anchorage system. *J Clin Orthod.* 2002;36:455–459.
  26. Erverdi N, Tosun T, Keles A. A new anchorage site for the treatment of anterior open bite: zygomatic anchorage case report. *World J Orthod.* 2002;43:147–153.
  27. Erverdi N, Keles A, Nanda R. The use of skeletal anchorage in open bite treatment: a cephalometric evaluation. *Angle Orthod.* 2004;74:381–390.
  28. Sherwood K, Burch J, Thompson W. Closing anterior open bites by intruding molars with titanium miniplate anchorage. *Am J Orthod Dentofacial Orthop.* 2002;122: 593–600.