

Relapse Tendency after Orthodontic Correction of Upper Front Teeth Retained with a Bonded Retainer

Sasan Naraghi^a; Anders Andrén^b; Heidrun Kjellberg^c; Bengt Olof Mohlin^d

ABSTRACT

Objective: To investigate the amount and pattern of relapse of maxillary front teeth previously retained with a bonded retainer.

Materials and Methods: The study group consisted of 135 study casts from 45 patients. Recordings from study models before treatment (T1), at debonding (T2), and 1 year after removal of the retainer (T3) were present. All patients had been treated with fixed edgewise appliances. The irregularity index (sum of contact point displacement [CPD]) and rotations of front teeth toward the raphe line were calculated at T1, T2, and T3.

Results: The mean irregularity index at T1 was 10.1 (range 3.0–29.9, SD 5.4). At T2 it was 0.7 (range 0.0–2.1, SD 0.7), and at T3 it was 1.4 (range 0.0–5.1, SD 1.2). Fifty-five teeth in 42 patients were corrected more than 20° between T1 and T2 (mean correction 31.4° range 20.0–61.7), and mean relapse in this group was 7.3° (range 0.0–20.5). Regarding alignment of the maxillary front teeth, the contact relationship between the laterals and centrals seems to be the most critical. A significant positive correlation was found between the amount of correction of incisor rotation and the magnitude of relapse but not between the amount of correction of CPD and the magnitude of relapse. Eighty-four percent of the overcorrected CPDs returned to a desired position.

Conclusions: Minor or no relapse was noted at the 1-year follow-up. (*Angle Orthod* 2005;76: 570–576.)

KEY WORDS: Retention; Rotation; Crowding; Irregularity; Incisors

INTRODUCTION

Morphologic stability is one important goal after orthodontic treatment, and from the patients point of view, stability of the upper front teeth is of considerable importance.^{1,2} Relapse, the tendency for teeth to return toward their pretreatment positions, has been the subject of many studies,^{3–9} the long-term results

reported from Seattle being the most extensive.^{3,17} Because of type of malocclusion, treatment procedure, cooperation during and after treatment, growth, etc,^{5,7–9} variability in long-term treatment outcome is quite common. Additional factors are type and duration of retention.¹⁰ There is some information in the literature regarding maxillary irregularity after retention with a maxillary Hawley retainer,^{6,7,11,12} but many studies^{8,9,10,12} do not specify the retention method in the upper arch, the duration of retention, or the length of the postretention period at the time of examination.

Bonded multistrand wire has been used as a method of retention for 30 years^{13,14} and is now a reasonably reliable form of retention^{15,16} in a short-term perspective. Bonded retainers appear to be accepted well by patients and are relatively independent of patient cooperation. The relapse tendency of the upper front teeth after correction of contact point displacements (CPDs) and rotations and after use of bonded retainers has yet to be reported.

Surbeck et al¹⁷ found that the pattern of pretreatment rotational displacement of maxillary anterior teeth had a tendency to repeat itself after retention.

^a Consultant Orthodontist, The County Orthodontic Clinic in Växjö, Kronoberg, Sweden.

^b Consultant Orthodontist, The County Orthodontic Clinic in Mariestad, Västra Götaland, Sweden.

^c Associate Professor, Faculty of Odontology Orthodontics, The Sahlgrenska Academy at Goteborg University, Goteborg, Sweden.

^d Professor, Faculty of Odontology Orthodontics, The Sahlgrenska Academy at Goteborg University, Orthodontics, Goteborg, Sweden.

Corresponding author: Dr. Sasan Naraghi, The County Orthodontic Clinic, Klostergatan 16 B, Växjö, Kronoberg S-352 31, Sweden (e-mail: sasan@telia.com)

Accepted: July 2005. Submitted: April 2005.

© 2005 by The EH Angle Education and Research Foundation, Inc.

TABLE 1. Distribution of Extraction and Nonextraction Treatments

Nonextraction	12
Four premolar extraction	14
Two upper premolar extraction	10
Other extracted teeth/agensis	9

However, relapse of CPD because of labial or lingual position only was random relative to the pretreatment positions. The authors also held that incomplete alignment during treatment was a risk factor for relapse and suggested slight overcorrection during active treatment of severely rotated teeth; however, they did not specify the method of retention. Several questions arise when studying the relapse tendency of the upper front teeth after retention with a bonded retainer. For instance, does overcorrection of rotations or labial/lingual displacements retained with bonded retainer decrease the amount of relapse? Does overcorrection result in teeth remaining in overcorrected positions? How large is the relapse of rotated or displaced (or both) maxillary front teeth after a period of bonded retention?

Objectives of this study

- Study the amount of relapse of the maxillary front teeth after retention with a bonded retainer;
- Investigate the pattern of relapse regarding type of movement after correction of rotations and labial/lingual displacements;
- Examine the effect of overcorrection of CPD in stability outcome;
- Analyze the influence of expansion of the intercanine distance on stability outcome.

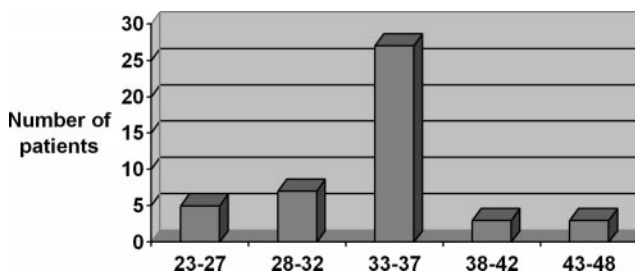
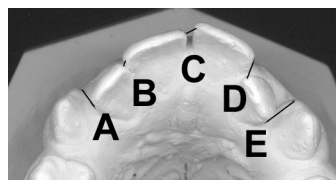
MATERIALS AND METHODS

The study group consisted of 45 patients treated with fixed orthodontic edgewise appliances. The patients were selected from The County Orthodontic Clinic in Mariestad, Sweden, when their upper bonded retainer was removed. The wire used was 0.0195-inch Wildcat (GAC International Inc., Central Islip, NY). Their mean age at the 1-year follow-up was 18.8 years (range 15.8–21.5). Extraction or nonextraction cases with various diagnoses and whose upper arches were retained with a bonded retainer only were included. All six front permanent teeth had to be present before treatment and presenting irregularity. Spaced dentitions in the upper front teeth and treatments started as adults were excluded. Study models before treatment (T1), after active treatment (T2), and 1 year out of upper retention (T3) had to be available.

The extraction and nonextraction distribution and number of patients is shown in Table 1, and the ex-

TABLE 2. Extension of Retainer

	No. Patients
Eight teeth	22
Seven teeth	3
Six teeth	14
Five teeth	1
Four teeth	5

**FIGURE 1.** Duration of retention in months.**FIGURE 2.** Irregularity index: the sum of five frontal contact displacements in millimeters (A + B + C + D + E).

tension of the retainers in Table 2. The mean duration of the retention period was 33 months (range 23–48 months) (Figure 1). Of 306 teeth with bonded retainers, the bonding failed on six teeth in five patients (2%) during the retention period. No wires fractured during the retention period.

Method for studying CPD

Labiolingual displacements of the anatomic contact points from the mesial of the right canine through to the mesial of the left canine were measured with a digital caliper on the casts from T1, T2, and T3, with 0.1 mm accuracy. CPDs less than 0.5 mm were judged to be zero.

The irregularity index (Figure 2), ie, the sum of the five CPDs (A + B + C + D + E), was calculated as described by Little.¹⁸

Method for studying rotations and intercanine distance

An Agfa DuoScan F40 (Agfa-Gevaert N.V., Mortsel, Belgium) scanner was used to scan the casts at 300 DPI (dots per inch) resolutions. All 45 × 3 casts were scanned in 300 DPI and then placed on the upper third part of the glass, with almost the same size of the

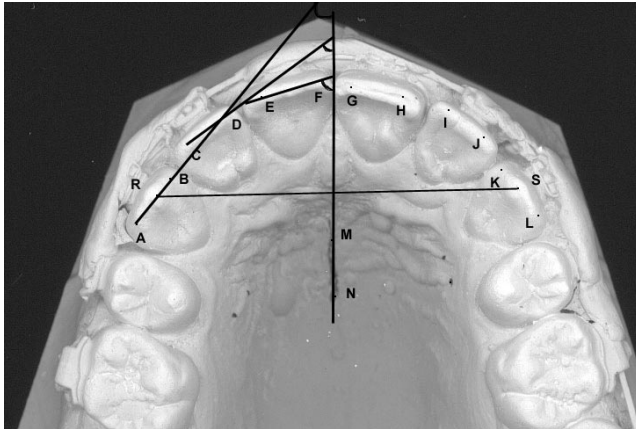


FIGURE 3. Teeth angles on right side to the raphe line and intercanine distance.

scanned area. To avoid distortions, all front teeth were optimally in contact with the glass surface of the scanner. To measure rotation changes and intercanine distance, a computer program (Scion Image) was used to mark points on the pictures of the scanned casts. The rotations were measured as the angle between a line through the mesial and distal points on the incisal edge of the teeth and the raphe line. The intercanine distance was measured between the cusp tips of the upper canines (Figure 3).

Statistical analysis

Paired *t*-tests were applied to test differences in CPD, rotations, and intercanine distance between T1, T2, and T3. Pearson's product-moment correlation test was applied to test correlations between CPD and rotations at T1 and changes during treatment and the follow-up period. The SAS® v8.2 program (SAS Institute Inc, Cary, NC) was used for all statistical analysis. For all statistical analyses, the statistical significance level was set to 5%.

Measurement error

The reproducibility of the measurements for rotations and intercanine distance was determined by double measurements of 45 scanned models from 15 patients at T1, T2, and T3. The error of the method was calculated using Dahlberg's equation.¹⁹

$$S_x = \sqrt{\frac{\sum D^2}{2N}}$$

Where D is the difference between repeated measurements and N is the number of measurements. The errors were 3.1° for canines, 2.8° for laterals, and 2.4° for centrals. The error of measuring the intercanine distance was 1.1 mm.

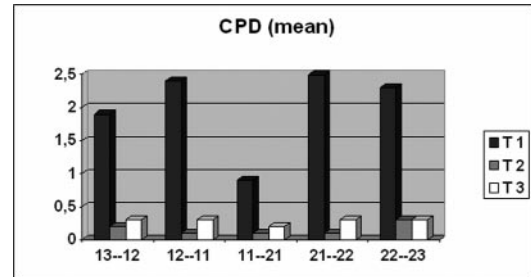


FIGURE 4. Contact point displacements before treatment (T1), after treatment (T2), and 1 year after retention (T3).

Double measurements of 60 models in 20 patients were used to calculate the error of measuring CPD. Using this procedure, the measuring error for CPD was 0.14 mm.

RESULTS

Contact point discrepancies

Before treatment (T1). The mean irregularity index at T1 was 10.1 (range 3.0–29.9, SD 5.4). The largest displacements were recorded between laterals and centrals followed by the displacement between laterals and canines, whereas the smallest deviations were found between the centrals (Figure 4).

After treatment (T2). At T2, the mean irregularity index was 0.7 (range 0.0–2.1, SD 0.7). There was a significant difference in the index between T1 and T2 ($P < .0001$). Forty-three contacts were overcorrected (Figure 5a). When overcorrections were excluded from the calculation, the mean irregularity index was 0.3.

Eighteen overcorrections were less than 0.5 mm (all were nonmeasurable) and could only be detected at close inspection.

After retention (T3). The mean irregularity index at T3 was 1.4 (range 0–5.1, SD 1.2), ie, 14% of the irregularity at T1. There was a significant difference in the index between T2 and T3 ($P < .0001$). Of the 225 CPDs from 45 patients, those with the largest CPD at T1 (5–11 mm, $n = 17$) had a mean CPD at T3 of 0.5 (range 0–1.8). The intermediary CPD at T1 (3.0–4.9 mm, $n = 33$) had a mean CPD at T3 of 0.4 (range 0–1.5). The smallest CPD at T1 (1–2.9 mm, $n = 97$) had a mean CPD at T3 of 0.3 (range 0–1.5). None of these differences was statistically significant ($P = .733$).

Sixteen contacts in 11 patients were displaced more than 1 mm, 1 year after retention.

Four CPDs changed from T2 to T3 in the opposite direction to their pretreatment positions.

Seven of 25 contacts remained overcorrected. Six of these seven contacts were displaced because of rotations and one because of buccolingual displacement at T1.

Four overcorrected CPDs at T2 had relapsed de-

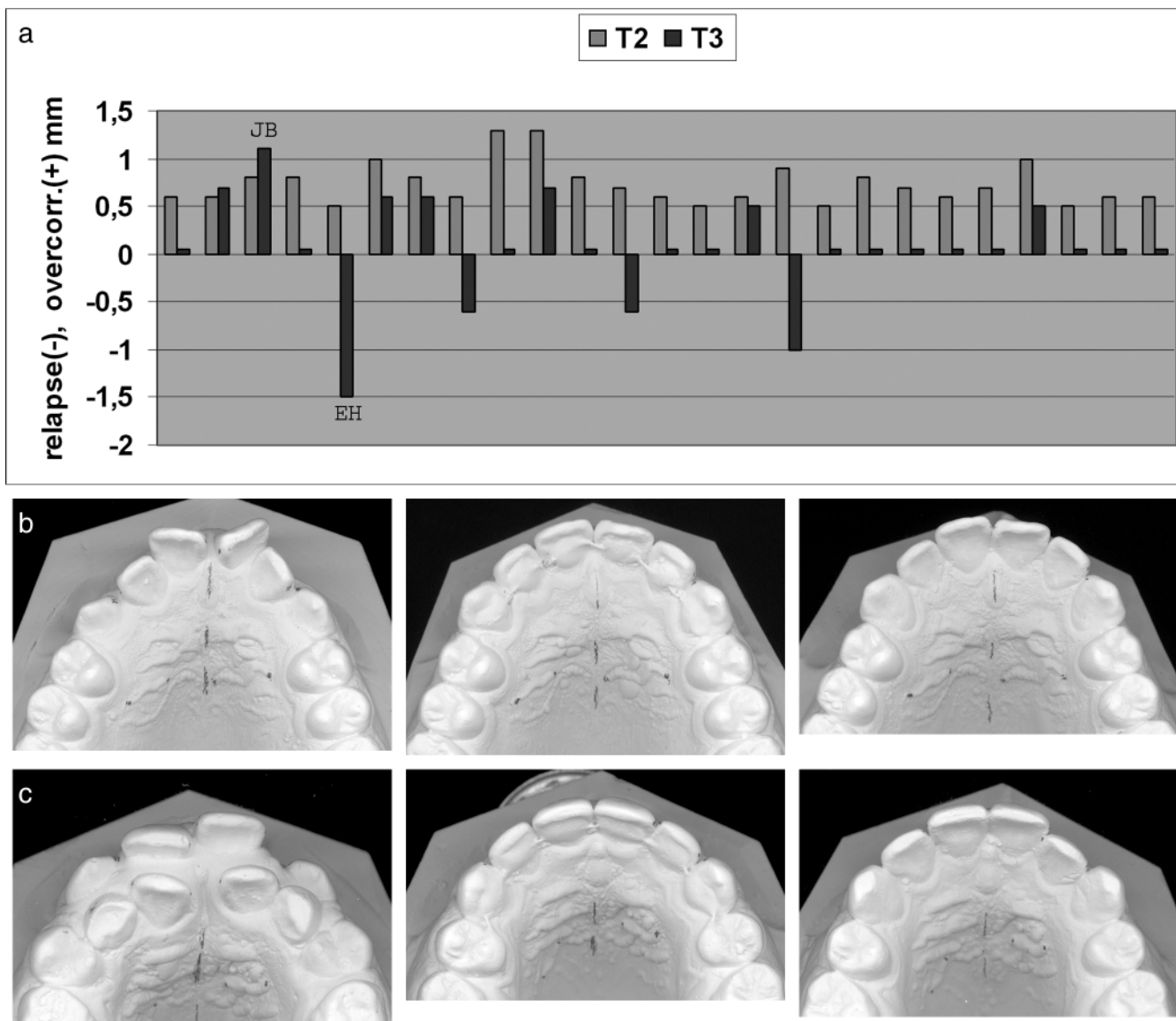


FIGURE 5. (a) Overcorrected contacts after treatment and 1 year after retention. (b) Patient JB: overcorrected contact between 22/23, no rebound, overcorrection remains. (c) Patient EH: 22/21 overcorrected 0.5 mm and relapse of 1.5 mm.

spite overcorrection; three of these were because of rotations recorded at T1 (Figure 5a–c).

Rotations

There was a significant correlation between the amount of rotational change (for all six teeth) because of treatment and relapse ($P < .0001$). However, when looking at each tooth, group centrals ($P < .0130$) and laterals ($P < .0001$) showed significant correlations but not the canines ($P = .0622$).

Totally, 55 teeth in 42 patients were corrected more than 20.0° between T1 and T2 (mean correction 31.4°, range 20.0–61.7). Mean relapse in this group was 7.3° (range 0.0–20.5) (Figure 6). Of these 55 teeth, 18 relapsed more than 10° (Table 3).

Inter canine distance

The intercanine distance in 31 patients did not change during treatment. In 14 patients, the intercanine distance was expanded equal to or more than 1.5 mm (range 1.5–6.4). Four of these 14 patients showed a reduction of the intercanine width at T3 of 1 mm or more (range 1.0–2.3). Patients in this small group were not more irregular regarding CPDs and rotations than the rest of the sample.

Fiberotomy

Three laterals and six centrals were subjected to circumferential supracrestal fiberotomy. This technique resulted in a mean correction of 33° (27–41) and a

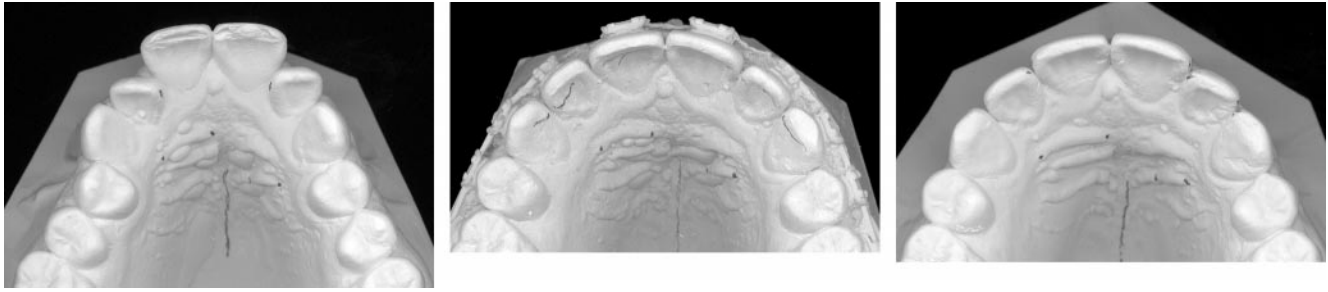


FIGURE 6. Patient ÅG: tooth 22 corrected 43°; 22 relapse 20.5°, highest rotational relapse.

TABLE 3. Teeth That Were Derotated More Than 20.0° (n = 55)

	n	\bar{x} Correction in Degrees	\bar{x} Relapse in Degrees	% Relapse
Cuspids	13	28	6	21
Laterals	23	34.8	9	26
Centrals	19	26.3	6.5	25

relapse of 7.6°. If the nine teeth subjected to fibero-tomy were excluded from the group of 55 corrected rotations, the 46 remaining teeth had a mean relapse of 7.1°.

DISCUSSION

This study has demonstrated that 89% of the patients had a score of less than 3 for the maxillary irregularity index, 1 year out of retention. The change from a mean irregularity index of 0.7 after treatment to 1.4 after retention can be regarded as a minor relapse compared with the corrections achieved during treatment. No correlations were observed between the severity of pretreatment irregularity and the amount of relapse.

Of 306 teeth with bonded retainers, there were a few bonding failures (six teeth in five patients) during the retention period. Bonding failures may occur in cases when lower teeth interfere with the retainers. In this study, most patients achieved a proper overbite with almost no interferences. In cases with pointed lower canines, the technicians were informed to position the wire more cervically on the upper canine and on the distal part of the upper lateral. In patients with short upper clinical crowns, the wire was placed more cervically.

Difficulty in locating the raphe line equally on the pretreatment, posttreatment, and postretention study models is probably the main reason for the relatively large measurement errors when measuring rotations. By using fixed reference points such as implants, this problem could have been easily avoided. Variation in the quality of the plaster casts is another factor that might have increased the error. Changes in archform,

which frequently occur during both the treatment and posttreatment period, may have also influenced the measurements. If the arch changes to a wider form, the angular measurement will tend to increase, even if no contact point discrepancy has occurred relative to the dental arch. The position of the incisors in buccolingual direction gives different angles to the raphe line, meaning that more proclined teeth give a smaller angle and more retroclined teeth give a larger angle.

A computer-generated archform as a reference is a method used by Surbeck et al.¹⁷ Rotation of the incisors relative to the dental arch was measured as the angle between the line connecting the points representing the mesial and distal point angles and the line connecting the projections of these points on the arch, recorded as positive if mesially rotated and negative if distally rotated. Surbeck et al.¹⁷ state that this method indicates CPD and incisor rotations even in a group selected for perfect alignment. This shows that a computer-generated archform may not represent the actual dental arch.

Because the follow-up period was short, being only 1 year, the results are to be considered as short term. Of course, we believe that 1-year postretention control is short and not sufficient, but registrations 1-year postretention were done within the routine treatment program. A recall visit 1 year out of retention was, in most cases, the patients' last visit to the orthodontist. However, small contact displacements 1 year after retention may be potential starting points for increasing irregularity. The failure rate of bonded retained teeth (2%) is consistent with the findings of Zachrisson¹⁵ and must be considered acceptable, especially because four of six loose retainer bonds in our study affected premolars. Fortunately, none of the bond failures caused any measurable relapse.

The contact relationship between laterals and centrals showed the largest CPD at T1, which is in accordance with the earlier findings.⁷ The mean irregularity index after treatment was 0.7, including overcorrections that accounted for most of the displacements. The irregularity 1 year after retention was 14% of the value before treatment. In comparison with other stud-

ies^{6,7,10,11} using Hawley retainers, our results seem to be favorable; ie, less postretention changes were observed in our study. However, the studies are very difficult to compare because of different follow-up periods. The severe displacements at T1 did not rebound more than the medium CPD at T1. Four CPDs changed from T2 to T3 in the opposite direction of the expected relapse with some rotations involved. Therefore, we cannot posit that only labiolingual displacements relapsed at random to the pretreatment positions. Our data do not confirm the finding of Surbeck et al¹⁷ that rotations and labiolingual displacements have different relapse patterns.

Regarding alignment of the maxillary anterior teeth, the contact relationship between the lateral and central seems to be most critical. The correction of a bodily displaced tooth, often laterals, includes selective root torque to minimize the relapse tendency. In patient EH (Figure 5c), the torque of the left lateral was not quite successful. During the postretention period, the crown tended to upright over the root resulting in a small relapse despite overcorrection.

The most severe rotations were found among the laterals. The number of severely rotated laterals and centrals were slightly higher than for the canines, which confirm the trend reflected in the CPD measurements (Figure 4). This finding, together with a larger error of method when measuring canine rotations, might be a plausible explanation for the lack of significant correlations between rotational correction and relapse of canines.

Only a few individuals exhibited an increased intercanine width during treatment. No obvious changes could be recorded in the intercanine distance between T2 and T3, which is in accordance with other studies.^{6-8,17} Because four subjects showed a decreased width, no firm conclusions can be drawn from these findings.

Fiberotomy was performed on only nine incisors. Their degree of relapse was not different from the remaining 46 teeth corrected more than 20°. However, because of the small number of teeth treated with fiberotomy, it is hard to draw any conclusions as to whether fiberotomy has any influence on the relapse tendency. Studies that used Hawley retainers^{11,20} as retention found less relapse in a group with fiberotomies as compared with a group without fiberotomies.

Of the 25 measurable overcorrections at T2, 14 had returned to zero CPD at T3. We do not know if the four overcorrections that relapsed toward the original position (T1) would have been of a different magnitude without overcorrection, but it is unlikely that the influence of overcorrection was negative. The seven remaining overcorrections were so small (0.5–1.1 mm) that they probably did not cause the patients any dissatisfaction. It can be concluded that overcorrections

should be small because there is a risk that some do not rebound to zero CPD. It is uncertain how much the result can be improved by overcorrection.

From a clinical point of view, only 11% of the patients had an irregularity index of more than 3 at the follow-up. The patient with the largest index (5.1) had a deviant growth pattern after treatment, which caused an open bite and an asymmetric mandible, resulting in instability. This could account for the relapse in this specific case. A combined orthodontic and surgical treatment approach is now planned for this patient.

CONCLUSIONS

- Minor or no relapse in short-term follow-up (1 year) was noted in the maxillary front after correction of irregularity and a 2- to 4-year period of bonded retention.
- There was a significant positive correlation between the amount of correction of incisor rotation and the magnitude of relapse.
- No significant relation was found between the amount of correction of CPD and magnitude of relapse.
- There was no difference in the relapse pattern between rotational displacements and labiolingual displacement.
- 84% of the overcorrected CPDs returned to a desired position.

REFERENCES

1. Helm S, Kreiborg S, Solow B. Psychosocial implications of malocclusion: a 15-year follow-up study in 30-year-old Danes. *Am J Orthod*. 1985;87:110–118.
2. Espeland LV, Stenvik A. Perception of personal dental appearance in young adults: relationship between occlusion, awareness, and satisfaction. *Am J Orthod Dentofacial Orthop*. 1991;100:234–241.
3. Little RM, Riedel RA, Årtun J. An evaluation of changes in mandibular anterior alignment from 10 to 20 years postretention. *Am J Orthod Dentofacial Orthop*. 1988;93:423–428.
4. De la Cruz A, Sampson P, Little RM, Årtun J, Shapiro PA. Long-term changes in arch form after orthodontic treatment and retention. *Am J Orthod Dentofacial Orthop*. 1995;107:518–530.
5. Berg R. Post-retention analysis of treatment problems and failures in 264 consecutively treated cases. *Eur J Orthod*. 1979;1:55–68.
6. Sadowsky C, Schneider BJ, BeGole EA, Tahir E. Long-term stability after orthodontic treatment: nonextraction with prolonged retention. *Am J Orthod Dentofacial Orthop*. 1994;106:243–249.
7. Vaden JL, Harris EF, Gardner RL. Relapse revisited. *Am J Orthod Dentofacial Orthop*. 1997;111:543–553.
8. Hellekant M, Lagerstrom L, Gleeup A. Overbite and overjet correction in a Class II division 1 sample treated with edge-wise therapy. *Eur J Orthod*. 1989;11:91–106.
9. Jones ML. The Barry Project—a further assessment of occlusal treatment change in a consecutive sample: crowding and arch dimensions. *Br J Orthod*. 1990;17:269–285.

10. Destang DL, Kerr WJ. Maxillary retention: is longer better? *Eur J Orthod.* 2003;25:65–69.
11. Edwards JG. A long-term prospective evaluation of the circumferential supracrestal fiberotomy in alleviating orthodontic relapse. *Am J Orthod Dentofacial Orthop.* 1988;93:380–387.
12. Huang L, Årtun J. Is the postretention relapse of maxillary and mandibular incisor alignment related? *Am J Orthod Dentofacial Orthop.* 2001;120:9–19.
13. Kaswiner B. A new method of retention. *J Clin Orthod.* 1973;7:744–750.
14. Gazit E, Lieberman MA. An esthetic and effective retainer for lower anterior teeth. *Am J Orthod.* 1976;70:91–93.
15. Zachrisson BU. Clinical experience with direct-bonded orthodontic retainers. *Am J Orthod.* 1977;71:440–448.
16. Dahl EH, Zachrisson BU. Long-term experience with direct-bonded lingual retainers. *J Clin Orthod.* 1991;25:619–630.
17. Surbeck BT, Årtun J, Hawkins NR, Leroux B. Associations between initial, posttreatment, and postretention alignment of maxillary anterior teeth. *Am J Orthod Dentofacial Orthop.* 1998;113:186–195.
18. Little RM. The irregularity index: a quantitative score of mandibular anterior alignment. *Am J Orthod.* 1975;68:554–563.
19. Dahlberg G. *Statistical Methods for Medical and Biological Students.* London, UK: George Allen and Unwin Ltd; 1940.
20. Taner TU, Haydar B, Kavuklu I, Korkmaz A. Short-term effects of fiberotomy on relapse of anterior crowding. *Am J Orthod Dentofacial Orthop.* 2000;118:617–623.