

Functional Lateral Deviation of the Mandible and Its Positional Recovery on the Rat Condylar Cartilage during the Growth Period

Chu Sato^a; Takeshi Muramoto^b; Kunimichi Soma^c

Abstract: The objective was to examine the effects of a lateral functional shift of the rat mandible and the effects of a shift release on the condylar cartilage during the growth period. Fifty 5-week-old male Wistar rats were initially divided into three groups: shift, recovery, and control. At 5 weeks of age, each animal in the shift and recovery groups received an appliance designed to produce a lateral functional shift of the mandible to the left side. For the recovery group, the appliance was removed after 2 weeks. For the shift group, the appliance was used for 4 weeks. Total cartilage thickness, 5-bromo-2'-deoxyuridine-labeling index, and toluidine blue and tartrate-resistant acid phosphatase-positive cell number in the condylar cartilage at 1, 2, 3, and 4 weeks were compared with those in age-matched controls that had no appliances. In the shift group at 2 weeks, the cartilage thickness and labeling index increased in the central region on the contralateral side, whereas these decreased in the lateral region on the ipsilateral side. However, in the recovery group, 1 to 2 weeks after appliance removal, the cartilage thickness and labeling index in both investigated regions became similar to the control groups. These results emphasize the importance of early treatment to normalize occlusion and create appropriate conditions for normal occlusal development. (*Angle Orthod* 2006;76:591–597.)

Key Words: Condylar cartilage; Functional lateral deviation; BrdU; Growth period; Recover

INTRODUCTION

Unilateral posterior crossbite is one of the most frequent malocclusions in the deciduous and early mixed dentitions, with a reported incidence of 7% to 23%.^{1–3} In the early stages, such crossbites are associated

with a lateral functional shift of the mandible in approximately 80% of the cases.^{4,5} A few studies have demonstrated that a functional shift is rarely detected with a unilateral crossbite. This may be an indication of adaptive remodeling changes of the temporomandibular joint (TMJ) with age, leading to development of skeletal asymmetry.^{6,7} Early treatment for such patients by eliminating the functional factors is therefore advisable. It has been clinically reported that early intervention can correct the skeletal deformity, achieving symmetrical growth of jaw bones.^{8,9}

The growth and development of the condyle is thought to be associated with heredity, hormones, environment, and metabolism.¹⁰ There have been various studies in which malocclusion was experimentally induced and its influence on the condyle was histopathologically examined.

Some histological studies have evaluated the effect of lateral forced bite on the condylar growth and on the mandible in rats after appliance usage.¹¹ Lateral deviations of the mandible alter muscles attached to the mandible and induce maxillary deformity. Another study reported that a long-term functional shift affects the structure of the mandible and condyle, based on

^a Graduate Student, Orthodontic Science, Department of Orofacial Development and Function, Division of Oral Health Science, Graduate School, Tokyo Medical and Dental University, Tokyo, Japan.

^b Research Assistant, Orthodontic Science, Department of Orofacial Development and Function, Division of Oral Health Science, Graduate School, Tokyo Medical and Dental University, Tokyo, Japan.

^c Professor and Chairman, Orthodontic Science, Department of Orofacial Development and Function, Division of Oral Health Science, Graduate School, Tokyo Medical and Dental University, Tokyo, Japan.

Corresponding author: Dr. Chu Sato, Orthodontic Science, Department of Orofacial Development and Function, Division of Oral Health Science, Graduate School, Tokyo Medical and Dental University, 1-5-45 Yushima Bunkyo-ku, Tokyo 113-8549, Japan (e-mail: chusato.orts@tmd.ac.jp)

Accepted: June 2005. Submitted: June 2005.

© 2006 by The EH Angle Education and Research Foundation, Inc.

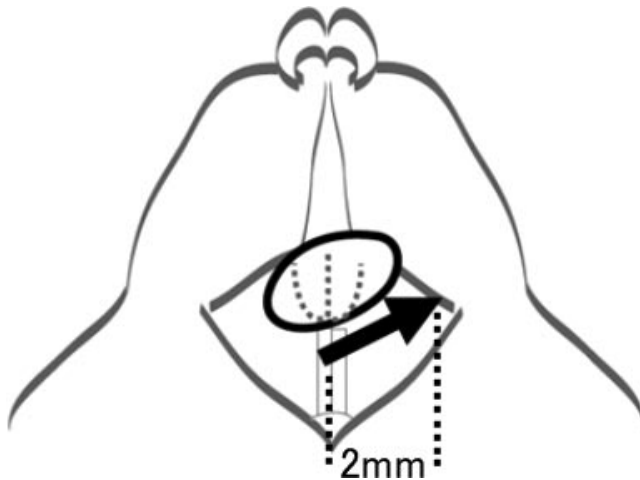


FIGURE 1. Five-week-old rat with an appliance in frontal view, designed to produce shift to the left side.

evaluation using micro-CT.¹² Moreover, an investigation of rat condylar cartilage in the parasagittal plane indicated that a lateral functional shift of the mandible to the left side resulted in an increased thickness by proliferation of prechondroblastic cells on the right side, while causing a growth decrease on the left side.¹³ Although some studies have elucidated the mechanism of a lateral functional shift of the rat mandible, there is no report of a frontal observation of condylar cartilage changes after appliance removal, allowing recovery of the cartilage tissues.

In this study, we examined for 4 weeks, by means of histochemical and immunohistochemical techniques, the effects of a lateral functional shift of the rat mandible and the effects of a shift release on the condylar cartilage during the growth period.

MATERIALS AND METHODS

Five-week-old, male Wistar rats were used in this study. All animals had access to powder form fodder (Rodent Diet CE-2; Japan Clea Inc, Shizuoka, Japan) and drinking water ad libitum. All procedures followed the guidelines of the Tokyo Medical and Dental University for Animal Research. The experimental protocols were approved by the local ethics committee.

Experimental model and tissue preparations

Fifty rats were initially divided into three groups: a shift group of 20 rats, a recovery group of 10 rats, and a control group of 20 rats. At 5 weeks of age, each animal in the shift and recovery groups received an appliance designed to produce a 2-mm lateral functional shift of the mandible to the left side (Figure 1). For the recovery group, the appliance was removed after 2 weeks to allow for TMJ recovery. The animals

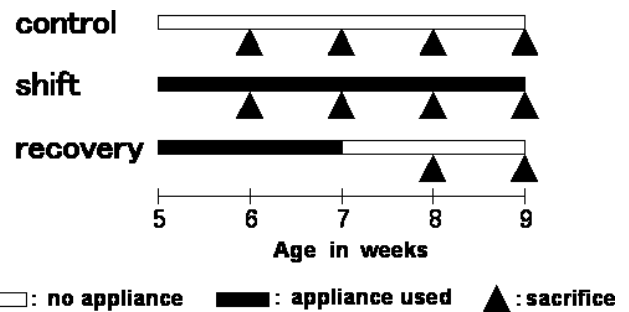


FIGURE 2. Summary of experimental time schedules and protocols. Animals in the shift and control groups were sacrificed at 1, 2, 3, or 4 weeks. Animals in the recovery group had their appliances removed after 2 weeks and then were sacrificed at 1 week or 2 weeks after appliance removal.

in the control group received no appliances. An appliance made of band material (0.180 × 0.005 inch; Rocky Mountain, Denver, Colo) was attached to the maxillary incisor using light-curing composite resin (Clearfil Liner Bond 2; Kuraray Co, Ltd, Okayama, Japan) under deep anesthesia. The left mandibular condyle was designated the ipsilateral side, whereas the right one was designated the contralateral side.

Five animals in each of the shift and control groups were sacrificed at four time points (1, 2, 3, and 4 weeks). All animals in the recovery group had the appliances removed after 2 weeks, and five animals were sacrificed at each point 1 week and 2 weeks after appliance removal. The experimental time schedule and protocols are summarized in Figure 2.

All the animals were deeply anesthetized with diethyl ether and an intraperitoneal injection of chloral hydrate (400 mg/kg body wt) and perfused transcardially with 4% paraformaldehyde (EM, TAAB, Berkshire, England) in 0.1 M phosphate buffer (pH 7.4). Both TMJs were removed and further immersed in the same fixative for 12 hours at 4°C, decalcified in 4% ethylene diamine tetraacetic acid solution (pH 7.4) for 5 weeks at 4°C, and embedded in paraffin by conventional methods. Then, 5- μ m-thick serial frontal sections of the condyle were cut (RM2155, LEICA Co Ltd, Nussloch, Germany) to include the surrounding tissues. For histologic and histochemical examinations, the sections were stained with toluidine blue and tartrate-resistant acid phosphatase (TRAP), and observed with a light microscope.

Immunohistochemistry

The activity of the cells in the proliferate zone of the condylar cartilage was evaluated in recently divided cells by immunohistochemical reactivity of 5-bromo-2'-deoxyuridine (BrdU).¹³⁻¹⁵ The rats were injected intraperitoneally with BrdU (10 mg/kg body wt) 1 to 2 hours before fixation. The recently divided cells were de-

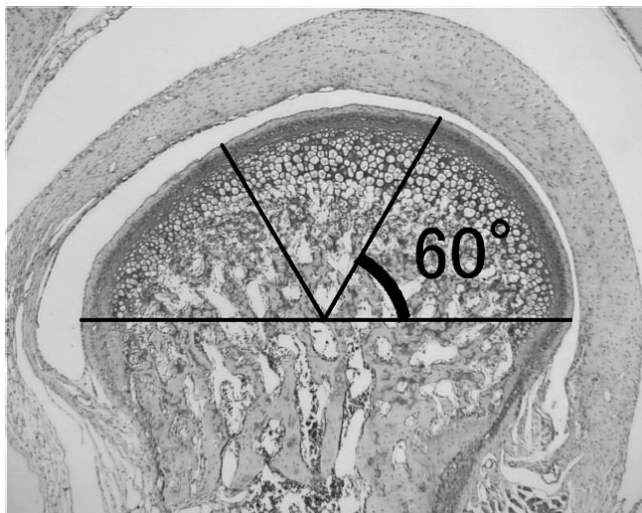


FIGURE 3. Frontal section of the mandibular condyle. The upper portion of the condylar head was divided into three regions of 60° each: the lateral, central, and medial regions.

tected using Monoclonal Anti-BrdU (Anti-Bromodeoxyuridine formalin grade, Roche Diagnostics, Inc, Indianapolis, Ind) according to the manufacturer's instructions, and the immunoreactive sites were observed using a liquid DAB substrate kit (Zymed, San Francisco, Calif).

Histomorphometry and statistical analysis

The sections were photographed with a digital camera (Nikon DXm1200, Kanagawa, Japan). A horizontal line was drawn through the most prominent lateral and medial points of the condylar head. From the middle point of the line, the upper portion of the condylar head was divided into three regions of 60° each: the lateral, central, and medial regions (Figure 3). We evaluated the lateral region of the ipsilateral side and the central region of the contralateral side, where the most drastic changes in cell dynamics was observed by the three methods mentioned below.

The total thickness of the cartilage stained with toluidine blue was measured. The number of TRAP-positive, multinucleated chondroclasts, which were discriminated from osteoclasts, was counted. The number of BrdU-positive cells per square millimeter in the entire proliferative layer of the condylar cartilage was counted and reported. The ratio of the number of BrdU-labeled cells to the area of the layer was obtained and designated the labeling index (number of labeled cells per area in mm²). In both inspected regions, all measurements were performed using Image-Pro Plus Software (version 4.1; Media Cybernetics, Silver Spring, Ga).

To evaluate the differences among the groups at each week, a statistical analysis was performed by Schiff's post hoc test using Stat View 5.0J software (SAS Institute, Cary, NC). The significance level was set at $P = .05$.

RESULTS

Cartilage thickness

In the control group, the total cartilage thickness gradually decreased over the experimental period in the condylar lateral and central regions (Figure 3). In the shift group, the total cartilage thickness of the lateral region on the ipsilateral side significantly decreased after 2 weeks of appliance usage (Figures 4 through 6). However, the total cartilage thickness of the central region on the contralateral side doubled compared with the control group at 2 weeks but decreased at 3 and 4 weeks. On the other hand, after appliance removal, the total cartilage thicknesses in both investigated regions had no significant difference between the recovery and control groups at week 4.

BrdU labeling

In the control group, at 2 weeks, the labeling index of both investigated regions increased but gradually

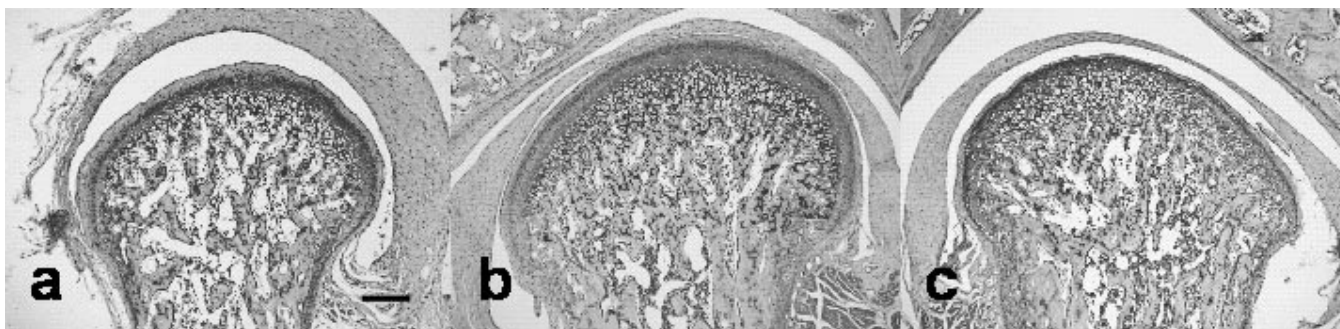

FIGURE 4. Frontal section of the condylar cartilage at 2 weeks stained with toluidine blue. Compared with the control group (a) total cartilage thickness in the shift group increased in the central region of the contralateral side (b) and decreased in the lateral region of the ipsilateral side (c). Bar = 200 μm .

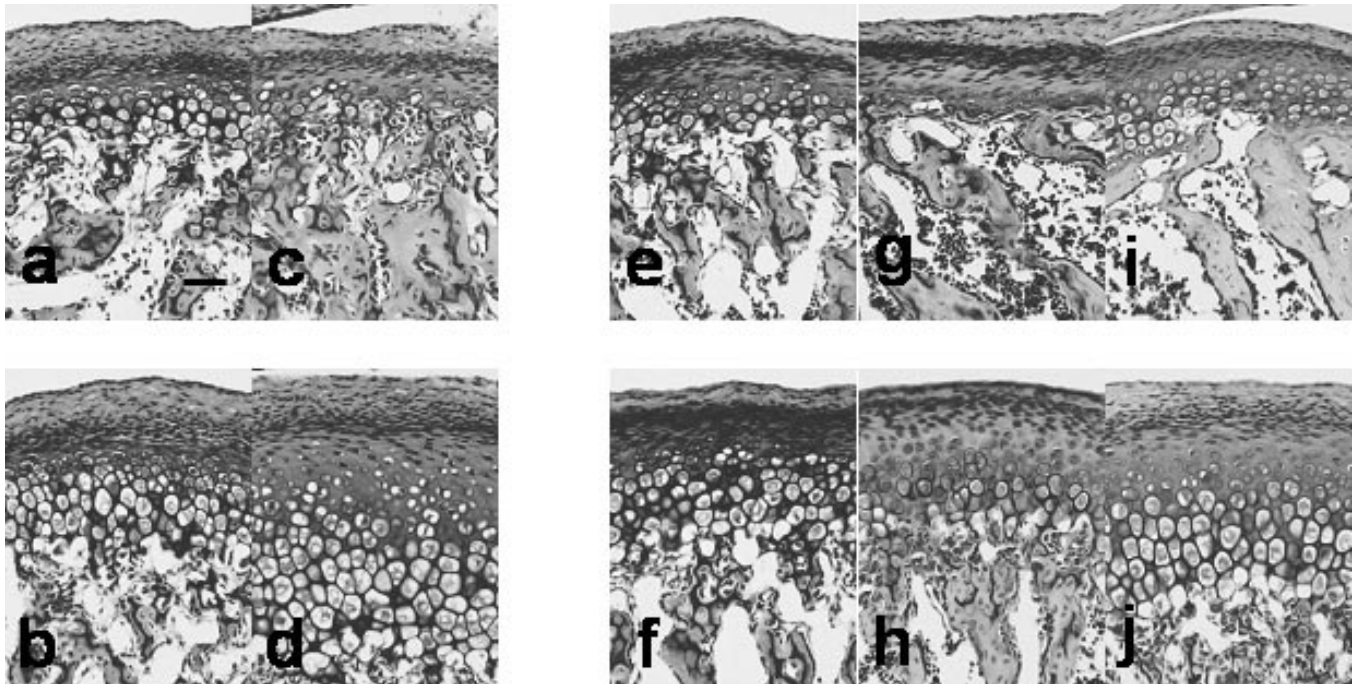


FIGURE 5. Photomicrographs of mandibular condylar sections stained with toluidine blue. The upper view is the lateral region of the ipsilateral side and the lower view is the central region of the contralateral side. (a, b, c, d), at 2 weeks; (e, f, g, h, i, j), at 4 weeks. (a, b, e, f), in the control group; (c, d, g, h), in the shift group; (i, j), in the recovery group. Bar = 50 μ m.

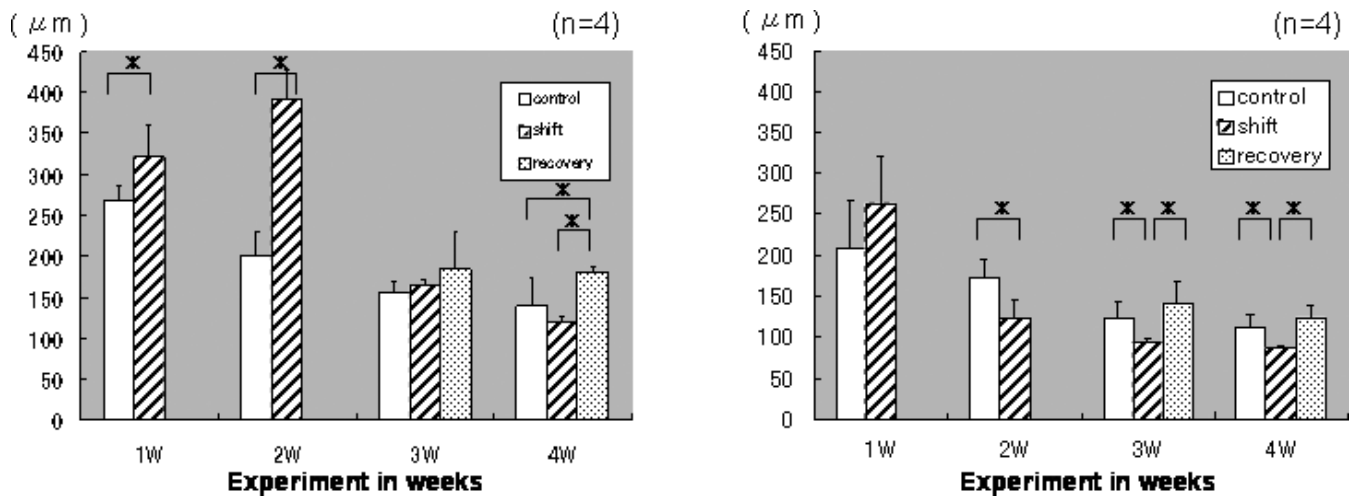


FIGURE 6. Total cartilage thickness of the central region on the contralateral side (left graph) and of the lateral region on the ipsilateral side (right graph) ($P < .05$, $n = 4$).

decreased at 3 and 4 weeks (Figure 7). In the shift group, the labeling index of the lateral region on the ipsilateral side increased at 1 week but significantly decreased, approximately 50%, at 2 weeks. Moreover, it gradually decreased at 3 and 4 weeks. Conversely, the labeling index of the central region on the contralateral side showed the highest increase, approximately 25% more than in the controls at 2 weeks, and then, it became similar to the control group at 3 weeks. In the recovery group, the labeling index of the lateral

region on the ipsilateral side after 2 weeks of appliance removal significantly increased compared with the shift group, but at 4 weeks it showed no significant difference from the control group. The labeling index of the central region on the contralateral side showed no disparities with the shift group.

TRAP-positive cell number

In the control group, the TRAP-positive cell number in both investigated regions increased for the first 2

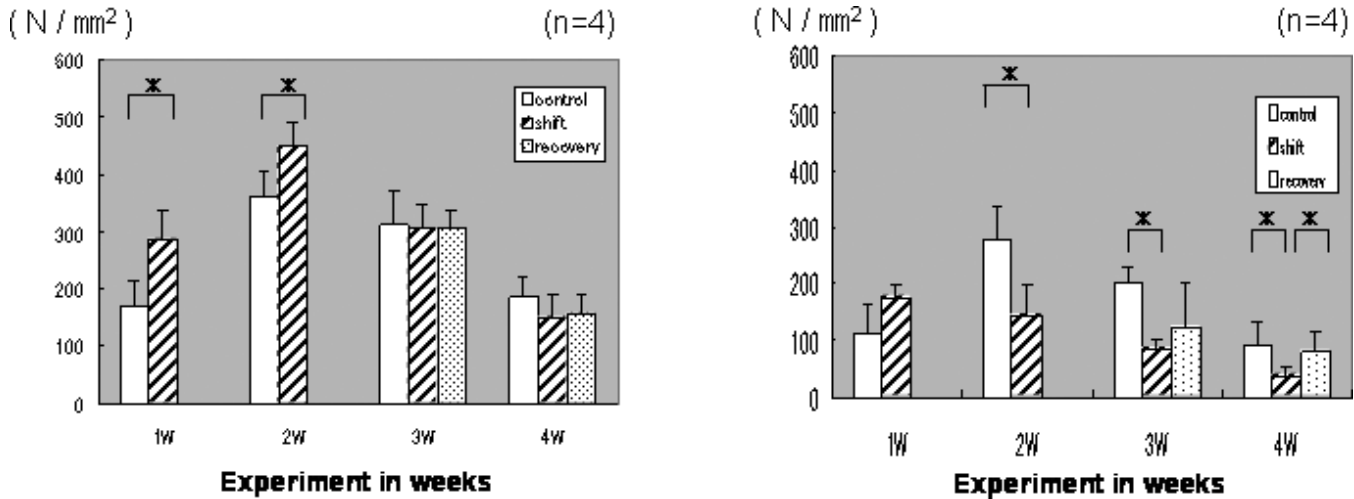


FIGURE 7. 5-bromo-2'-deoxyuridine-labeling index (number of labeled cells per area in mm^2). The left graph is the labeling index of the central region on the contralateral side. The right graph is the lateral region on the ipsilateral side ($P < .05$, $n = 4$).

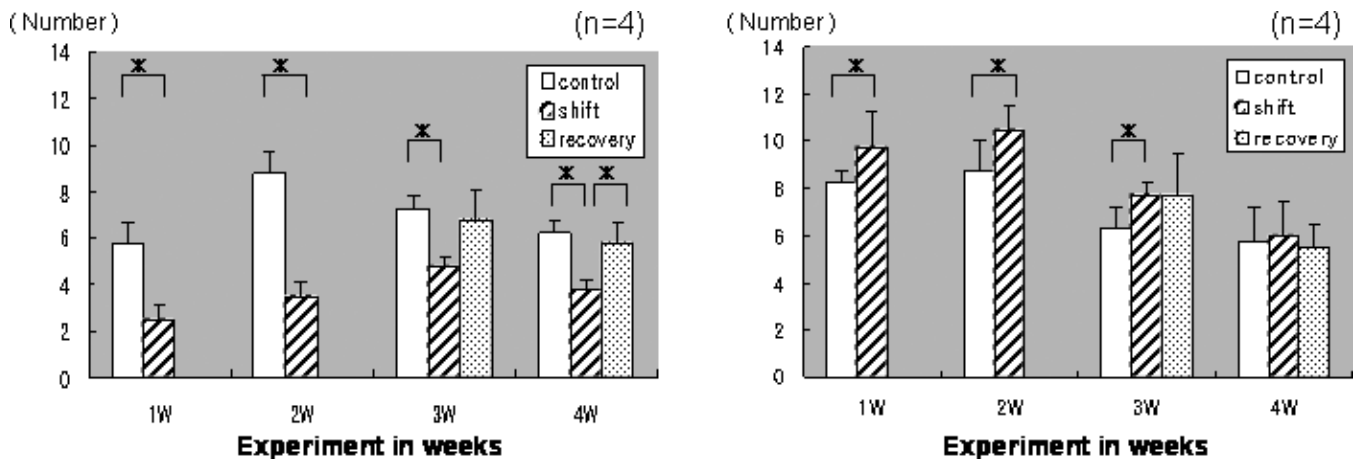


FIGURE 8. The number of toluidine blue and tartrate-resistant acid phosphatase-positive cell was counted. The left graph is the number in the central region of the contralateral side, and the right graph is the number in the lateral region of the ipsilateral side ($P < .05$, $n = 4$).

weeks but reduced at weeks 3 and 4 (Figure 8). In the shift group, the TRAP-positive cell number in the lateral region on the ipsilateral side increased until 3 weeks. On the other hand, the TRAP-positive cell number of the central region on the contralateral side was significantly reduced, relative to the control group, during the same time period. In the recovery group, the TRAP-positive cell number of both investigated regions showed the same pattern as the control group two weeks after appliance removal.

DISCUSSION

Numerous appliances have been developed to induce malocclusion affecting rat condylar cartilage.^{16,17} In this study, we developed an appliance that can be placed for a long period of time (4 weeks) but also can be removed easily to allow tissue recovery. There are

almost no morphological changes of the condylar cartilage if the extent of the shift is one mm. On the other hand, a long-term experiment cannot be performed if the shift is 3 mm or more because of nutritional problems. After considering these points, we established the extent of the shift as 2 mm, as shown in Figure 1. During the experimental period, no significant body weight differences were observed among the groups.

The results of this study show that lateral functional shift of the mandible affects the condylar cartilage during the growth period. This finding of augmented total cartilage thickness of the central region on the contralateral side can be correlated with numerous reports of proliferation in the posterior region of condylar cartilage in response to protrusion of the rat mandible.^{18,19} On the other hand, the reduced total cartilage thickness of the lateral region on the ipsilateral side can be

correlated with the reduction in the posterior region of condylar cartilage, in response to retrusion of rat mandible.^{15,20} Considering our findings that total cartilage thickness of the recovery group in both investigated regions recovered to the same amount as the control group at 4 weeks, it can be suggested that early clinical intervention of functional shift of the mandible can minimize potential development of skeletal asymmetry.

Proliferating cells in the perichondrium of the mandibular condyle are progenitor cells of mesenchymal origin, which later differentiate into chondroblasts and hypertrophy to become chondrocytes. After mineralization, the cartilage is replaced by bone via erosion. The balance in timing between the cell proliferation from the surface of the condyle and the erosion of the marrow is surmised to maintain the cartilage thickness of the condyle.²¹

Evaluation of cell dynamics with time in condylar cartilage was achieved by immunohistochemical reactivity of BrdU to detect cell proliferation and by the use of TRAP to stain osteoclasts. Given that the molecular basis of the condylar response is being actively investigated,^{22,23} BrdU-labeled cells, ie, the S phase cells, were clearly visible with well-preserved cytological detail.¹³⁻¹⁵ The fact that the BrdU-labeling index of the central region on the contralateral side significantly increased at 1 and 2 weeks implies that extension on one side can be accounted for by the proliferation of the cartilage thickness in the region. In contrast, in the lateral region of the ipsilateral side, the BrdU-labeling index decreased and, also, the total cartilage thickness reduced at 2 weeks. This indicates that the compression force increased in the referred region. The increase of the TRAP-positive cell number in the lateral region on the ipsilateral side at 1 and 2 weeks supports the view that bone resorption accelerates to adapt to sudden environmental changes.²⁴

Many investigations have indicated that skeletal growth and development are modulated by mechanical forces, particularly in bones formed by endochondral ossification from secondary cartilages.^{25,26} Condylar cartilage is important for condylar growth and plays an important role as a part of the TMJ. It is known that compressive, shearing, and other complex functional forces are exerted on the mandibular condyle during mastication. Compressive loading on the mandibular condyle has been shown to reduce the thickness of cartilage *in vitro*²⁷ and *in vivo*,²⁸ when loading is applied for more than 1 week. These findings are compatible with our results in the lateral region of the ipsilateral side, a region which is believed to have received excessive compressive loading.

Clinical reports demonstrate that children with unilateral functional crossbite exhibit mandibular skeletal

asymmetries.^{6,7} The asymmetry is expressed not only in the skeletal pattern but also in the functional pattern, including muscular activity and mandibular movement.²⁹ Moreover, patients with lateral deviation can have displaced disk and morphological changes of the condyle in the shifted side.³⁰ Early treatment for such patients, by eliminating the functional factors, is therefore advisable.

CONCLUSIONS

- Functional shift of rat mandible during the growth period changes the morphology of the condylar cartilage in the lateral region on the ipsilateral side and in the central region on the contralateral side.
- After appliance removal, the cartilage layer gradually became similar to the control group.
- These results emphasize the importance of early treatment to normalize occlusion and create appropriate conditions for normal occlusal development.

ACKNOWLEDGMENTS

This work was partially supported by Grant-in-Aids for Scientific Research (14370688, 15791202, 15592156, and 15592158) from the Ministry of Education, Culture, Sports, Science, and Technology of Japan.

REFERENCES

1. Foster TD, Day AJ. An investigation into the prevalence of molar crossbite and some associated etiological conditions. *Dent Pract.* 1971;21:402-410.
2. Hawes RR, Kutin G. Posterior crossbites in the deciduous and mixed dentitions. *Am J Orthod.* 1969;56:491-504.
3. Infante PF. An epidemiologic study of finger habits in preschool children as related to malocclusion, socioeconomic status, race, sex and size of community. *J Dent Child.* 1976; 1:33-38.
4. Bergland L, Kurol J. Longitudinal study and cost-benefit analysis of the effect of early treatment of posterior crossbites in the primary dentition. *Eur J Orthod.* 1992;14:173-179.
5. Wahlund S, Thilander B, Lennartsson B. The effect of early interceptive treatment in children with posterior crossbite. *Eur J Orthod.* 1984;6:25-34.
6. Myers DR, Barenie JT, Bell RA, Williamson EH. Condylar position of children with functional posterior crossbite: before and after crossbite correction. *Pediatr Dent.* 1980;2: 190-194.
7. Kantomaa T, Pirttiniemi P, Lahtela P. Relationship between craniofacial and condyle path asymmetry in unilateral crossbite patients. *Eur J Orthod.* 1990;12:408-413.
8. Mongini F, Schmid W. Treatment of mandibular asymmetries during growth. A longitudinal study. *Eur J Orthod.* 1987;9:51-67.
9. Vig PS, Vig KW. Hybrid appliances: a component approach to dentofacial orthopedics. *Am J Orthod Dentofacial Orthop.* 1986;90:273-285.
10. Copray JC, Jansen HW, Duterloo HS. Growth of the mandibular condylar cartilage of the rat in serum-free organ culture. *Arch Oral Biol.* 1983;28:967-974.

11. Ishii K. A histological study on the maxillary change to lateral deviation of the mandible and morphologic recovery after renovation of it. *J Jpn Orthod Soc.* 1992;51:109–125.
12. Nakano H, Maki K, Shibasaki Y, Miller AJ. Three-dimensional changes in the condyle during development of an asymmetrical mandible in a rat: a microcomputed tomography study. *Am J Orthod Dentofacial Orthop.* 2004;126:410–420.
13. Fuentes MA, Opperman LA, Buschang P, Bellinger LL, Carlson DS, Hinton RJ. Lateral functional shift of the mandible: part I. Effects on condylar cartilage thickness and proliferation. *Am J Orthod Dentofacial Orthop.* 2003;123:153–159.
14. Gratzner HG. Monoclonal antibody to 5-bromo-and 5-iododeoxyuridine: a new reagent for detection of DNA replication. *Science.* 1982;218:474–475.
15. Teramoto M, Kaneko S, Shibata S, Yanagishita M, Soma K. Effect of compressive forces on extracellular matrix in rat mandibular condylar cartilage. *J Bone Miner Metab.* 2003;21:276–286.
16. Cholasueksa P, Warita H, Soma K. Alterations of rat temporomandibular joint in functional posterior displacement of the mandible. *Angle Orthod.* 2004;74:677–683.
17. Kantomaa T, Pirttiniemi P. Differences in biologic response of the mandibular condyle to forward traction or opening of the mandible. *Acta Odontol Scand.* 1996;54:138–144.
18. Ghafari J, Degroote C. Condylar cartilage response to continuous mandibular displacement in the rat. *Angle Orthod.* 1986;55:49–57.
19. Rabie AB, She TT, Hägg U. Functional appliance therapy accelerates and enhances condylar growth. *Am J Orthod Dentofacial Orthop.* 2003;123:40–48.
20. Asano T. The effects of mandibular retractive force on the growing rat mandible. *Am J Orthod Dentofacial Orthop.* 1986;90:464–474.
21. Kantomaa T, Tuominen M, Pirttiniemi P. Effect of mechanical forces on chondrocyte maturation and differentiation in the mandibular condyle of the rat. *J Dent Res.* 1994;73:1150–1156.
22. Tang GH, Rabie AB. Runx2 regulates endochondral ossification in condyle during mandibular advancement. *J Dent Res.* 2005;84:166–171.
23. Nakamura H, Kato R, Hirata A, Inoue M, Yamamoto T. Localization of CD44 (Hyaluronan Receptor) and Hyaluronan in rat mandibular condyle. *J Histochem Cytochem.* 2005;53:113–120.
24. Sugiyama H, Lee K, Imoto S, Sasaki A, Kawata T, Yamaguchi K, Tanne K. Influences of vertical occlusal discrepancies on condylar responses and craniofacial growth in growing rats. *Angle Orthod.* 1999;69:356–364.
25. Garcia AM, Black AC, Gray ML. Effect of physiochemical factors on growth of mandibular condyles in vitro. *Calcif Tissue Int.* 1994;54:499–504.
26. Bouvier M. Effects of age on the ability of the rat temporomandibular joint to respond to changing functional demands. *J Dent Res.* 1988;67:1206–1212.
27. Copray JC, Jansen HW, Duterloo HS. An in vitro system for studying the effect of variable compressive forces on the mandibular condylar cartilage of the rat. *Arch Oral Biol.* 1985;30:305–311.
28. Endo Y, Mizutani H, Yasue K, Senga K, Ueda M. Influence of food consistency and dental extractions on the rat mandibular condyle: a morphological, histological and immunohistochemical study. *J Craniomaxillofac Surg.* 1998;26:185–190.
29. Miyawaki S, Tanimoto Y, Araki Y, Katayama A, Kuboki T, Takano-Yamamoto T. Movement of the lateral and medial poles of the working condyle during mastication in patients with unilateral posterior crossbite. *Am J Orthod Dentofacial Orthop.* 2004;126:549–554.
30. Ueki K, Nakagawa K, Takatsuka S, Shimada M, Marukawa K, Takazakura D. Temporomandibular joint morphology and disk position in skeletal Class III patients. *J Craniomaxillofac Surg.* 2000;28:362–368.