

Current Concept review

Intertrochanteric fractures

GS Kulkarni, Rajiv Limaye, Milind Kulkarni, Sunil Kulkarni

Post Graduate Institute of Swasthiyog Pratishthan, Extn. Area, Miraj, Maharashtra.

Intertrochanteric fracture is one of the most common fractures of the hip especially in the elderly with porotic bones, usually due to low-energy trauma like simple falls. The incidence of intertrochanteric fracture is rising because of increasing number of senior citizens with osteoporosis. By 2040 the incidence is estimated to be doubled. In India the figures may be much more. Problems of these fractures are (1) association with substantial morbidity and mortality (2) malunion (3) implant failure, cutout of head, and penetration into hip. (4) great financial burden to the family (5) associated medical problem like diabetes, hypertension.

Historically Smith Peterson nail and Jewet nail were introduced in the 1930's. In the 1950's and 60's Pugh and Massie modified sliding devices and dynamic hip screw (DHS) were developed. Kuntscher¹, Zickle, Grosse², Kempf and Russel and Taylor³ developed intramedullary nail (IMN) with sliding hip screw (SHS). Recently second generation nails have been developed. Some have 2 screws to be inserted in the head e.g. proximal femoral nail of AO.

It is universally agreed that the treatment of intertrochanteric fractures is stable internal fixation as early as possible. Stable fixation is the keystones of successful union of trochanteric fractures. Factors beyond the control of surgeon for successful treatment are: (i) fracture geometry and stability, (ii) bone quality, (iii) comminution. Factors under the control of surgeon are: (i) good reduction, (ii) proper choice of implant, (iii) proper surgical technique, and (iv) availability of modern operation rooms, entire set of implants, instrumentation and image intensifier.

The factors most significant for instability and fixation failure are: (i) loss of posteromedial support, (ii) severe comminution, (iii) subtrochanteric extension of the fracture, (iv) reverse oblique fracture. (v) shattered lateral wall (vi) extension into femoral neck area and (vii) poor bone quality. Osteoporosis is particularly important in the fixation of proximal femoral fractures. This can be measured by Singh's index and bone densitometry.

GS Kulkarni, MS, MS (Orth), FICS, Director
Rajiv Limaye, MS (Orth), Consultant Orthopaedic Surgeon
Milind Kulkarni, MS (Orth), Consultant Orthopaedic Surgeon
Sunil Kulkarni, MS (Orth), Consultant Orthopaedic Surgeon
Fracture & Orthopaedic Hospital, Post Graduate Institute of Swasthiyog
Pratishthan, Extn. Area, Miraj, Maharashtra. ✉

Mechanism of Injury: 90% or more of hip fracture occur in the elderly from a simple fall in the house due to direct or indirect forces. Five factors contribute to hip fracture. 1) Person landing on the hip (2) Inadequate reflexes (3) Absence of local shock absorber – Muscles and fat around the hip and (4) Osteoporosis. Currently more attention is paid to prevention of hip fracture. Hip fracture can occur from cyclic mechanical stresses resulting in stress fracture.

Classification

Commonly, fractures are described by the number of "parts" (fragments) and instability. The presence of certain fracture characteristics such as displaced postero-medial fragment shattered lateral wall, indicate instability.

There are several classifications⁴⁻⁷. Evans⁴ has based his classification on stability of the fracture. Jansen has modified Evans classification into three groups. (1) Stable (2) Unstable (3) Very unstable. Gotfried⁵ and Kyle⁶ each have added a new variety of intertrochanteric fracture. Using Evan-Jansen's and AO/OTA classification and adding the new varieties described by Gotfried⁵ and Kyle⁶, authors present a new treatment oriented classification.

Type I : Stable fractures consists of nondisplaced, stable intertrochanteric fractures without comminution. Fractures are stable, minimally comminuted and displaced. Reduction of these fractures leads to a stable construct. Stable fractures heal well with any fixation device. These can be very well treated by dynamic hip screw (DHS) with excellent results.

Type I A is undisplaced, 2 stable piece fracture, type I B is displaced, reducible, stable, 2 piece fracture, Type I C is displaced, but reducible, stable fracture with a small piece of lesser trochanter.

Type II- Unstable fractures: These, the so-called problem fractures are unstable and are 3 piece or 4 piece fractures with a large displaced postero-medial fragment which includes lesser trochanter. Gotfried⁵ has shown that shattered lateral wall is an unstable fracture. These above described unstable fractures can be treated with DHS with some modification or IMN with SHS.

Type III : Very unstable fractures : this fracture type includes 1.reverse oblique 2.trochanteric fractures with subtrochanteric extension 3. comminuted trochanteric fracture with extension into neck of the femur (Kyle variety).

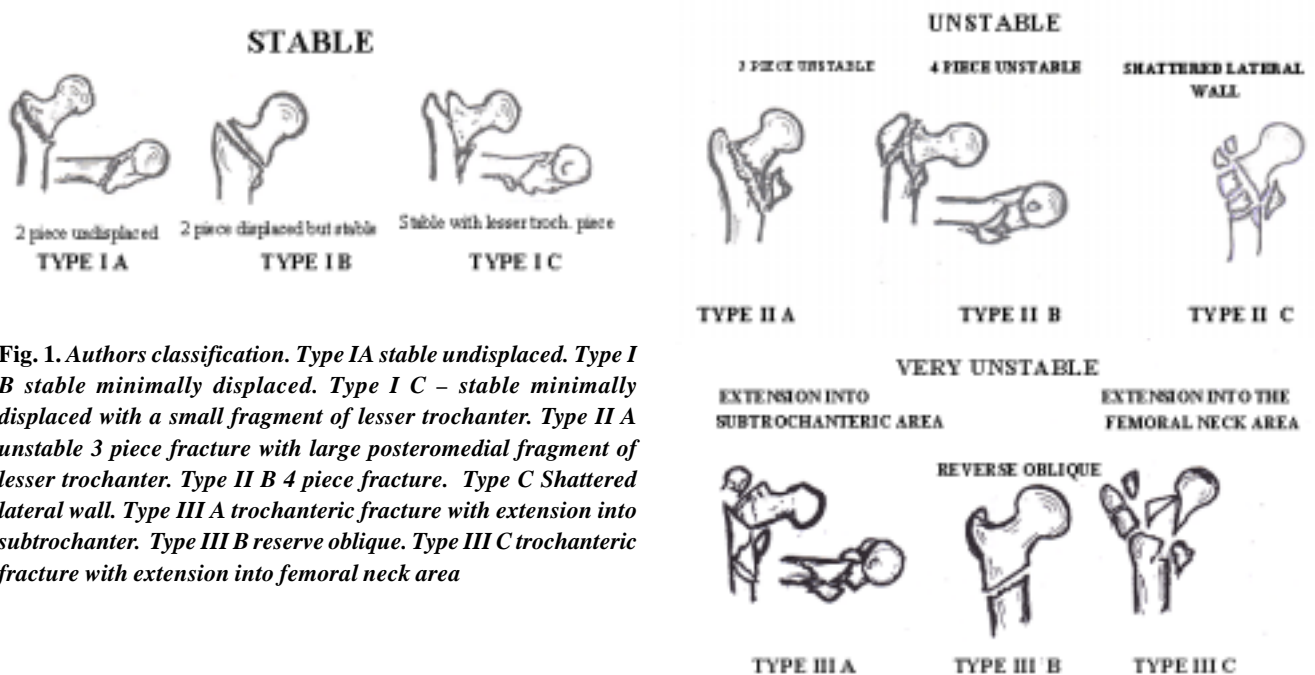


Fig. 1. Authors classification. Type IA stable undisplaced. Type I B stable minimally displaced. Type I C – stable minimally displaced with a small fragment of lesser trochanter. Type II A unstable 3 piece fracture with large posteromedial fragment of lesser trochanter. Type II B 4 piece fracture. Type C Shattered lateral wall. Type III A trochanteric fracture with extension into subtrochanter. Type III B reverse oblique. Type III C trochanteric fracture with extension into femoral neck area

These very unstable fractures require different kind of treatment than DHS. In these fractures DHS gives poor results.

The lateral trochanteric wall: Gotfried⁵ has described the important lateral trochanteric wall as a key element of instability. The lateral trochanteric wall acts as buttress to the proximal fragment. A shattered lateral wall allows excessive collapse of the proximal fragment over the sliding screw. Excessive collapse results in pain, reduced mobility of hip, inability to walk sometimes nonunion and failure. It is important to prevent lateral wall fracture during surgery. If fractured, it should be reconstructed by tension band wiring or lateral buttress plate or lag screws.

Unusual fracture pattern: Basi-cervical neck fracture may be included in intertrochanteric fracture. This fracture is prone to avascular necrosis of the head of the femur. There is also rotational instability. Therefore, additional derotation screw should be used.

Trochanteric fracture associated with fracture of the shaft of femur. These two fractures may be treated by Recon, long Gamma or proximal femoral nail. Pathological fracture forms a separate variety⁸⁻¹¹.

Reverse oblique fracture: Use of DHS in reverse oblique fracture may cause excessive collapse leading to failure. Excessive collapse occurs due to shearing forces and to powerful muscles acting on fragments. In fracture with shattered lateral wall, treated by DHS excessive collapse occurs due to loss of buttressing effect of lateral wall.

Excessive collapse: Recently it has been shown that excessive collapse results in 1. Functional deficit – reduced mobility of hip. 2. Pain resulting in inability to walk and nonunion. 3. Implant failure. Excessive collapse occurs due to excessive sliding as in reverse oblique when treated with D.H.S., lateral wall fracture, severe instability due to comminution.

Excessive collapse may be prevented by trochanteric plate, double barrel plate, reconstruction of lateral wall and IMN.

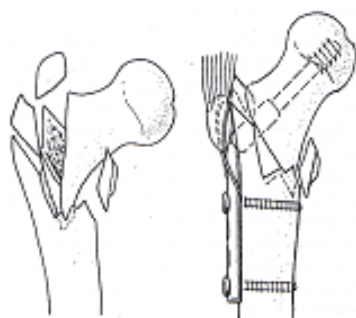
Choice of implant for intertrochanteric fractures

1. Dynamic hip screw.
2. I. M. nailing with sliding hip screw
3. DCS or 95 blade plate (rarely used in reverse oblique fracture)
4. External fixator
5. Arthroplasty- Bipolar or total hip replacement.

Dynamic hip screw : (DHS)

The use of static implants with a fixed angle at nail plate junction like Smith-Peterson nail, Jewett nail. AO 95 degree blade plate, Thronton, McLaughlin nail plate, etc. are no longer justified since dynamic screw fixation has given uniformly good results due to controlled impaction and stable contact of the fragments. The sliding devices have gained universal popularity as the fixation device for all intertrochanteric fracture. DHS is the gold standard (Fig. 2).

Fig. 2. Typical fracture morphology to be treated with a DHS if the proximal main fragment is very short, femoral head prosthesis can be considered. The main trochanteric fragment is fixed by means of a wire tension band (the screw should be somewhat more distal).



Modifications of DHS:

1. Medoff's plate¹²: Medoff has designed a device that allows axial compression. Medoff recommends the axial compression for unstable fractures.

2. Trochanteric stabilizing plate: The trochanteric stabilizing plate construct buttress the greater trochanter and prevents lateral displacement and excessive fracture collapse which results in limb shortening.

When the lateral wall is shattered it is reconstructed using a lag screw or tension band wire passing through tendon of abductor muscles. Trochanteric stabilizing plate is useful when lateral wall is fractured.

3 Augmentation¹³: Tricalcium phosphate cement or Norian SRS is injected into the void in the postero medial area in unstable fractures. This increases stability.

4. Hydroxyapatite (H.A) coated screw: achieves better fixation in osteoporotic bone.

Surgical technique of DHS: Patient is kept in supine position on a fracture table. It is reduced by traction, slight internal rotation (occasionally external rotation) and by rotating the proximal fragment with the help of guidewires or by lifting the distal fragment up with a bone lever. If there is a posterior sagging it is lifted upward by hohman spike. A crutch can be used to elevate the sagging femur. A slight valgus position is preferred. If closed reduction is not satisfactory, open reduction is performed.

Lateral incision is taken starting from the tip of the greater trochanter about 7cm downwards. While exposing the lateral surface, the vastus lateralis should not be split longitudinally. This maneuver denervates the posterior fibers and is associated with greater bleeding. Entire vastus is elevated subperiosteally. Guidewire is passed in the dead center of head and neck in both anteroposterior and lateral views, the so-called "bull's eye" or center-center placement which is the optimal position. Sliding screw is placed with the tip within 10mm of the sub-chondral border.

Tapping of the femoral head to cut screw threads prior to insertion of the screw is done in all but the most osteoporotic bone. More the barrel covers the distal portion (at 2/3 of barrel) of screw, better it is biomechanically. Hence using long barrel and 32mm thread length screw is preferred to prevent implant failure.

In basal fracture an additional lag screw is inserted to prevent rotation.

Open Reduction: Open reduction is rarely required when closed maneuver fails. Limited exposure of the fracture is performed. In comminuted fractures, the greater trochanter fragment is pulled superiorly to allow direct visualization of the fracture.

Surgical precautions which must be observed in DHS⁶

1. Ascertain that there is no impingement of the labia or scrotum from the fracture table post. Achieve near anatomic reduction in both anteroposterior and lateral views.
2. Satisfactory reduction is crucial for fracture union.
3. Use 135° angle guides to insert the guide pin.
4. Screw in the dead center of femoral head.
5. Observe TAD.
6. Use a standard (long-barrel) plate and 32mm thread length screw.
7. Impact the fracture statically during surgery.
8. Minimum of 4 screw fixed in the distal fragment. If bone is osteoporotic 5 screws are needed.
9. Reconstruct lateral wall if fractured
10. Start weight bearing to tolerance on day 1, if fixation is stable.

Miraj sliding Screw:

We have modified the Richard's dynamic hip screw to make the procedure simpler. More static compression is achieved when required. Following are the modifications.

While the proximal end of screw has coarse threads as in the standard device, its distal end is also threaded. The distal threaded end passes through the nut, instead of the nut entering into the distal end of the screw. When Richard system or DHS is used, the distal end of the screw has to be at least 1 cm away from the cortex to make effective compression of the fragments of inter-trochanteric fracture (however, dynamic compression during the postoperative period is possible). Therefore, the screw must be of exact length. The gap between the two major fragments, especially posteriorly, makes the measurements of the screw inaccurate. If the distal end of the DHS touches the cortex, then there will be no static compression. When Miraj sliding screw is used, even if the

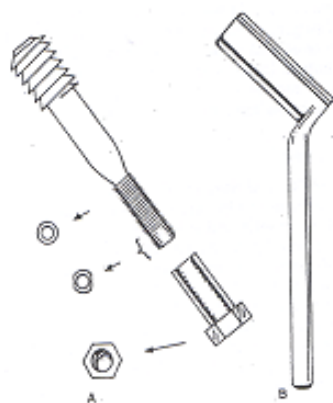


Fig. 3 A and B: (A) Modified Richard's (Miraj screw)—the end of the screw passes through the nut, and (B) barrel plate

end of the screw is out of the femoral cortex, one can compress the two fragments (Fig. 3). With larger nut and hexagonal head, one can apply stronger force to compress the fragments. Good static compression is necessary for the cancellous fragments to make the fracture stable, and unite early.

If the barrel touches the screw thread, the system acts as a fixed angled-plate. Even though it is a fixed angle system, penetration into the acetabulum will not occur because of the blunt tip.

Postoperative management after D.H.S. fixation¹⁴

Most of the elderly patients are allowed immediate weight bearing as tolerated. If there is severe osteoporosis, Singh Gr. I, II, or if the implant is insecure, and in type IV fractures (with subtrochanteric extension). Weight bearing is delayed.

Advantages of sliding screw:

DHS offers the advantages of a simple, predictable surgical technique, and a long clinical history of successful results.

1. Controlled impaction and progressive stabilization. The sliding screw guides the proximal fragment into a stable position. Settling of fracture fragments occurs. Screw sliding in the barrel depends on: (i) fracture geometry, (ii) quality of reduction, (iii) position of screw in the head and neck of femur, (iv) angle of the barrel and plate. (v) integrity of lateral wall.

2. The shearing force on the femoral head being transferred to the axis of the sliding screw, hence producing a compressive force. Because of the bone growth into the threads of the screw, cutting of the implant out of the head and neck is rare (except in Singh's Gr. I osteoporotic bone).

3. Because of the blunt tip, the implant does not penetrate into the acetabulum.

4. With tightening of the nut, a good static compression occurs. As the fracture is in the cancellous bone, compression

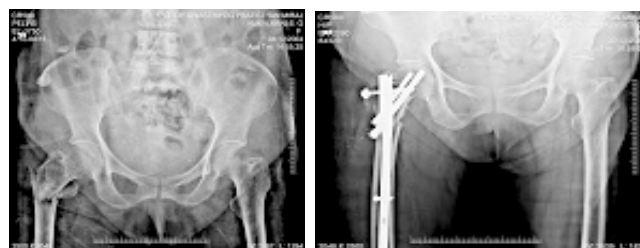

Fig. 4. Comminuted trochanteric fractures with extension into subtrochanteric area

enhances the stability. Dynamic compression occurs during the post-operative period as the patient bears weight on the limb.

5. Because of less pain and good stability, it allows early mobilization and early weight bearing.

6. There is reduced reoperation rate.

7. Incidence of breakage or separation of the components is much less.

Disadvantages of sliding screw:

Despite these theoretical and biomechanical advantages, sliding hip screw constructs have limitations. Excessive collapse results in failure.

1. Sliding of more than 15mm leads to a higher prevalence of fixation failure. Rha and associates found that excessive sliding was the major factor causing failure of fixation.

2. Medialization of the femoral shaft by greater than one third of the diameter of the femur is associated with a seven fold increase in fixation failure.

3. Cutout of implant may occur in severe osteoporotic bone and wrong implant placement.

4. Failure rate of D.H.S. is about 5%.

Pitfalls in using DHS

1. Insufficient or excessive sliding length available between the screw and barrel.

2. Jamming of screw in the low angle barrel plate. (120 or 125 angle).

3. Majority of failure due to poor positioning of screw. TAD > 25 and screw not in the center of head.

4. Lateral wall fracture. Fracture of lateral wall during surgery.

5. D.H.S gives poor results in reverse oblique fracture.

Advantages of central placement of the implant:

1. The placing of the lag screw in a central position avoids the potential complication of a peripherally placed screw,

which may appear to be within the femoral head on both the AP and lateral views at operation, but may lie partly outside the femoral head as seen in tangential view.

2. Central placement prevents penetration of the joint.

3. Centrally placed screw is in the crossing of the trabeculae, which is the strongest part of bone. Therefore the purchase is better.

4. If centrally placed screw length can be longer—more number of threads can be engaged in the strongest part of bone in the femoral head.

Tip apex distance¹⁵:

The tip to apex distance has been described as a guide to accurate screw placement, and should be less than 20 mm. Risk of cutout and is easily measured intra-operatively. Risk of fixation failure approaches zero if TAD < 20 mm. Risk increases rapidly as the screw is placed more peripherally and shallow.

The barrel plate angle is determined from the normal side.

Optimum ideal angle is 135 degree, which is most commonly used. There appears to be no evidence to suggest that any other angle is superior. If the screw is placed inadvertently in the superior half of the head, then a higher angled blade plate (140 degree) may be required. If the screw is placed in the lower half of the head, barrel and plate is less than 135 degree, usually 130 degree.

Mechanical failure rate of the fixation is decreased by anatomic reduction, and by placing the implant centrally within the femoral head. The success of fixation is dependent much more on the technical expertise of the surgeon than on the bone quality of the patient.

Biomechanics¹⁶⁻¹⁸: Strong muscle forces act on the proximal and distal fragments. The proximal fragment is displaced proximally and laterally. Distal fragment is pulled

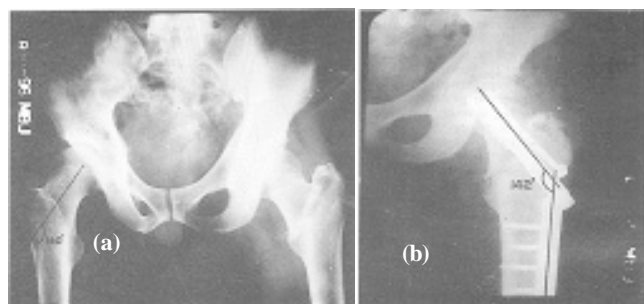


Fig. 5. (a) Stable fracture internal fixation on left side—neck-shaft angle on opposite side is 140 degrees, and (b) close reduction and stable fixation with modified Miraj nailing with AP angle of 142 degree.

up and adducted, resulting in varus external rotation deformity if untreated.

Barrios et al¹⁸ demonstrated that the forces applied to the femoral head and proximal femur with activities such as lifting the leg and getting on and off a bedpan often equal or exceed the load applied during protected ambulation.

Intertrochanteric fractures occur through cancellous bone, which has an excellent blood supply. The fracture unites promptly, even if left untreated albeit with varus deformity. This results in short leg gait, limp, pain, and future osteoarthritis.

In majority of the cases bones are severely porotic with poor implant holding capacity, which may result in implant failure – bending, breaking, pullout of the screws and breakage of the screws heads.

Fracture geometry and stability: Three part or four part fracture with displaced large posteromedial fragment which includes the lesser trochanter is very unstable. Lesser trochanter is a key to evaluating instability. However, the mere presence of a lesser trochanteric fragment does not constitute instability. The size and displacement of the fragment are the critical factors in this evaluation. Large forces act on this portion of the femur. Reconstruction of posteromedial wall by bone graft or augmentation by calcium phosphate cement or by a lag screw is necessary.

Timing of surgery: Operation should be done as soon as possible after the medical condition is improved, because delay in operation is associated with complications¹⁸⁻²⁰. Most of the patients were operated within 48 hours. In some delay was in making the patient medically fit by treating diabetes, hypertension, cardiac problem etc.

Intramedullary nail

IMN with SHS is designed for insertion through greater trochanter. It has a valgus offset of proximal nail which is wider to allow lag screw passage. It can be statically locked and is more expensive than sliding hip screw.

The unstable cases can be helped by medullary fixation as there is more failure of D.H.S. Definitive indications for the intramedullary nail devices are: (1) Reverse oblique fracture (2) Intertrochanteric fracture with subtrochanteric extension. Relative indications are 3 part or 4 part unstable fractures.

Proximal femoral nail (PFN) developed by AO has two sliding screws. Advantages of two sliding screws are:

1. More stable fixation

2. Prevention of rotational deformity. The disadvantage is on weight bearing the proximal screw may penetrate into the hip. So this screw should not be inserted into the head.

Operative technique of intramedullary nailing (I.M.N.):

Using image intensification a closed reduction is performed to as near an anatomical position as possible.

4 cm incision is made just proximal to the greater trochanter. A Awl is positioned on the medial tip of the greater trochanter and advanced within the canal to the level of the lesser trochanter. Guide rod is advanced in the medullary canal and the canal is reamed. Once the nail is seated, the targeting device is used to make a 2cm stab incision. Guide pin is advanced into the femoral head. Correct length of pin is measured by the calibrated reamer. Screw is placed in the both center of the head or slightly inferiorly within 5 to 10mm of subchondral border. Distal locking screws are placed through the zig.

It is preferable to have the nail allowing for use of more angles (125-135), depending on patient anatomy, achieved reduction, and guide pin placement. Different lengths and diameters could help to match more precisely the nail to the patient anatomy (including build in anterolateral curvature).

The nail should be designed for introduction through more anterior entrance portal on the greater trochanter (base of the neck is situated more in front on sagittal projection) than in "piriformis fossa entry portal" antegrade nails (on lateral view entrance is more posterior). Anatomic curvature, rotation, and blunt nail tip will help to avoid distal cortex anterior penetration.

If two C-arms are available, they are positioned at 90-90 degrees angle to each other this could lessen irradiation time up to 60 percent and significantly speed up the procedure.

It is better to put at least one screw in dynamic slot (controls rotation and allows some axial impaction). In very unstable subtrochanteric fractures, two distal locking screws will provide better fixation. Short nails have jigs for easier locking, long nails need "free-hand technique".

If fracture line extends distally to the lesser trochanter more than 3 cm, long nail should be used (ending in distal metaphysis). Distal locking trough the slot, not close to nail tip provides rotational stability allowing at the same time some axial dynamization (if desired). Two distal locking screws will provide more rigidity to the system.

Advantages of intramedullary nail*Biological :*

1. A closed reduction and less soft tissue dissection, therefore more biological fixation.
2. Shorter surgical time.
3. Less blood loss.

4. Improved early patient mobility at 1 and 3 months postoperatively

Mechanical :

1. The nail also has a shorter lever arm, which decreased the tensile strain on the implant and reduced the risk of mechanical failure. It is subjected to lower bending moment due to their intramedullary location. It is a load sharing device, allowing early weight bearing.

2. Controlled fracture impaction is maintained.

Disadvantages of intramedullary nail: Femoral shaft fracture is a complication of the use of first-generation intramedullary nails, 5%. This may occur during or after surgery. Because of the high implant stiffness, high hoop stresses, created by mismatch in implant size and canal diameter have contributed to nondisplaced fractures during nail insertion, which may propagate after weight bearing. This is particularly true with inadequate reaming of the medullary canal and forceful nail insertion. With newer implants, reaming and proper technique and care the fracture incidence is reduced.

1. Thigh pain has been reported to occur in 17% of patients treated with a first-generation nail, and a relationship between thigh pain and the use of two distal interlocking screws and slotted distal hole cause less thigh pain than did one with the standard interlocking holes.

2. The rate of cutout of first-generation intramedullary nails from the femoral head has ranged from 2% to 4.3%. Rotational deformity and back out of nail with resultant pain and stiffness may occur.

3. Nailing of intertrochanteric fracture is a demanding procedure and has great learning curve. Intramedullary implants are associated with unique implant related complications such as: i. haft fracture, due to stress riser effect. ii. Penetration of anterior femoral cortex. iii. Missed targeting of locking. iv. Implant disengagement

Tips for intramedullary nailing:

1. Use second generation nail with decrease curvature length and diameter.
2. Over ream the femoral canal.
3. Insert implant only by hand.
4. Meticulous placement of distal interlocking screws without creating additional stress risers.
5. Anatomical reduction of fracture is a must.

Ender's condylocephalic nail²¹: Ender's nail is associated with complications like distal and proximal

migration, sinus formation, persistent pain external rotation deformity, supracondylar fracture, high reoperation rate and nail breakage or penetration into the hip joint. Therefore it is not popular.

Asia-pacific nail^{8-10,22,23}: Leung in Hong Kong⁸ observed, that the Asian femora are smaller and there were complications. He designed Gamma AP (Asia Pacific) nail for Asian with reduced length, diameter and medially lateral angle.

Second generation intramedullary nails: Second-generation intramedullary nails have: 1. decrease in the distal diameter to 11mm. 2. decrease in the valgus offset to 4°. 3. Shortening of the length. 4. One smaller diameter distal locking hole or slot farther away from the tip. 5. less invasive technique.

The rate of clinical failures here decreased with use of second-generation nails.

The second-generation nails are (1) Proximal femoral nail. (2) Gamma nail (3) Russel - Taylor³ recon nails & others.

External fixation: External fixation is being used at many centers in poor risk patients. With advent of epidural anesthesia, most of the poor risk patients can now be treated with sliding hip screw.

Arthroplasty²⁴: The role of primary prosthetic replacement for intertrochanteric fractures remains controversial. The potential advantages of primary prosthetic replacement for an unstable intertrochanteric fracture in a patient with severely osteoporotic bone are relatively predictable pain relief, early mobilization, and revision rates may be lower. The disadvantages include the more extensive surgery, the frequent necessity to use calcar replacing, long-stem cemented implants in medically frail patients. Majority of well-reduced intertrochanteric hip fractures treated with DHS will heal predictably without complication.

Prosthetic replacement is indicated in patients with pathologic fractures as a result of neoplasm, neglected fractures with deformity and poor bone stock precluding internal fixation, or for patients in whom internal fixation attempts have failed.

Prognosis and complications: Prognosis of trochanteric fractures is good as compared to intracapsular fractures as the complications of fixation of trochanteric fractures are minimal. Failure rate of DHS depends upon its placement in neck and head. Nail breakage is rare. The complication rate of treatment related to the fracture itself is less than 10 percent.²⁵

Shortening due to medialization of the shaft due to severe comminution, collapse of the fracture or varus hip is common

with trendelenburg lurch and many patients need a walking stick. Occasionally, the trochanter unites with fibrous tissue and in some it may cause abductor muscle weakness, and using DHS trochanteric fragment needs fixation with screw.

Fixation failure is rare in spite of allowing the patient full weight bearing the day after surgery even in patients with severe osteoporosis and comminution, provided the sliding implant is placed properly.

Nonunion: Nonunion may occur due to implant or bone failure or neglected fractures. In nonunion, which does not exceed 1 percent, removal of the device and fixation in more valgus position with bone grafting gives the success rate of 90 percent. In elderly patients, a nonunion is best treated by total hip replacement, particularly if the joint is damaged by the penetration of a fixation device or if there is arthritis of the hip.

Malunion: Malunion is usually in varus and external rotation. This deformity is treated by valgus osteotomy. Schatzker²⁵ advocates lateralization of the shaft to restore mechanical axis of the femur from the midsagittal plane. DHS causes medialization of the shaft and subsequent valgus over load at the knee. Schatzker *et al*²⁵ have found the 120 degrees repositioning blade plates to be the appropriate fixation devices as they allow for lateralization of the shaft. Avascular necrosis has not been reported in any series above 1 percent. In the elderly shoe raise may help if surgery is contraindicated.

Conclusions

Dynamic Hip Screw (DHS) is still the gold standard for treating intertrochanteric fractures. The new classification, modified Jensen-Evan's classification is treatment oriented. Unstable intertrochanteric fracture needs some modification or may be treated by IMN with S.H.S. very unstable fractures need I.M.N. or arthroplasty.

Conclusions drawn on evidence based medicine are; given the lower complication rates, a sliding hip screw is superior for intertrochanteric fracture fixation. More studies are needed to determine whether IM nails are superior for select fracture types (reverse oblique fractures). The sliding hip screw remains the implant of choice for stabilization of intertrochanteric hip fractures.

References

1. Kuntscher G. A new method of treatment of pertrochanteric fractures. *Proc R Soc Med.* 1970; 63: 1120.
2. Grosse A, Kempf I, Lafforgue D. *Fen Chir Orthop* 64: (Suppl) 33, 1978

3. **Russel TA.** Fractures of hip and pelvis: In Crenshaw AH (Ed): Campbell's Operative Orthopaedics (8th ed). St Louis: CV Mosby. 1992: 895.
4. **Evans EM.** The treatment of trochanteric fracture of femur. *J Bone Joint Surg (Br)*.1949; 31: 190-203.
5. **Gotfried Y.** The lateral trochanteric wall. *Clin Orthop*. 2004; 425:82-86.
6. **Kyle RF, Gustilo RB, Premer RF.** Analysis of 622 intertrochanteric hip fractures—a retrospective and prospective study. *J Bone Joint Surg (Am)*.1979; 61: 216-21.
7. **Boyd HB, Griffin LL.** Classification and treatment of trochanteric fractures. *Arch Surg*. 1949; 38: 853.
8. **Goldhaggen PR, O'connor DR, Schumarze D et al.** Prospective comparative study of compression hip screw in the Gamma nail. *J Orthop Trauma*. 1994; 8: 367-72.
9. **Leung Ks, So WS, Shung WY et al.** Gamma nails and dynamic hip screws for peritrochanteric fractures—a randomized prospective in the elder patients. *J Bone Joint Surg (Am)*.1992 ;74: 345-51.
10. **Radford PJ, Needoff M, Webb JK.** A prospective prolonged comparison of the dynamic hip screw and the Gamma locking nail. *J Bone Joint Surg (Br)*.1993 ; 75B: 789-93.
11. **Williams WW, Parker BC.** Complications associated with use of the Gamma nail. *Injury*. 1992; 23: 291.
12. **Medoff RJ, Maes K: Mitsunaga M, Chappuis JL.** Axial compression screw: anew implant for the fixation of the high subtrochanteric and unstable intertrochanteric fractures of the hip. Poster exhibit at the 53rd Annual Meeting of the American Academy of Orthopaedic Surgeons, New Orleans, 1990.
13. **Cheug CL, Chow SP, Leons TCV.** Long term results and complications of cement augmentation in the treatment of unstable trochanteric fractures. *Injury* 134, 1989.
14. **Karani R, Meier DE.** Systemic pharmacologic postoperative pain management in the geriatric orthopaedic patient; *Clin Orthop*. No. 425 Aug. 2004.
15. **Baumgaertner MR, Curtin SL, Lindskog DM, Keggi JM.** The value of the tip-apex distance in predicting failure of fixation of peritrochanteric hip fractures of the hip, *J Bone Joint Surg (Am)*. 1995;77:1058.
16. **Spivak JM, Zuckerman JD, Kummer FJ et al.** Fatigue failure of sliding screw in hip fracture fixation—Report of three cases. *J Orthop Trauma*. 1991; 3: 325-31.
17. **Tordis TC.** Stress analysis of femur. *J Biomech*. 1969; 2: 163.
18. **Barrios C, Brostrom LA, Stark A et al.** Healing complications after internal fixation of trochanteric hip fractures—the prognostic value of osteoporosis. *J Orthop Trauma*. 1993; 7:438-42.
19. **Pun WK, Chow SP, Chan KC et al.** Effusions in the knee in elderly patients who were operated on for fracture of the hip. *J Bone Joint Surg (Am)*. 1988; 70: 117-18.
20. **Shi LY, Chen TH, Lo WH.** Avascular necrosis of the femoral head and unusual complications of an intertrochanteric fractures. *J Orthop Trauma*. 1992; 6:82-85.
21. **DiMayo FR, Haheer TR, Splain SH et al.** Stress riser fractures of the hip after sliding screw plate fixation. *Ortho Rev* . 1992; 10: 1229-31.
22. **Bridle SH, Patel AD, Bircher M et al.** Fixation of intertrochanteric fractures of the femur—a randomized perspective comparison of the Gamma nail and dynamic hip screw. *J Bone Joint Surg (Br)*.1991;73: 330-334.
23. **Halder SC.** The Gamma nail for peritrochanteric fractures. *J Bone Joint Surg (Br)*.1992; 74: 340-44.
24. **Green S, Moore T, Proano F.** Bipolar prosthetic replacement for the management of unstable intertrochanteric hip fractures in the elderly. *Clin Orthop*. 1987; 224: 169-77.
25. **Schatzker J.** Subcapital and intertrochanteric fractures. Schatzker J, Tile M (Eds): *The rationale of operative fracture care* (IInd ed) Springer: Berlin. 1996:340.