

## C-Orthodontic Microimplant for Distalization of Mandibular Dentition in Class III Correction

Kyurhim Chung, DMD, MS, PhD<sup>a</sup>; Seong-Hun Kim, DMD, MS<sup>b</sup>; Yoonah Kook, DMD, MS, PhD<sup>c</sup>

**Abstract:** A 16-year-old male patient with a Class III malocclusion and 2 lower missing central incisors presented for treatment. The treatment plan consisted of asymmetrically distalizing the lower dentition and regaining space for lower anterior prosthetic work. C-implants were to be used as anchorage for Class III intermaxillary elastics, and two C-orthodontic microimplants (C-implants) were placed in the interdental spaces between the upper second premolars and first molars. The particular design of the C-implant head minimized gingival irritation during the orthodontic treatment. Sliding jigs were applied on the buccal for distalization of the lower posterior teeth. The correct overbite and overjet were obtained by distalizing the entire lower dentition into its proper position with C-implant anchorage, which contributed to an improvement in facial balance. It took 15 months to treat this case. The application of this new microimplant, considerations for case selection, and the sequence of treatment are presented. (*Angle Orthod* 2004;75:119–128.)

**Key Words:** Skeletal anchorage, Molar distalization, Class III malocclusion, C-implant, Intermaxillary elastics

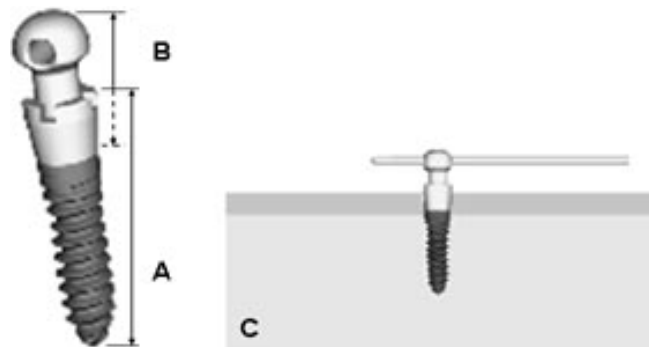
### INTRODUCTION

A Class III malocclusion is defined as an abnormal relationship of the arches where all the lower teeth occlude mesial to normal, with the cusp of the upper second premolar in the sulcus between the mesiobuccal and middle buccal cusps of the lower first molar.<sup>1</sup> The arrangement of teeth may vary from even alignment to crowding and overlapping, especially in the upper arch. Because Class III malocclusion is not a single diagnostic entity, numerous treatment protocols have been advocated. These treatment protocols include a variety of fixed appliances, face mask and arch expansion appliances, functional jaw orthopedic appliances, chin cups, and surgery.<sup>2–6</sup>

Class III elastics are often used in fixed orthodontic treatment to correct the anteroposterior relations of the occlusion.<sup>7</sup> Class III elastics, however, effectively move teeth in

all 3 planes of space, not just in an anteroposterior direction. Vertical extrusion is a prominent part of the tooth movement, whether or not it is desired. It is hard to apply eccentric forces and to correct midline discrepancies and an interarch relationship simultaneously with only intermaxillary elastics during conventional orthodontic treatment.

In addition to retracting the lower teeth and proclining the uppers incisors, Class III elastics elongate the lower incisors and upper molars. These vertical changes rotate the occlusal plane down posteriorly and up anteriorly. These elastics also can cause transverse changes that tend to widen the molars and roll their crowns lingually. Proclining the upper incisors and extruding the upper molars increases the facial height of the patient. Increasing the lower anterior



**FIGURE 1.** C-orthodontic microimplant (C-implant): (A) screw part, (B) head part, (C) diagram of placed C-implant.

<sup>a</sup> Director, Korea Society of Speedy Orthodontics, Seoul, South Korea.

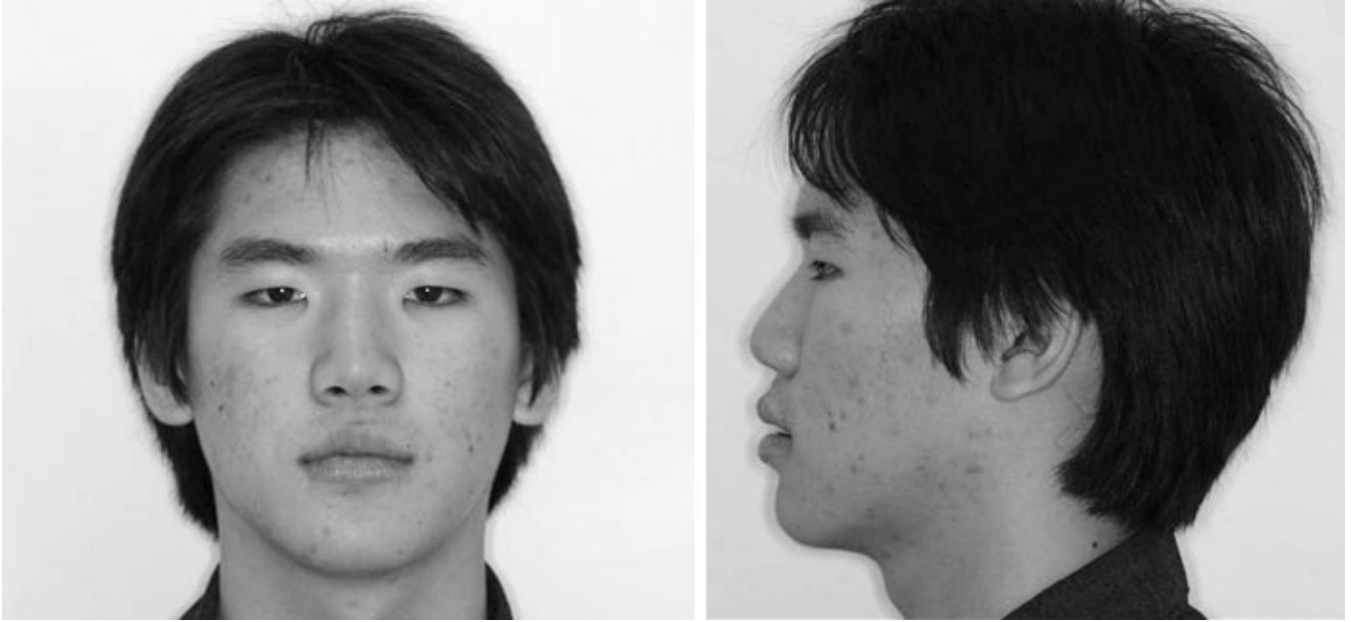
<sup>b</sup> Instructor, Department of Orthodontics, The Catholic University Korea, Uijongbu, South Korea.

<sup>c</sup> Chairman, Department of Orthodontics, The Catholic University of Korea, Seoul, South Korea.

Corresponding author: Seong-Hun Kim, DMD, MS, Department of Orthodontics, The Catholic University Korea, Uijongbu St Mary's Hospital, 65-1 Kumoh-dong Uijongbu Kyonggi-do, 480-130 South Korea (e-mail: bravortho@catholic.ac.kr).

Accepted: February 2004. Submitted: January 2004.

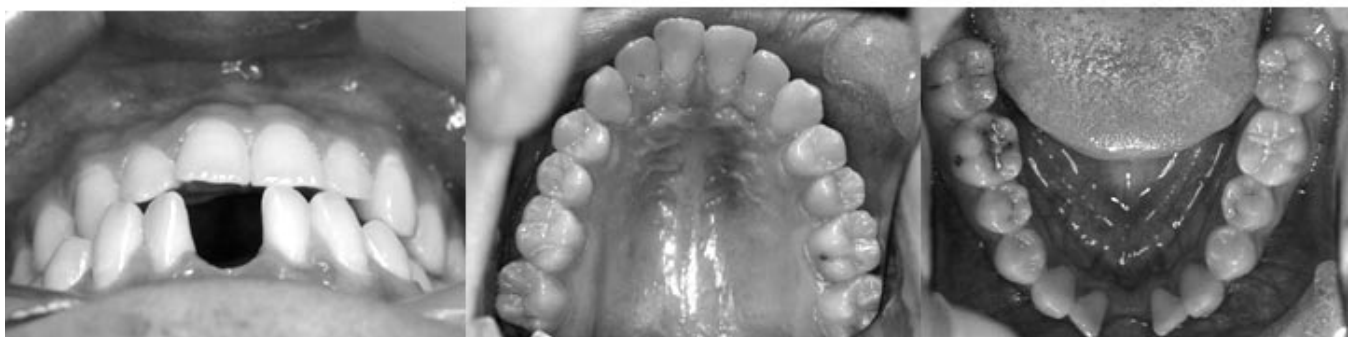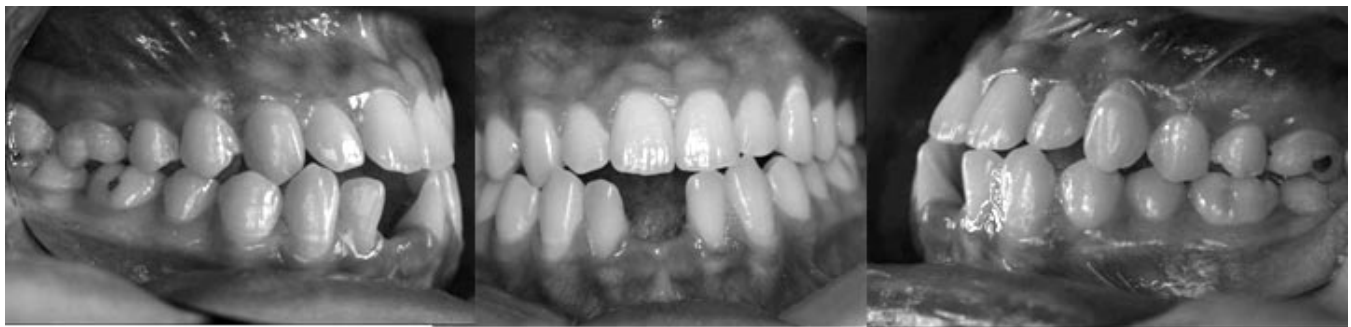© 2004 by The EH Angle Education and Research Foundation, Inc.



**FIGURE 2.** Pretreatment extraoral photographs.

facial height by extrusion of molars may not always be a stable situation in adult patients. In some cases, which show a long anterior facial height and shallow overbite, such reactions to Class III elastics as extrusion of upper molars

and proclination of the upper dentition should be prevented or minimized. To prevent these unwanted changes, absolute anchorage can be applied to the upper molar area to use as a hook for Class III elastics.



**FIGURE 3.** Pretreatment intraoral photographs.

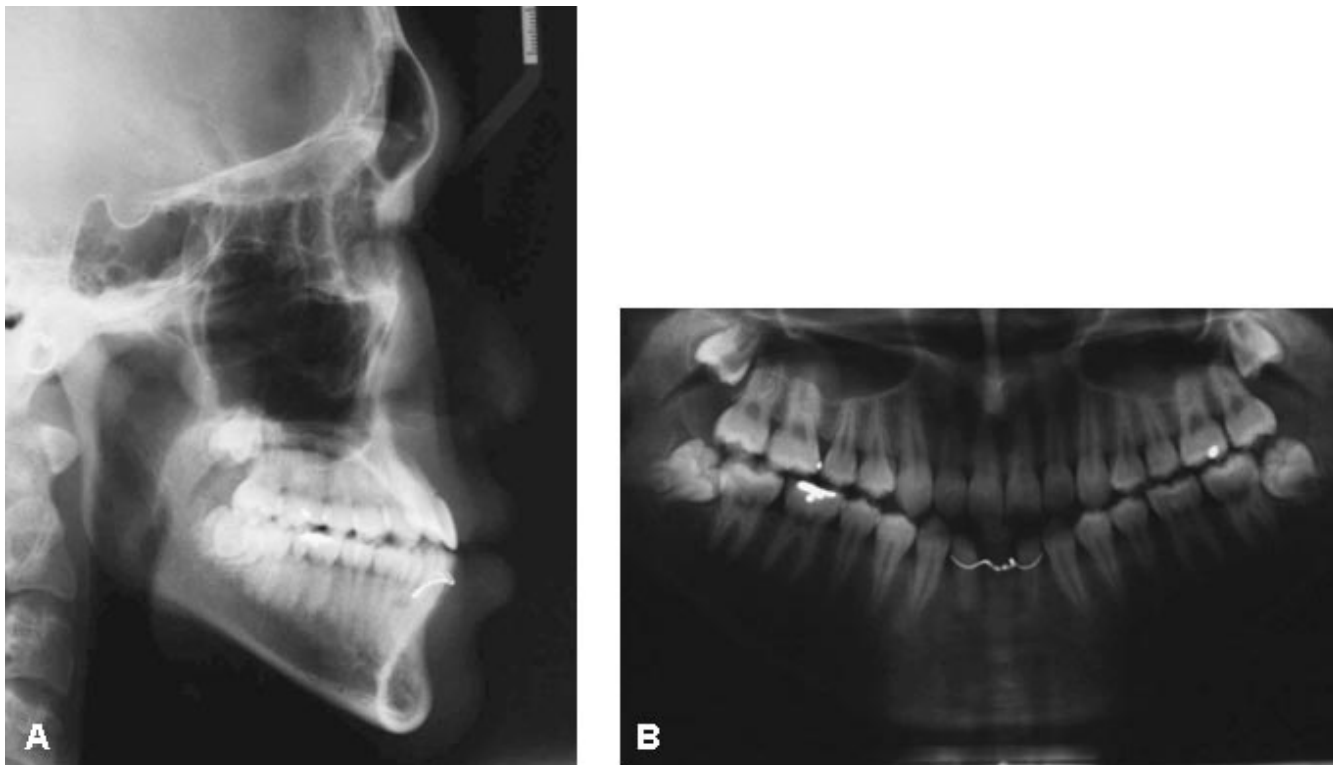

FIGURE 4. Pretreatment cephalometric and panoramic radiographs.

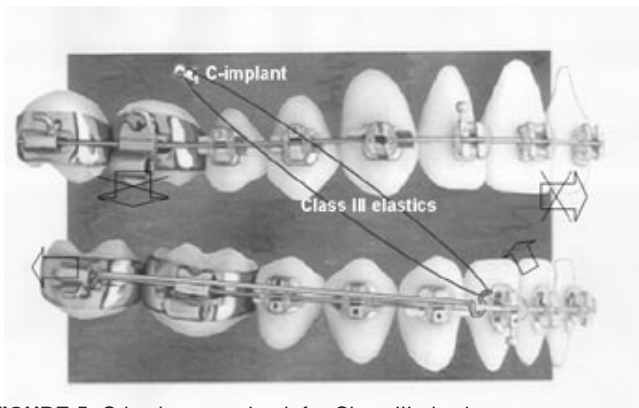


FIGURE 5. C-implant as a hook for Class III elastics.

**The C-orthodontic microimplant as an absolute anchorage**

Numerous skeletal anchorage systems have their particular design (K. R. Chung, S. H. Kim, Y. A. Kook, personal communication).<sup>8-15</sup> The shape of the upper part of the microimplant is especially important for the clinician to apply various types of orthodontic treatment. However, conventional orthodontic miniscrews are not adequate for the use of intermaxillary elastics when compared with orthodontic tubes. To overcome the limitations of conventional skeletal anchorage, we have developed a new type of absolute anchorage system named the C-orthodontic microimplant (C-implant: Dentium Inc, Seoul, Korea).<sup>14,15</sup> The C-implant can be used as an independent orthodontic treatment system in

itself as well as an auxiliary to conventional orthodontic mechanics. The 2-component system of the C-implant (screw part and head part) prevents the fracture of the neck area of the fixture during implantation and removal. Also, the long span between head part and screw body prevents gingival irritation during retraction (Figure 1). The screw part has a 1.8-mm diameter and 8.5-, 9.5-, or 10.5-mm length. The surface except for the upper 2 mm is sandblasted, large-grit, and acid etched. The head part has 2.5-mm diameter and comes in 3 heights: 5.35, 6.35, or 7.35 mm. The distances between the hole of head and screw are 1, 2, or 3 mm, respectively. The diameter of the hole is 0.8 mm.

In this case report, we will document a new approach to treatment for a Class III malocclusion using C-implant-controlled mechanics. The clinical and radiographic changes will be described.

**CASE REPORT**

**Pretreatment evaluation**

A 16-year-old-male presented with the chief complaint of missing lower anterior teeth, lower anterior protrusion, and eagerness for an attractive smile. He had a history of missing lower central incisors because of a traffic accident at 7 years of age. No space maintainer was used during growth. The extraoral examination revealed the facial characteristics of a mild Class III lower anterior protrusion patient with a deep labiamental sulcus and a prominent and

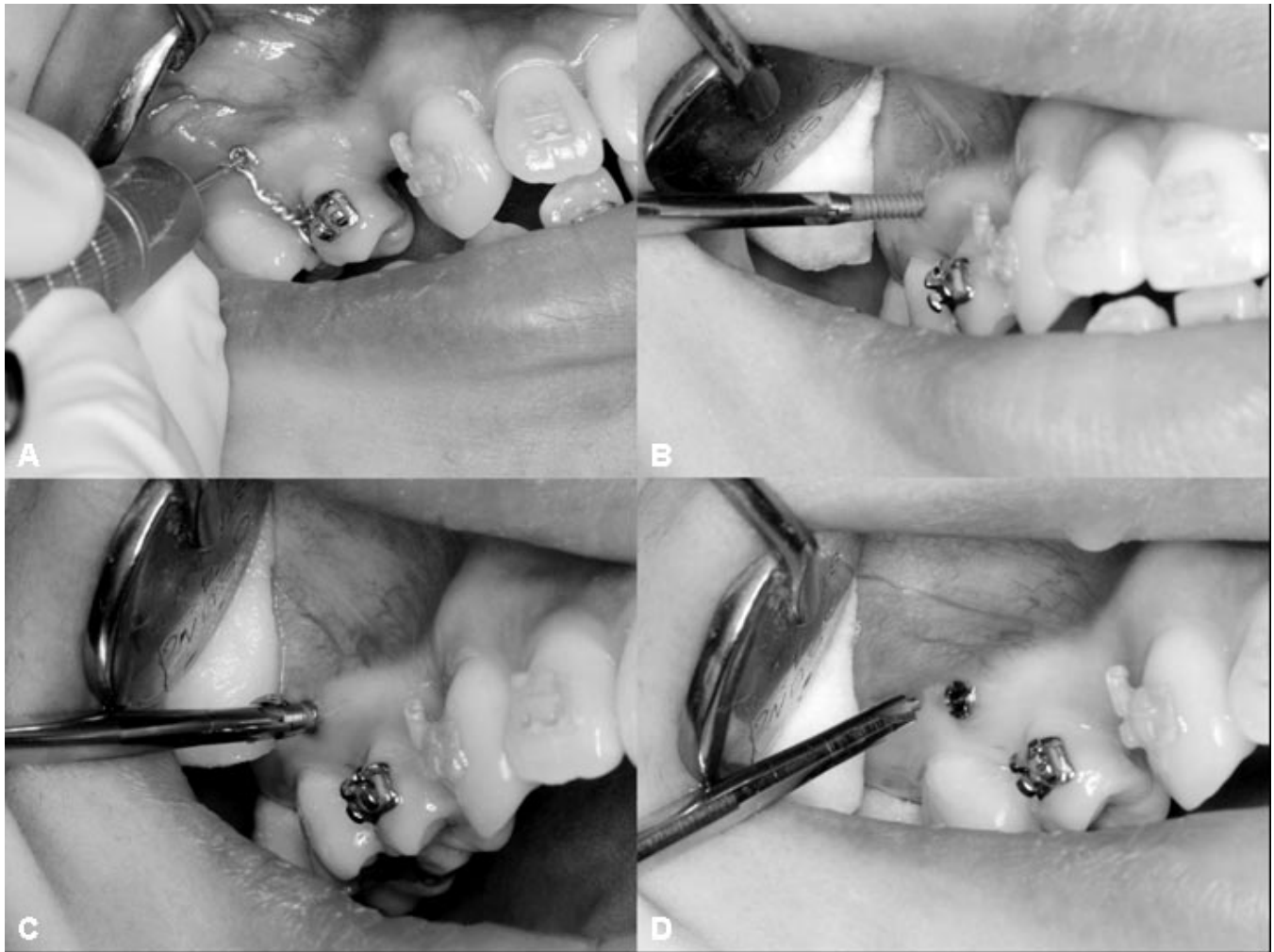


FIGURE 6. C-implant application procedure: screw part.

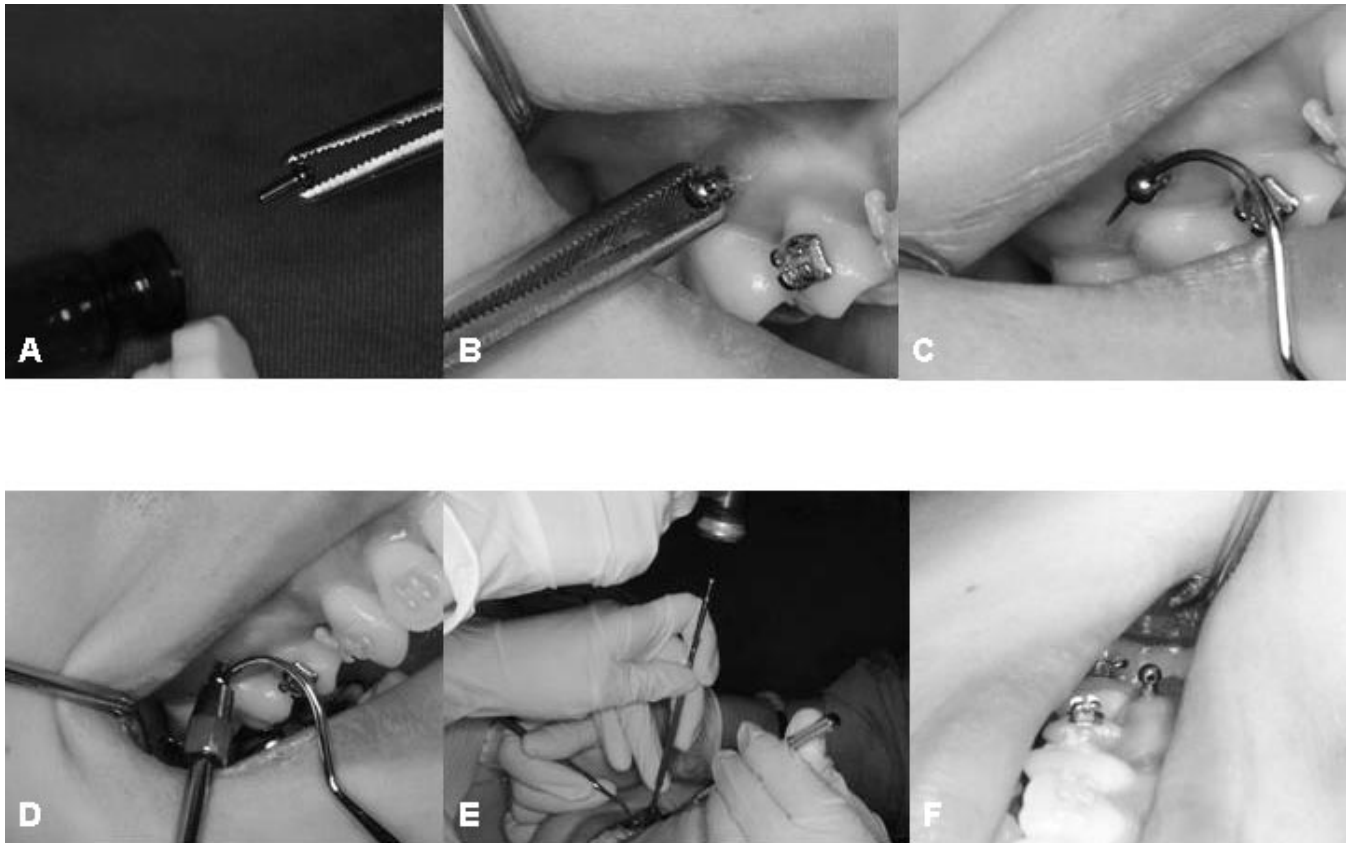
TABLE 1. Cephalometric Survey<sup>a</sup>

	Average (Male)	Pretreatment	Posttreatment
SNA (°)	82	82	82.5
SNB (°)	80	83	83
ANB (°)	2	-1	-0.5
PFH/AFH (%)	95/136 (70%)	91/142 (64.2%)	93/144 (64.6%)
SN-OP (°)	15	11	13
FH-UI (°)	116	125	127
FMA (°)	22	29	30
IMPA (°) Mn 2	<sup>b</sup>	91	83
FMIA (°) Mn 2	<sup>b</sup>	60	67
UL-E plane (mm)	-0.7	0	0.5
LL-E plane (mm)	0.5	3	0.5
Interincisal angle (°)	124	116	121
Mx 1 to NA (mm)	8	10	11
Mx 1 to NA (°)	26	33	37
Mn 2 to NB (mm)	<sup>b</sup>	7	5
Mn 2 to NB (°)	<sup>b</sup>	30	23
SN to PP (°)	9	7	9
Wits appraisal	-2	-9	-5

<sup>a</sup> Supplement Korean Journal of Orthodontics, 1997.

<sup>b</sup> No cephalometric norms for lower lateral incisors.





**FIGURE 7.** C-implant application procedure: head part.

everted lower lip with an increased interlabial gap (Figure 2). The intraoral examination revealed a severe asymmetrical dental Class III malocclusion with an anterior shallow overbite and a negative overjet. There was no occlusal centric relationship discrepancy on closure. Skeletal and dental characteristics showed a slightly prognathic mandible, protruded upper incisors, and procumbent lower incisors. The temporomandibular joint function was normal. The maxillary midline was coincident with the facial midline. However, the mandibular midline did not coincide with the facial midline due to the lost space in the missing lower anterior dentition (Figure 3).

The radiographic examination revealed that the patient had a concave profile with an ANB angle of  $-1.5^\circ$ , a slightly prognathic mandible (SNB angle  $83^\circ$ , SN-Pg angle  $84^\circ$ , and Wits appraisal  $-9$  mm), a high mandibular plane (FMA  $29^\circ$ ), and protrusive upper incisors (interincisal angle  $116^\circ$ , maxillary incisor to NA angle  $33^\circ$ , maxillary incisor to NA distance 10 mm) (Figure 4). The pretreatment panoramic radiograph illustrated excellent periodontal support and the presence of impacted third molars.

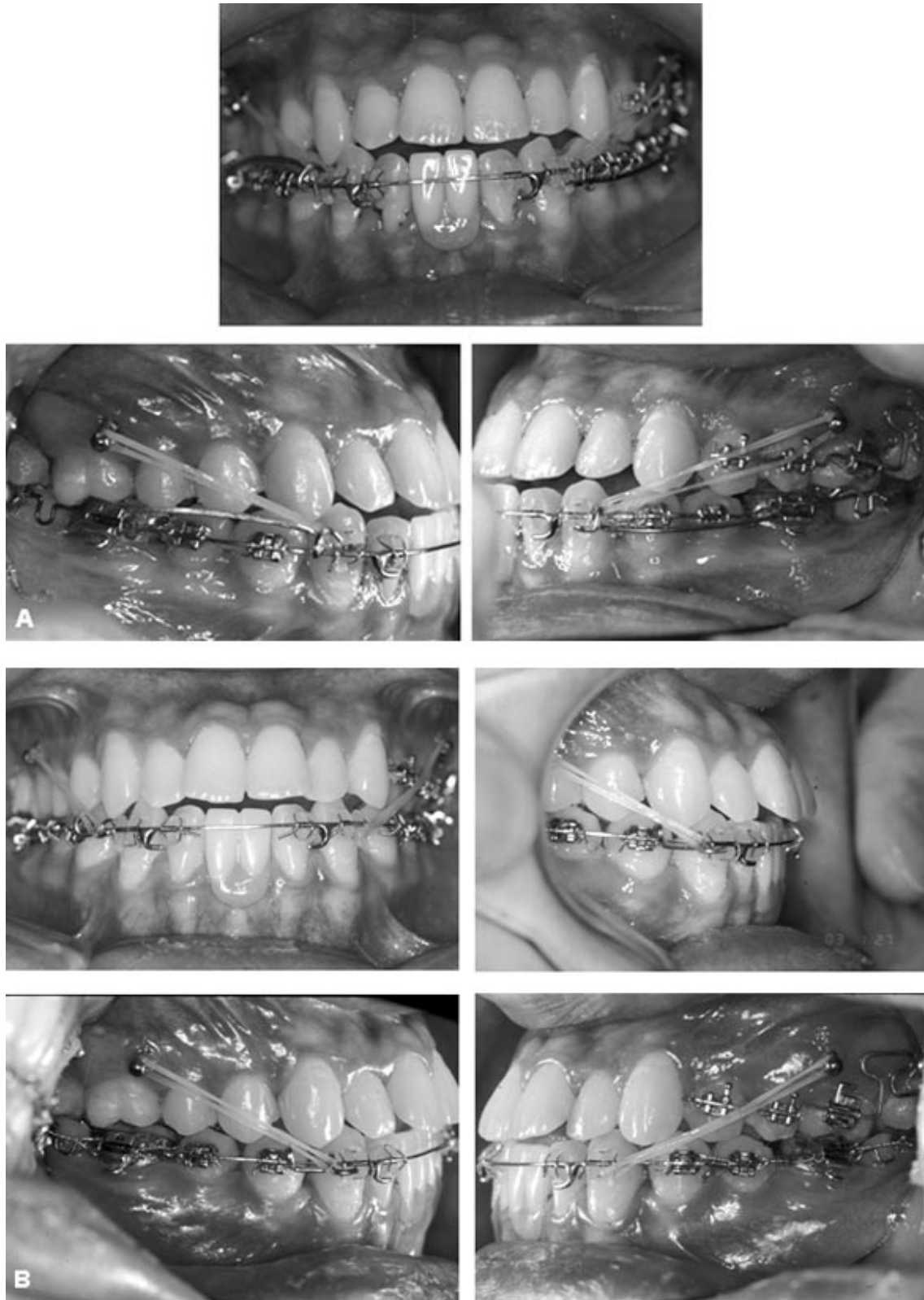
### Treatment plan

The patient requested only conventional orthodontic treatment and did not want his upper front teeth to be pro-

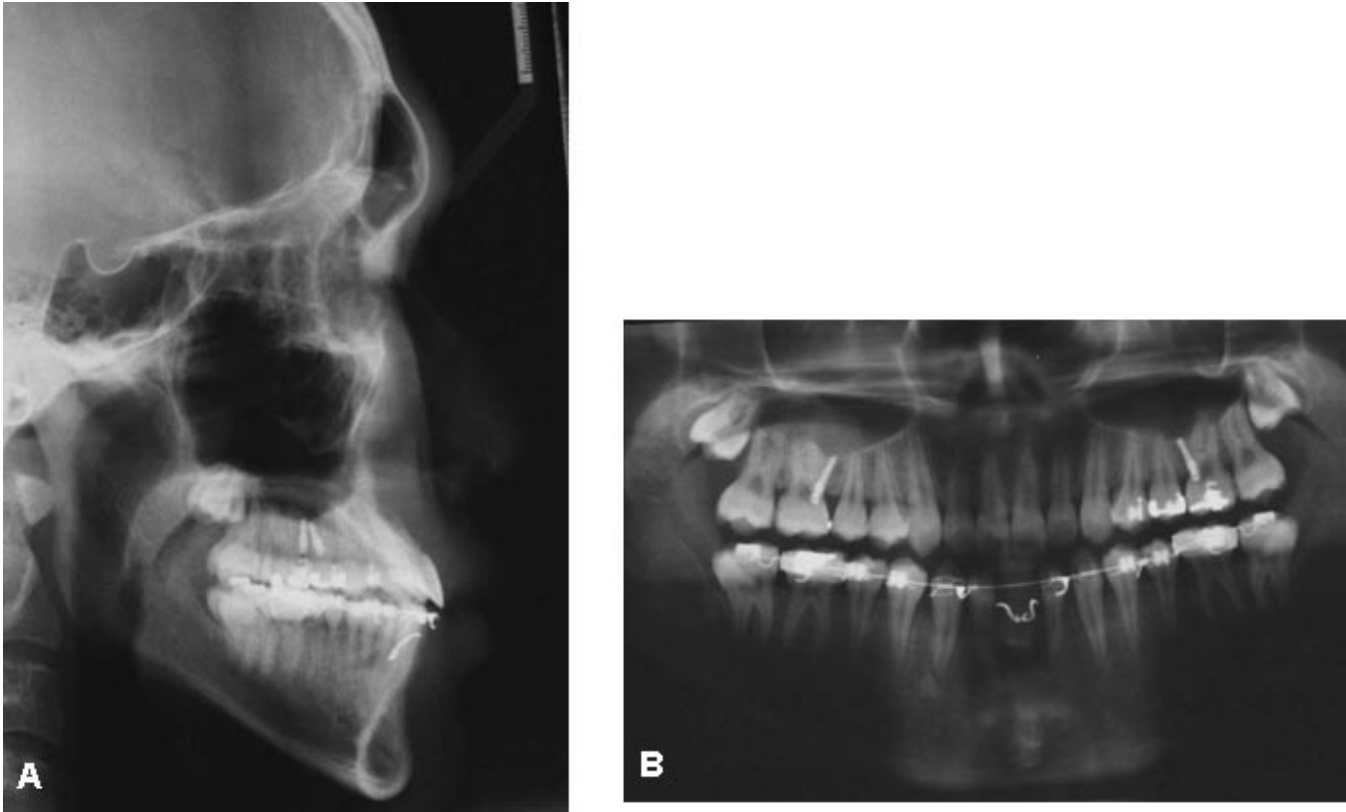truded any further. Based on the results of the cephalometric and study model analyses, the treatment objectives were to establish a Class I molar and canine relationship, create an ideal overjet and overbite, improve the occlusal interdigitation, regain space to allow an esthetic dental restoration of the lower anterior edentulous area, and improve the facial balance. However, en masse retraction of the full lower dentition by conventional orthodontic treatment could cause the reactive extrusion of the upper anchor teeth and upper anterior protrusion with a change in the upper midline. Therefore, the treatment strategy was to place a C-implant in the upper molar area and to apply Class III mechanics between lower dentition and upper C-implant using Class III elastics to correct the Class III molar and canine relationship. The biomechanics of the C-implant as an orthodontic hook is shown in Figure 5.

### Treatment progress

Two C-implants were implanted in the interdental spaces between the upper second premolars and first molars. After incision of the mucosal area, drilling was carried out at 1500 rpm of drill speed and 15 Ncm of drill pressure with profuse irrigation with isotonic saline solution. The 1.5-mm diameter guide drill (Carl Martin, GmbH, Solingen, Germany) was selected when drilling to depth in cortical bone.



**FIGURE 8.** Progress intraoral photographs: (A) during sliding jig treatment and (B) after full distalization of lower dentition.



**FIGURE 9.** After full distalization of lower dentition, cephalometric, and panoramic radiographs.

The screw part was placed clockwise into the prepared site using internal and external sterile saline cooling (Figure 6). After an 8-week healing period, the head part of C-implant was assembled into the screw part by lightly tapping with a small mallet 1 to 2 times. Immediate loading is possible, mainly in areas where dense bone is located and where primary stability can be achieved (Figure 7).

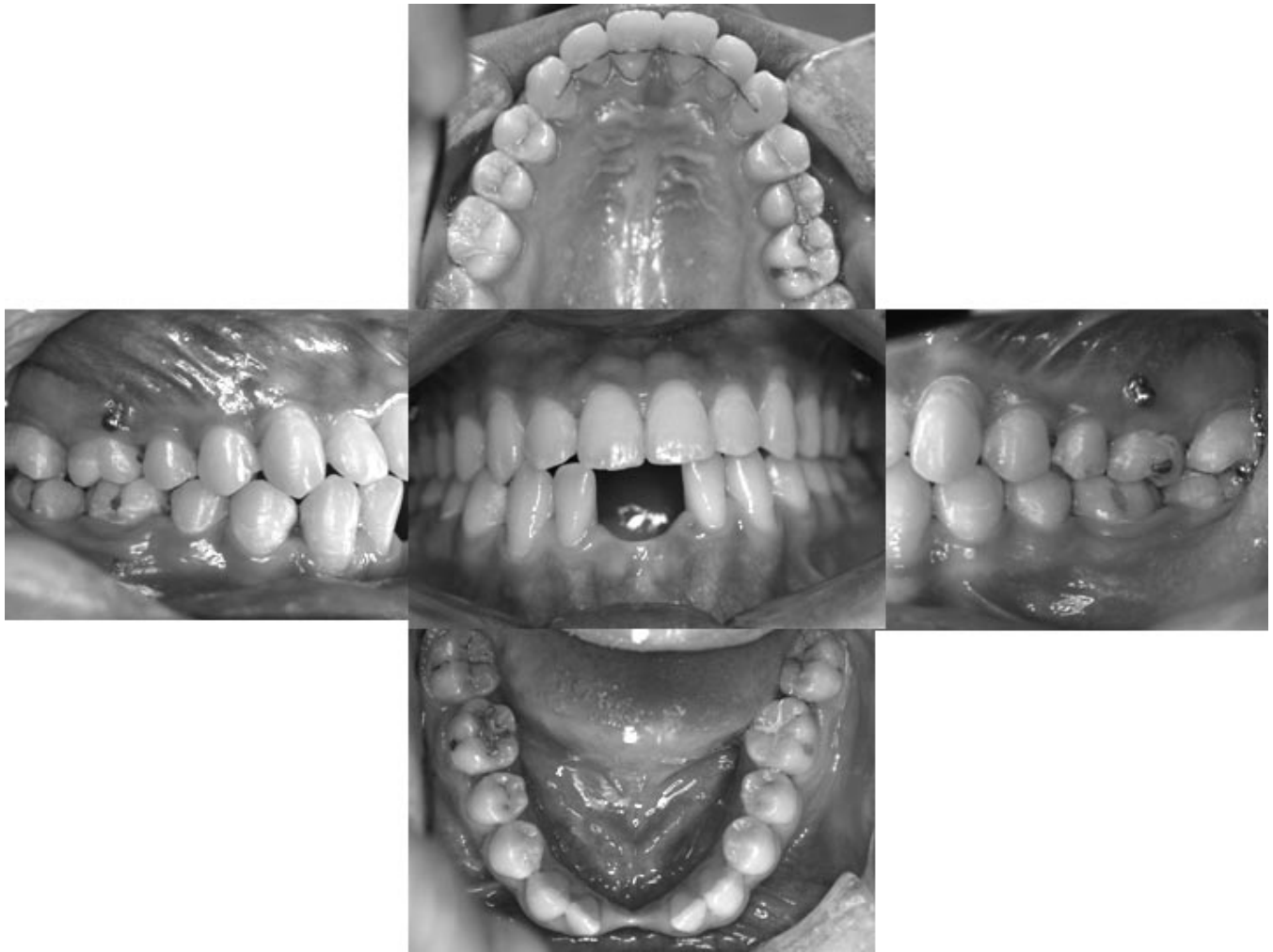
Treatment was initiated with the leveling and distalization of the lower posterior dentition. Because of the patient's dental and skeletal problems, no bonds were placed on the maxillary anterior and right posterior teeth. However, brackets were placed on the upper left posterior teeth, followed by the placement of a segmented 0.022 × 0.028 inch preadjusted arch wire appliance for intrusion of the upper left second molar. The lower third molars were all removed. The patient was instructed to wear Class III elastics as long as possible to move the lower dentition distally. The missing lower anterior space was almost completely regained after 12 months of active tooth movement (Figures 8 and 9). The fixed appliances were removed, and a tooth positioner was used for 1 month for finishing. The retention was provided by an upper fixed retainer and removable lower Hawley retainer.

#### Treatment results and discussion

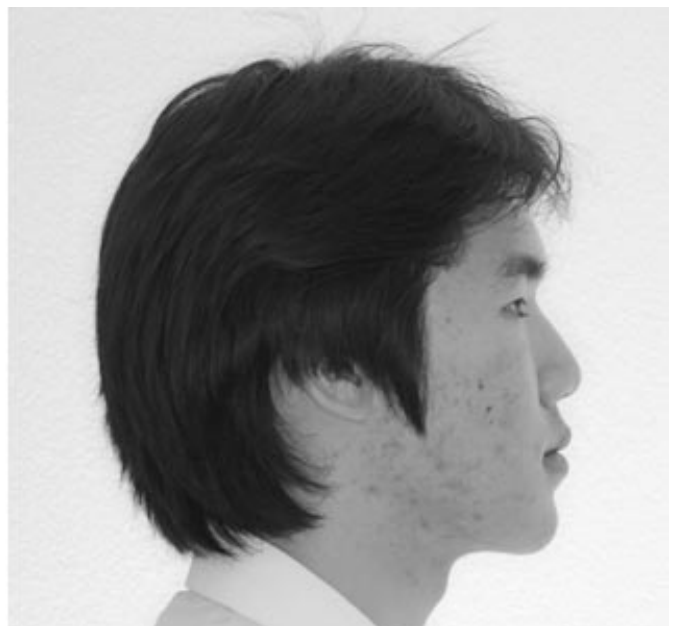

After treatment, a Class I molar and canine relationship with midlines coincident, correct tooth position, and proper

alignment were present. Ideal overjet, overbite, and facial balance were also achieved, and the incisors were not proclined (Figures 10 and 11). The lower dentition was notably distalized 5 mm on the left and 2 mm on the right side. Cephalometric analysis showed a slight downward and backward mandibular movement as well as an asymmetric distalization of the lower dentition (Figures 12 and 13). The FMA changed slightly from 29° to 30°. The backup with the C-implant hook can be assumed not to change the position of the upper molars, which minimized any increased steepness of the mandibular plane. However, the intrusive force on the upper left second molar using a sectional archwire is believed to have caused a slight extrusion of the upper molars.

We should have used the C-implant as an anchorage appliance for intrusion of the upper left second molar simultaneously with lower distal movement. The occlusal plane was not changed significantly after treatment because of extrusion of both the upper and lower posterior teeth during distal movement (SN to OP angle 11° to 13°). The upper incisors were slightly protruded (FH-U1 angle 125°–127°, maxillary incisor to NA distance 10–11 mm, maxillary incisor to NA angle 33°–37°). The lower incisors were uprighted and retracted. In this case, lower lateral incisors were used as the landmarks for deciding the lower incisor position because of the missing lower central incisors (IMPA 91°–83°, FMIA 60°–67°, mandibular incisor to NB

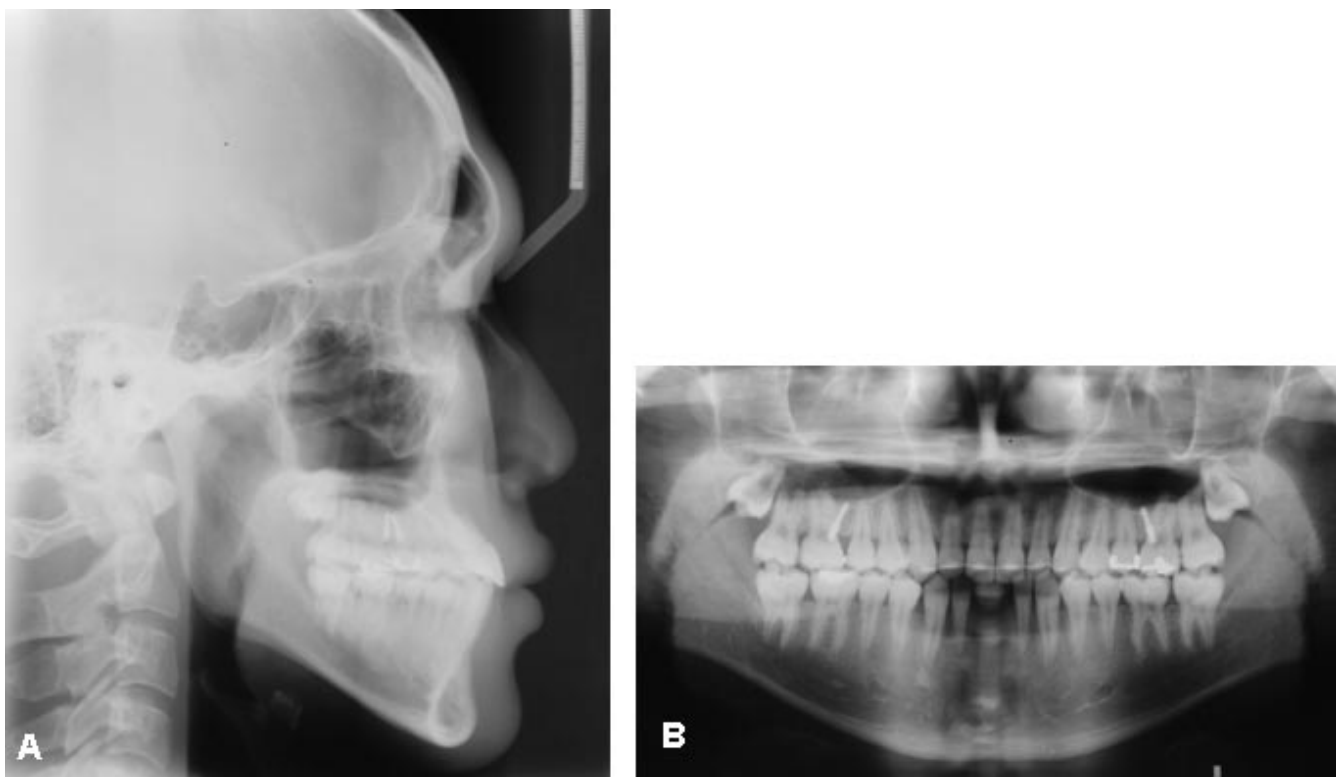


**FIGURE 10.** Posttreatment intraoral photographs.

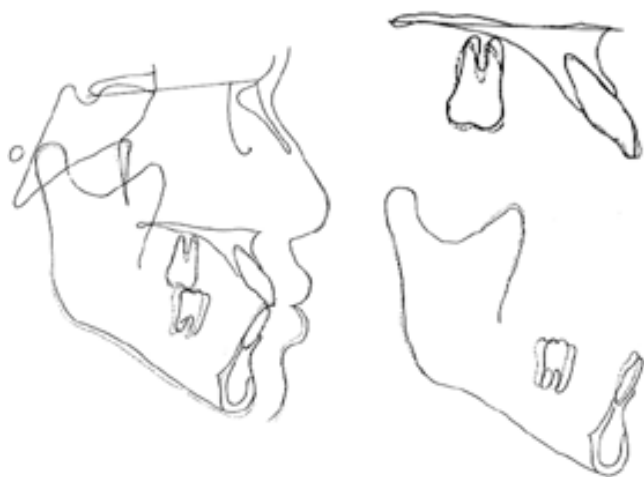

**FIGURE 11.** Posttreatment extraoral photographs.





**FIGURE 12.** Posttreatment cephalometric and panoramic radiographs.



**FIGURE 13.** Superimpositions of lateral cephalograms: pretreatment (solid line) to posttreatment (dotted line).

distance 7 mm to 5 mm, mandibular incisor to NB angle  $30^{\circ}$ – $23^{\circ}$ ) (Table 1). The lips were competent in repose (upper lip to E-plane 0 mm to 0.5 mm, lower lip to E-plane 3 mm to 0.5 mm). The interincisal angle was improved to a normal range ( $116^{\circ}$ – $121^{\circ}$ ). The ANB changed a little during treatment (SNA  $82^{\circ}$ – $82.5^{\circ}$ , SNB  $83^{\circ}$ – $83^{\circ}$ , Wits appraisal  $-9$  mm to  $-5$  mm). The posterior/anterior facial height ratio was slightly increased after treatment (91/142 mm, 64.2% to 93/144 mm, 64.6%).

The entire lower dentition was distalized successfully by

using the C-implant as a hook for elastics. The treatment result was quite acceptable, and the patient was pleased with the final treatment results despite the space for the anterior restoration being slightly deficient.

Even though the use of the conventional prosthetic implant as orthodontic anchorage has expanded, the biomechanical and clinical scope of orthodontics, the large size, location, complication of surgery, long osseointegration period, and high cost have limited its orthodontic application.<sup>16–23</sup>

On the contrary, the small size, 2-part design, efficiency, possibility of immediate or early loading, and inexpensiveness of C-implant make it useful in various orthodontic cases. There are several advantages of the C-implant systems as a hook for intermaxillary elastics. Compared with conventional orthodontic miniscrews, it is possible to place various kinds of elastics on the C-implant. The round head part with the 0.8-mm-diameter round hole of the C-implant allows the patient to apply elastics easily without gingival irritation. The head part of the C-implant can be simply disassembled from the screw part by twisting.

Lee and Chung<sup>24</sup> demonstrated the effect of early loading on the osseointegration of the prototype of the C-implant in animal experiments. They showed that there was no difference between immediately loaded implants and unloaded implants. The premature loading after a 4-week healing period did not halt the progress of the osseointegration between bone and implant surface.

## CONCLUSIONS

Absolute anchorage can be used as a hook for intermaxillary elastics in cases where extrusion of anchor teeth is to be avoided. The C-implant can create absolute anchorage and a wide spectrum of clinical applications because of its particular design. In this article, the timing of implantation, sequencing of treatment, and method of establishing the proper force application of the C-implant were described. Further research and studies on C-implant mechanics are required to establish the timing of orthodontic or orthopedic force, to combine it with various orthodontic treatment mechanics, and to determine the guidelines for treating adult patients with systemic complications.

## ACKNOWLEDGMENT

We would like to thank Mr. Hyewoong Kim of the Department of Orthodontics at Kyunghee University Dental Hospital for his expert technical assistance in the preparation of this manuscript.

## REFERENCES

- Bishara SE. Orthodontic diagnosis and treatment planning. In: Bishara SE, ed. *Textbook of Orthodontics*. Philadelphia, Pa: WB Saunders Co; 2001:98–112.
- Fränkel R. Maxillary retrusion in Class III and treatment with the functional corrector III. *Trans Eur Orthod Soc*. 1970;46:249–259.
- Turley P. Orthopedic correction of Class III malocclusion with palatal expansion and custom protraction headgear. *J Clin Orthod*. 1988;22:314–325.
- Kim YH. Anterior openbite and its treatment with multiloop edgewise archwire. *Angle Orthod*. 1987;57:290–321.
- Graber LW. Chin cup therapy for mandibular prognathism. *Am J Orthod*. 1977;72:23–41.
- Epker BN, Stella JP, Fish LC. Section III: Class III dentofacial deformities. In: Epker BN, Stella JP, Fish LC, eds. *Dentofacial Deformities: Integrated Orthodontic and Surgical Correction*. St Louis, Mo: Mosby; 1996:574–1014.
- Proffit WR. Interarch elastics: their place in modern orthodontics. In: Hösl E, Baldauf A, eds. *Mechanical and Biological Basics in Orthodontic Therapy*. Germany: Hüthig; 1991:173–178.
- Umemori M, Sugawara J, Mitani H, Nagasaka H, Kawamura H. Skeletal anchorage system for open-bite correction. *Am J Orthod Dentofacial Orthop*. 1999;115:166–174.
- Costa A, Raffaini M, Melsen B. Microscrews as orthodontic anchorage: a preliminary report. *Int J Adult Orthod Orthognath Surg*. 1998;13:201–209.
- Kanomi R. Mini-implant for orthodontic anchorage. *J Clin Orthod*. 1997;31:763–767.
- Park HS, Bae SM, Kyung HM, Sung JH. Micro-implant anchorage for lingual treatment of a skeletal Class II malocclusion. *J Clin Orthod*. 2001;35:643–647.
- Kyung HM, Park HS, Bae SM, Sung JH, Kim IB. Development of orthodontic micro-implants for intraoral anchorage. *J Clin Orthod*. 2003;37:321–328.
- Maino BG, Bender J, Pagin P, Mura P. The spider screw for skeletal anchorage. *J Clin Orthod*. 2003;37:90–97.
- Chung KR, Kim YS, Linton JL, Lee YJ. The miniplate with tube for skeletal anchorage. *J Clin Orthod*. 2002;36:407–412.
- Chung KR. C-implant. In: Chung KR, ed. *Text Book of Speedy Orthodontics*. Seoul, South Korea: Jeeseung; 2001:99–113.
- Brånemark PI. Osseointegration and its experimental background. *J Prosthet Dent*. 1983;50:399–410.
- Arbuckle GR, Nelson CL, Roberts WE. Osseointegrated implants and orthodontics. *Oral Maxillofac Surg Clin North Am*. 1991;3:903–919.
- Roberts W, Smith RK, Zilberman Y, Mozsary PG, Smith RS. Osseous adaptation to continuous loading of rigid endosseous implants. *Am J Orthod*. 1984;86:95–111.
- Wehrbein H, Diedrich P. Endosseous titanium implants during and after orthodontic load—an experimental study in the dog. *Clin Oral Impl Res*. 1993;4:76–82.
- Odman J, Lekholm U, Jemt T, Thilander B. Osseointegrated implants as orthodontic anchorage in the treatment of partially edentulous adult patients. *Eur J Orthod*. 1994;16:187–201.
- Roberts WE, Nelson CL, Goodacre CJ. Rigid implant anchorage to close a mandibular first molar extraction site. *J Clin Orthod*. 1994;28:693–704.
- Romanos G, Toh CG, Siar CH, Swaminathan D, Ong AH, Donath K, Yaacob H, Nentwig GH. Peri-implant bone reactions to immediately loaded implants: an experimental study in monkeys. *J Periodontol*. 2001;72:506–511.
- Gapski R, Wang HL, Mascarenhas P, Lang NP. Critical review of immediate loading. *Clin Oral Implants Res*. 2003;14:515–527.
- Lee SJ, Chung KR. The effect of early loading on the direct bone-to-implant surface contact of the orthodontic osseointegrated titanium implant. *Korean J Orthod*. 2001;31:173–185.