

## Maxillary Canine Transposition to Incisor Site: A Rare Condition

Hakan Türkkahraman, DDS, PhD<sup>a</sup>; M. Özgür Sayın, DDS, PhD<sup>a</sup>; H. Hüseyin Yılmaz, DDS, PhD<sup>b</sup>

**Abstract:** Tooth transposition is defined as positional interchange of 2 adjacent teeth within the same quadrant. The incidence has been reported as about 0.4%, and the maxillary permanent canine has been reported as the tooth most frequently involved. Several etiologic factors like genetics, interchange in position of the developing tooth buds, trauma, mechanical interferences, and early loss of incisors have been associated with tooth transposition. Articles in the literature report various kinds of transpositions, but there are only a few reported cases of transposition of the maxillary canine to central incisor site. This kind of transposition has been suggested as resulting primarily by opportunistic canine migration into the space left from an early lost central incisor. However, there are only 2 long-term roentgenographic follow-up studies documenting maxillary canine migration and substantiating this hypothesis. This report shows 2 cases of this rare condition, with 1 of them documented with long-term records. (*Angle Orthod* 2005; 75:284–287.)

**Key Words:** Ectopic eruption, Maxillary canine, Tooth transposition

### INTRODUCTION

Tooth transposition is defined as the positional interchange of 2 adjacent teeth within the same quadrant.<sup>1–5</sup> It is identified as complete transposition when the crowns and the roots of the involved teeth exchange places in the dental arch and as incomplete transposition when the crowns are transposed but the roots remain in their normal positions.<sup>1</sup> The incidence has been reported as about 0.4%.<sup>6</sup> Tooth transpositions occur more commonly in the maxilla than the mandible,<sup>6,7</sup> and the maxillary permanent canine has been reported as the tooth most frequently involved in transposition.<sup>6,8</sup>

Tooth transpositions are more commonly observed in females<sup>2–4,7–9</sup> and may occur unilaterally or bilaterally.<sup>10</sup> A greater frequency of left-side occurrence in unilateral transposition cases were also reported.<sup>2,3,6–8,11</sup> Other dental anomalies like peg-shaped or congenitally missing upper lateral incisors, retention of deciduous canines, malpositioned ad-

jacent teeth, and rotations frequently accompany tooth transpositions.<sup>2,4,6–9</sup>

Several etiologic factors like genetics,<sup>2,4,6,12,13</sup> interchange in the position of the developing tooth buds,<sup>11,14</sup> trauma,<sup>3,10,15,16</sup> mechanical interferences,<sup>2,8,9,11</sup> and early loss of incisors<sup>3,16,17</sup> have been associated with tooth transposition.

In the literature, 6 types of transpositions were clearly identified.<sup>3,4,18</sup> These are:

1. Maxillary canine-first premolar (Mx.C.P1).
2. Maxillary canine-lateral incisor (Mx.C.I2).
3. Maxillary canine to first molar site (Mx.C to M1).
4. Maxillary lateral incisor-central incisor (Mx.I2.I1).
5. Maxillary canine to central incisor site (Mx.C to I1).
6. Mandibular lateral incisor-canine (Mn.I2.C) transpositions.

Articles reporting various kinds of transpositions existed in the literature, but there are only a few reported cases of transposition of the maxillary canine to the central incisor site.<sup>10,16,17,19,20</sup> The Mx.C to I1 transposition has been hypothesized to result primarily from an opportunistic canine migration to an early lost central incisor area.<sup>3</sup> But there are only 2 long-term roentgenographic follow-up studies<sup>10,16</sup> documenting maxillary canine migration, which substantiate this hypothesis. This report shows 2 cases of this rare condition, 1 of them with long-term records.

### CASE REPORTS

#### Case 1

The patient HÖ, a 10-year- 6-month-old girl, was referred to the Orthodontic Department for orthodontic eval-

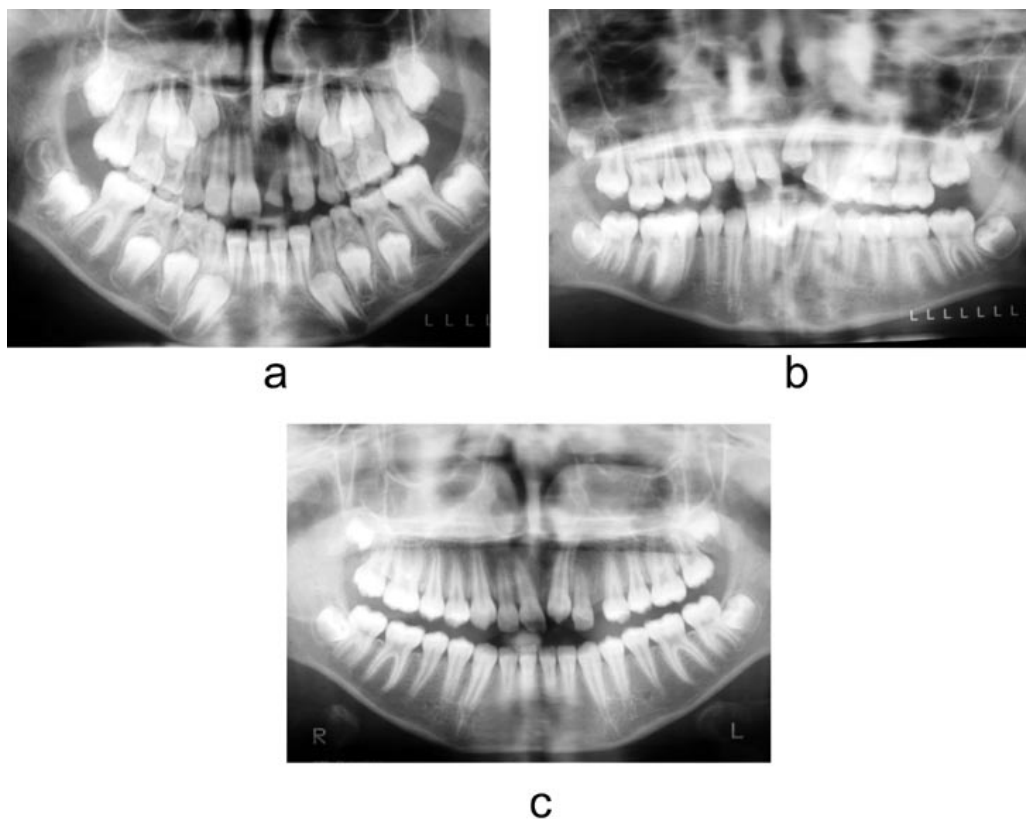
<sup>a</sup> Assistant Professor, Department of Orthodontics, Faculty of Dentistry, University of Suleyman Demirel, Isparta, Turkey.

<sup>b</sup> Assistant Professor, Department of Oral Diagnosis and Radiology, Faculty of Dentistry, University of Suleyman Demirel, Isparta, Turkey.

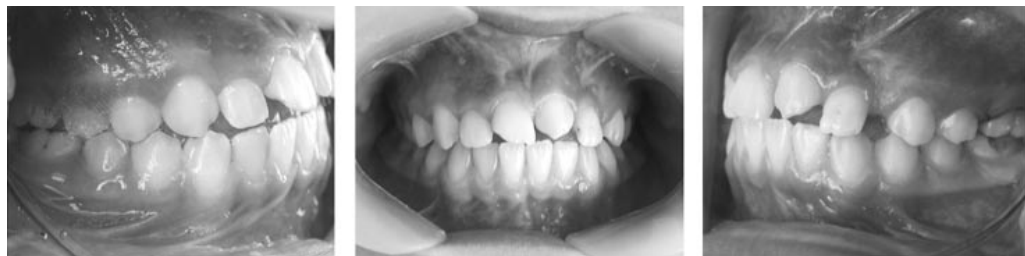Corresponding author: Hakan Türkkahraman, DDS, PhD, Department of Orthodontics, Faculty of Dentistry, University of Suleyman Demirel, 32260 Cunur, Isparta, Turkey (e-mail: kahraman@med.sdu.edu.tr).

Accepted: January 2004. Submitted: March 2004.

© 2005 by The EH Angle Education and Research Foundation, Inc.



**FIGURE 1.** Panoramic radiographs of HÖ at (a) 7 years 6 months of age, (b) 10 years of age, and (c) 10 years 6 months of age.



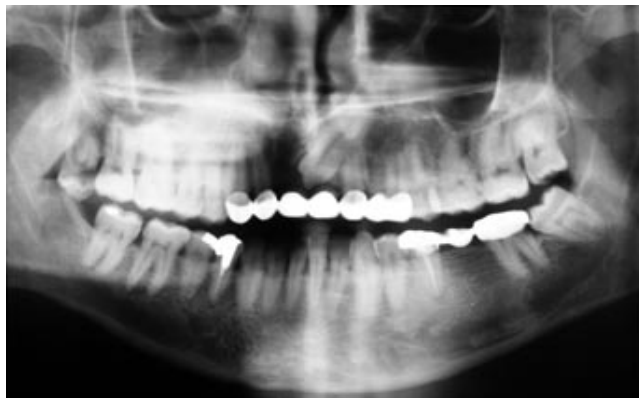
**FIGURE 2.** Intraoral views of HÖ.

uation. According to her parents, the patient had an alveolar trauma when she was about 1.5 years old. This trauma induced widening of the diastema between the maxillary primary central incisors. When she was 7 years 6 months old, the patient and her parents were referred to an orthodontist with a chief complaint of delayed eruption of one of the permanent central incisors. Extraoral radiographs (Figure 1a) showed impaction of the maxillary left central incisor and a retained maxillary primary left central incisor. The impacted maxillary left central incisor was surgically removed.

At 10 years of age, another panoramic radiograph was obtained (Figure 1b) in the Social Insurance Hospital, and the patient was referred to an orthodontic department. Six months later, patient HÖ was referred to the Orthodontic Department of Suleyman Demirel University. Extraoral and

intraoral photographs and radiographs, dental casts, and a detailed medical and dental history were obtained. The extraoral radiographs showed the absence of the maxillary left central incisor and a fully erupted maxillary left canine to its place (Figure 1c). The root of the maxillary right second premolar was dilacerated. All third molar germs were present.

A clinical examination revealed Angle Class I occlusion with 3 mm of overjet and 1.5 mm of overbite (Figure 2). Interestingly, the position of the canine was normal in the first records (Figure 1a). Two and a half years later, after removal of the central incisor, the canine changed its path and began to erupt to central incisor site (Figure 1b). The latest records show a fully erupted canine in the central incisor area (Figure 1c). The patient had no severe orthodontic malocclusion, but reshaping of the incisal surfaces



**FIGURE 3.** Panoramic radiograph of AA showing mesially migrated and impacted maxillary left canine.

with composite materials and an additional periodontal gingival recontouring procedure<sup>21</sup> was indicated for recovery of optimal anterior esthetics.

### Case 2

The patient, AA, a 44-year-old man, was referred to the Oral Diagnosis and Radiology Department for prosthetic replacement. Extraoral radiographs showed an absence of both maxillary central incisors and ectopic eruption of the maxillary left canine into the incisor area (Figure 3). In the medical history, the patient mentioned an early loss of a central incisor because of mobility when he was 20 years old. No trauma history was noted. Clinical examination revealed a Class III skeletal pattern with a prognathic mandible and anterior teeth in an endon occlusion. Surgical removal of the impacted canine and prosthetic replacement were planned, but the patient refused any surgical operation.

### DISCUSSION

The maxillary canine is the tooth that is most frequently involved in transpositions. Shapira and Kuflinec<sup>1</sup> explained this high incidence with the canine's longest period of development and longest way of eruption. The mechanism that causes ectopic eruption is still obscure. But localized pathologic processes,<sup>22</sup> trauma,<sup>3,10,16</sup> and mechanical interferences<sup>1,2,8,9,11</sup> are reported to cause ectopic eruption and transposition.

Retained deciduous canines were suggested as a cause for extreme ectopic eruption of the maxillary canines into the incisor, second premolar, or first molar area.<sup>8</sup> However, according to Peck et al,<sup>2</sup> a retained deciduous tooth is a consequence of the anomaly, not its cause.

A greater frequency of left-side occurrence in unilateral transposition cases has been reported.<sup>2,3,6-8,11</sup> In both the cases in this study, transposition also occurred in the left side. However, if maxillary canine to incisor site transpositions are strongly related to early loss of the central incisor and

laterality or sidedness is more likely to occur in genetically controlled anomalies, it would appear more logical to disregard side dominance in this kind of transposition.

Peck and Peck<sup>3</sup> examined 77 publications reporting 201 people with maxillary tooth transpositions from worldwide sources. Only 4 cases (2%) had canine to central incisor site transposition. Shapira and Kuflinec<sup>8</sup> suggested that maxillary canine to central incisor site transpositions should be classified as ectopic eruptions. This variation has been also described as a canine-lateral incisor transposition.<sup>16,20</sup> However, Peck and Peck<sup>3</sup> found this erroneous because the lateral incisors had not shifted distally in these cases. Regardless of what the phenomenon is called, this kind of transposition is a rare condition. In these reports, migration of the canine to incisor area was related to an early loss of a central incisor.

Curran and Baker<sup>17</sup> reported a case with bilateral transposition of the maxillary canines to the central incisor area. Although the dental history of the patient was vague, the patient was sure that some teeth that were protruding labially had been removed from the central incisor area when she was 10 years old.

Gholston and Williams<sup>16</sup> reported another bilateral transposition of the maxillary canines to the incisor area. The patient's medical history included 2 significant incidents of trauma where the upper central incisors of the patient were avulsed. Later, the maxillary canines ectopically erupted into the central incisor area. The authors suggested that the missing central incisors had facilitated the bilateral transposition of the canines.

Weeks and Power<sup>10</sup> reported a case with transposed maxillary central and lateral incisors. A supernumerary tooth in the upper incisor region caused displacement of these teeth distally. After the removal of the supernumerary tooth, the canine migrated mesially and erupted in the site of the central incisor.

Peck and Peck<sup>3</sup> suggested that Mx.C to II transposition is generated primarily by opportunistic canine migration as a byproduct of adventitious tooth loss. Our findings support this suggestion. The first panoramic view of patient HÖ shows normal positioning of the developing canine bud (Figure 1). After the removal of the central incisor, the canine surprisingly began to change its path of eruption (Figure 2). The last records show complete transposition of the maxillary canine to the incisor site (Figure 3). The longitudinal follow-up of the canine eruption provides strong evidence for opportunistic canine migration. Therefore, periodic radiographic monitoring of the maxillary permanent canine after early loss of the central incisor is essential. Interceptive extraction of the maxillary deciduous canine after loss of permanent central incisor may allow the permanent canine to erupt to its normal position, thus preventing its ectopic migration to the central incisor site.<sup>23</sup>

A cause-and-effect dilemma existed in case 2. The incisors might have been lost because of abnormal root resorp-

tion induced by the mesially impacted maxillary canine. Secondly, the opportunistic canine migration might have occurred as a byproduct of incisor tooth loss.

Patient AA failed to provide valuable information or previous radiographic records, so it is unclear whether the loss of incisors is the “cause” or the “effect” of the canine’s ectopic eruption into the incisor site.

Disturbances in permanent tooth eruption may occur after trauma to the deciduous dentition. Panoramic radiographs of HÖ support this suggestion (Figure 1). A trauma at 1.5 years of age caused impaction of maxillary left central incisor. Chaushu et al<sup>24</sup> reported that in 41.3% of the subjects with impacted central incisor, the canine’s path of eruption was deviated. However, in our case, the canine’s position in the first panoramic radiograph seems to be normal (Figure 1), so the main etiologic factor seems to be the extraction of the central incisor, not the impaction of it.

### CONCLUSIONS

The findings of these cases strongly suggest that abnormal eruptive migration of the canines rather than a positional change at the anlage stage causes this kind of transposition. Trauma and early loss of the central incisors can induce ectopic migration of the maxillary canine to central incisor site. Therefore, the maxillary canines should be regularly monitored after early loss of maxillary central incisors.

### REFERENCES

1. Shapira Y, Kuflinec MM. Tooth transpositions—a review of the literature and treatment considerations. *Angle Orthod.* 1989;59:271–276.
2. Peck L, Peck S, Attia Y. Maxillary canine-first premolar transposition, associated dental anomalies and genetic basis. *Angle Orthod.* 1993;63:99–110.
3. Peck S, Peck L. Classification of maxillary tooth transpositions. *Am J Orthod Dentofacial Orthop.* 1995;107:505–517.
4. Peck S, Peck L, Kataja M. Mandibular lateral incisor-canine transposition, concomitant dental anomalies, and genetic control. *Angle Orthod.* 1998;68:455–466.
5. Talbot TQ, Hill AJ. Transposed and impacted maxillary canine with ipsilateral congenitally missing lateral incisor. *Am J Orthod Dentofacial Orthop.* 2002;121:316–323.
6. Chattopadhyay A, Srinivas K. Transposition of teeth and genetic etiology. *Angle Orthod.* 1996;66:147–152.
7. Plunkett DJ, Dysart PS, Kardos TB, Herbison GP. A study of transposed canines in a sample of orthodontic patients. *Br J Orthod.* 1998;25:203–208.
8. Shapira Y, Kuflinec MM. Maxillary tooth transpositions: characteristic features and accompanying dental anomalies. *Am J Orthod Dentofacial Orthop.* 2001;119:127–134.
9. Shapira Y. Transposition of canines. *J Am Dent Assoc.* 1980;100:710–712.
10. Weeks EC, Power SM. The presentations and management of transposed teeth. *Br Dent J.* 1996;181:421–424.
11. Joshi MR, Bhatt NA. Canine transposition. *Oral Surg Oral Med Oral Pathol.* 1971;31:49–54.
12. Allen WA. Bilateral transposition of teeth in two brothers. *Br Dent J.* 1967;123:439–440.
13. Feichtinger CH, Rosswall B, Wunderer H. Canine transposition as autosomal recessive trait in an inbred. *J Dent Res.* 1977;56:1449–1452.
14. Lupton T, Silling G. Canine transposition: approaches to treatment. *J Am Dent Assoc.* 1983;107:746–748.
15. Dayal PK, Shodhan KH, Dave CJ. Transposition of canine with traumatic etiology. *J Ind Dent Assoc.* 1983;55:283–285.
16. Gholston LR, Williams PR. Bilateral transposition of maxillary canines and lateral incisors: a rare condition. *ASDC J Dent Child.* 1984;51:58–63.
17. Curran JB, Baker CG. Bilateral transposition of maxillary canines. *Oral Surg.* 1973;36:905–906.
18. Shapira Y, Kuflinec MM. Orthodontic management of mandibular canine-incisor transposition. *Am J Orthod.* 1983;83:271–276.
19. Jackson M. Upper canine in position of upper central incisor [abstract]. *Br Dent J.* 1951;90:243.
20. Caplan D. Transposition of the maxillary canine and the lateral incisor. *Dent Pract Dent Rec.* 1972;22:307.
21. Shapira Y, Kuflinec MM. A unique treatment approach for maxillary canine-lateral incisor transposition. *Am J Orthod Dentofacial Orthop.* 2001;119:540–545.
22. Shapira Y, Borell G, Kuflinec MM, Nahlieli O. Bringing impacted mandibular second premolars into occlusion. *J Am Dent Assoc.* 1996;127:1075–1078.
23. Ericson S, Kurol J. Early treatment of palatally erupting maxillary canines by extraction of the primary canines. *Eur J Orthod.* 1988;10:283–295.
24. Chaushu S, Zilberman Y, Becker A. Maxillary incisor impaction and its relationship to canine displacement. *Am J Orthod Dentofacial Orthop.* 2003;124:144–150.