

Abnormal Mandibular Growth after Craniovertebral Surgery in Morquio Syndrome Type A

Ef시오 Defraia^a; Andrea Marinelli^b; Antonino Antonini^a; Veronica Giuntini^c

Abstract: Morquio syndrome or MPS4A is an autosomal recessive inherited metabolic disease, due to a deficiency of *N*-acetyl-galactosamine-6-sulfatase (OMIM 253000). Hypoplastic odontoid processes causing atlantoaxial subluxation and cervical myelopathy are usual clinical findings. Surgical intervention of craniocervical fusion is often performed to prevent this complication. Clinical and cephalometric findings in a patient affected by Morquio syndrome after craniovertebral surgery are described. Facial growth pattern in the lateral plane changed dramatically. The mandibular gonial angle (ArGoMe), the body of the mandible (GoGn), and the total length of the mandible (CoGn) increased abnormally, whereas the mandibular ramus (CoGo) exhibited normal growth. Knowledge of the possibility of abnormal mandibular growth may contribute in long-term orthodontic management of such subjects. (*Angle Orthod* 2005;75:461–464.)

Key Words: Morquio syndrome; Mucopolysaccharidosis

INTRODUCTION

Patients with Morquio syndrome are free from neurological symptoms until the first year of life. Spinal deformity and growth retardation are also not evident until about the same time.¹ The hypoplastic odontoid process causes atlantoaxial subluxation and cervical myelopathy that can lead to neurological symptoms. In recent years, surgical intervention of craniocervical fusion has been proposed to prevent this complication.²

The clinical case of a female patient affected by Morquio syndrome type A undergoing orthodontic treatment is described, with particular attention to follow-up of craniovertebral posture and mandibular growth, which increased unexpectedly after neuro-orthopedic surgery. This outcome has not been reported previously in the literature.

CASE REPORT

The patient, a female, aged 19 years, was observed for the first time at age seven years at the Department of Or-

thodontics of the University of Florence. When she was six years old, she underwent bilateral tibial osteotomies, to increase stature. Clinical examination revealed characteristic signs of Morquio syndrome, such as deficiency in statural height, short neck, pectus carinatum, and coxa valga. Typical defects in enamel structure of teeth were present as well.³ Orthodontic therapy was started at age 11 years (Figures 1 and 2) to improve the transverse dimensions of the upper arch and to correct the posterior crossbite. Cephalometric analysis confirmed a well-balanced position in the lateral view. At 12 years of age, the patient underwent surgical intervention of craniocervical fusion, due to paresthesia in the right hand and neurological abnormalities in the lower limb because of cervical myelopathy. Odontoid instability was treated by posterior fixation of arches of C¹ and C².

After surgical intervention, the facial growth pattern in the lateral plane changed dramatically. Comparisons between measurements on head films of the patient and standard values⁴ taken before and after surgery show that the mandibular dimensions increased abnormally. The mandibular gonial angle (ArGoMe), the body of the mandible (GoGn), and the total length of the mandible (CoGn) increased extraordinarily, whereas the mandibular ramus (CoGo) exhibited normal growth (Table 1). The mandible overgrew the maxilla significantly in the postsurgical period, with an increased backward direction of condylar growth (Figures 3 and 4).

DISCUSSION

Patients with Morquio syndrome present pathognomonic clinical characteristics related to skeleton and facial defor-

^a Research Associate, Department of Orthodontics, University of Florence, Florence, Italy.

^b Associate Professor, Department of Orthodontics, University of Florence, Florence, Italy.

^c PhD program in Clinical Pediatrics, Department of Orthodontics, University of Florence, Florence, Italy.

Corresponding author: Andrea Marinelli, DDS, PhD, Department of Orthodontics, University of Florence, Via del Ponte di Mezzo 46–48, Florence 50127, Italy (e-mail: a.marinelli@yahoo.com).

Accepted: June 2004. Submitted: May 2004.

© 2005 by The EH Angle Education and Research Foundation, Inc.

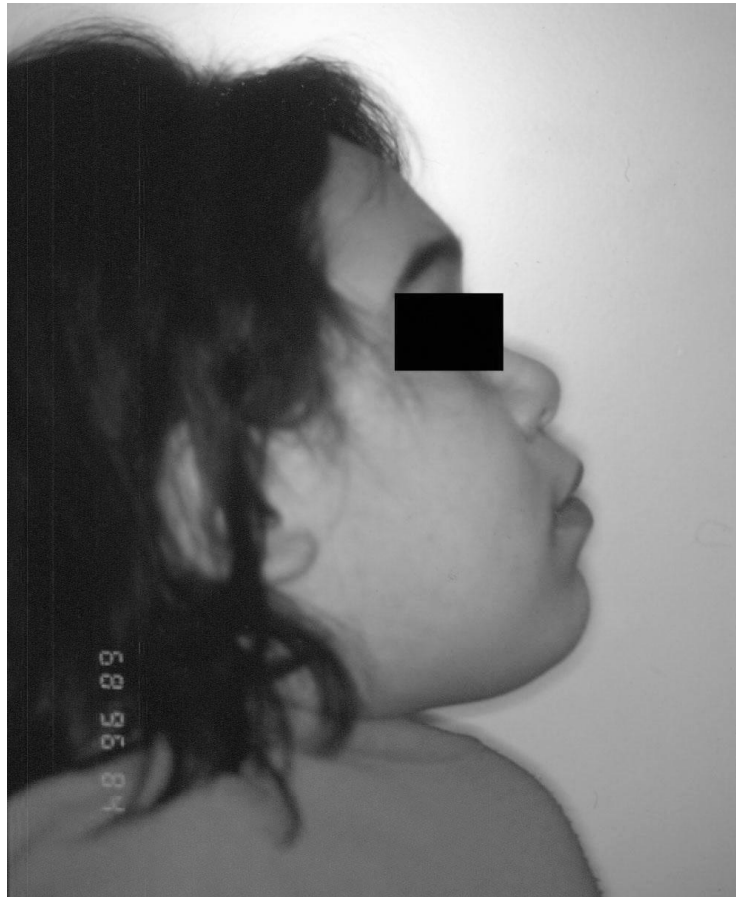

FIGURE 1. Age 11 years; lateral view of the face.

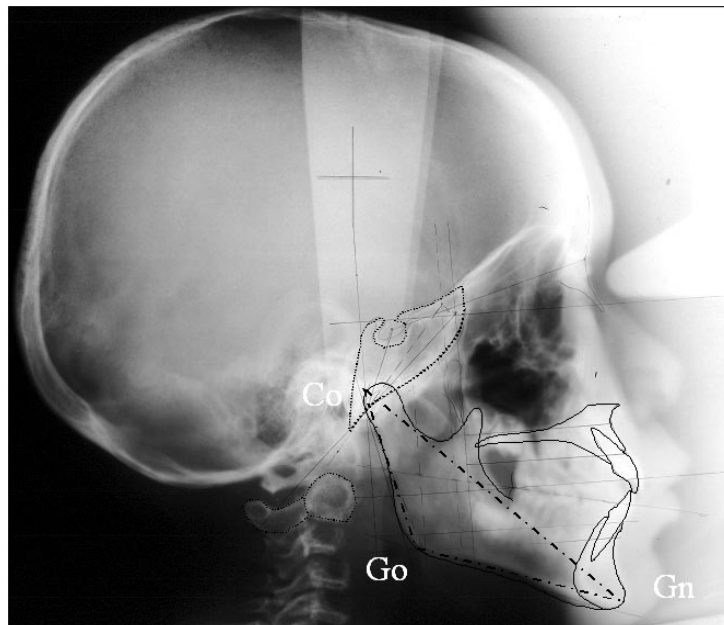


FIGURE 2. Age 11 years; lateral radiograph of the head.

TABLE 1. Comparison between Standard and Individual Mandibular Cephalometric Measurements before Surgical Treatment (11 Years) and after Surgical Treatment (15 Years)

	Ar Go Me (°)	Co Gn (mm)	Co Go (mm)	Go Gn (mm)
Standard values at the age of 11 years (females)	131.1 ± 4.4	111.4 ± 4.2	53.2 ± 3.1	72.5 ± 3.4
Patient's values at the age of 11 years	130.5	111.0	54.0	74.5
Standard values at the age of 15 years (females)	129.0 ± 4.5	119.6 ± 4.2	58.5 ± 3.5	77.6 ± 3.9
Patient's values at the age of 15 years	140.0	121.5	59.0	84.5

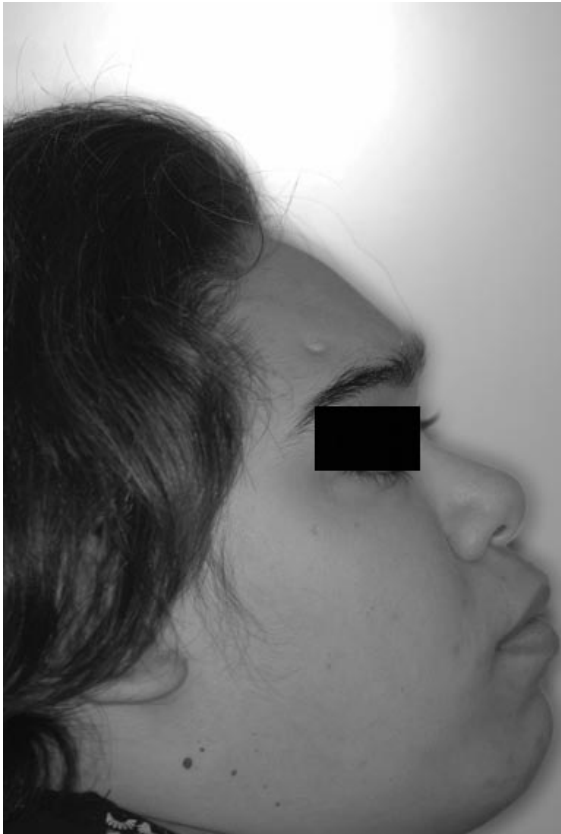


FIGURE 3. Age 15 years; lateral view of the face.

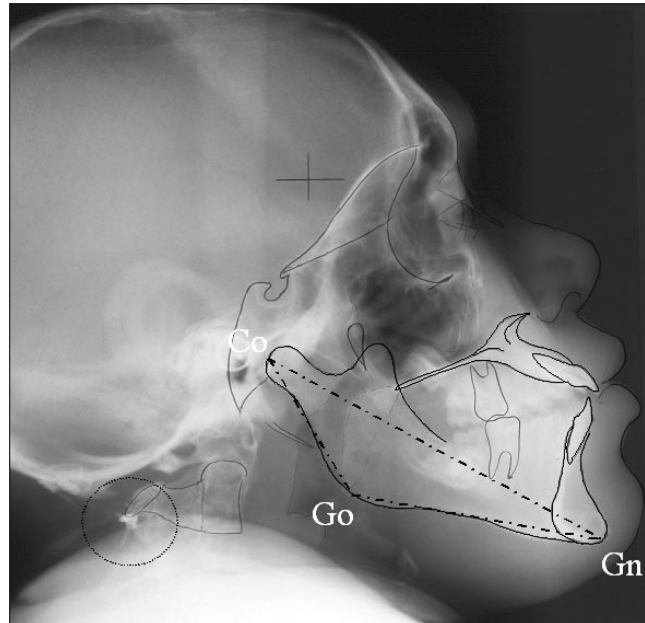


FIGURE 4. Age 15 years; lateral radiograph of the head.

mities and their effects on the central nervous system. Enamel defects in both the deciduous and permanent teeth make them very vulnerable to caries.³

Hypoplasia of the odontoid process of the second cervical vertebra is a pathognomonic sign, always present in the clinical complex. In Morquio syndrome, both mortality and morbidity are related primarily to atlantoaxial subluxation resulting from the instability of odontoid process. A minor fall or extension of the neck can result in cord transection and subsequent quadriplegia or death,⁵ and it can be avoided by surgical craniocervical fusion.

Because of lack of information in the literature about the mandibular growth pattern in Morquio syndrome after craniocervical surgery, the excessive amount of mandibular enlargement was an unexpected finding, affecting particularly in mandibular body size and total length, probably as a consequence of the modified craniocervical posture and in

the position of the tongue. The increase of the gonial angle (ArGoMe) had an important influence on the improvement in the total mandibular length. It increased 9.5°. In normal subjects, it reduces physiologically about 2° during the observed period.⁴ The change in head posture after the surgical intervention probably had an important role in the change of growth direction. Solow and Kreiborg⁶ hypothesized that the stretching of soft tissues after head extension causes an increase in caudally directed forces that redirect facial growth. The great improvement in length of the mandibular body was probably induced by tongue thrust, and the abnormal low posture was certainly worsened by the change of posture after the surgical intervention. Tongue thrust may have contributed to the development of mandibular prognathism by causing the mandible to be positioned forward constantly.⁷

CONCLUSIONS

In patients with Morquio syndrome who are scheduled to undergo surgical craniocervical treatment, a long-term follow-up of mandibular growth is recommended, especially in cases in which surgical intervention was performed before the peak of mandibular growth. We believe that a

compensatory orthodontic treatment should be associated with orthopedic therapy aimed at managing the anteroposterior growth of the mandible.

REFERENCES

1. Holzgreve W, Grobe H, von Figura K, Kresse H, Beck H, Mattei JF. Morquio syndrome: clinical findings in 11 patients with MPS IVA and 2 patients with MPS IVB. *Hum Genet.* 1981;57(4):360–365.
2. Northover H, Cowie RA, Wraith JE. Mucopolysaccharidosis type IVA (Morquio syndrome): a clinical review. *J Inherit Metab Dis.* 1996;19(3):357–365.
3. Sela M, Eidelman E, Yatziv S. Oral manifestations of Morquio's syndrome. *Oral Surg Oral Med Oral Pathol.* 1975;39(4):583–589.
4. Saksena SS, Walker GF, Bixler D, Yu P. *A Clinical Atlas of Roentgenocephalometry in norma lateralis.* New York, NY: Alan R Liss Inc; 1987:189.
5. Rigante D, Antuzzi D, Ricci R, Segni G. Cervical myelopathy in mucopolysaccharidosis type IV. *Clin Neuropathol.* 1999;18(2):84–86.
6. Solow B, Kreiborg S. Soft-tissue stretching: a possible control factor in craniofacial morphogenesis. *Scand J Dent Res.* 1977;85(6):505–507.
7. Proffit WR, Fields HW Jr. *Contemporary Orthodontics.* 2nd ed. St Louis, Mo: CV Mosby Company; 1993:128–129