

Orthodontic Effects on Dentofacial Morphology in Women with Bilateral TMJ Disk Displacement

Sug-Joon Ahn^a; Shin-Jae Lee^a; Tae-Woo Kim^b

ABSTRACT

Objective: To determine the difference in skeletal response to orthodontic treatment between patients with bilateral disk derangement and normal disk position of the temporomandibular joint (TMJ).

Materials and Methods: Subjects consisted of 46 women whose malocclusions were treated only by orthodontics. All patients had TMJ magnetic resonance imaging (TMJ MRI) taken prior to orthodontic treatment. They were classified into three groups according to results of the TMJ MRI: bilateral normal disk position (BN), bilateral disk displacement with reduction (BDDR), and bilateral disk displacement without reduction (BDDNR). Twenty cephalometric variables were evaluated by the Kruskal-Wallis test to identify any differences in morphological changes between the three groups during orthodontic treatment.

Results: This study showed that patients with BDDNR had more severe sagittal and vertical skeletal discrepancies than those with BN and BDDR at the pretreatment stage with discrepancies maintained after treatment. Compared to patients with BN, BDDR patients exhibited significant changes in SNB, N perpendicular to pogonion, SN to mandibular plane angle, total anterior facial height, ramus inclination, and effective mandibular length during treatment. This means that patients with BDDR showed more backward movement and rotation of the mandible than those with BN. In contrast, patients with BDDNR who had the most severe skeletal discrepancies did not show any significant skeletal changes during orthodontic treatment compared to those with BN or BDDR.

Conclusion: In patients with bilateral TMJ disk displacement, orthodontic treatment should be undertaken carefully to prevent backward rotation and movement of the mandible.

KEY WORDS: Orthodontic effect; Dentofacial morphology; TMJ disk displacement

INTRODUCTION

Disk displacement (DD) is the most common type of temporomandibular disorder and is characterized by progressive disk displacement of the articular disk, which may lead to temporomandibular joint (TMJ) clicking, crepitus, and in some cases, pain and limi-

tations in jaw movement.^{1,2} DD is the principal clinical sign of internal derangement, which progresses from a reducing to a nonreducing state.^{3,4}

DD contributes to changes in facial morphology, because it can alter the condylar and mandibular morphology, resulting in facial changes.⁵⁻¹² A backward rotation of the ramus and mandible, a short ramal height, a decrease in effective mandibular length, and mandibular asymmetry are the skeletal characteristics of patients with TMJ DD. Specifically, a backward rotation of the ramus and a decrease in effective mandibular length are reported as early cephalometric signs of TMJ DD.^{9,10,12} These skeletal characteristics become more severe as DD progresses.^{9,10,12}

There have been many arguments about the role of orthodontic treatment in TMJ DD and vice versa, but only a few studies to date,¹³⁻¹⁹ and in those, the effects of orthodontic treatment were not sufficiently analyzed. Some investigators suggest that orthodontic treatment

^a Assistant Professor, Department of Orthodontics, School of Dentistry and Dental Research Institute, Seoul National University, Seoul, Korea.

^b Professor and Department Chair, Department of Orthodontics, School of Dentistry, Seoul National University, Seoul, Korea.

Corresponding author: Dr Shin-Jae Lee, Department of Orthodontics, School of Dentistry and Dental Research Institute, Seoul National University, 28-22 Yunkeun-Dong, Chongro-Ku, Seoul 110-768, Korea (ROK) (e-mail: nonext@snu.ac.kr)

Accepted: April 2006. Submitted: February 2006.

© 2007 by The EH Angle Education and Research Foundation, Inc.

may play a causative role in the development of TMJ DD,^{13,14} whereas others say that orthodontic treatment may not be a risk factor for the development of signs and symptoms of temporomandibular disorder (TMD), though this is not specific to TMJ DD.¹⁵⁻¹⁹ These studies evaluated differences in TMJ sounds, tenderness, and TMJ or muscle pain, which are all subjective signs of TMJ DD and as such may not be reliable. Additionally, many studies on the relationship between orthodontic treatment and TMJ DD have been based on anecdotal evidence or retrospective studies.^{5,14,17,19} Because the examination methods were not standardized, the studies to date have lacked objective and quantitative rigor.

Until recently, the research on orthodontic treatment has assumed that the condyle and TMJ are normal in all patients receiving various orthodontic treatments. However, we believe that diagnoses and treatment plans should consider the status of TMJ in patients with TMJ DD, because the dentofacial morphology in patients with TMJ DD can be influenced by orthodontic treatment.

Recently, the occurrence of patients with TMJ DD has been gradually increasing in orthodontics because of the prevalence of TMJ DD increasing with age and the increased number of adults undergoing orthodontic treatment.¹⁵ In addition, adult patients no longer have the capacity to compensate for TMJ DD through growth and development. The purpose of this study was to evaluate differences in the skeletal response to orthodontic treatment between adult patients with bilateral TMJ DD and patients with bilateral normal disk position, based on TMJ magnetic resonance imaging (MRI).

MATERIALS AND METHODS

All the subjects in this retrospective study had a primary complaint of a malocclusion. Irrespective of TMJ status, all subjects consented to a bilateral high-resolution MRI in the sagittal (open and closed) and coronal (closed) planes to evaluate their TMJs. The MRIs were obtained using a Signa Horizon (GE, Waukesha, Wis) operating at 1.5 T and with a unilateral 3-inch surface receiver coil (GE). Initially, the axial scout images were obtained at the level of the TMJs in order to identify the long axes of the condyles. Nonorthogonal sagittal sections were obtained perpendicular to the condyles, and nonorthogonal coronal oblique sections were also obtained. Closed-mouth images were taken at a maximum dental intercuspation, and open-mouth images were taken at the maximum unassisted vertical mandibular opening using a Burnett bidirectional TMJ device (Medrad, Pittsburgh, Pa). T1-weighted 600/12 (repetition time [TR] ms/echo time [TE] ms)

and proton-density 4000/14 (TR ms/TE ms) pulse sequences were performed in the sagittal plane using a 3-mm slice thickness, a 10-cm field of view, two excitations, and an image matrix of 254 × 192 pixels. T1-weighted 500/12 (TR ms/TE ms) pulse sequences were performed in the coronal plane under the same conditions.

Radiologists with TMJ MRI experience interpreted the images without clinical information on the patients. According to previous criteria,²⁰ TMJ disk status was divided into three categories: normal disk position, disk displacement with reduction, and disk displacement without reduction. Cases lacking the clarity necessary for the diagnosis of DD were rejected.

The subjects were selected from a pool of patients according to the following inclusion criteria:

1. Female adult patients over the age of 17;
2. Patients with no history of rheumatoid arthritis;
3. Patients with no history of previous orthodontic treatment;
4. Patients in whom only orthodontic treatment had been designed and completed;
5. Patients in whom treatment results were followed clinically for at least 6 months after debonding;
6. Patients having bilateral normal disk position (BN), bilateral disk displacement (BDDR), or bilateral disk displacement without reduction (BDDNR);
7. Medial or lateral disk displacements were only included when accompanied by anterior disk displacements;
8. Patients who complained of specific clinical signs or symptoms of TMJ were referred to the TMJ clinic and treated completely before orthodontic treatment;
9. Transpalatal arch and/or highpull headgear were used to reinforce vertical anchorage in patients who had Frankfort mandibular plane angle (FMA) greater than 33° (one patient in group 1, five patients in group 2, and 12 patients in group 3).

Forty-six women were selected from 245 patients. The patients were divided into three groups based on their TMJ MRI results: BN (Group 1), BDDR (Group 2), and BDDNR (Group 3). All subjects were treated using a preadjusted appliance with 0.022-inch slots. There was no significant difference in age at the start of orthodontic treatment or treatment time among the three groups (Table 1).

Pretreatment and posttreatment lateral cephalograms were analyzed. A single investigator traced all cephalograms. The tracings were digitized with a digitizer interfaced with a desktop computer. Fifteen landmarks, from which 20 variables were calculated, were digitized on each radiograph. For convenience of analysis, the variables were subdivided into four categories.

Table 1. Means and Ranges of Age at the Start of Orthodontic Treatment and Treatment Times of Patients With Normal Disk Position (Group 1), Disk Displacement With Reduction (Group 2), and Disk Displacement Without Reduction (Group 3)

	Group 1 n = 13	Group 2 n = 17	Group 3 n = 16	Total n = 46	Significance ^a
Age (y)					
Mean (SD)	23.9 (5.2)	24.2 (7.2)	22.8 (3.6)	23.6 (5.4)	NS
Range	17.4–32.2	18.2–43.7	18.5–26.9	17.4–43.7	
Treatment time (mo)					
Mean (SD)	26.4 (10.7)	27.3 (11.8)	28.8 (8.7)	27.6 (10.4)	NS
Range	9–37	11–48	11–47	9–48	

^a A Kruskal-Wallis test was used to analyze the difference in age and treatment times between the three groups at a significance level of $\alpha = .05$. NS indicates not significant.

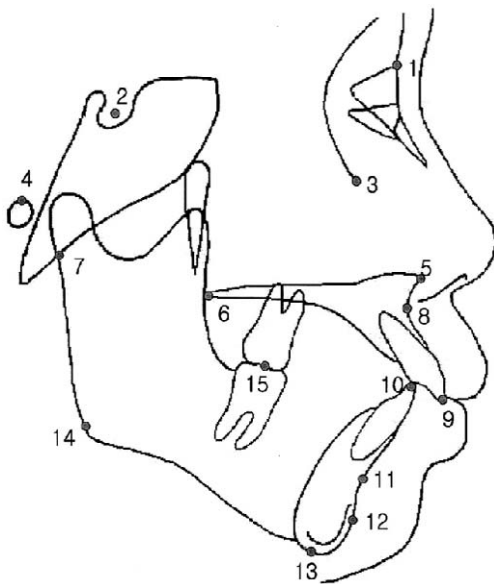


Figure 1. The landmarks used in this study. (1) Nasion, (2) sella, (3) orbitale, (4) porion, (5) anterior nasal spine, (6) posterior nasal spine, (7) articulare, (8) point A, (9) incisal end of upper incisor, (10) incisal end of lower incisor, (11) point B, (12) pogonion, (13) menton, (14) gonion, and (15) articulation of upper molar and lower molar.

ries: maxillomandibular relationship, vertical skeletal relationship, size and form of the mandible, and dental relationship. The positions of all the landmarks are shown in Figure 1 and their measurements are shown in Figures 2 and 3.

Descriptive statistics for each variable were calculated at pretreatment (Table 2) and posttreatment stages (Table 3), and during orthodontic treatment (Table 4). The skeletal changes during the treatment were described by subtracting the pretreatment from the posttreatment value of a given variable. The Kruskal-Wallis test was used to determine any significant differences in dentofacial morphology at the pretreatment and posttreatment stages and skeletal changes during orthodontic treatment among the three groups. A Mann-Whitney *U*-test was performed with a signifi-

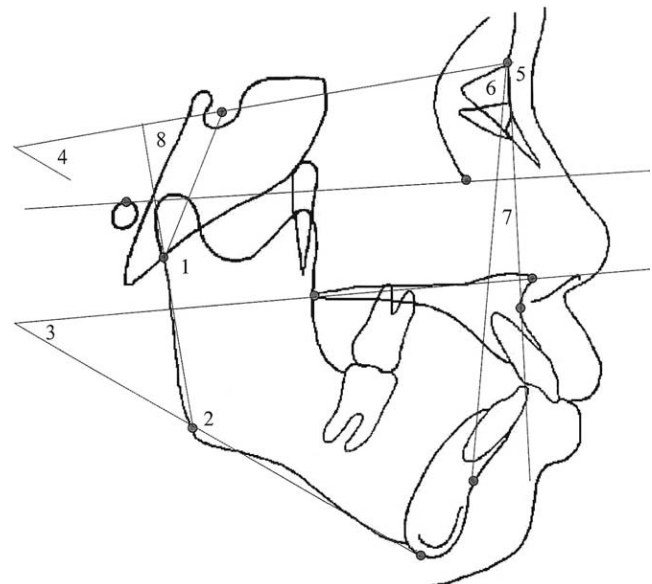


Figure 2. The angular measurements used in this study. (1) Articular angle (S-Ar-Go), (2) gonial angle (Ar-Go-Me), (3) palatal plane to mandibular plane angle, (4) SN to mandibular plane angle, (5) SNA, (6) SNB, (7) ANB, and (8) ramus inclination (N-S to Ar-Go)

cance level of $\alpha = .05$ to compare differences between groups.

A random sample of 10 cephalometric radiographs were traced and digitized 1 month after they were originally traced in order to test the magnitude of error during landmark identification, tracing, and digitization. Using Dahlberg's formula,²¹ the error ranged from 0.12 to 0.68 mm for the linear measurements and from 0.20 to 0.78° for the angular measurements.

RESULTS

Table 2 shows the differences in dentofacial morphology at the onset of treatment. Eleven of 20 cephalometric variables showed statistically significant differences. The differences were mainly because of the discrepancies between group 3 and groups 1 or 2. The patients with BDDNR had the largest ANB, facial con-

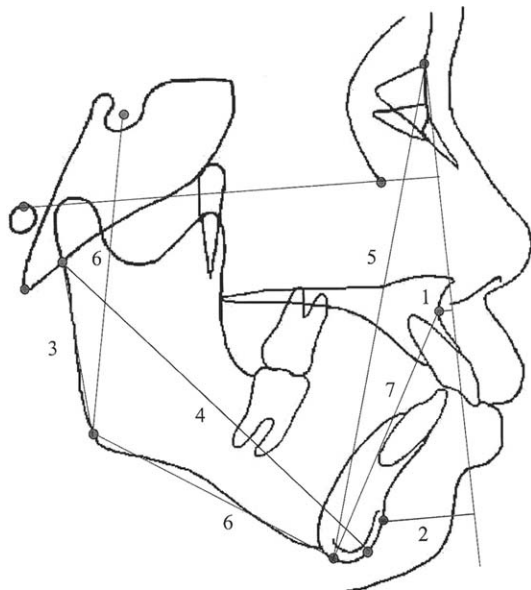


Figure 3. The linear measurements used in this study. (1) N-perpendicular to point A, (2) N-perpendicular to pogonion, (3) ramus height (Ar-Go), (4) total mandibular length (Ar-Pog), (5) total anterior facial height (N-Me), (6) total posterior facial height (S-Go), and (7) lower anterior facial height (ANS-Me).

vexity, and overjet, and a steeper maxillomandibular plane angle and ramus inclination. This indicates that the patients with BDDNR had a larger anteroposterior jaw discrepancy and a more hyperdivergent skeletal pattern than those with BN or BDDR.

The skeletal discrepancies shown at the pretreatment stage persisted after the orthodontic treatment (Table 3). The anteroposterior and vertical skeletal discrepancies were still present between the subjects in groups 1 or 2 and group 3 at the end of the treatment. These results suggest that orthodontic treatment could not treat the skeletal Class II pattern with vertical dysplasia in patients with BDDNR. Nevertheless, achieving a normal range of overjet and overbite means that the dental problems of the patients can be corrected relatively well by orthodontic treatment.

Table 4 shows the changes in skeletal variables of the three groups during orthodontic treatment. SNB, N perpendicular to pogonion, SN to mandibular plane angle, total anterior facial height, ramus inclination, and effective mandibular length showed statistically significant differences between groups 1 and 2, whereas differences in overjet were significant between groups 1 and 3.

Table 2. Comparisons of Jaw Bone Morphology Between Patients With Normal Disk Position (Group 1), Disk Displacement With Reduction (Group 2), and Disk Displacement Without Reduction (Group 3) at the Pretreatment Stage

Variables	Mean (SD)			Significance ^a
	Group 1 (n = 13)	Group 2 (n = 17)	Group 3 (n = 16)	
Maxillomandibular relationship				
SNA (°)	81.3 (2.5)	81.7 (3.1)	81.4 (3.5)	NS
SNB (°)	77.6 (3.7)	77.5 (3.2)	74.8 (4.4)	(1 > 3),* (2 > 3)*
N perpendicular to point A (mm)	2.1 (2.8)	1.9 (2.8)	1.8 (2.9)	NS
N perpendicular to pogonion (mm)	-3.2 (7.9)	-4.3 (6.6)	-11.4 (7.3)	(1 > 3),** (2 > 3)*
Facial convexity (N-A-Pog) (°)	6.8 (7.4)	7.6 (4.2)	13.6 (7.3)	(1 < 3),* (2 < 3)*
ANB (°)	3.6 (3.2)	4.2 (2.0)	6.6 (3.1)	(1 < 3),* (2 < 3)*
Vertical skeletal relationship				
SN to mandibular plane angle (°)	39.6 (6.5)	40.4 (4.6)	43.9 (8.9)	NS
Maxillomandibular plane angle (ANS-PNS/Go-Me) (°)	27.9 (5.7)	30.3 (6.2)	34.4 (8.2)	(1 < 3)*
Total anterior facial height (N-Me) (mm)	132.9 (4.1)	131.8 (5.0)	131.7 (6.8)	NS
Total posterior facial height (S-Go) (mm)	84.0 (7.3)	82.7 (7.3)	80.1 (6.4)	NS
Lower anterior facial height (ANS-Me) (mm)	76.5 (3.2)	75.8 (3.9)	77.3 (5.0)	NS
Total anterior facial height/total posterior facial height (%)	63.2 (5.4)	62.8 (4.3)	60.9 (5.6)	NS
Lower anterior facial height/total anterior facial height (%)	54.3 (2.5)	54.6 (2.4)	53.6 (1.6)	NS
Size and form of mandible				
Ramus height (Ar-Go) (mm)	50.9 (6.3)	49.4 (6.0)	47.3 (3.3)	(1 > 3)*
Ramus inclination (SN to Ar-Go) (°)	96.7 (6.2)	97.3 (5.9)	103.7 (5.5)	(1 < 3),** (2 < 3)**
Effective mandibular length (Ar-Pog) (mm)	111.4 (7.7)	110.4 (6.1)	104.9 (4.9)	(1 > 3),* (2 > 3)*
Gonial angle (Ar-Go-Me) (°)	123.0 (6.0)	123.2 (7.4)	120.3 (7.8)	NS
Articular angle (S-Ar-Go) (°)	153.0 (9.1)	152.8 (7.3)	160.5 (7.4)	(1 < 3),** (2 < 3)**
Dental relationship				
Overbite (mm)	-1.0 (1.9)	0.2 (2.9)	-1.7 (1.8)	(2 < 3)*
Overjet (mm)	3.3 (2.0)	4.8 (1.6)	5.9 (2.9)	(1 < 3),* (2 < 3)*

^a Mann-Whitney U-test was used for comparisons between groups at a significance level of $\alpha = .05$. NS indicates not significant.

* $P < .05$; ** $P < .01$.

Table 3. Comparisons of Jaw Bone Morphology Between Patients With Normal Disk Position (Group 1), Disk Displacement With Reduction (Group 2), and Disk Displacement Without Reduction (Group 3) at the Posttreatment Stage

Variables	Mean (SD)			Significance ^a
	Group 1 (n = 13)	Group 2 (n = 17)	Group 3 (n = 16)	
Maxillomandibular relationship				
SNA (°)	81.7 (2.4)	81.5 (3.3)	81.3 (4.4)	NS
SNB (°)	77.5 (3.5)	76.6 (3.3)	74.2 (4.1)	(1 > 3),* (2 > 3)*
N perpendicular to point A (mm)	2.5 (2.8)	0.8 (2.7)	2.1 (2.9)	NS
N perpendicular to pogonion (mm)	-3.2 (7.5)	-7.3 (7.4)	-12.2 (7.8)	(1 > 3),** (2 > 3)*
Facial convexity (N-A-Pog) (°)	7.7 (6.4)	8.8 (4.1)	15.1 (8.8)	(1 < 3),* (2 < 3)*
ANB (°)	4.1 (2.9)	4.9 (1.8)	7.0 (3.8)	(1 < 3),* (2 < 3)*
Vertical skeletal relationship				
SN to mandibular plane angle (°)	39.5 (6.1)	41.6 (4.9)	44.9 (8.3)	NS
Maxillomandibular plane angle (ANS-PNS/Go-Me) (°)	27.8 (5.1)	31.1 (6.4)	35.2 (7.9)	(1 < 3)*
Total anterior facial height (N-Me) (mm)	133.4 (3.9)	133.3 (4.3)	132.8 (6.2)	NS
Total posterior facial height (S-Go) (mm)	84.7 (7.5)	83.1 (7.4)	80.3 (6.3)	NS
Lower anterior facial height (ANS-Me) (mm)	76.8 (3.6)	77.3 (3.9)	78.6 (4.6)	NS
Total anterior facial height/total posterior facial height (%)	63.5 (5.3)	62.2 (4.5)	60.5 (5.2)	NS
Lower anterior facial height/total anterior facial height (%)	54.5 (2.8)	54.6 (2.3)	53.3 (2.0)	NS
Size and form of mandible				
Ramus height (Ar-Go) (mm)	51.3 (6.2)	48.9 (5.5)	47.7 (4.3)	(1 > 3)*
Ramus inclination (SN to Ar-Go) (°)	96.1 (6.2)	98.2 (5.9)	104.5 (5.7)	(1 < 3),** (2 < 3)**
Effective mandibular length (Ar-Pog) (mm)	111.5 (7.9)	108.9 (6.0)	104.2 (6.2)	(1 > 3),* (2 > 3)*
Gonial angle (Ar-Go-Me) (°)	123.4 (5.8)	123.3 (7.8)	120.4 (7.4)	NS
Articular angle (S-Ar-Go) (°)	152.1 (9.8)	154.0 (6.9)	160.5 (7.5)	(1 < 3),* (2 < 3)*
Dental relationship				
Overbite (mm)	2.2 (1.9)	2.9 (1.2)	2.4 (1.8)	NS
Overjet (mm)	3.7 (0.7)	4.3 (1.1)	3.9 (1.3)	NS

^a Mann-Whitney *U*-test was used for comparisons between groups at a significance level of $\alpha = .05$. NS indicates not significant.

* $P < 0.05$; ** $P < 0.01$.

DISCUSSION

Generally, successful orthodontic treatment is based on the assumption that the condyle and the TMJ respond normally to various orthodontic treatments. Normal joints may respond to therapeutic orthodontic forces in a favorable and regular manner, but structurally damaged joints, such as in TMJ DD, may respond in an unfavorable and pathologic manner because the functional environment of the TMJ and its adaptive capacity are altered.²²⁻²⁴ This indicates that orthodontic treatment may have a detrimental effect on patients with TMJ DD and vice versa. A few studies suggest that orthodontic treatment may be a contributing factor for the development of TMD or TMJ DD.^{5,13,14} In particular, Drace and Enzmann¹³ evaluated 30 asymptomatic volunteers with MRI and found six subjects with internal derangement who had orthodontic treatment. However, no objective evidence has been reported about the effect of orthodontic treatment on changes in dentofacial morphology in patients with TMJ DD. The purpose of this study was to evaluate whether there are any differences in the skeletal response to orthodontic treatment between patients with bilateral TMJ DD and BN.

It was very difficult to collect patients with TMJ DD who were treated only with orthodontics, because TMJ DD patients often sought to correct their other skeletal discrepancies, such as a retrognathic mandible, a vertical skeletal dysplasia, and mandibular asymmetry.⁶⁻¹² As such, many TMJ DD patients selected surgical orthodontic treatment, which excluded them from our study, because it was not possible to determine the skeletal response of dentofacial morphology to orthodontic treatment. Patients with unilateral DD or those with more severe DD on the unilateral than the contralateral side were also excluded from our study, because the effect of orthodontic treatment on the affected side could not be determined accurately from the lateral cephalograms. From the initial pool of over 200 candidates, 46 patients were selected.

Previous studies showed a significant difference in dentofacial morphology between subjects with TMJ DD and BN. These included decreases in posterior facial height and ramus height, and a backward rotation and retruded position of the mandible.^{9,10,12} These changes became more severe as DD progressed to BDDNR. The present study also showed significant skeletal discrepancies in dentofacial morphology be-

Table 4. Comparison of Changes in Jaw Bone Morphology During Orthodontic Treatment Between Patients With Normal Disk Position (Group 1), Disk Displacement With Reduction (Group 2), and Disk Displacement Without Reduction (Group 3).^a

Variables	Mean (SD)			Significance ^b
	Group 1 (n = 13)	Group 2 (n = 17)	Group 3 (n = 16)	
Maxillo-mandibular relationship				
SNA (°)	0.4 (1.0)	-.2 (1.1)	-0.1 (1.8)	NS
SNB (°)	-0.1 (0.6)	-1.0 (1.0)	-0.5 (1.0)	(1 > 2)*
N perpendicular to point A (mm)	0.4 (1.0)	-0.7 (1.7)	0.3 (1.4)	NS
N perpendicular to pogonion (mm)	0.0 (2.6)	-2.7 (2.8)	-0.9 (2.8)	(1 > 2)**
Facial convexity (N-A-Pog) (°)	0.9 (2.6)	1.5 (2.4)	1.5 (3.2)	NS
ANB (°)	0.5 (1.1)	0.7 (1.1)	0.5 (1.7)	NS
Vertical skeletal relationship				
SN to mandibular plane angle (°)	-0.2 (1.1)	1.3 (1.2)	1.0 (1.5)	(1 < 2)*
Maxillomandibular plane angle (ANS-PNS/Go-Me) (°)	-0.1 (1.7)	0.9 (1.8)	0.8 (1.3)	NS
Total anterior facial height (N-Me) (mm)	0.5 (1.1)	1.9 (1.2)	1.1 (1.7)	(1 < 2)*
Total posterior facial height (S-Go) (mm)	0.7 (1.4)	0.6 (0.9)	0.2 (1.5)	NS
Lower anterior facial height (ANS-Me) (mm)	0.3 (1.7)	1.6 (1.6)	1.3 (1.1)	NS
Total anterior facial height/total posterior facial height (%)	0.2 (1.3)	-0.5 (1.0)	-0.4 (1.8)	NS
Lower anterior facial height/total anterior facial height (%)	0.2 (1.0)	0.0 (1.2)	-0.3 (1.8)	NS
Size and form of mandible				
Ramus height (Ar-Go) (mm)	0.4 (1.5)	-0.5 (1.9)	0.4 (1.9)	NS
Ramus inclination (SN to Ar-Go) (°)	-0.6 (1.8)	1.0 (2.2)	0.8 (2.6)	(1 < 2)*
Effective mandibular length (Ar-Pog) (mm)	0.1 (1.5)	-1.3 (1.7)	-0.8 (2.8)	(1 > 2)*
Gonial angle (Ar-Go-Me) (°)	0.4 (1.8)	0.3 (2.3)	0.2 (2.3)	NS
Articular angle (S-Ar-Go) (°)	-0.8 (2.9)	1.1 (2.4)	0.1 (3.3)	NS
Dental relationship				
Overbite (mm)	3.2 (3.5)	2.7 (2.2)	4.2 (1.6)	NS
Overjet (mm)	0.4 (2.0)	-0.4 (1.5)	-2.0 (3.5)	(1 > 3)*

^a The changes during the treatment were described by subtracting pretreatment from posttreatment values of a given variable.

^b Mann-Whitney *U*-test was used for comparisons between groups at a significance level of $\alpha = .05$. NS indicates not significant.

* $P < .05$. ** $P < .01$

tween patients with BN and those with BDDNR. However, there were no statistically significant differences between patients with BN and those with BDDR (Table 2). Additionally, the skeletal discrepancies between BN and bilateral DD were much less than those previously reported, which had shown discrepancies in the dentoskeletal morphology between BN and BDDR.^{9,10,12} This could be because the patients in our study were treated only with orthodontics, because these patients had less severe skeletal problems than those treated with surgical orthodontic treatment.

The results of this study showed some statistical differences in the skeletal response to orthodontic treatment between patients with BN and bilateral DD (Table 4). Only six skeletal variables, including SNB, N perpendicular to pogonion, SN to mandibular plane angle, total anterior facial height, ramus inclination, and effective mandibular length were significantly changed after orthodontic treatment in patients with BDDR compared to those with BN. On the other hand, changes in overjet were much greater in patients with BDDNR than in those with BN. In the case of overjet, the significant changes during treatment were the re-

sults of orthodontic treatment, because patients with BDDNR initially had a significantly larger overjet compared to those with BN at the pretreatment stage (Table 2).

However, the differences in treatment changes of the six skeletal variables may not have been intentional. All six variables showed significant differences only between patients with BN and those with BDDR. The mandible moved and rotated backward after treatment more in patients with BDDR than in those with BN. This change was accompanied with increased anterior vertical dimensions, as total anterior facial height revealed significant difference between the two groups. The most reasonable explanation for these changes may be the inadequate response of TMJ to orthodontic treatment. TMJ DD is a localized disturbance in the functional environment of TMJ²²⁻²⁴ that can result in inadequate remodeling in the condylar region, which in turn portends changes in dentofacial morphology during orthodontic treatment.

Nevertheless, there were no significant differences in dentofacial morphology during orthodontic treatment between patients with BN and those with BDDNR. If

orthodontic treatment influences the TMJ and results in skeletal changes in patients with TMJ DD, patients with BDDNR would be affected more than those with BDDR, because patients with BDDNR have the most significant skeletal discrepancies (skeletal Class II with severe vertical dysplasia) as well as TMJ problems before treatment (Table 2). However, the patients with BDDNR did not show significant differences in their orthodontic responses compared with the other two patient groups. This can be explained by differences in treatment options between the patients with BDDR and those with BDDNR. Surgical orthodontic treatment should have been performed in the patients with BDDNR because of their severe skeletal dysplasia before orthodontic treatment. However, these patients selected nonsurgical treatment options.

We made constant efforts to minimize the further clockwise rotation and backward movement of the mandible, which could prevent unfavorable changes in the skeletal relationship during orthodontic treatment. For example, highpull headgear and transpalatal arches were used in the majority of the patients with BDDNR to prevent aggravation of their severe skeletal dysplasia. These efforts may help successful adaptation of the TMJ to orthodontic treatment and prevent unfavorable vertical skeletal changes in patients with BDDNR. In contrast, the patients with BDDR were treated in a similar way to those with BN, because the patients with BDDR had less severe skeletal problems than those with BDDNR and exhibited similar skeletal patterns to those with BN (Table 2). The results of this study indicate that successful orthodontic treatments are possible in patients with DD.

This study suggests that orthodontic treatment should be carefully applied to patients with BDDNR. First, we did not include patients who had greater skeletal discrepancies and required surgical orthodontic treatment. Therefore, patients showing relatively fewer skeletal discrepancies were included and corrected only by orthodontic treatment. Second, backward rotation and movement of the mandible during orthodontic treatment was also shown in patients with BDDNR, although there were no statistically significant differences between groups 1 and 3 (Table 4). Additionally, the clinical signs and symptoms of TMJ DD, which would inhibit commencement of orthodontic treatment, were treated completely before orthodontic treatment, although some patients with TMJ DD did not show any specific clinical signs or symptoms of TMJ DD.

CONCLUSIONS

- Patients with BDDNR showed more backward position and rotation of the mandible than those with BN

or BDDR at the pretreatment stage. The skeletal discrepancies persisted after orthodontic treatment.

- Patients with BDDR showed more backward movement and rotation of the mandible during orthodontic treatment than those with BN.
- Patients with BDDNR, who had more severe skeletal discrepancy than those with BN or BDDR, did not show any significant skeletal changes during orthodontic treatment.

ACKNOWLEDGMENT

This work was supported by a grant of the Korea Health 21 R&D Project, Ministry of Health & Welfare, Republic of Korea (03-PJ1-PG1-CH09-0001).

REFERENCES

1. Dolwick MF, Katzberg RW, Helms CA. Internal derangement of the temporomandibular joint: fact or fiction? *J Prosthet Dent.* 1983;49:415-418.
2. Eversole LR, Machado L. Temporomandibular joint internal derangements and associated neuromuscular disorders. *J Am Dent Assoc.* 1985;110:69-79.
3. Rasmussen OC. Description of population and progress of symptoms in a longitudinal study of temporomandibular arthropathy. *Scand J Dent Res.* 1981;89:196-203.
4. Okeson JP. Diagnosis of temporomandibular disorders. In: *Management of Temporomandibular Disorder and Occlusion.* 5th ed. St. Louis, Mo: Mosby; 2003:321-364.
5. Roth RH. Temporomandibular pain-dysfunction and occlusal relationships. *Angle Orthod.* 1973;43:136-153.
6. Gidarakou IK, Tallents RH, Kyrkanides S, Moss ME. Comparison of skeletal and dental morphology in asymptomatic volunteers and symptomatic patients with bilateral disk displacement with reduction. *Angle Orthod.* 2002;72:541-546.
7. Nebbe B, Major PW, Prasad NGN. Female adolescent facial pattern associated with TMJ disk displacement and reduction in disk length: part I. *Am J Orthod Dentofacial Orthop.* 1999;116:168-176.
8. Bosio JA, Burch JG, Tallents RH, Wade DB, Beck FM. Lateral cephalometric analysis of asymptomatic volunteers and symptomatic patients with and without bilateral temporomandibular joint disk displacement. *Am J Orthod Dentofacial Orthop.* 1998;114:248-255.
9. Ahn SJ, Kim TW, Nahm DS. Cephalometric keys to internal derangement of temporomandibular joint in women with Class II malocclusion. *Am J Orthod Dentofacial Orthop.* 2004;126:486-494.
10. Byun ES, Ahn SJ, Kim TW. Relationship between internal derangement of temporomandibular joint and dentofacial morphology in women with anterior open bite. *Am J Orthod Dentofacial Orthop.* 2005;128:87-95.
11. Ahn SJ, Lee SP, Nahm DS. Relationship between temporomandibular joint internal derangement and facial asymmetry in women. *Am J Orthod Dentofacial Orthop.* 2005;128:583-591.
12. Ahn SJ, Baek SH, Kim TW, Nahm DS. Discrimination of internal derangement of temporomandibular joint by lateral cephalometric analysis. *Am J Orthod Dentofacial Orthop.* In press.
13. Drace JE, Enzmann DR. Defining the normal temporomandibular joint: closed-, partially open- and open-mouth MR

- imaging of asymptomatic subjects. *Radiology*. 1990;97:67–71.
14. Ricketts RM. Clinical implications of the temporomandibular joint. *Am J Orthod*. 1966;52:416–439.
 15. Artun J, Hollender LG, Truelove EL. Relationship between orthodontic treatment, condylar position, and internal derangement in the temporomandibular joint. *Am J Orthod Dentofacial Orthop*. 1992;101:48–53.
 16. Carlton KL, Nanda RS. Prospective study of posttreatment changes in the temporomandibular joint. *Am J Orthod Dentofacial Orthop*. 2002;122:486–490.
 17. Katzberg RW, Westesson PL, Tallents RH, Drake CM. Orthodontics and temporomandibular joint internal derangement. *Am J Orthod Dentofacial Orthop*. 1996;109:515–520.
 18. Hirata RH, Heft MW, Hernandez B, King GJ. Longitudinal study of signs of temporomandibular disorders (TMD) in orthodontically treated and nontreated groups. *Am J Orthod Dentofacial Orthop*. 1992;101:35–40.
 19. Henrikson T, Nilner M, Kurol J. Signs of temporomandibular disorder in girls receiving orthodontic treatment. A prospective and longitudinal comparison with untreated Class II malocclusions and normal occlusion subjects. *Eur J Orthod*. 2000;271–281.
 20. Tasaki MM, Westesson P, Isberg AM, Ren YF, Tallents RH. Classification and prevalence of temporomandibular joint disk displacement in patients and symptom-free volunteers. *Am J Orthod Dentofacial Orthop*. 1996;109:249–262.
 21. Dahlberg G. *Statistical Methods for Medical and Biological Students*. New York, NY: Interscience Publication; 1940.
 22. Stegenga B, deBont LG, Boering G, van Willigen JD. Tissue responses to degenerative changes in the temporomandibular joint: a review. *Oral Maxillofac Surg*. 1991;49:1079–1088.
 23. Luder HU. Articular degeneration and remodeling in human temporomandibular joints with normal and abnormal disc position. *J Orofacial Pain*. 1993;7:391–402.
 24. Axelsson S. Human and experimental osteoarthritis of the temporomandibular joint. Morphological and biochemical studies. *Swed Dent J*. 1993;92:1–45.