

## Open Bite Correction by Intrusion of Posterior Teeth with Miniscrews

Young-Chel Park<sup>a</sup>; Han-Ah Lee<sup>b</sup>; Nak-Chun Choi<sup>b</sup>; Doo-Hyung Kim<sup>b</sup>

### ABSTRACT

The application of orthodontic miniscrews has simplified the treatment of an anterior open bite by making it more efficient and esthetic. A 19-year-old woman with an anterior open bite was treated by an intrusion of the maxillary posterior teeth using miniscrews. The posterior teeth were splinted on the palatal side with rapid maxillary expansion (RME), and an intrusive force was then applied to the miniscrews on the buccal side. The 3.5 mm anterior open bite was corrected after 5 months of intrusion. As a result, a harmonious facial profile was achieved by a closing mandibular rotation.

**KEY WORDS:** Molar intrusion; Open bite correction; Anchorage; Miniscrew; Nonextraction treatment

### INTRODUCTION

An anterior open bite is considered to be one of the most difficult problems to treat in orthodontics. In conventional orthodontic treatment, various treatment modalities for the correction of an anterior open bite have been proposed such as extrusion of the anterior teeth using intermaxillary elastics,<sup>1,2</sup> the uprighting of molars using a multi-loop edgewise arch wire (MEAW),<sup>3-5</sup> and inhibition of molar eruption during growth.<sup>6,7</sup> However, none of these methods are satisfactory due to detrimental effects on the skeletal/esthetic pattern and a strong tendency for relapse.

Another treatment option is the repositioning of both the maxilla and mandible through a surgical correction.<sup>8-10</sup> Although satisfactory results can be achieved by orthognathic surgery, the complexity, risks, and costs of surgery have initiated a search for alternative treatments.

With the absolute intrusion of the posterior teeth, it is possible to autorotate the mandible in a closing counterclockwise direction, close the open bite, and reduce the anterior facial height without the need for surgical intervention.

It has been reported<sup>11</sup> that intrusion provides a more

stable treatment result than extrusion. Since the tendency for relapse is higher in adults,<sup>12</sup> it is important to choose both a stable and predictable treatment method.

This can be accomplished using temporary anchorage devices such as osseointegrated implants,<sup>13-18</sup> miniplates,<sup>19-21</sup> onplants,<sup>22,23</sup> and miniscrews.<sup>24-27</sup> Miniscrews have many advantages over other various temporary anchorage devices. Miniscrews are relatively simple and easy to insert, less traumatic, stable for the optimal force, and make it possible to apply a force immediately after insertion. Other advantages include fewer limitations of the implantation site and lower costs. This article presents a case report of an open bite correction using miniscrews.

### Diagnosis and Etiology

A 19-year-old woman visited our clinic complaining of an anterior open bite. She had a finger-sucking habit in the past, which might have influenced the opening situation. In the lateral profile, a retruded mandibular posture was observed (Figure 1).

The intraoral examination presented a Class I canine and molar position on both sides with a 3.5 mm anterior open bite. The upper denture midline was consistent with the facial midline, while the lower denture midline was 1.0 mm off to the left side. There were two different occlusal planes between posterior and anterior teeth (Figure 2). Cast analysis revealed 6.0 mm of crowding in the upper and 5.0 mm of crowding in the lower dentition. A 3.5 mm anterior open bite was visible and there was no occlusal contact from the first premolar on the left to the first premolar on the right (Figure 3).

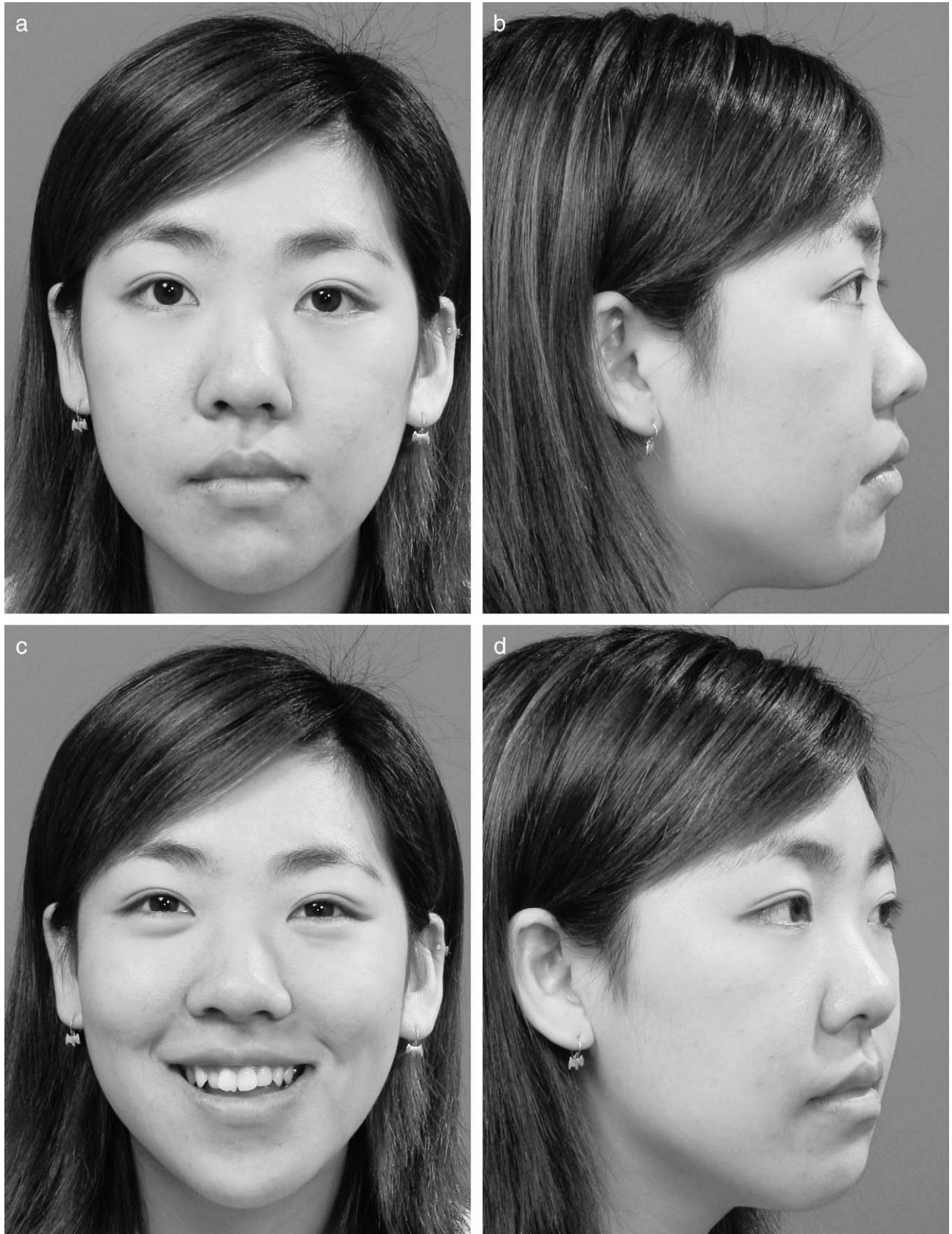<sup>a</sup> Professor, Department of Orthodontics, College of Dentistry, Yonsei University, Seoul, South Korea.

<sup>b</sup> Resident, Department of Orthodontics, College of Dentistry, Yonsei University, Seoul, South Korea.

Corresponding author: Dr Young-Chel Park, Department of Orthodontics, College of Dentistry, Yonsei University, 134 Shinchon-dong, Seodaemun-gu, Seoul, 120-752, South Korea (e-mail: ypark@yumc.yonsei.ac.kr)

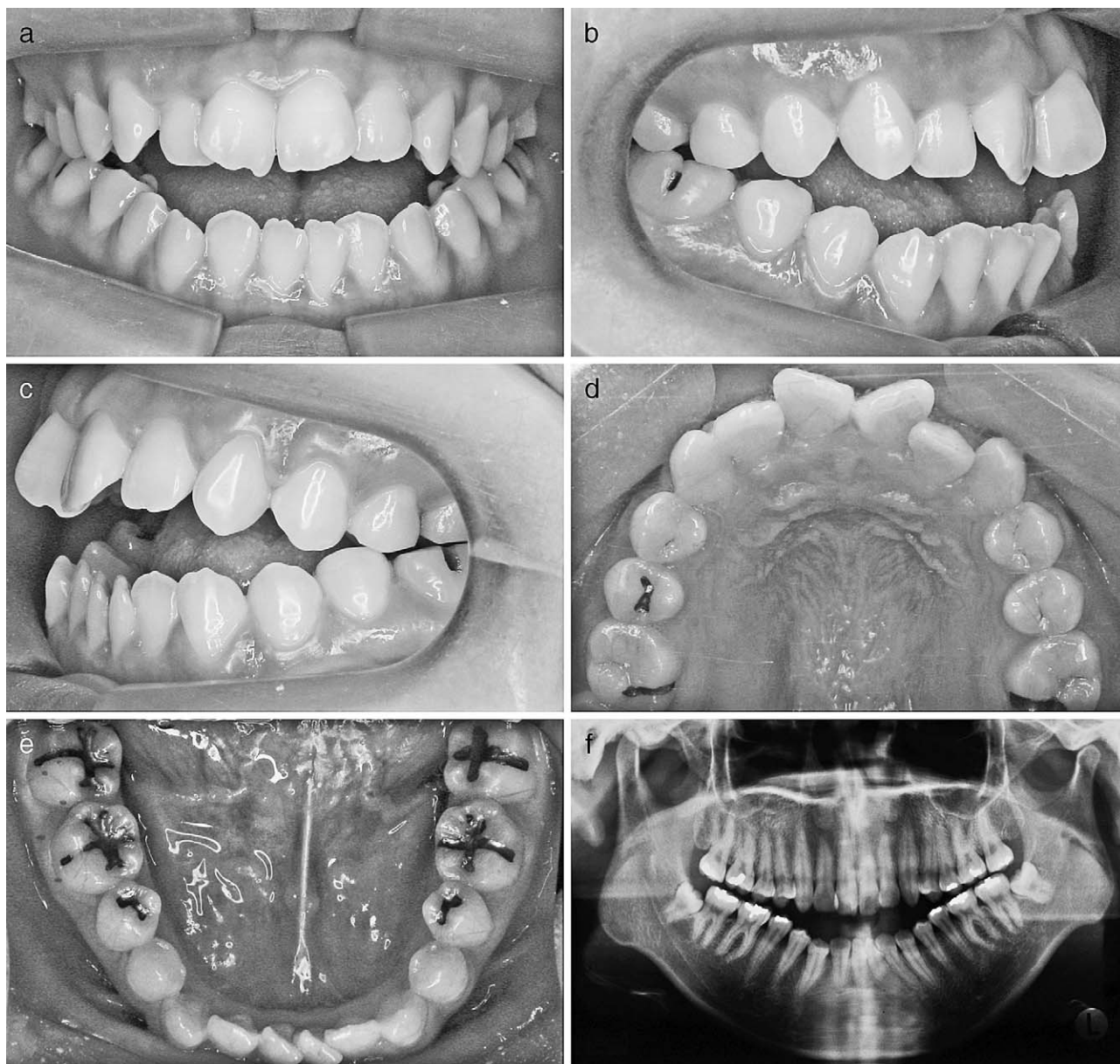
Accepted: March 2007. Submitted: December 2006.

© 2008 by The EH Angle Education and Research Foundation, Inc.



**Figure 1.** Pretreatment extraoral photographs.





**Figure 2.** Pretreatment intraoral photographs and radiograph.

Cephalometric analysis (Table 1) revealed a large ANB ( $5.6^\circ$ ), and a small APDI ( $79.33^\circ$ ) indicating a Class II anterior-posterior relationship. The steep mandibular plane angle (SN-GoMe) ( $51.3^\circ$ ), the large sum ( $409.99^\circ$ ), the small facial height ratio ( $59.7^\circ$ ), and the large FMA ( $40.6^\circ$ ) exhibited a backward and downward rotation of the mandible, suggesting a long anterior facial height. The upper incisor inclination was upright (U1 to SN:  $96.5^\circ$ ). The upper molars were significantly extruded compared with the normal range (U6 to PP: 31.0 mm) (Figure 4). The mandibular rotation suggested a Class II anterior-posterior relationship, but the patient's condition was diagnosed as skeletal Class I with an anterior open bite.

### Treatment Objectives

Four treatment objectives were identified: (1) correction of the open bite, (2) improvement in the facial profile, (3) establishment of a proper overjet and overbite, and (4) relief of crowding.

### Treatment Alternatives

The first treatment option was orthognathic surgery with maxillary posterior impaction. Although this can correct the jaw rotations and reduce the anterior facial height, it has disadvantages in being more expensive and carries a greater risk of surgery. The patient re-

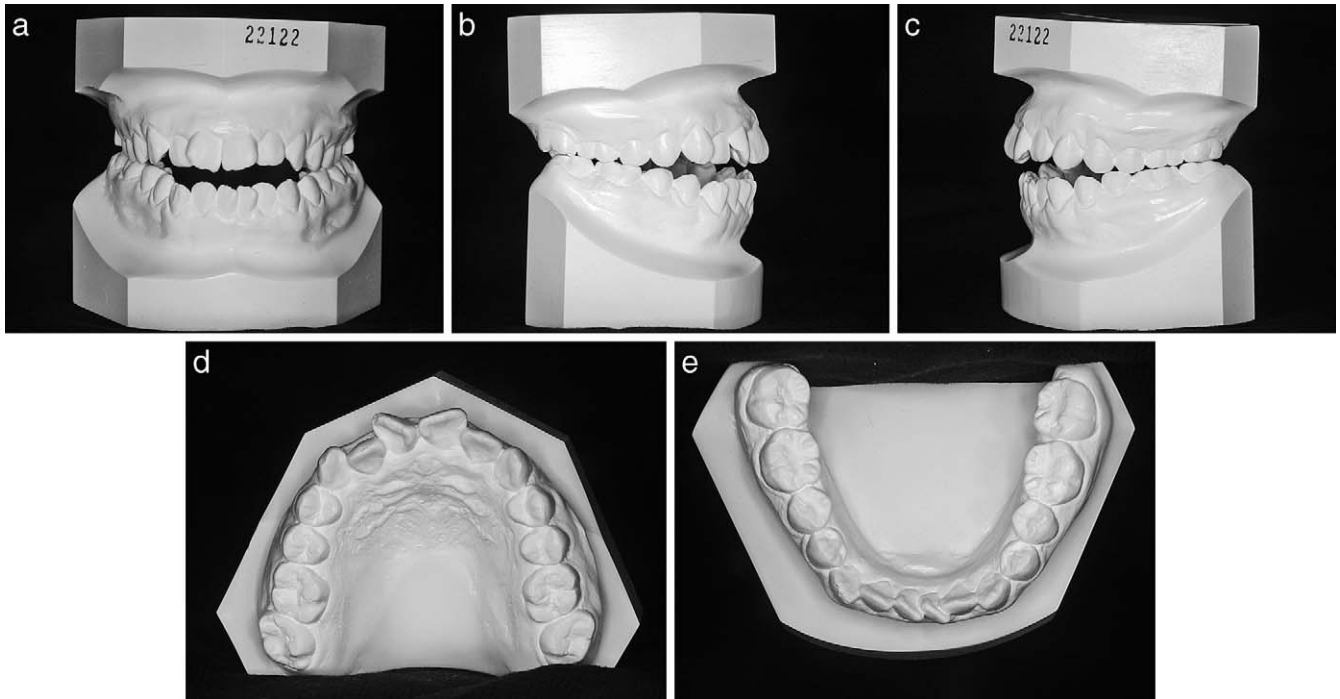


Figure 3. Pretreatment cast photographs.

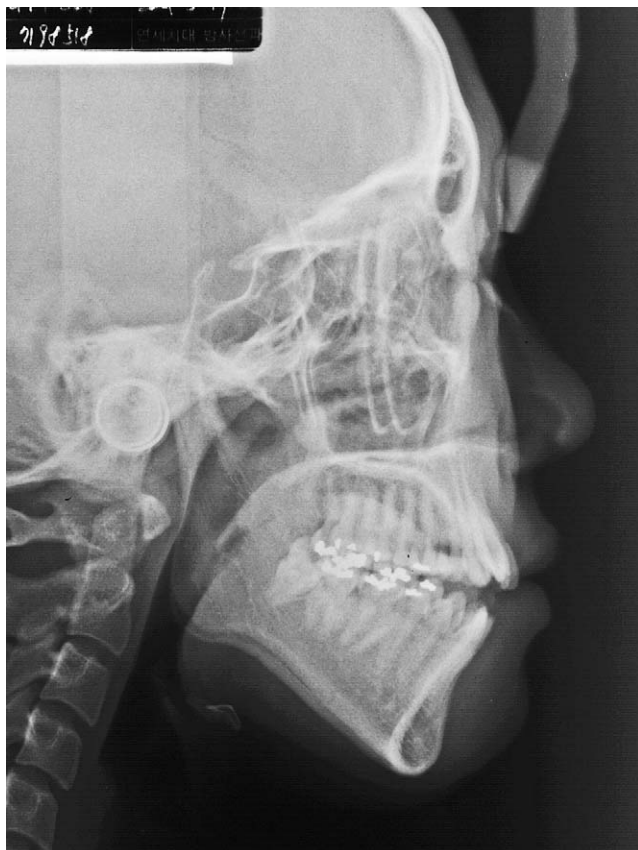

Figure 4. Pretreatment cephalogram.

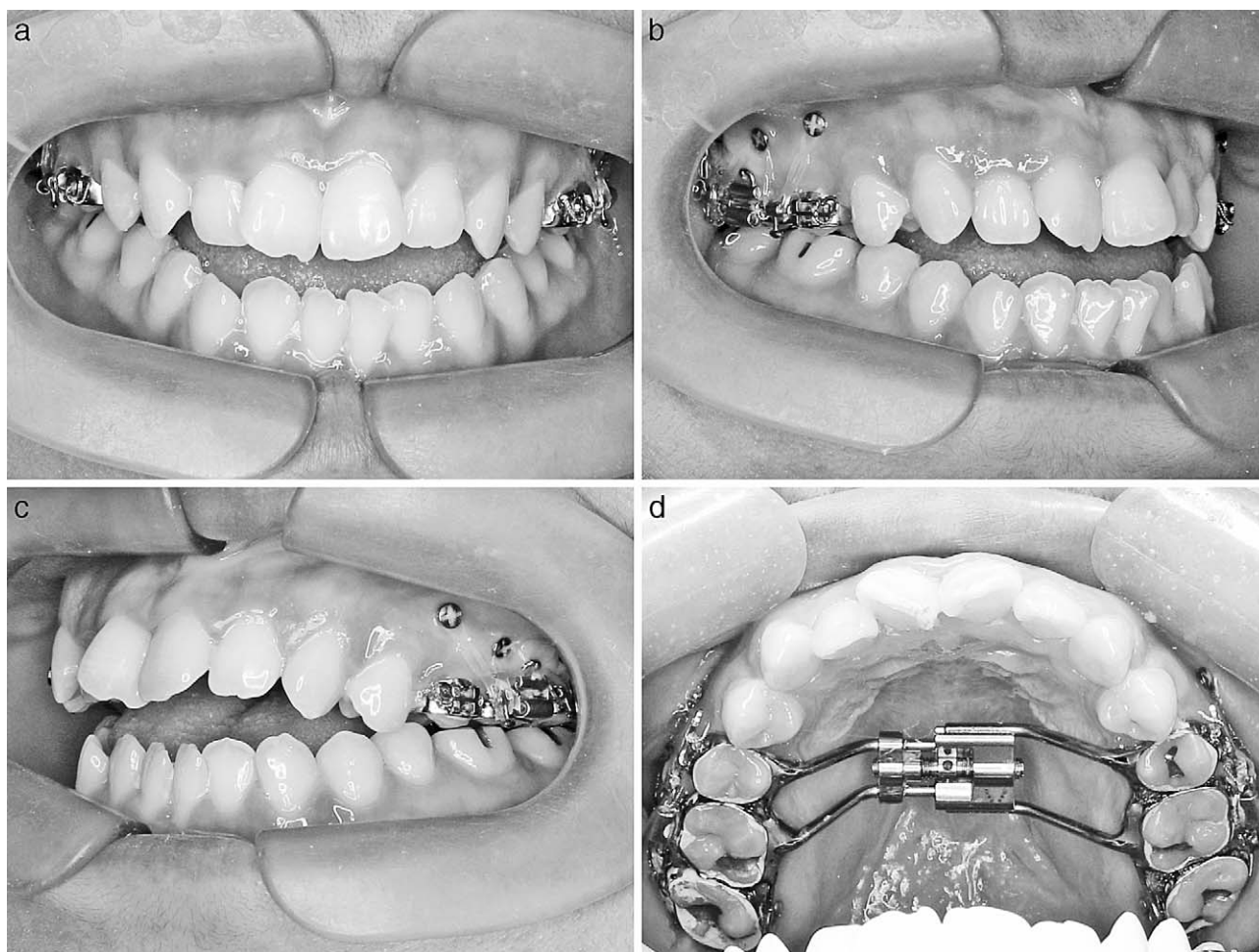
fused orthognathic surgery due to high cost and the risk of surgery.

The second treatment option was intrusion of the posterior teeth using miniscrews to correct the anterior open bite. Miniscrews have a lower surgical burden and cause less discomfort to the patient, making them easier to implant. This patient had two different occlusal planes. Therefore, molar intrusion was considered to be the best treatment choice because it leads to an autorotation of the mandible in the counterclockwise direction, thus improving the long anterior facial height. For the upper molar intrusion, implantation of miniscrews to the buccal side of the maxilla was planned.

Table 1. Cephalometric Measurements

|                             | Pretreatment | Posttreatment | Retention<br>1 year |
|-----------------------------|--------------|---------------|---------------------|
| SNA (°)                     | 76.9         | 76.7          | 76.1                |
| SNB (°)                     | 71.3         | 72.7          | 72.8                |
| ANB difference (°)          | 5.6          | 4.0           | 3.3                 |
| Anterior facial height (mm) | 146.1        | 140.4         | 143.1               |
| Facial height ratio (%)     | 59.7         | 59.4          | 60.2                |
| SN-GoMe (°)                 | 51.3         | 49.7          | 48.4                |
| Sum (°)                     | 409.9        | 409.7         | 408.4               |
| FMA (°)                     | 40.6         | 36.1          | 36.0                |
| ODI                         | 69.4         | 63.0          | 64.7                |
| APDI                        | 79.3         | 80.6          | 81.5                |
| U1 to SN (°)                | 96.5         | 100.7         | 100.7               |
| IMPA (°)                    | 89.0         | 85.9          | 92.4                |
| Upper lip to E-line (mm)    | -0.3         | 2.5           | 2.0                 |
| Lower lip to E-line (mm)    | 0.5          | 2.9           | 3.6                 |
| WITS (mm)                   | -4.4         | -4.4          | -3.7                |





**Figure 5.** Intraoral photographs with rapid maxillary expansion (RME) and the application of an intrusive force on the buccal miniscrew.

### Treatment Progress

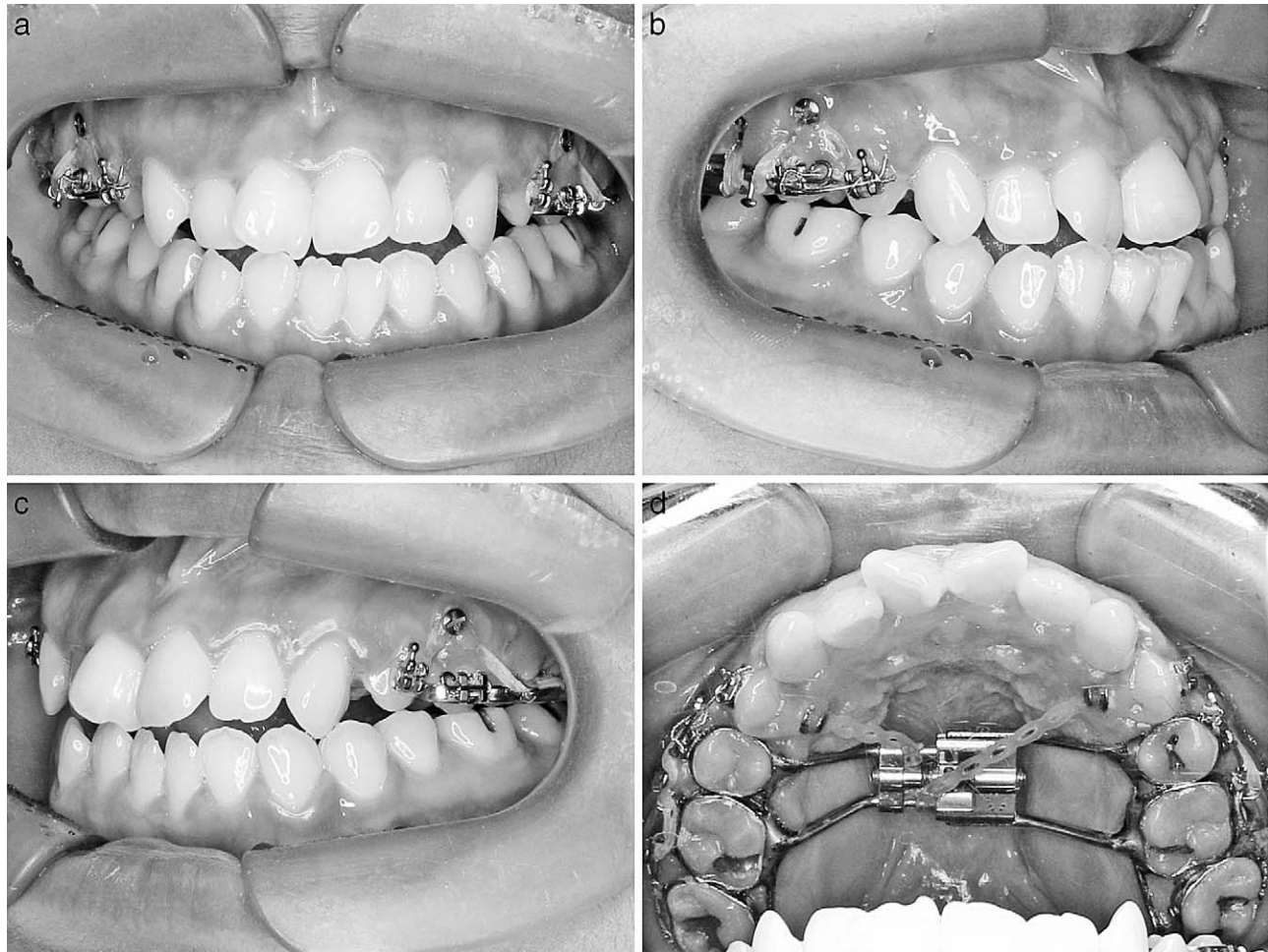
The patient required maxillary expansion. Therefore, a rapid maxillary expansion (RME) appliance was first applied. After sufficient expansion had been accomplished, miniscrews (Martin, Tuttlingen, Germany), 2 mm in diameter and 8 mm in length, were placed on the buccal alveolar bone between the first bicuspid and second bicuspid, between the second bicuspid and first molar, and between the first molar and second molar. The RME was maintained as a palatal splint to prevent buccal tipping of the posterior teeth while an intrusive force was applied to the buccal side. Elastomeric chains were used to apply the intrusion force, and the force magnitude was approximately 150–200 grams on each tooth (Figure 5). After 5 months, the molar intrusion was accomplished and the anterior open bite was corrected (Figure 6).

Intrusion of the maxillary posterior teeth resulted in mandibular autorotation, and the molar relationship was overcorrected to a Class III relationship. Brackets were bonded to the anterior teeth to level and align

the mild crowding. After 9 months, the leveling and alignment were complete, and Class III elastics were used to correct the shallow overjet. The treatment was complete after 21 months with a normal overjet and overbite. After treatment, lingual canine to canine retainers were bonded in the maxillary and mandibular arch. The patient was instructed to use a circumferential retainer (Figure 7).

### RESULTS

After treatment, the patient had a normal overbite (1.5 mm) and overjet (2.5 mm) relationship and a stable occlusion, a Class I canine and molar relationship, as well as a consonant midline. The cephalometric superimposition showed maxillary molar intrusion (2.0 mm) and simultaneous counterclockwise rotation of the mandible (Figure 8). As a consequence, the ANB difference, APDI, and Wits were corrected to within the normal range, and the FMA was reduced from 41° to 36°. The patient's anterior facial height was reduced from 146 mm to 140 mm, and a retruded chin greatly



**Figure 6.** After molar intrusion, the open bite was closed.

improved the now harmonious facial profile (Figure 9). Dentally, the U1 to SN was flared to the labial, and IMPA was inclined to the lingual for the compensating mandibular autorotation. After 1 year of retention, the FMA, APDI, and WITS were maintained. As the IMPA moved towards the normal range, the overbite opened slightly and the patient was instructed to pay close attention to the tongue posture (Figure 10). After 3 years of retention, the good occlusion and normal overbite and overjet were well maintained (Figure 11).

## DISCUSSION

In conventional orthodontics, molar intrusion for an open bite correction is one of the most difficult objectives, and is always accompanied with unwanted side effects. Subtelny and Sakuda<sup>28</sup> previously stated that, "If a real skeletal open bite is evident, then treatment may be impossible. To reiterate, in some cases the best treatment may be not to attempt orthodontic therapy." The advent of miniscrews has expanded orthodontic treatment beyond limited teeth movement, and

now this statement can be considered only partially true. The results of this case show that molar intrusion had been accomplished successfully using miniscrews without any major surgical involvement to correct the open bite.

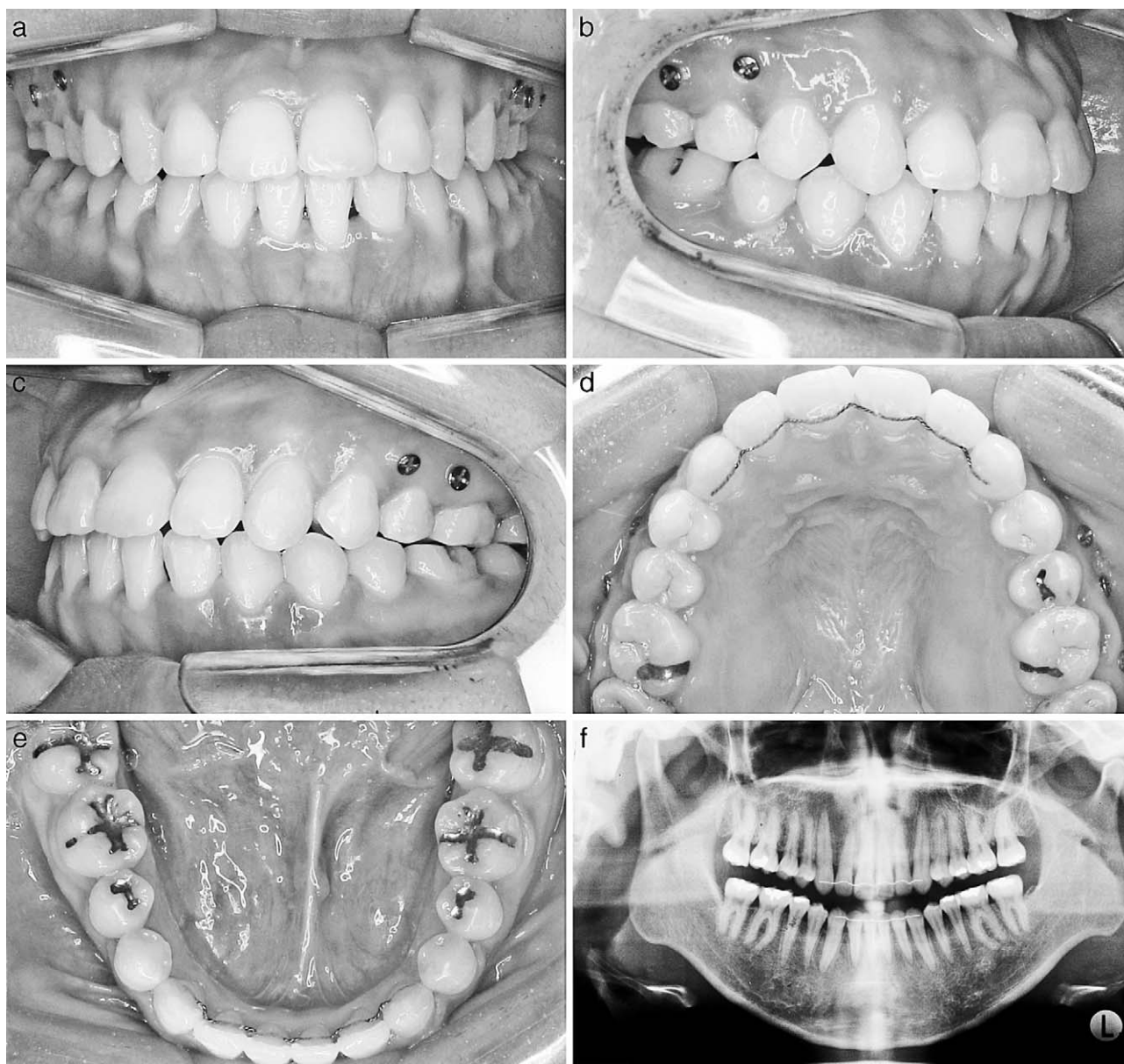
Using posterior segmental intrusion, there are advantages in both effectiveness and esthetics. If we want to accomplish intrusion using the continuous arch technique, unwanted tooth movement as well as posterior intrusion would also occur.

Posterior segment splinting allows the application of a more direct and efficient force. Appliances do not need to be bonded to the anterior segment during intrusion, making a more esthetic treatment possible.

Although molar intrusion using miniscrews is an effective treatment modality for an open bite correction, it is not a universal method for all types of open bite. Therefore, a prudent diagnosis and treatment plan is of utmost importance.

The first aspect to consider is the skeletal relationship including the vertical, transverse, and anterior-





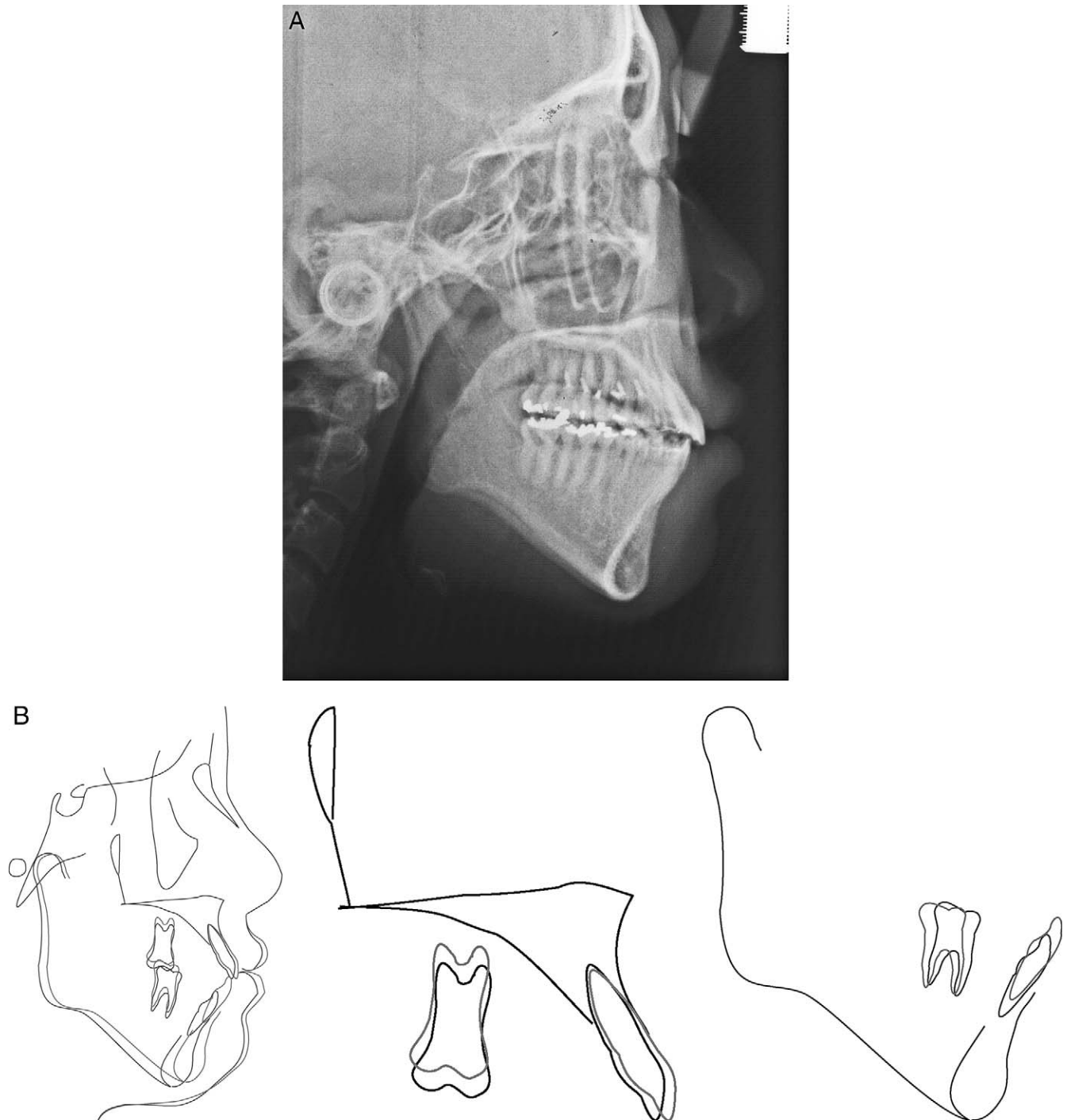
**Figure 7.** Posttreatment intraoral photographs, radiograph.

posterior relations. For example, a skeletal Class II open bite with a long anterior facial height can be treated successfully by the intrusion of the posterior teeth. This would produce a closing counterclockwise rotation of the mandible with a shortening of the anterior facial height and a correction of the open bite. Sugawara et al<sup>20</sup> reported that during intrusion of the molars with SAS, the anterior lower facial height, mandibular plane angle, and ANB difference were reduced significantly, whereas the overbite and Wits appraisal increased significantly. Therefore, the intrusion of the molars appears to be the most rational treatment procedure for skeletal open bite patients who show long

face types with skeletal Class I or mild skeletal Class II jaw relationships.

In the case of a skeletal Class III open bite, the counterclockwise rotation by an intrusion of the posterior teeth would worsen the Class III relationship despite the open bite correction, making orthognathic surgery necessary.

The second aspect to consider is the facial esthetics because a patient's expectation for esthetic improvement is increasing continuously. Incisor exposure at rest and smile are important objectives to consider before treatment. Patients who do not show sufficient incisor exposure should not be treated by molar intrusion, making



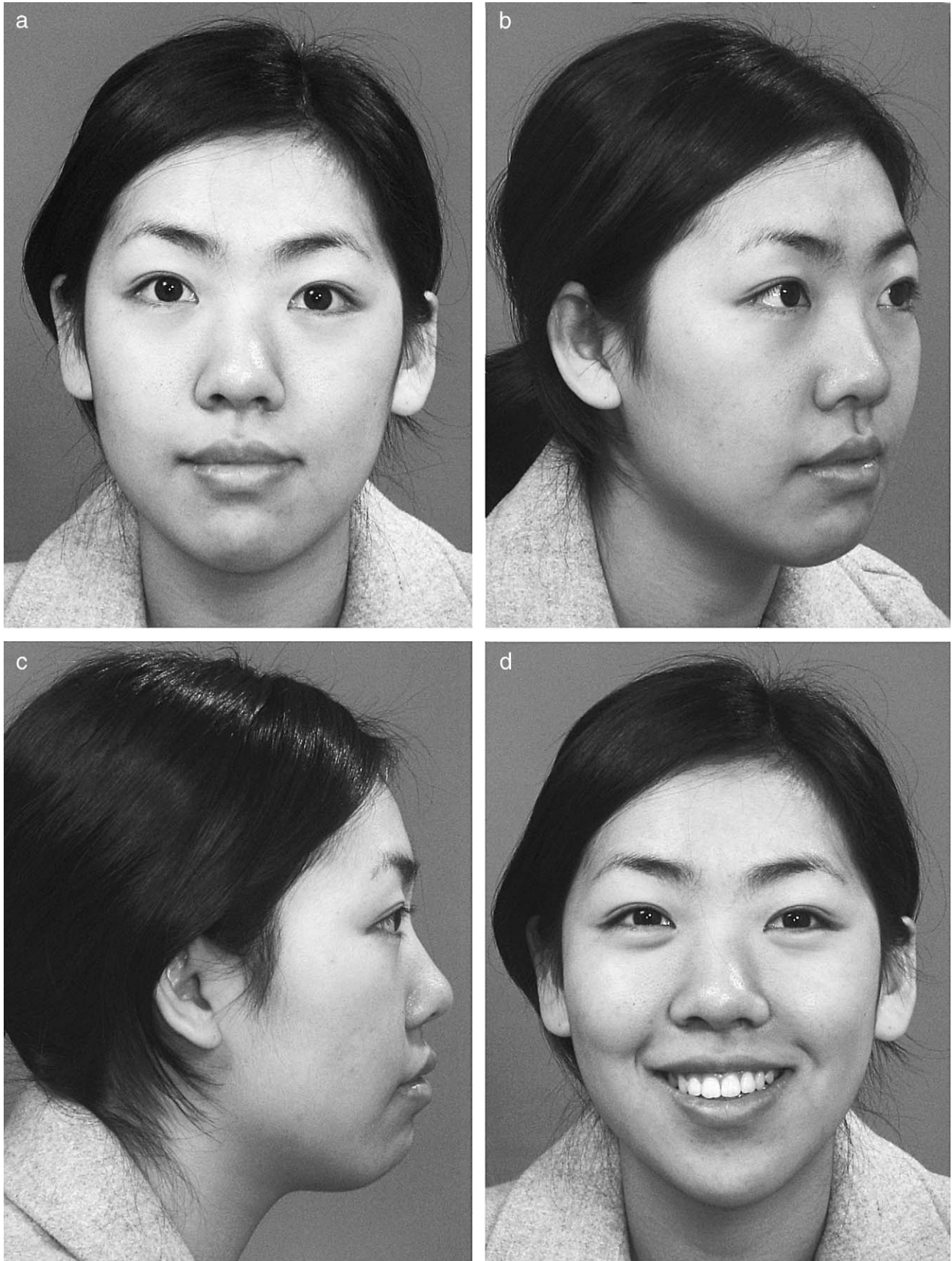**Figure 8.** (A) Posttreatment cephalogram. (B) Pretreatment and posttreatment cephalometric superimposition.

the more conventional method of incisor extrusion a more suitable option for open bite correction.

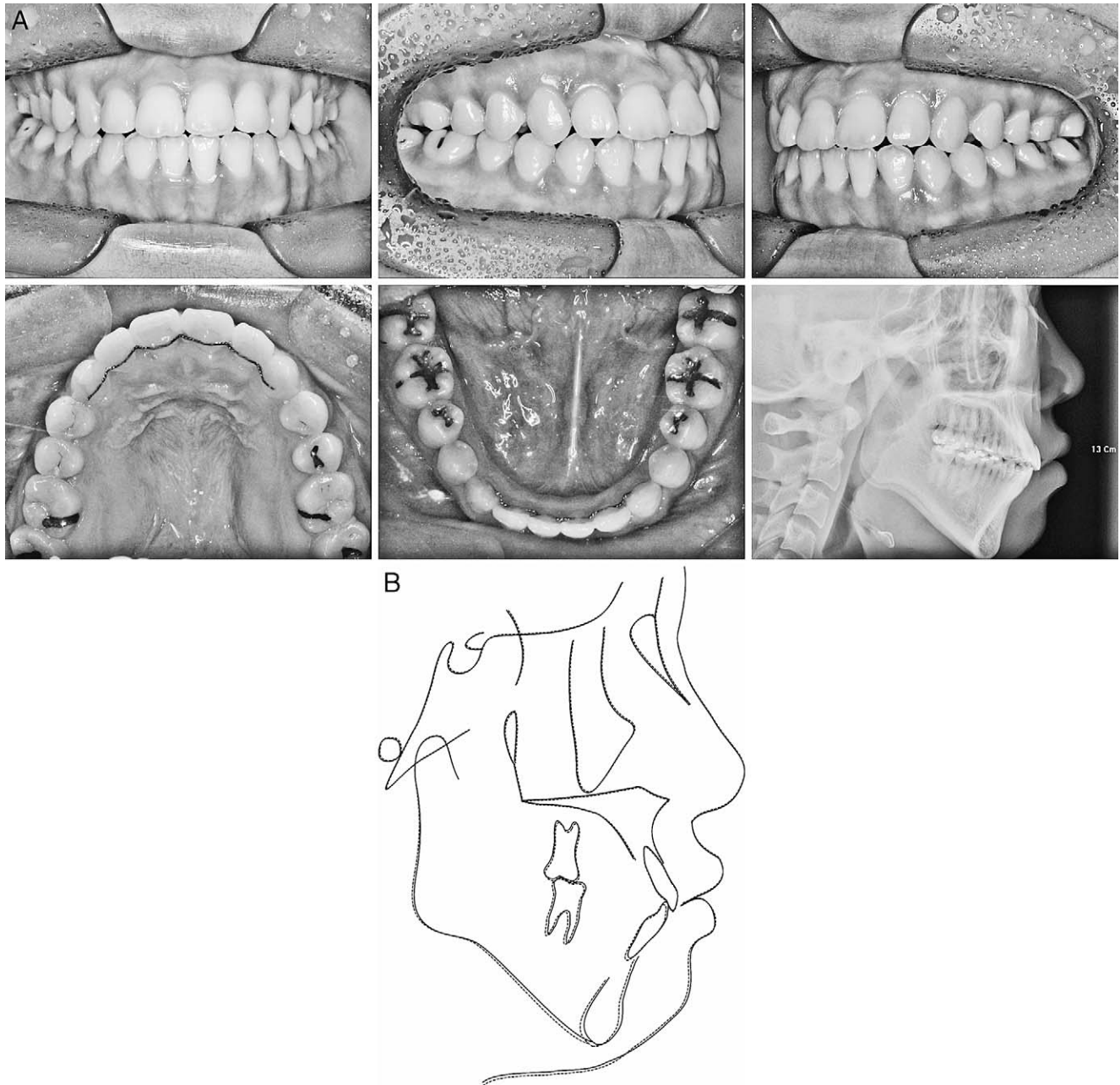
Third, during the active intrusion phase, careful monitoring is essential for a successful treatment outcome. The first, second, and third order relationship of the intruded molars should be monitored. In the case of segmental force application, the in and out position (first order) of molars and the archform integrity are

difficult to maintain, making careful monitoring quite important. In terms of the mesial distal angulation (second order), control of the intruded molars is important because anterior bite closure is more effective the closer the teeth are intruded to the hinge axis. Posterior torque (third order) control is the most important factor for molar intrusion. For a pure intrusion of molars, the force should be applied from both the buccal





**Figure 9.** Posttreatment extraoral photographs.



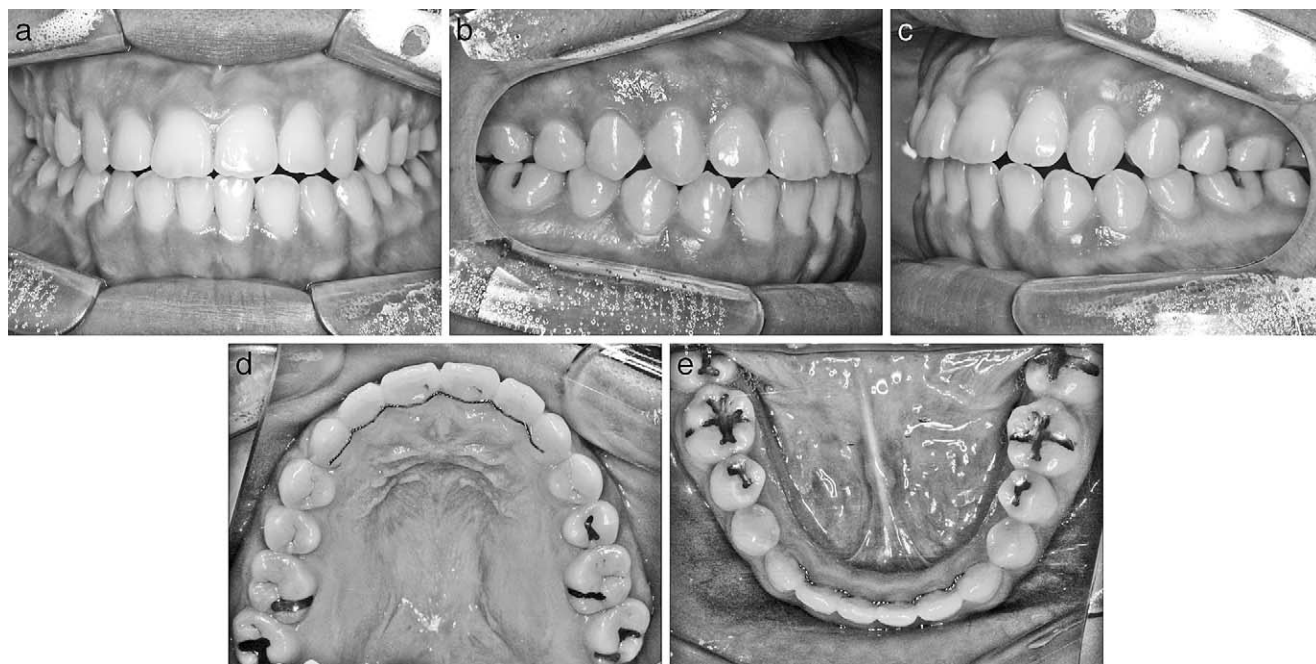
**Figure 10.** (A) One-year retention intraoral photographs, cephalogram. (B) Posttreatment and 1-year retention cephalometric superimposition.

and palatal direction. The implantation of miniscrews on both the buccal and palatal sides can be considered force application from both sides. In our case a RME was used for expansion purposes prior to intrusion. Therefore, miniscrew implantation was done only on the buccal side, using the RME as a cross-arch stabilizing appliance in order to prevent a buccal tipping effect. As shown by the treatment results, this method was successful.

The fourth aspect to consider carefully is the periodontal condition. Regarding the intrusion of molars with periodontal disease, Melsen et al<sup>29</sup> reported that

the periodontal tissue recovers by new attachment through intrusion, whereas Vanarsdall<sup>30</sup> suggested that for the health of the periodontal tissue, the tooth should be extruded rather than intruded, because bone deposition can occur with tension rather than with pressure. In patients with slight periodontal disease, adequate periodontal treatment is essential before undergoing any orthodontic treatment, and periodic periodontal management and radiographs should be taken during treatment. Surgical intervention is the first treatment objective for open bite correction if the periodontal condition is unsuitable for molar intrusion.





**Figure 11.** Three-year retention intraoral photographs.

In regard to the posttreatment stability, molar intrusion still has a 30% relapse rate.<sup>20</sup> In addition, over-correction is suggested to compensate for any relapse.

## CONCLUSIONS

- Intrusion of the posterior teeth is a good treatment method for patients with a chief complaint of an anterior open bite. Intrusion was accomplished successfully with miniscrews implanted on the buccal side only; there were no side effects.

## ACKNOWLEDGMENT

This paper was supported by 2006 Yonsei University Dental College research fund and Craniofacial Deformity Center.

## REFERENCES

1. Rinchuse DJ. Vertical elastics for correction of anterior open bite. *J Clin Orthod.* 1994;28:284.
2. Kucukkeles N, Acar A, Demirkaya AA, Evrenol B, Enacar A. Cephalometric evaluation of open bite treatment with NiTi arch wires and anterior elastics. *Am J Orthod Dentofacial Orthop.* 1999;116:555–562.
3. Kim YH. Anterior openbite and its treatment with multiloop edgewise archwire. *Angle Orthod.* 1987;57:290–321.
4. Huang GJ, Drangsholt M. Stability of anterior open bite correction with MEAW. *Am J Orthod Dentofacial Orthop.* 2001; 119:14A.
5. Endo T, Kojima K, Kobayashi Y, Shimooka S. Cephalometric evaluation of anterior open-bite nonextraction treatment, using multiloop edgewise archwire therapy. *Odontology.* 2006;94:51–58.
6. Kuster R, Ingervall B. The effect of treatment of skeletal open bite with two types of bite-blocks. *Eur J Orthod.* 1992; 14:489–499.
7. Gurton AU, Akin E, Karacay S. Initial intrusion of the molars in the treatment of anterior open bite malocclusions in growing patients. *Angle Orthod.* 2004;74:454–464.
8. Swinnen K, Politis C, Willems G, et al. Skeletal and dentoalveolar stability after surgical-orthodontic treatment of anterior open bite: a retrospective study. *Eur J Orthod.* 2001; 23:547–557.
9. Epker BN, Fish L. Surgical-orthodontic correction of openbite deformity. *Am J Orthod.* 1977;71:278–299.
10. Bell WH, Creekmore TD, Alexander RG. Surgical correction of the long face syndrome. *Am J Orthod.* 1977;71:40–67.
11. Reitan K. Biomechanical principles and reactions. In: Graber TM, Vanarsdall RL, eds. *Orthodontics-Current Principles and Techniques.* 2nd ed. Place of publication: Mosby; 1994:168–169.
12. Kahl-Nieke B. Retention and stability considerations for adult patients. *Dent Clin North Am.* 1996;40:961–994.
13. Kato S, Kato M. Intrusion of molars with implants as anchorage: a report of two cases. *Clin Implant Dent Relat Res.* 2006;8:100–106.
14. Roberts WE, Engen DW, Schneider PM, Hohlt WF. Implant-anchored orthodontics for partially edentulous malocclusions in children and adults. *Am J Orthod Dentofacial Orthop.* 2004;126:302–304.
15. Goodacre CJ, Brown DT, Roberts WE, Jeiroudi MT. Prosthodontic considerations when using implants for orthodontic anchorage. *J Prosthet Dent.* 1997;77:162–170.
16. Roberts WE, Arbuckle GR, Analoui M. Rate of mesial translation of mandibular molars using implant-anchored mechanics. *Angle Orthod.* 1996;66:331–338.
17. Roberts WE, Nelson CL, Goodacre CJ. Rigid implant anchorage to close a mandibular first molar extraction site. *J Clin Orthod.* 1994;28:693–704.
18. Roberts WE, Marshall KJ, Mozsary PG. Rigid endosseous implant utilized as anchorage to protract molars and close an atrophic extraction site. *Angle Orthod.* 1990;60:135–152.

19. Erverdi N, Keles A, Nanda R. The use of skeletal anchorage in open bite treatment: a cephalometric evaluation. *Angle Orthod.* 2004;74:381–390.
20. Sugawara J, Baik UB, Umemori M, Takahashi I, Nagasaka H, Kawamura H, Mitani H. Treatment and posttreatment dentoalveolar changes following intrusion of mandibular molars with application of a skeletal anchorage system (SAS) for open bite correction. *Int J Adult Orthodon Orthognath Surg.* 2002;17:243–253.
21. Sherwood KH, Burch JG, Thompson WJ. Closing anterior open bites by intruding molars with titanium miniplate anchorage. *Am J Orthod Dentofacial Orthop.* 2002;122:593–600.
22. Wehrbein H, Feifel H, Diedrich P. Palatal implant anchorage reinforcement of posterior teeth: a prospective study. *Am J Orthod Dentofacial Orthop.* 1999;116:678–686.
23. Wehrbein H, Merz BR. Aspects of the use of endosseous palatal implants in orthodontic therapy. *J Esthet Dent.* 1998;10:315–324.
24. Xun C, Zeng X, Wang X. Microscrew anchorage in skeletal anterior open-bite treatment. *Angle Orthod.* 2007;77:47–56.
25. Ko DI, Lim SH, Kim KW. Treatment of occlusal plane canting using miniscrew anchorage. *World J Orthod.* 2006;7:269–278.
26. Lee JS, Kim DH, Park YC, Kyung SH, Kim TK. The efficient use of midpalatal miniscrew implants. *Angle Orthod.* 2004;74:711–714.
27. Park YC, Lee SY, Kim DH, Jee SH. Intrusion of posterior teeth using mini-screw implants. *Am J Orthod Dentofacial Orthop.* 2003;123:690–694.
28. Subtelny JD, Sakuda M. Openbite: diagnosis and treatment. *Am J Orthod Dentofacial Orthop.* 1964;50:337–358.
29. Melsen B, Agerbaek N, Eriksen J, Terp S. New attachment through periodontal treatment and orthodontic intrusion. *Am J Orthod Dentofacial Orthop.* 1988;94:104–116.
30. Vanarsdall RL. Orthodontics and periodontal therapy. *Periodontol* 2000. 1995;9:132–149.