

## Spatial Relationships between the Mandibular Central Incisor and Associated Alveolar Bone in Adults with Mandibular Prognathism

Chiaki Yamada<sup>a</sup>; Noriyuki Kitai<sup>b</sup>; Naoya Kakimoto<sup>c</sup>; Shumei Murakami<sup>d</sup>; Souhei Furukawa<sup>e</sup>; Kenji Takada<sup>f</sup>

### ABSTRACT

**Objective:** To examine if there was any correlation between the labio-lingual inclinations of the mandibular central incisor and the associated alveolar bone, and to investigate the labio-lingual position of the mandibular central incisor root apex in the associated cancellous bone in adults with untreated mandibular prognathism.

**Materials and Methods:** High-resolution computed tomography images of the mandible were recorded in 20 adult patients with mandibular prognathism. The labio-lingual inclinations of a central incisor and its associated alveolar bone, the thickness of the associated cancellous bone, and the distance from the central incisor root apex to the inner contour of both the labial and lingual cortical plates were measured. Correlations and differences between the measured variables were tested for statistical significance.

**Results:** The labio-lingual inclination of the central incisor significantly correlated with the labio-lingual inclination of the associated alveolar bone, the thickness of cancellous bone, and the distance from the central incisor root apex to the inner contour of the lingual cortical bone. The distance from the central incisor root apex to the inner contour of the labial cortical plate of bone was significantly smaller than that to the lingual cortical plate.

**Conclusions:** In adults with untreated mandibular prognathism, when the mandibular central incisor was more lingually inclined, the associated alveolar bone was also more lingually inclined and thinner. The mandibular central incisor root apex was closer to the inner contour of the labial cortical bone than to the lingual cortical bone.

**KEY WORDS:** Alveolar bone; Mandibular symphysis; Mandibular prognathism; Computed tomography (CT)

---

<sup>a</sup> Assistant Professor, Department of Orthodontics and Dentofacial Orthopedics, Osaka University, Osaka, Japan.

<sup>b</sup> Professor and Department Chair, Orthodontic Department, Asahi University, Gifu, Japan.

<sup>c</sup> Assistant Professor, Department of Oral and Maxillofacial Radiology, Graduate School of Dentistry, Osaka University, Osaka, Japan.

<sup>d</sup> Associate Professor, Department of Oral and Maxillofacial Radiology, Graduate School of Dentistry, Osaka University, Osaka, Japan.

<sup>e</sup> Professor and Department Chair, Department of Oral and Maxillofacial Radiology, Graduate School of Dentistry, Osaka University, Osaka, Japan.

<sup>f</sup> Professor and Department Chair, Department of Orthodontics and Dentofacial Orthopedics, Osaka University, Osaka, Japan.

Corresponding author: Kenji Takada, DDS, PhD, Dean, Graduate School of Dentistry, Osaka University, 1-8 Yamadaoka, Suita, Japan  
(e-mail: ktakada@dent.osaka-u.ac.jp)

Accepted: October 2006. Submitted: July 2006.

© 2007 by The EH Angle Education and Research Foundation, Inc.

### INTRODUCTION

Mandibular prognathism, a gross skeletal deformity of the craniofacial area, is frequently seen in the Japanese population.<sup>1</sup> As reported in previous studies, some of these patients have lingually inclined mandibular incisors.<sup>2-4</sup> For patients with a skeletal Class III jaw base relationship and lingually inclined mandibular incisors, there are two treatment options. One is orthodontic treatment combined with orthognathic surgery to correct the skeletal discrepancy, and the other is orthodontic camouflage of the skeletal discrepancy. In surgical orthodontic treatment, a frequent objective of presurgical orthodontic treatment is to tip the lingually inclined mandibular incisors labially to facilitate a more favorable postsurgical result.<sup>3</sup> In orthodontic camouflage of the skeletal discrepancy, more lingual tipping of the mandibular incisors is required.<sup>5</sup>

The antero-posterior thickness of the alveolar bone in the incisor region has been reported to be thin in

**Table 1.** Cephalometric Measurements (N = 20)

Variable	Mean $\pm$ SD	Minimum	Maximum	Normative Mean $\pm$ SD (Japanese Male Adult)	Normative Mean $\pm$ SD (Japanese Female Adult)
S-N, (mm)	71.7 $\pm$ 3.9	69.5	79.4	72.2 $\pm$ 3.3	67.9 $\pm$ 3.7
SNA, ( $^{\circ}$ )	80.8 $\pm$ 3.9	75.7	88.2	81.5 $\pm$ 3.3	80.8 $\pm$ 3.6
SNB, ( $^{\circ}$ )	82.8 $\pm$ 4.6	75.0	90.6	78.2 $\pm$ 4.0	77.9 $\pm$ 4.5
ANB, ( $^{\circ}$ )	-2.0 $\pm$ 2.4	-7.9	0.7	3.2 $\pm$ 2.4	2.8 $\pm$ 2.4
Mp to FH, ( $^{\circ}$ )	31.7 $\pm$ 5.2	21.9	38.2	28.0 $\pm$ 6.1	30.5 $\pm$ 3.6
FMIA, ( $^{\circ}$ )	65.6 $\pm$ 10.1	44.6	83.3	56.7 $\pm$ 7.8	56.0 $\pm$ 8.1
IMPA, ( $^{\circ}$ )	82.7 $\pm$ 10.0	66.0	97.2	95.2 $\pm$ 6.2	93.4 $\pm$ 6.8

mandibular prognathism,<sup>2-4</sup> and the distance available for orthodontic movement of the incisor seems to be small. Given that the incisor root apex is frequently close to the cortical bone surface, considerable amount of orthodontic changes in mandibular incisor inclination may not be advisable. It has been shown that if the incisor root apex is moved against the cortical plate of the alveolus or beyond the alveolus, severe root resorption and/or bony dehiscence may occur.<sup>6,7</sup> It is important, therefore, to evaluate the precise position of the mandibular incisor root apex within the associated alveolar bone before the orthodontic treatment.

The purposes of the present study in adult patients with untreated mandibular prognathism were (1) to investigate whether the associated alveolar bone inclines more lingually with lingual inclination of the mandibular central incisor, (2) to investigate whether the cancellous bone of the associated alveolar bone becomes thinner when the mandibular central incisor inclines more lingually, and (3) to investigate where the mandibular central incisor root apex is located in the cancellous bone of the associated alveolar bone.

The resulting information will increase our understanding of the morphology of the alveolar bone in the mandibular central incisor region as well as provide a basis for the formulation of treatment plans for adults with mandibular prognathism.

## MATERIALS AND METHODS

### Subjects

Twenty Japanese adults (10 men and 10 women; mean age, 23 years 0 months; range, 18 years 7 months to 42 years 3 months) seeking orthodontic treatment because of mandibular prognathism and malocclusion participated in this study. Each was cephalometrically diagnosed as having a skeletal Class III jaw base relationship based on the ANB angle (mean,  $-1.0^{\circ}$ ; range,  $-7.9^{\circ}$  to  $+0.7^{\circ}$ ). ANB angles were smaller than the Japanese normative mean<sup>8</sup> minus 1 standard deviation for healthy adults. Means and ranges of several cephalometric variables are shown in Table 1. The subjects had good general and

dental health, complete or nearly complete dentition, and no history of temporomandibular joint disorders. The subjects gave consent to participate after receiving a full explanation of the aim and design of the study. The study was approved by the Ethical Committee of the Osaka University Graduate School of Dentistry.

### Recording Method

Computed tomography (CT) images of the mandible were recorded for each subject using a multidetector CT scanner (Light Speed QX/I; General Electric Company, Milwaukee, Wis). Scanning planes were parallel to the occlusal plane, and the scanning ranged from the most superior point of the mandibular condyle to menton. Slice thickness was 1.25 mm with no slice gap. The CT images were reconstructed so that their effective slice thickness would be 0.5 mm. The field of view was 15 cm, and the number of matrices was 512 to provide one pixel size of 0.29 mm.

### Data Analyses

CT image data were transferred to a workstation (Advantage Workstation 3.1; General Electric Company) and a graphics computer (O2 workstation; Silicon Graphics, Inc, Mountainview, Calif). From the CT data set, craniofacial skeletal structures were segmented on the basis of a threshold of the CT value, which was determined as 160 Hounsfield units. Volume renderings of the CT data sets were carried out. The volume-rendered images sectioned in the axial, coronal, and sagittal directions were visualized, and several anatomical landmarks were determined visually using a software package (Analyze; Biomedical Imaging Resource, Mayo Clinic and Foundation, Rochester, MN, USA, Table 2).

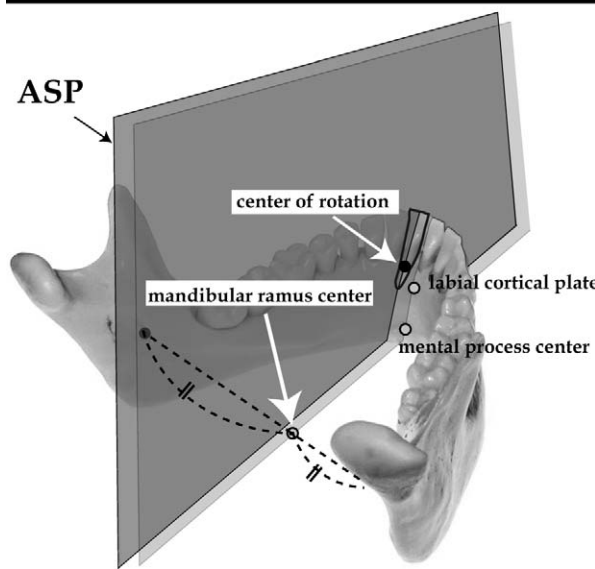
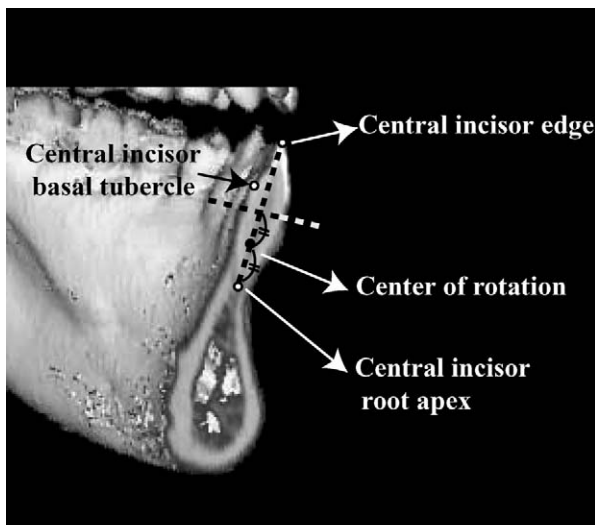
Mandibular incisor and alveolar bone variables in the left central incisor region were defined as follows:

The central incisor midsagittal plane for determining the length of each tooth root was defined as a plane through the points central incisor edge, central incisor root apex, and central incisor basal tubercle.

**Table 2.** Definitions of Dento-mandibular Landmarks

Landmark	Definition
Central incisor edge	Mesio-distal midpoint of the edge of the mandibular central incisor
Central incisor root apex	Apex of the mandibular central incisor root
Central incisor basal tubercle	Most superior point of the basal tubercle of the mandibular central incisor
Center of rotation	Center of the hypothetical rotation of the mandibular central incisor; a midpoint of the embedded portion of the root.
Labial cortical plate	Inner contour of the cortical plate at the labial border of the mandibular symphysis
Mental process center	Center point of the mental process
Mandibular ramus center	Midpoint between bilateral most medio-inferior points of the open site of the mandibular foramen

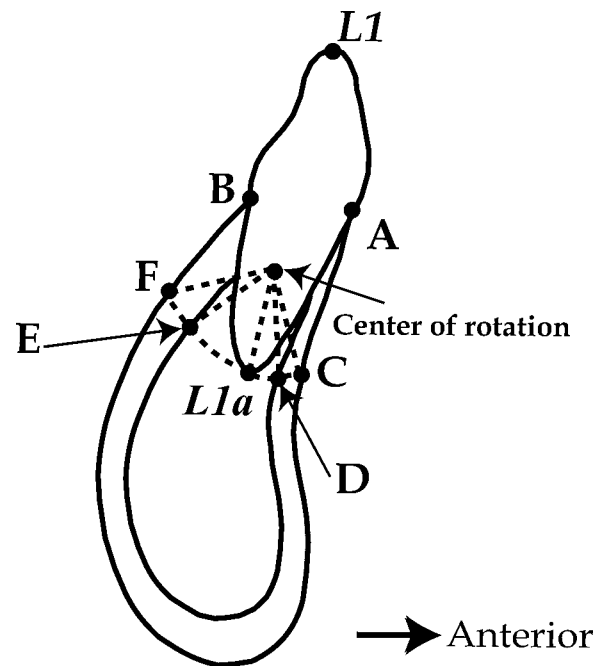
The center of rotation was defined as a midpoint of the embedded portion of the root<sup>9,10</sup> (Figure 1-1). Alveolar bone sagittal plane through the center of rotation (ASP) was defined as a plane that was parallel to a plane through the labial cortical plate, men-



**Figure 1.** (1-1) Definition of the central incisor mid-sagittal plane. (1-2) Definition of the alveolar bone sagittal plane through the center of rotation (ASP).

tal process center, and mandibular ramus center (Figure 1-2).

The landmarks on the ASP are shown in Figure 2. Points A and B were defined as the most antero-superior point and the most postero-superior point of the mandibular alveolar bone, respectively. Points C, D, E, and F were defined on the trajectory of the hypothetical tipping movement of the mandibular central incisor root around the center of rotation. Points C and F were defined as the most anterior point and the most posterior point of the mandibular alveolar bone, respectively. Points D and E were defined as the inner contour of the anterior cortical plate and the inner contour of the posterior cortical plate, respectively. Points L1 and L1a were defined as a midpoint of the incisor edge and a root apex, respectively, projected to the ASP after the transverse inclination of the



**Figure 2.** The landmarks on the alveolar bone sagittal plane through the center of rotation (ASP).

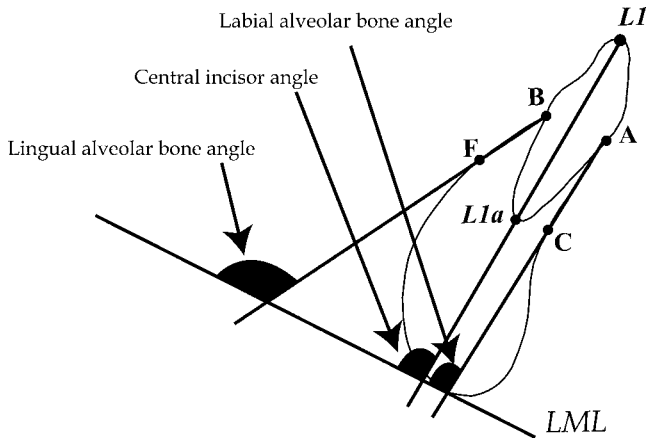


Figure 3. Angular variables.

central incisor was corrected upright so that it would be parallel to the ASP.

The lower mandibular line (LML) was defined as a midline of right and left tangent lines to the lower border of mandibular angles and the mandibular symphysis,<sup>11</sup> which was projected to the ASP.

The following variables were measured (Figures 3 and 4):

Central incisor angle: angle between the line L1-L1a and the LML.

Labial alveolar bone angle: angle between the line A-C and the LML.

Lingual alveolar bone angle: angle between the line B-F and the LML.

L1a-D: the arc between the points L1a and D.

L1a-E: the arc between the points L1a and E.

Alveolar cancellous bone thickness (D-E): the arc between the points D and E.

Root apex position ratio: the ratio of L1a-D to the alveolar cancellous bone thickness.

**Statistical Analyses**

Differences in all variables between men and women were tested using the Mann-Whitney test. Spearman rank correlation coefficients were calculated between the central incisor angle and the labial alveolar bone angle, between the central incisor angle and the lingual alveolar bone angle, between the central incisor angle and the alveolar cancellous bone thickness, between the central incisor angle and the L1a-D, and between the central incisor angle and the L1a-E. The difference between the L1a-D and the L1a-E was tested using the Wilcoxon signed rank test. The *P* < .05 level of significance was chosen for all tests. Analyses were performed using statistical software (Stat View 5.0; Abacus Concepts, Inc, Cary, NC).

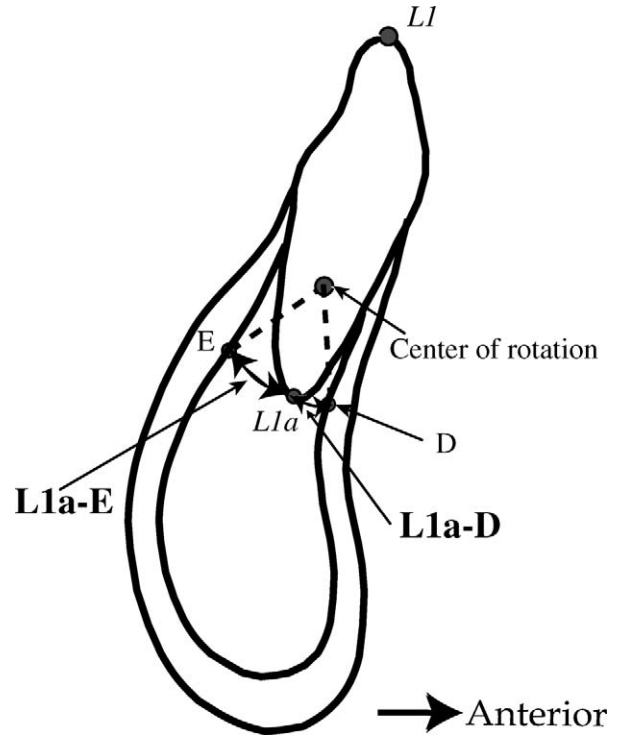


Figure 4. Linear variables.

**Measurement Reproducibility**

All variables were measured twice by one of the authors (C.Y.), with a minimum interval of 1 day. The coefficient of variation (CV) for three repeated measurements in 10 subjects was calculated for each variable. CVs for the two repeated measures for each variable ranged from 0.0% to 6.7% for the linear measurements and from 0.1% to 3.3% for the angular measurements.

**RESULTS**

The mean, standard deviation, minimum, and maximum for all variables are shown in Table 3. No significant difference was found between men and women for any variable. Therefore, combined male and female data were used for subsequent analyses. Spearman rank correlation coefficients between angular and linear variables are shown in Figure 5. Significant positive correlations were found between the central incisor angle and the labial alveolar bone angle, between the central incisor angle and the lingual alveolar bone angle, between the central incisor angle and the alveolar cancellous bone thickness, and between the central incisor angle and the L1a-E. A significant correlation was not found between the central incisor angle and the L1a-D.

The value of L1a-D was significantly smaller than

**Table 3.** Definitions of Dento-mandibular Landmarks

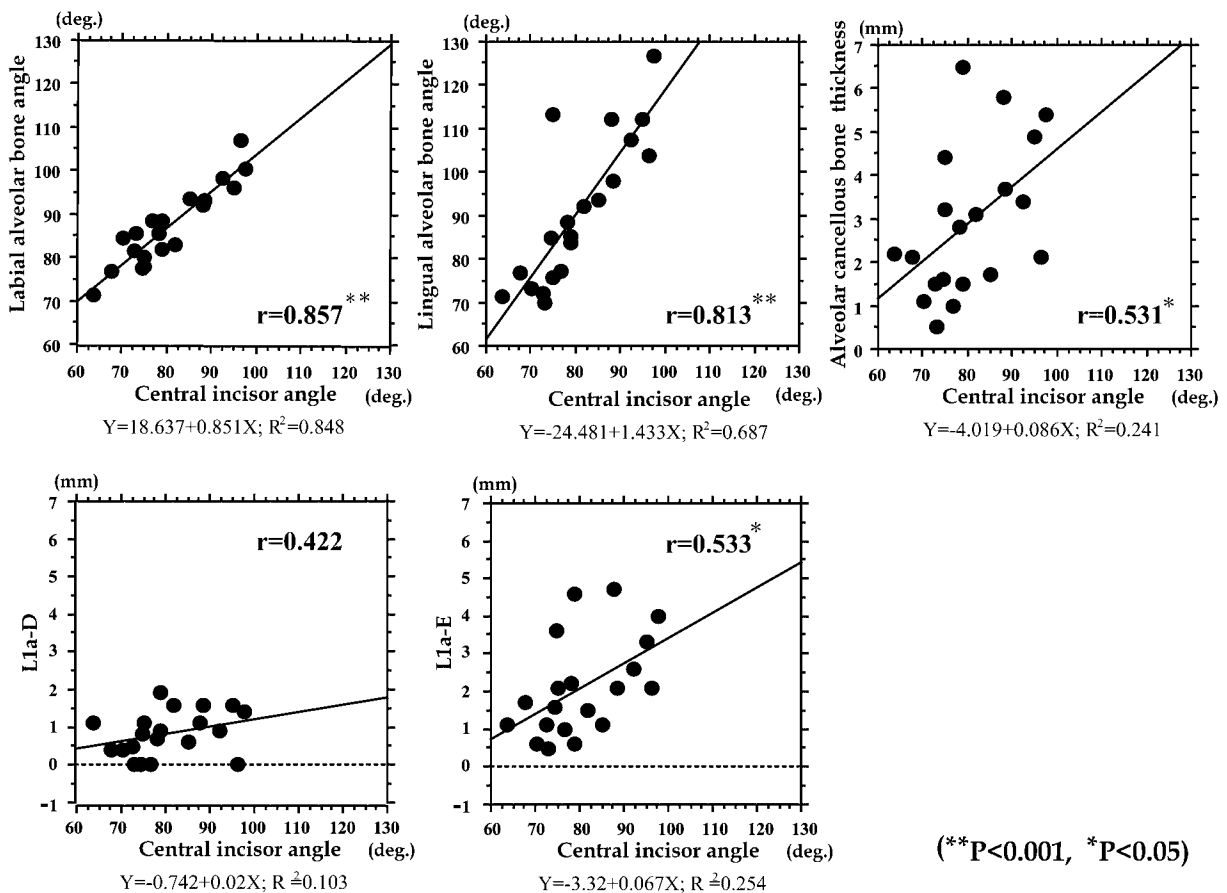
Variable	Male (n = 10)			Female (n = 10)			Combined (N = 20)		
	Mean ± SD	Min	Max	Mean ± SD	Min	Max	Mean ± SD	Min	Max
Angular variables, (°)									
Labial alveolar bone angle	86.9 ± 11.5	71.4	106.9	87.4 ± 6.4	77.7	98.4	87.1 ± 9.0	71.4	106.9
Lingual alveolar bone angle	91.8 ± 20.2	71.4	126.9	89.9 ± 13.9	69.9	113.4	90.9 ± 16.9	69.9	126.9
Central incisor angle	80.5 ± 12.7	63.8	97.6	80.5 ± 6.4	73.1	92.3	80.5 ± 9.8	63.8	97.6
Linear variables, (mm)									
L1a-D	0.8 ± 0.7	0	1.9	0.8 ± 0.5	0	1.6	0.8 ± 0.6	0	1.9
L1a-E	2.5 ± 1.5	0.6	4.7	1.7 ± 1.0	0.5	3.6	2.1 ± 1.3	0.5	4.7
Alveolar cancellous bone thickness (D-E)	3.3 ± 2.1	1.1	6.5	2.5 ± 1.3	0.5	4.4	2.9 ± 1.7	0.5	6.5
Ratio									
Root apex position	0.3 ± 0.2	0	0.5	0.3 ± 0.2	0	0.6	0.3 ± 0.2	0.0	0.6

the value of L1a-E ( $P < .001$ ). The value of the root apex position ratio was hardly greater than 0.5.

**DISCUSSION**

Several investigators<sup>6,12,13</sup> have examined the morphology of the alveolar bone in the mandibular incisor region using conventional cephalometric radiographs. It is almost impossible, however, to examine the labio-

lingual inclination and thickness of the alveolar bone in the mandibular incisor region using cephalometric radiographs. This is because the radiographic images of the labial and lingual surfaces of the alveolar bone in the mandibular incisor region are projected images of the most anterior and the most posterior parts of the alveolar bone, respectively, and do not correspond specifically to the incisor region. Cephalometric radiographs have another disadvantage in that images of



(\*\* $P < 0.001$ , \* $P < 0.05$ )

**Figure 5.** Correlations between angular and linear variables. The regression lines and Spearman rank correlation coefficients are shown.

all structures in three-dimensional space overlap each other concurrently with substantial geometric magnification error because of the divergent nature of the x-ray beam.

Using high-resolution CT scanning enables us to examine the shape and the size of alveolar bones without the disadvantages of conventional radiographs.<sup>14-18</sup> Although high-resolution CT is an indispensable modality for investigating the morphological characteristics of the mandibular alveolar bone, surprisingly very few CT studies<sup>19,20</sup> have been published on the quantitative relationship between the morphology of the mandibular alveolar bone and the inclination of the incisor. The present study is a first effort to examine the labio-lingual inclinations of the alveolar bone surface on the labial and lingual aspects in the mandibular central incisor region projected to the mandibular mid-sagittal plane using high-resolution CT.

The labio-lingual inclination of the mandibular central incisor showed significant positive correlations with the labio-lingual inclinations of the associated mandibular alveolar bone on the labial and lingual aspects in subjects examined in the present study. The findings indicate that when the mandibular central incisor is more lingually inclined, the associated alveolar bone is also more lingually inclined. Judging from these results, the shape of the alveolar bone seems to correspond to the incisor inclination. These findings are consistent with previous reports that documented that subjects with mandibular condylar growth in the sagittal direction showed backward rotation of the mandibular symphysis concurrent with backward eruption of the anterior teeth.<sup>21</sup>

The labio-lingual inclination of the mandibular central incisor correlated with the associated cancellous bone thickness. The labio-lingual inclination of the mandibular central incisor also correlated with the distance between the central incisor root apex and the inner contour of the posterior cortical plate. Judging from these results, when the mandibular central incisor was lingually inclined, the associated cancellous bone was thinner. The thin cancellous bone was characterized by the small distance between the central incisor root apex and the inner contour of the posterior cortical plate. Therefore, we must pay attention to the boundary limit for tooth movement in presurgical orthodontic treatment for subjects with lingual inclination of the mandibular central incisor and the thin cancellous bone. A previous report in which the alveolar bone thickness was evaluated documented that a narrow alveolus is frequently seen around the mandibular incisors in subjects with a high mandibular plane angle and in subjects with Class III malocclusion.<sup>6</sup>

In the present study, the mandibular central incisor root apex was closer to the inner contour of the labial

cortical bone than the lingual cortical bone. The maximum value of the distance from the root apex to the inner contour of the lingual cortical bone was 4.7 mm and to the labial cortical bone was 1.9 mm. The slight labial tipping of the mandibular central incisors may be acceptable because the tipping movement makes the root apex close to the center of the alveolar bone. However, lingual tipping of the incisor may cause problems because the incisor root apex is very close to or attaches directly to the inner contour of the labial cortical bone. In such patients, the present results suggest that lingual tipping of the incisor for orthodontic camouflage is not a reasonable treatment alternative.

## CONCLUSIONS

- In adults with mandibular prognathism, when the mandibular central incisor is more lingually inclined, the associated alveolar bone would also be more lingually inclined.
- The associated cancellous bone was thinner when the mandibular central incisor was lingually inclined.
- The mandibular central incisor root apex was closer to the inner contour of the labial cortical bone than to the lingual cortical bone.
- The morphology of the alveolar bone in the central incisor region may be associated with the inclination of the central incisor.
- To diagnose the central incisor position in consideration of the boundary limit of the alveolar bone, it is important to evaluate the morphology and size of the alveolar bone.

## ACKNOWLEDGMENTS

The authors are deeply grateful to Dr Nellie W. Kremenak for grammatical correction of the manuscript. This research was supported by the Grant for Development of Highly Advanced Medical Technology and Grant-in-Aid for Scientific Research (C-16592044) sponsored by the Japanese Ministry of Education, Science and Technology.

## REFERENCES

1. Takada K, Petdachai S, Sakuda M. Changes in dentofacial morphology in skeletal Class III children treated by a modified maxillary protraction headgear and a chin cup: a longitudinal cephalometric appraisal. *Eur J Orthod.* 1993;15: 211-221.
2. Solow B. The dentoalveolar compensatory mechanism: background and clinical implications. *Br J Orthod.* 1980;7: 145-161.
3. Worms FW, Isaacson RJ, Speidel TM. Surgical orthodontic treatment planning: profile analysis and mandibular surgery. *Angle Orthod.* 1976;46:1-25.
4. Rakosi T. Treatment of Class III malocclusions. In: Graber TM, Rakosi T, Petrovic A, eds. *Dentofacial Orthopedics With Functional Appliances*. St Louis, Mo: Mosby Year Book; 1997:391-411.
5. Brodie A. Analysis of changes during and subsequent to

- orthodontic management of Class III malocclusion. *Angle Orthod.* 1938;8:330–351.
6. Handelman CS. The anterior alveolus: its importance in limiting orthodontic treatment and its influence on the occurrence of iatrogenic sequelae. *Angle Orthod.* 1996;66:95–109.
  7. Wehrbein H, Bauer W, Diedrich P. Mandibular incisors, alveolar bone, and symphysis after orthodontic treatment: a retrospective study. *Am J Orthod Dentofacial Orthop.* 1996;110:239–246.
  8. Wada K. A study on the individual growth of maxillofacial skeleton by means of lateral cephalometric roentgenograms. *J Osaka Univ Dent Soc.* 1977;22:239–269.
  9. Davidian EJ. Use of a computer model to study the force distribution on the root of the maxillary central incisor. *Am J Orthod.* 1971;59:581–588.
  10. Christiansen RL, Burstone CJ. Centers of rotation within the periodontal space. *Am J Orthod.* 1969;55:353–369.
  11. Downs WB. Variation in facial relationships: their significance in treatment and prognosis. *Am J Orthod.* 1948;34:812–840.
  12. Aki T, Nanda RS, Currier GF, Nanda SK. Assessment of symphysis morphology as a predictor of the direction of mandibular growth. *Am J Orthod Dentofacial Orthop.* 1994;106:60–69.
  13. Nojima K, Nakakawaji K, Sakamoto T, Isshiki Y. Relationships between mandibular symphysis morphology and lower incisor inclination in skeletal class III malocclusion requiring orthognathic surgery. *Bull Tokyo Dent Coll.* 1998;39:175–181.
  14. Fuhrmann R. Three-dimensional interpretation of periodontal lesions and remodeling during orthodontic treatment. Part III. *J Orofac Orthop.* 1996;57:224–237.
  15. Fuhrmann RA, Bucker A, Diedrich PR. Assessment of alveolar bone loss with high resolution computed tomography. *J Periodontal Res.* 1995;30:258–263.
  16. Fuhrmann RA, Wehrbein H, Langen HJ, Diedrich PR. Assessment of the dentate alveolar process with high resolution computed tomography. *Dentomaxillofac Radiol.* 1995;24:50–54.
  17. Fuhrmann R. Three-dimensional interpretation of labiolingual bone width of the lower incisors. Part II. *J Orofac Orthop.* 1996;57:168–185.
  18. Nauert K, Berg R. Evaluation of labio-lingual bony support of lower incisors in orthodontically untreated adults with the help of computed tomography. *J Orofac Orthop.* 1999;60:321–334.
  19. Tsunori M, Mashita M, Kasai K. Relationship between facial types and tooth and bone characteristics of the mandible obtained by CT scanning. *Angle Orthod.* 1998;68:557–562.
  20. Masumoto T, Hayashi I, Kawamura A, Tanaka K, Kasai K. Relationships among facial type, buccolingual molar inclination, and cortical bone thickness of the mandible. *Eur J Orthod.* 2001;23:15–23.
  21. Bjork A. Variations in the growth pattern of the human mandible: longitudinal radiographic study by implant method. *J Dent Res.* 1963;42:400–411.