

Case Report

Intrusion of Overerupted Upper First Molar Using Two Orthodontic Miniscrews

A Case Report

Neal D. Kravitz^a; Budi Kusnoto^b; Peter T. Tsay^c; William F. Hohlt^d

ABSTRACT

Loss of the mandibular first molar often leads to the overeruption of the opposing maxillary first molar, resulting in occlusal interference, loss of periodontal bony support, and inadequate room to restore the mandibular edentulous space. Without orthodontic molar intrusion or segmental surgical impaction, restoring the posterior occlusion often entails the need for significant reduction of maxillary molar crown height, with the potential need for costly iatrogenic root canal therapy and restoration. The literature has cited successful maxillary molar intrusion with minor prosthodontic reduction using palatal orthodontic miniscrews and buccal zygomatic miniplates. In this report, the authors present successful maxillary molar intrusion with two orthodontic miniscrews in a patient with extreme dental anxiety and significant dental erosion due to gastric reflux. Using two orthodontic miniscrews for skeletal anchorage to intrude the maxillary molar simplified the orthodontic treatment by eliminating the need for extensive surgery, headgear, and intraoral multiunit anchorage and preserved indispensable tooth enamel. The clinical results showed significant intrusion through the maxillary sinus cortical floor while maintaining periodontal health, tooth vitality, and root length.

KEY WORDS: Overerupted molars; Intrusion; Miniscrew

INTRODUCTION

Loss of the mandibular first molar often results in overeruption of the opposing maxillary first molar, resulting in occlusal interference and functional disturbances, compromised periodontal health, and increased complexity of restoring the edentulous space.^{1,2} Prior to the application of orthodontic miniscrews for molar intrusion, leveling of the maxillary posterior occlusal plane often entailed invasive prosthodontic reduction with root canal treatment, sur-

gical impaction, or demanding orthodontic therapy requiring extraoral headgear or full-arch braces.¹⁻⁵

Despite the increasing demand of adult orthodontic care,⁶ many adults are wary of visible conventional braces,^{7,8} particularly in the upper arch. The orthodontist is often faced with the challenge of correcting the localized occlusal problem while working within the esthetic demands of the patient and treatment duration demands of the referring dentist, neither of whom may recognize the extent of treatment difficulty. Noninvasive posterior tooth intrusion using a combination of elastics with a clear Essex appliance has been reported,⁹ yet this method requires daily patient compliance and can result in posterior dislodgement of the appliance when significant intrusion is needed.

In this case report, a minimally invasive, noncompliant clinical procedure for maxillary molar intrusion using two orthodontic miniscrews is discussed in a patient with anxiety and significant dental erosion due to gastric reflux.

Case Presentation

A 44-year-old Hispanic female patient was referred from the Prosthodontic Department at the University of

^a Orthodontic Resident, Department of Orthodontics, University of Illinois at Chicago.

^b Clinical Chair, Clinical Assistant Professor, Department of Orthodontics, University of Illinois at Chicago.

^c Clinical Associate Professor, Department of Orthodontics, University of Illinois at Chicago.

^d Clinical Professor, Department of Orthodontics, University of Illinois at Chicago.

Corresponding author: Neal D. Kravitz, DMD, Department of Orthodontics, University of Illinois at Chicago, 801 South Paulina Street, MC 841, Chicago, IL 60612 (e-mail: neal.kravitz@yahoo.com)

Accepted: May 2006. Submitted: May 2006.

© 2007 by The EH Angle Education and Research Foundation, Inc.

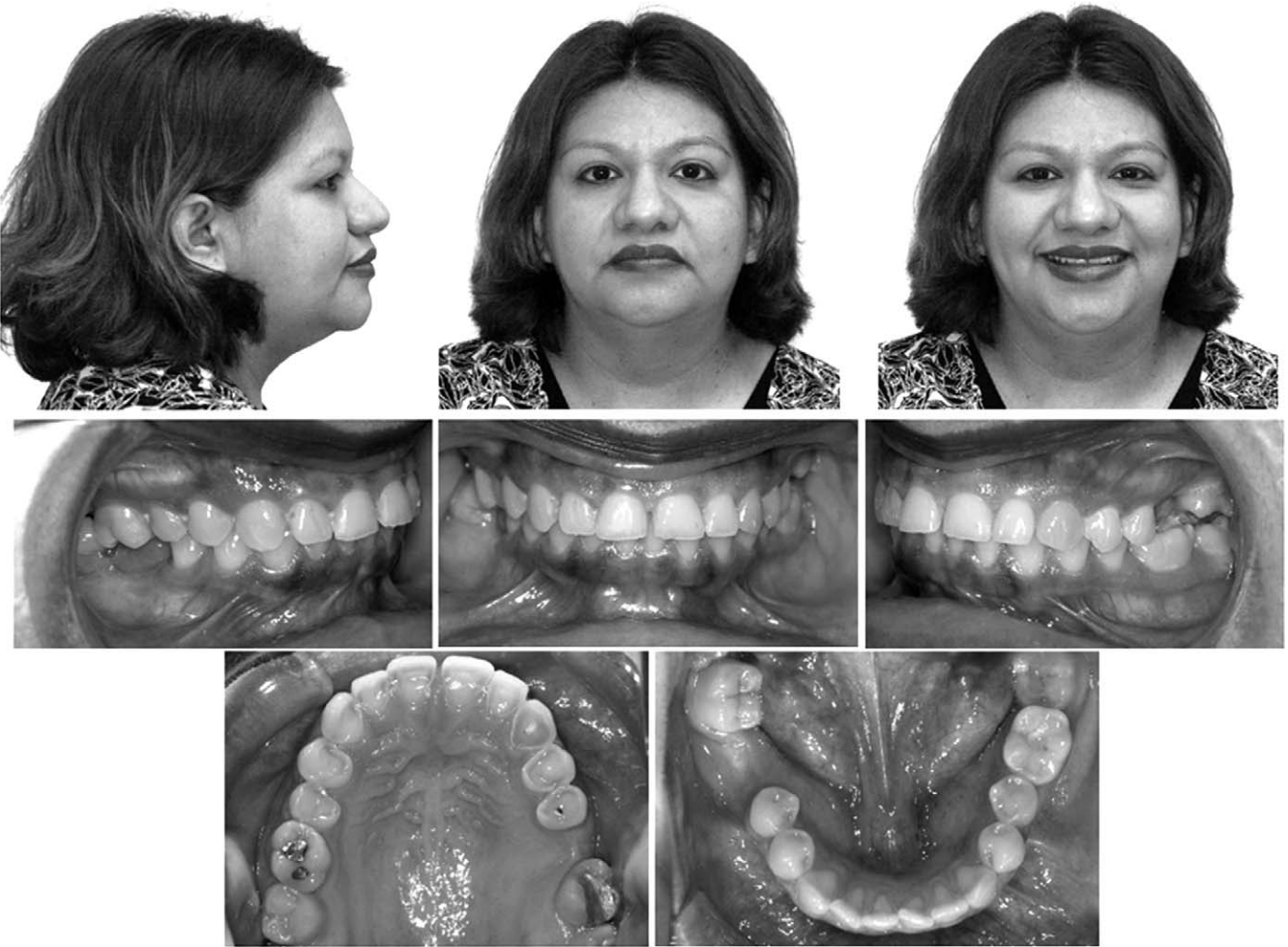

Figure 1. Pretreatment photographs.

Illinois at Chicago for molar uprighting of the lower right second molar to open space for an endosseous dental implant (Figure 1). Past dental history included significant generalized maxillary erosion (palatal and occlusal surfaces), incisal wear, bruxism, and prior extraction of the lower right first molar because of dental caries. Loss of the mandibular first molar resulted in mesial tipping of the lower right second and third molars and overeruption of the opposing maxillary first molar. The patient's medical history was significant for anxiety and long-standing gastric reflux (gastroesophageal reflux disease [GERD]). At the time of referral, the patient was planned for treatment of prosthetic full-crown coverage of the upper right first molar to the upper left second premolar, with iatrogenic endodontic treatment of the overerupted upper right first molar and a single endosseous dental implant and crown to replace the missing lower right first molar.

Diagnosis and Etiology

The patient presented with a Class I skeletal relationship and a bimaxillary dentoalveolar protrusion

(Figure 2A). Dentally, she revealed acceptable intercuspation of existing posterior teeth, 60% overbite, 3 mm overjet, generalized maxillary palatal and occlusal erosion, overerupted upper right first molar, missing upper left first molar and lower right first molar, and mesially inclined upper left molar and lower right second and third molars. The significant generalized erosion was a result of a long-standing medical history of gastric reflux. Loss of the lower right first molar resulted in mesially tipping of the teeth distal to the edentulous region as well as 3 to 4 mm overeruption of the opposing upper right first molar, prohibiting adequate restorative space for a lower endosseous implant and crown (Figure 2B).

GERD, Gastric Reflux, and Acid Reflux

GERD, or gastric reflux, is a condition in which peptic acid and bile from the stomach is regurgitated back into the esophagus and extraesophageal space.¹⁰ The acid liquid can damage the esophageal lining, resulting in ulcers, strictures (narrowing due to scar forma-

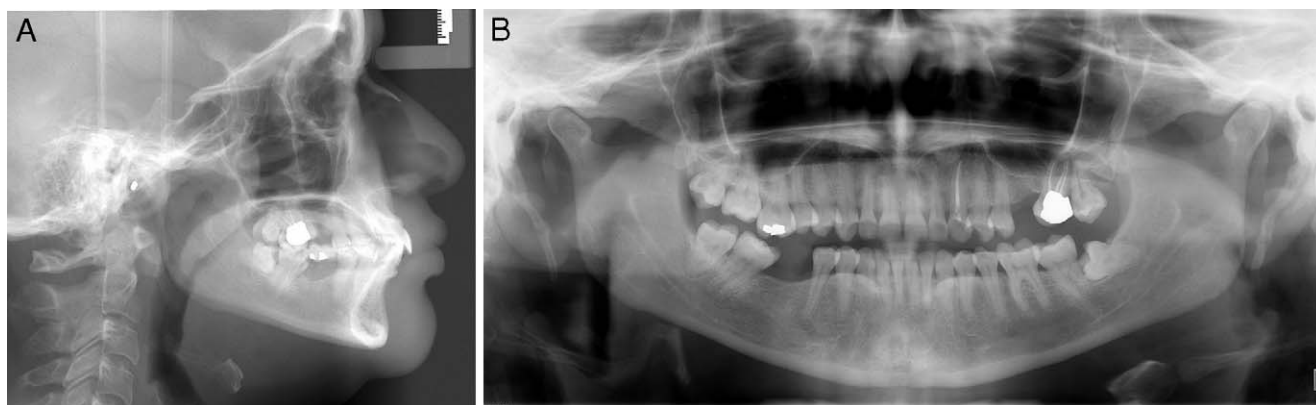


Figure 2. (A) Pretreatment lateral cephalograph. (B) Pretreatment panoramic radiograph.

tion), Barrett's esophagus (change in the cell lining), and adenocarcinoma, as well as extraesophageal complications such as chest pain, asthma, chronic cough, posterior laryngitis, and dental erosions on the palatal surface of maxillary teeth.^{10–15}

GERD can occur in childhood and afflicts approximately 20% of US adults on a weekly basis and 36% at least once a month.^{15,16} Once it begins, GERD is usually a lifelong condition.¹⁵ Orthodontic management includes a medical referral with routine examination; evaluation for bruxism, excessive attrition, vomiting, asthma, and obstructive sleep apnea; dietary management; and semisupine positioning during treatment.^{15,17} Orthodontic patients with GERD may present with sialorrhea¹⁸—a protective response against stomach acid secretion—and may be instructed by their physician to chew sugar-free nonmint gum to maintain a high salivary flow.

Treatment Objectives

The patient was first presented with an orthodontic treatment plan that included comprehensive upper and lower fixed appliances. The patient displayed great anxiety over any fixed appliance therapy on her upper teeth for fear that they would “break.” She agreed to a modified treatment plan of two maxillary orthodontic miniscrews in place of upper appliances (1) to intrude the maxillary first molar and eliminate the need for iatrogenic endodontic treatment and crown and full-arch lower fixed appliances, (2) to level and align, (3) to upright the lower right posterior occlusion, and (4) to open the vertical dimension. At the completion of orthodontic treatment, the patient would return to the prosthodontic clinic for full-coverage crowns for the upper right second premolar to left second premolar.

Progress of Molar Intrusion

Two orthodontic miniscrews (Dual Top; Rocky Mountain Orthodontics Inc, Denver, Colo), 1.4 mm in

diameter and 8 mm in length, were placed in the maxillary buccal dentoalveolus and palatal slope (Figure 3). The buccal miniscrew was inserted between the first and second molar, at the level of the mucogingival junction. The palatal miniscrew was inserted between the second premolar and first molar, just medial to the greater palatine nerve. Both miniscrews were placed using only topical anesthetic (TAC 20% alternate).

The miniscrews were immediately loaded with 100 g of intrusive force using a closed elastic power chain (Rocky Mountain Orthodontics Inc, Denver, CO). To prevent the elastic chain from slipping off the occlusal surface, the chain was made taut by twisting and further secured by a buildup of the mesial-lingual cusp with composite resin (Figure 4A). To prevent the elastic chain from slipping off the miniscrew head, elastic o-rings were placed on top of the chain. The chain was cut, leaving one remaining link, which would be used to grab and reactivate the chain at the subsequent appointment 2 weeks later (Figure 4B).

After 2 months of intrusive force with modest signs of change, a separator was placed between the first and second molar, and the elastic chain was replaced with a 7-mm-long, NiTi closed coil (150 g; GAC Inc; Figure 4C). The NiTi coil was secured to the miniscrew head with steel ligature and covered with elastic o-rings for patient comfort. Switching to NiTi coil allowed for the delivery of a more constant force, preventing the need for continual replacement and subsequent reactivation of the elastic chain, reducing the number of treatment appointments, and increasing the length of treatment intervals. By the fourth month of treatment (2 months of NiTi coil use), clinical intrusion was observed, and the separator was removed. The patient missed her scheduled 5-month appointment. After 6 months of treatment, the patient presented with the molar now 1 to 2 mm above the maxillary occlusal plane (Figure 5A,B). The miniscrews were removed, and upper and lower impressions were taken.

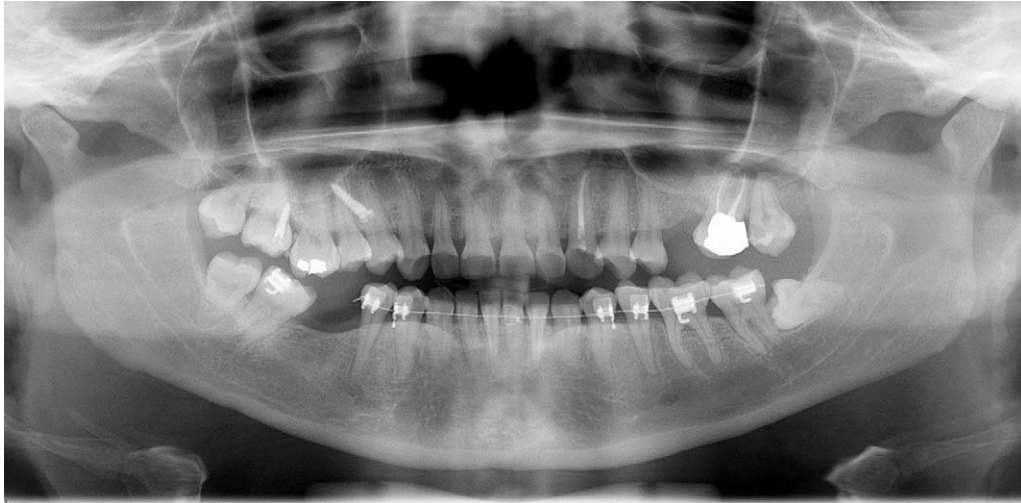


Figure 3. Placement of two self-drilling orthodontic miniscrews (8 mm in length, 1.4 mm in diameter). The buccal miniscrew (left) was placed between the first molar and second molar at the mucogingival junction. The palatal miniscrew (right) was placed between the second premolar and first molar, just medial to the greater palatine nerve.

The patient refused fixed retention of either the upper or lower dentition, as well as removable retention in the upper arch. Orthodontic treatment was retained using a lower Hawley with a resin block to replace the missing mandibular molar (Figure 6A). The patient agreed to bonding of three brackets and placement of a segmental 0.014-inch Cu-NiTi wire to help bring the upper first molar into better arch alignment. Anxious that the partial fixed braces would cause her top teeth to “break,” the patient returned to the orthodontic clinic after only 3 weeks and requested that the upper appliances be removed.

RESULTS

After 6 months of orthodontic treatment with two upper orthodontic miniscrews, full-arch lower appliances, and 3 additional weeks of upper partial fixed appliances, all treatment objectives were achieved. A functional occlusion was established in the right posterior dentition by intruding the upper first molar and uprighting the lower second and third molars, creating adequate space for an endosseous implant and crown. The maxillary first molar was intruded within the sinus floor using two orthodontic miniscrews, placed in the buccal dentoalveolus and palatal slope. Molar intrusion was accelerated after placement of an elastic separator between the first and second molar and use of a 150-g NiTi close coil spring. A lower Hawley maintained the mandibular edentulous space and lower anterior alignment and allowed the overintruded molar to settle into the occlusal plane (Figure 6B).

Cephalometric superimposition at maxillary stable reference points, comparing pretreatment digital records (Planmeca Instrumenatrium, Roselle, IL) to rec-

ords taken the day of miniscrew removal, revealed that the first molar was intruded 4.4 mm (Figure 7). Digital radiographs were magnified 5 \times , and molar intrusion was measured from the center of the occlusal surface to the palatal plane using Dolphin Imaging. The occlusal surface of the upper right first molar was easily identifiable on the lateral cephalograph because of the missing upper left and lower right first molars. A digital panoramic radiograph showed intact lamina dura around the first molar within the sinus floor, with no radiographically observable root resorption.

DISCUSSION

To intrude the supraerupted maxillary molar, one miniscrew was placed in the buccal dentoalveolus between the first and second molar at the level of the mucogingival junction; the second was placed in the palatal slope between the second premolar and first molar just medial to the greater palatine nerve. The largest amount of maxillary interradicular bone in the mesiodistal direction, buccally and palatally, is between the second premolar and first molar.^{19–21} The palatal miniscrew was placed mesial to the first molar to avoid the greater palatine foramen²² and the porous trabecular D4 bone found in the posterior maxilla.^{23–25} Adequate interradicular room and attached gingiva was present distal to the first molar to allow for placement of a buccal miniscrew.

The ideal location for placement of a palatal miniscrew is in the midline suture or the paramedian region. The palatal midline is typically composed of thick cortical D1 bone covered with 1-mm thin attached gingiva.²⁶ To allow for equal buccal and palatal intrusive force, an extension arm is needed to reach the palatal

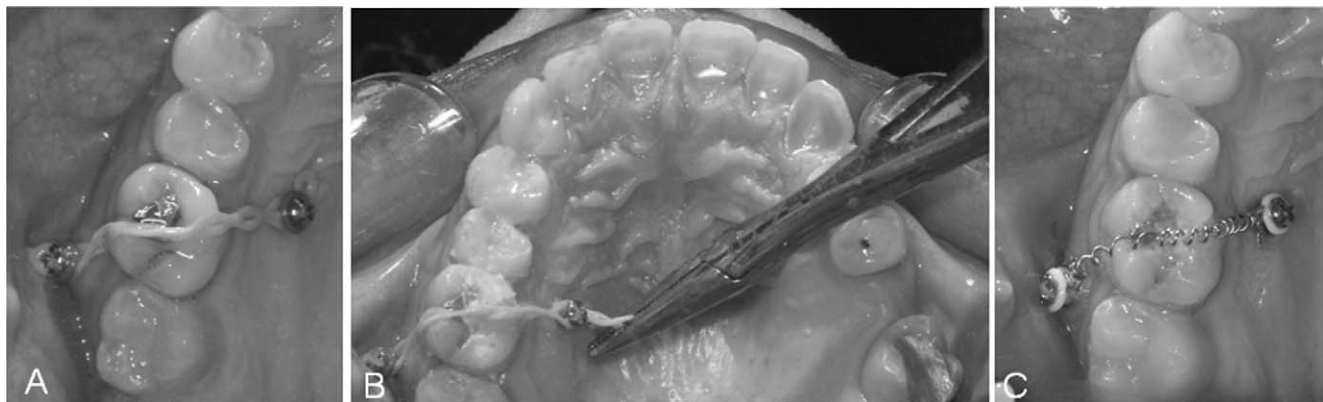


Figure 4. (A) Intrusion of the upper right first molar with elastic chain. The elastic chain was twisted, and the mesiolingual cusp was built up with composite resin to prevent slipping off of the occlusal table. The chain was secured to the miniscrew head with an elastic o-ring. Notice the extra chain linkage on either side of the miniscrew head. (B) Activation of elastic by grabbing the extra linkage. (C) NiTi coil (7 mm) and separator placed between the first and second molar to counteract the door-wedge effect of the second molar leaning under the distal height of contour of the first molar impeding intrusion. The NiTi coil is tied to the miniscrew head with steel ligature and covered with an elastic o-ring for comfort. Notice the early signs of intrusion and palatal crown tipping.

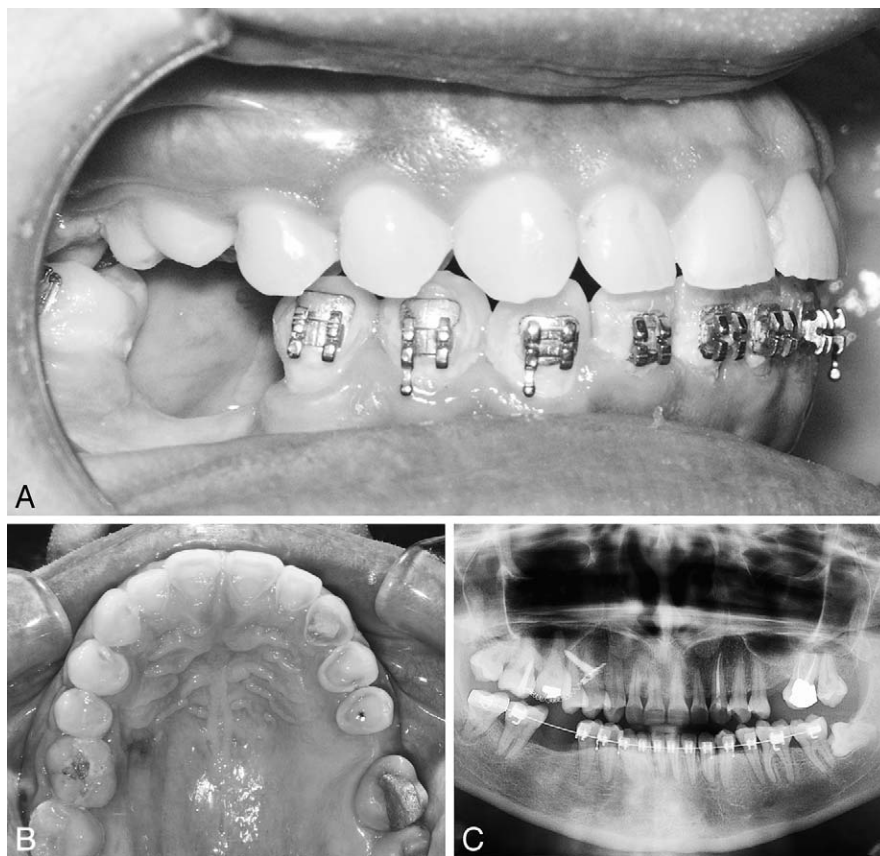


Figure 5. (A) Successful intrusion after 6 months without partial fixed appliances or prosthodontic reduction. Photo taken on the day of miniscrew removal. (B) (Right) Palatal crown tipping due to intrusion mechanics. Photo taken on the day of miniscrew removal. (C) Panoramic radiograph taken on the day of miniscrew removal. Maxillary right first molar intruded 1 to 2 mm above the occlusal plane.

slope.^{1,2} Placement of the miniscrew directly within the palatal slope may increase the risk of nerve involvement and stationary anchorage failure due to the thin cortical D3 bone and thick overlying tissue.^{26,27} In the

case presented, the miniscrew was placed in the palatal slope rather than the paramedian region to eliminate the need for an extension arm.

Prior to applying intrusive forces, it may be neces-

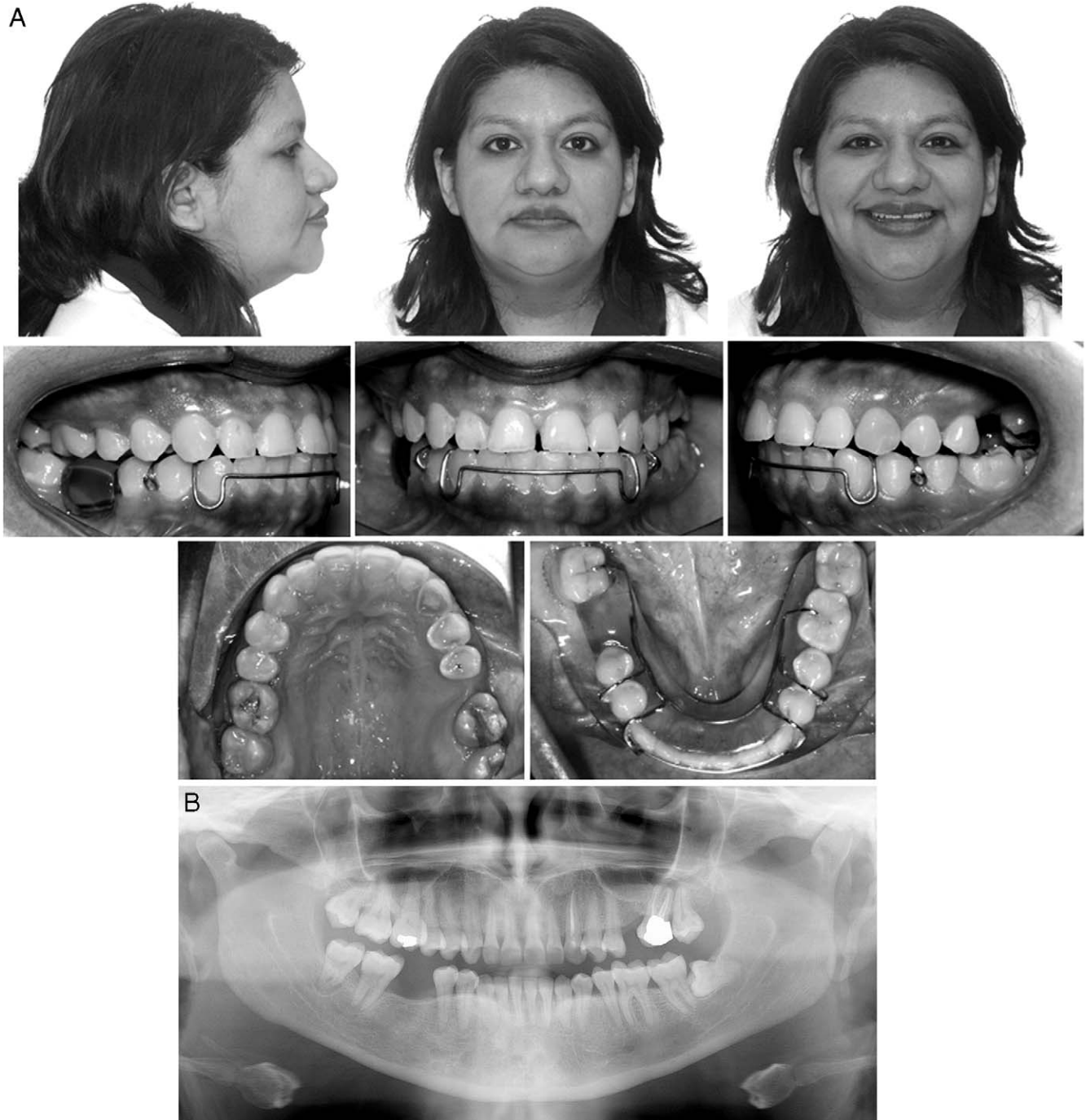

Figure 6. (A) Posttreatment photographs and lower Hawley. (B) Posttreatment panoramic radiograph.

sary to create adequate space between the over-erupted molar and its adjacent teeth. In particular, the mesial surface of the posterior tooth often leans against the distal surface of the overerupted molar below its height of contour. This door-wedge effect impedes intrusion and often requires placement of a thick elastic separator or prior distalization with an open-coil spring (Figure 8). While the use of an elastic separator can adequately and simply create room for mo-

lar intrusion in the absence of partial fixed appliances, there is the risk that the separating ring can slip subgingivally, resulting in periodontal damage.²⁸⁻³⁰ The orthodontist should remove the separator once molar intrusion becomes clinically evident.

Whether overerupted maxillary first molars can be intruded within the maxillary sinus floor without apical root resorption is controversial.³¹⁻⁴² Ari-Demirkaya et al⁴⁰ reported that the amount of resorption after molar

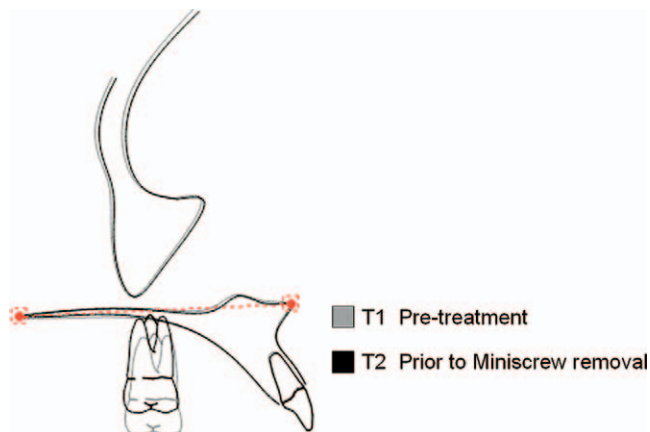


Figure 7. Maxillary superimposition.

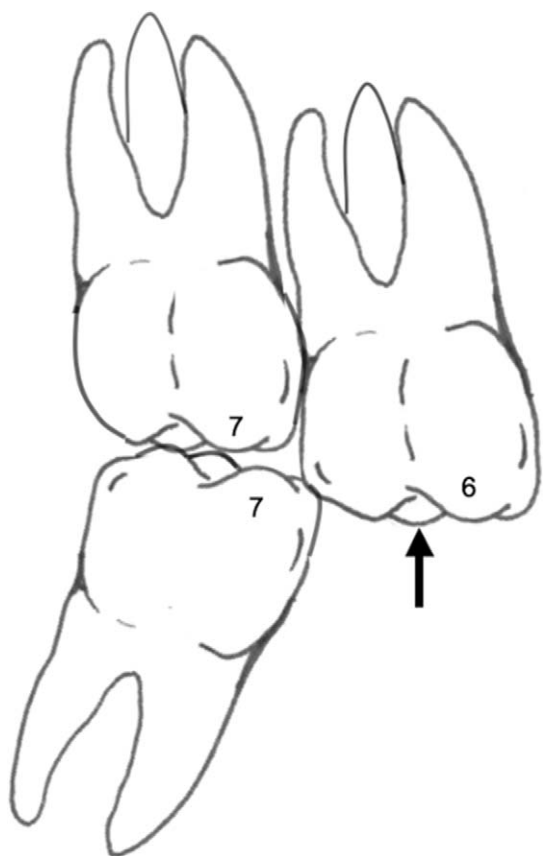


Figure 8. Door-wedge effect. Early loss of the lower first molar causes extrusion of the upper first molar and mesial tipping of the lower second molar. The upper second molar wedges under the distal height of contour of the extruded tooth, impeding intrusion. Prior separation between the upper first and second molar, either by distalization or placement of an elastic separator, may aid intrusion.

intrusion with skeletal anchorage was not clinically different from control groups treated without intrusion mechanics. Daimaruya et al⁴¹ intruded maxillary second premolars into the nasal floor of six beagle dogs and reported only 0.18 ± 0.18 mm (mean \pm SD) of

apical root resorption after 7 months of intrusion. The sinus floor membrane lifted intranasally, and a thin layer of newly formed cortical bone covered the intruding roots. Park et al⁴² reported two cases of successful maxillary molar intrusion using skeletal anchorage, without notable root resorption.

The question remains whether intruded molars will relapse to their original position? Sugawara et al³⁷ evaluated the posttreatment dentoalveolar changes following intrusion of mandibular molars using skeletal miniplates in nine adult open bite patients. The authors reported an average relapse rate of 30% for the lower first and second molars. In the near future, further long-term follow up studies will be needed to determine the relapse potential of molars intruded with skeletal anchorage.

CONCLUSIONS

- A supraerupted maxillary molar can be successfully intruded within the maxillary sinus cortical floor using two orthodontic miniscrews.
- Short-term molar intrusion can be achieved without clinically detectable apical root resorption.
- By using orthodontic miniscrews and a brief period of partial fixed appliances to correct a localized occlusal problem, the patient's dental anxiety was minimized, her restorative treatment finances were reduced, and tooth enamel and vitality were protected.

ACKNOWLEDGMENT

The first author would like to thank Drs Carla Evans, William Hohlt, and Terry Selke for their personal guidance.

REFERENCES

1. Yao CC, Wu CB, Wu HY, Kok SH, Chang HF, Chen YJ. Intrusion of overerupted upper left first and second molars by mini-implants with partial-fixed orthodontic appliances: a case report. *Angle Orthod.* 2004;74:550–557.
2. Yao CC, Lee JJ, Chen HY, Chang ZC, Chang HF, Chen YJ. Maxillary molar intrusion with fixed appliances and mini-implant anchorage studied in three dimensions. *Angle Orthod.* 2005;75:754–760.
3. Daly P, Pitsilllis A, Nicolopoulos C. Occlusal reconstruction of a collapsed bite by orthodontic treatment, pre-prosthetic surgery and implant supported prostheses: a case report. *SADJ.* 2001;56:278–282.
4. Melsen B. Management of severely compromised orthodontic patients. In: Nanda R, ed. *Biomechanics in Clinical Orthodontics*. Philadelphia, Pa: W.B. Saunders; 1997;294–319.
5. Schoeman R, Subramanian L. The use of orthognathic surgery to facilitate implant placement: a case report. *Int J Oral Maxillofac Implants.* 1996;11:682–684.
6. American Association of Orthodontists. 2006. Available at: http://www.braces.org/braces/about/faq/faq_adults.cfm. Accessed April 1, 2006.
7. Chenin DA, Trosien AH, Fong PF, Miller RA, Lee RS. Or-

- thodontic treatment with a series of removable appliances. *J Am Dent Assoc.* 2003;134:1232–1239.
8. Vlaskalic V, Boyd RL. Clinical evolution of the Invisalign appliance. *J Calif Dent Assoc.* 2002;30:769–776.
 9. Armbruster P, Sheridan JJ, Nguyen P. An Essix intrusion appliance. *J Clin Orthod.* 2003;37:412–416.
 10. *Stedman's Medical Dictionary.* 27th ed. Baltimore, Md: Lippincott Williams and Wilkins; 2000:514–515.
 11. Richter JE, Castell DO. Gastroesophageal reflux: pathogenesis, diagnosis, and therapy. *Ann Intern Med.* 1982;97:93–103.
 12. Richter JE. Beyond heartburn: extraesophageal manifestations of gastroesophageal reflux disease. *Am J Manag Care.* 2001;7(1 suppl):S6–S9.
 13. Rodriguez-Tellez M. Supra-esophageal manifestations of gastro-esophageal reflux disease. *Drugs.* 2005;65(suppl 1):67–73.
 14. Bartlett DW. The role of erosion in tooth wear: aetiology, prevention and management. *Int Dent J.* 2005;55(4 suppl 1):277–284.
 15. Gandara BK, Truelove EL. Diagnosis and management of dental erosion. *J Contemp Dent Pract.* 1999;1:16–23.
 16. Harding SM. Gastroesophageal reflux, asthma and mechanisms of interaction. *Am J Med.* 2001;111(suppl 8A):8S–12S.
 17. Chacon GE, Viehweg TL, Ganzberg SI. Management of the obese patient undergoing office-based oral and maxillofacial surgery procedures. *J Oral Maxillofac Surg.* 2004;62:88–93.
 18. Neville BW, Damm DD, Allen CM, Bouquot JE. *Oral and Maxillofacial Pathology.* 2nd ed. Philadelphia, Pa: W.B. Saunders; 2002:397.
 19. Carano A, Velo S, Incorvati C, Poggio P. Clinical applications of the mini-screw-anchorage system (M.A.S.) in the maxillary alveolar bone. *Prog Orthod.* 2004;5:212–235.
 20. Schnelle MA, Beck FM, Jaynes RM, Huja SS. A radiographic evaluation of the availability of bone for placement of miniscrews. *Angle Orthod.* 2004;74:832–837.
 21. Poggio PM, Incorvati C, Velo S, Carano A. “Safe zones”: a guide for miniscrew positioning in the maxillary and mandibular arch. *Angle Orthod.* 2006;76:191–197.
 22. Jaffar AA, Hamadah HJ. An analysis of the position of the greater palatine foramen. *J Basic Med Sci.* 2003;3:24–32.
 23. Misch CE. *Contemporary Implant Dentistry.* 2nd ed. St Louis, Mo: Mosby; 1998.
 24. Jaffin RA, Berman CL. The excessive loss of Branemark fixtures in type IV bone: a 5-year analysis. *J Periodontol.* 1991;62:2–4.
 25. Kravitz ND, Kusnoto B, eds. *Rocky Mountain Orthodontics Dual-Top Anchorsystem: Miniorthoscrew Seminar Manual.* Denver, CO: RMO, Inc. 2005.
 26. Lee JS, Kim DH, Park YC, Kyung SH, Kim TK. The efficient use of midpalatal miniscrew implants. *Angle Orthod.* 2004;74:711–714.
 27. Yun HS, Kim HJ, Park YC. *The Thickness of the Maxillary Soft Tissue and Cortical Bone Related With an Orthodontic Implantation* [master's thesis]. Seoul, South Korea: Yonsei University; 2001.
 28. Haralabakis NB, Tsianou A, Nicolopoulos C. Surgical intervention to prevent exfoliation of central incisors from elastic wear. *J Clin Orthod.* 2006;40:51–54.
 29. Zilberman Y, Shteyer A, Azaz B. Iatrogenic exfoliation of teeth by the incorrect use of orthodontic elastic bands. *J Am Dent Assoc.* 1976;93:89–93.
 30. Vandersall DC, Varble DL. The missing orthodontic elastic band, a periodontic-orthodontic dilemma. *J Am Dent Assoc.* 1978;97:661–663.
 31. Erverdi N, Keles A, Nanda R. The use of skeletal anchorage in open bite treatment: a cephalometric evaluation. *Angle Orthod.* 2004;74:381–390.
 32. Park HS, Jang BK, Kyung HM. Maxillary molar intrusion with micro-implant anchorage (MIA). *Aust Orthod J.* 2005;21:129–135.
 33. Beck BW, Harris EF. Apical root resorption in orthodontically treated subjects: analysis of edgewise and light wire mechanics. *Am J Orthod Dentofacial Orthop.* 1994;105:350–361.
 34. Melsen B, McNamara JA Jr, Hoenie DC. The effect of bite-blocks with and without repelling magnets studied histomorphometrically in the rhesus monkey (*Macaca mulatta*). *Am J Orthod Dentofacial Orthop.* 1995;108:500–509.
 35. Melsen B, Agerbaek N, Markenstam G. Intrusion of incisors in adult patients with marginal bone loss. *Am J Orthod Dentofacial Orthop.* 1989;96:232–241.
 36. Vanarsdall RL. Orthodontics and periodontal therapy. *Periodontol.* 1995;9:132–149.
 37. Sugawara J, Baik UB, Umemori M, Takahashi I, Nagasaka H, Kawamura H, Mitani H. Treatment and posttreatment dentoalveolar changes following intrusion of mandibular molars with application of a skeletal anchorage system (SAS) for open bite correction. *Int J Adult Orthodon Orthognath Surg.* 2002;17:243–253.
 38. Daimaruya T, Nagasaka H, Umemori M, Sugawara J, Mitani H. The influences of molar intrusion on the inferior alveolar neurovascular bundle and root using the skeletal anchorage system in dogs. *Angle Orthod.* 2001;71:60–70.
 39. McNab S, Battistutta D, Taverne A, Symons AL. External apical root resorption following orthodontic treatment. *Angle Orthod.* 2000;70:227–232.
 40. Ari-Dermirkaya AA, Masry MA, Erverdi N. Apical root resorption of maxillary first molars after intrusion with zygomatic skeletal anchorage. *Angle Orthod.* 2005;75:761–767.
 41. Daimaruya T, Takahashi I, Nagasaka H, Umemori M, Sugawara J, Mitani H. Effects of maxillary molar intrusion on the nasal floor and tooth root using the skeletal anchorage system in dogs. *Angle Orthod.* 2003;73:158–166.
 42. Park HS, Jang BK, Kyung HM. Maxillary molar intrusion with micro-implant anchorage (MIA). *Aust Orthod J.* 2005;21:129–135.