

Long-term Anteroposterior and Vertical Maxillary Changes in Skeletal Class II Patients Treated with Slow and Rapid Maxillary Expansion

Roberto M.A. Lima Filho^a; Antonio C.O. Ruellas^b

ABSTRACT

Objective: To evaluate a 10-year follow-up of anteroposterior and vertical maxillary changes in skeletal Class II patients treated with slow and rapid maxillary expansion methods.

Materials and Methods: The sample consisted of 70 patients divided into two groups: (1) treated with a cervical headgear with expansion of the inner bow (CHG) and (2) using a Haas-type rapid maxillary expansion appliance in conjunction with cervical headgear (RME-CHG). The CHG group consisted of 40 patients (18 males and 22 females; average age 10.6 years at pretreatment [T₁], 13.6 years at posttreatment [T₂], and 23.6 years at postretention [T₃]). The RME-CHG group consisted of 30 patients (14 males and 16 females; average age 10.4 years at T₁, 14.0 years at T₂, and 24.6 years at T₃). The profiles of SNA and SN-PP angles showed no significant differences in either group at T₁, T₂, and T₃ phases.

Results: For the entire sample, the profile analysis between the phases showed reduction in the SNA angle from T₁–T₂ and an increase from T₂–T₃. The SN-PP angle showed an increase from T₁–T₂ and a decrease from T₂–T₃. Treatment of skeletal Class II patients with slow and rapid maxillary expansions was efficient and stable over the long-term.

Conclusions: The profiles of SNA and SN-PP at T₁, T₂, and T₃ achieved with slow and rapid maxillary expansions were clinically equivalent.

KEY WORDS: Skeletal Class II; Maxillary changes; Maxillary expansion; Long-term

INTRODUCTION

The maxilla differs from the mandible in that the former is composed of two distinct bones joined at the midpalatal and intermaxillary sutures. This anatomical characteristic allows greater orthopedic effects. Class II malocclusion is related to a narrow maxilla. Therefore, a transverse expansion of the maxillary arch is necessary to correct this anomaly.¹

The transverse maxillary expansion can be obtained through slow or rapid maxillary expansion. Rapid maxillary expansion (RME) is a mechanical procedure that utilizes great forces and is designed to produce maximum skeletal response with minimum tooth movements.² After RME, as the two halves of the maxilla rotate anteriorly and laterally away from their posterior

articulations, point A is displaced anteriorly.³ The initial downward and forward movement of the maxilla, together with a downward and backward rotation of the mandible,⁴ produce a negative effect on the Class II correction. This has been demonstrated to be temporary because the maxilla and the mandible tend to return to their original positions during the stabilization period.⁵

The cervical headgear has been used for correction of skeletal Class II malocclusion mainly in the mixed dentition when the skeletal system is more dynamic and easily remodeled. If treatment of a Class II malocclusion is started during the transitional dentition, after the eruption of first premolars, 90% of the cases are successfully corrected.⁶ Although the Kloehe cervical headgear is the most frequently used appliance, there are still controversies regarding its influence in relation to the SNA angle,⁷ first molar extrusion,^{8,9} and palatal plane.^{10,11} When the inner bow of the appliance is expanded laterally, there is slow apical base expansion that promotes a significant widening of the maxillary dental arch and an increase in intranasal capacity.¹²

The long-term effects of slow and rapid maxillary ex-

^a Private Practice, São José do Rio Preto, SP, Brazil.

^b Associate Professor, Department of Orthodontics, Universidade Federal do Rio de Janeiro, Rio de Janeiro, Brazil.

Corresponding author: Dr. Roberto M. A. Lima Filho, Avenida Alberto Andaló 4025, São José do Rio Preto, SP, Brazil 15015-000 (e-mail: robertomario@terra.com.br)

Accepted: September 2006. Submitted: July 2006.

© 2007 by The EH Angle Education and Research Foundation, Inc.

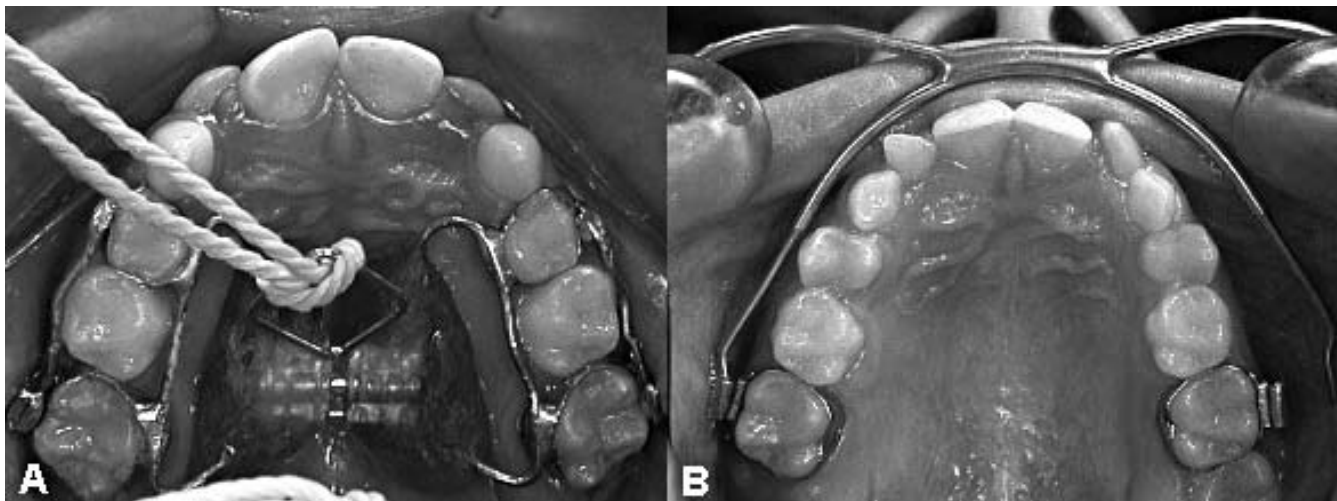


Figure 1. Intraoral photographs of Haas-type rapid maxillary expansion appliance (A) and Kloehn cervical gear with expanded inner bow (B).

pansions in the skeletal Class II treatment are not found in the literature. Thus, studies are necessary to verify the clinical benefits of these therapies in this type of malocclusion. The objective of this study is to evaluate the long-term (10-year follow-up) behavior of anteroposterior and vertical maxillary changes in skeletal Class II patients treated with slow and rapid maxillary expansions.

MATERIALS AND METHODS

The sample consisted of 70 patients selected consecutively from the file records of the Lima Ortodontia Clinic in São José do Rio Preto, State of São Paulo, Brazil, by one practitioner. The inclusion criteria were: (1) skeletal Class II with ANB ≥ 5°; (2) treatment by nonextraction; (3) same fixed appliance therapy after obtaining Class I molar relationship; (4) absence of intermaxillary Class II elastics, and (5) same retention protocol at the end of treatment. The option for rapid maxillary expansion was based on the severity of the transverse discrepancy. The 70 patients were divided into 2 groups: (1) slow maxillary expansion employing cervical headgear with expanded inner bow (CHG) and (2) rapid maxillary expansion using a tissue-borne Haas-type RME appliance followed by cervical headgear (RME-CHG) (Figure 1).

The CHG group consisted of 40 patients, 18 males and 22 females. The RME-CHG group consisted of 30 patients, 14 male and 16 female. The sample age characteristics are shown in Table 1.

The extraoral appliance used in this study was a Kloehn cervical headgear recommended to be worn for 12 to 14 hours per day. The force applied for the 70 patients averaged 450 g. The patients were seen monthly when attention was given to three areas of adjustment: (1) the inner bow was maintained at a 4

to 8 mm expansion; (2) the outer bow was maintained at a 10° to 20° elevation to prevent distal tipping of the molars, and (3) the ends of the inner bow were adjusted to rotate the molars.

All palatal expanders were manufactured at the same clinic. The expansion rate was two quarter turns (0.5 mm) per day until adequate overexpansion was achieved when the lingual cusps of the upper posterior teeth approximated the buccal cusps of the lower posterior teeth as determined by clinical observation. The RME appliance was left cemented in place for 3–9 months while extraoral traction was applied against the maxilla. A loose removable acrylic plate was placed within 48 hours of removing the expander. Each patient wore the acrylic plate for a variable amount of time, usually one year.

In the lateral cephalometric radiographs, the degree of image distortion was determined using a 100 mm correction ruler adapted to the patient, on the midsagittal plane. Kodak T-Mat™ film (20.3 × 25.4 cm) was used and placed on the left side of the cephalostat, to avoid image enlargement beyond 8% in relation to the structures.¹³

Cephalometric points were digitized (Numonics Corp, model AccuGrid XNT A30BL, Montgomeryville,

Table 1. Mean Age and Range (Years) of Skeletal Class II Patients at Pretreatment (T₁), Posttreatment (T₂), and Postretention (T₃)^a

Phase	CHG			RME-CHG		
	n	Mean	Range	n	Mean	Range
T ₁	40	10.6	8.10–13.2	30	10.4	7.1–15.0
T ₂	40	13.6	11.7–16.4	30	14.0	11.0–17.7
T ₃	40	23.6	17.6–33.5	30	24.6	17.1–36.3

^a CHG indicates cervical headgear with expansion of the inner bow; RME-CHG, rapid maxillary expansion appliance in conjunction with cervical headgear; n, number of subjects.

Table 2. Descriptive Statistics of Measurements Obtained From 40 CHG and 30 RME-CHG Patients at Pretreatment (T₁), Posttreatment (T₂), and Postretention (T₃)^a

Measures	Phase	CHG				RME-CHG			
		Mean	SD	Min	Max	Mean	SD	Min	Max
SNA ^b	T ₁	83.4	3.05	76.1	88.6	81.6	4.22	71.6	88.0
	T ₂	80.2	3.94	70.9	86.1	79.1	3.56	70.0	85.0
	T ₃	81.0	3.29	75.0	87.0	80.1	3.85	68.6	87.1
SN-PP ^b	T ₁	6.1	3.10	-0.4	11.5	6.0	3.18	0.1	13.2
	T ₂	7.8	3.39	1.5	15.0	7.6	3.50	1.4	16.6
	T ₃	7.3	3.15	1.0	13.6	6.6	3.74	-0.6	15.7

^a CHG indicates cervical headgear with expansion of the inner bow; RME-CHG, rapid maxillary expansion appliance in conjunction with cervical headgear. SD, standard deviation; Min, minimum; Max, maximum.

^b Angular measurements (degrees).

Pa), according to Ortho lateral regimen and processed with Dentofacial Planner Plus software, version 2.5b (DentoFacial Software Inc, Toronto, Ontario, Canada). The angular measurements included SNA (maxillary protrusion) and SN-PP (maxillary inclination).

To evaluate the reproducibility of the present research in determining the cephalometric points, preliminary tests were performed to determine the errors in the method employed. Eleven randomly chosen lateral cephalograms were digitized at predetermined intervals (minimum two weeks) between the first and the second. The largest error was 0.8° and the smallest was 0.1°.

The hypotheses consisted of verifying through profile analysis the differences in the measurements taken at pretreatment (T₁), posttreatment (T₂), and postretention (T₃). Analysis included:

- H₀₁: Are the profiles parallel?
- H₀₂: Assuming the profiles are parallel, are the profiles coincident?
- H₀₃: Assuming the profiles are coincident, are the profiles level?

The data were statistically analyzed by using exploratory analyses for the variables studied in the T₁,

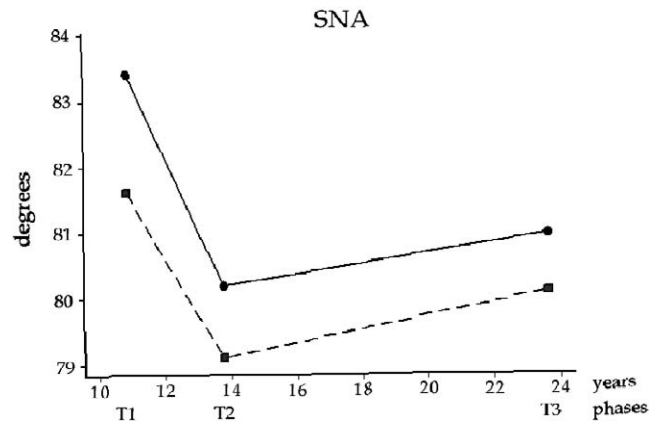


Figure 2. Mean profiles of SNA angle in pretreatment (T₁), posttreatment (T₂), and postretention (T₃) phases. —■— RME-CHg: rapid and slow maxillary expansions; —●— CHG: slow maxillary expansion.

T₂, and T₃ phases. In hypotheses H₀₁ and H₀₂, Hotellings T² test was used to test the profile of each group. In H₀₃, the F-Snedecor test was applied to the entire sample when H₀₁ and H₀₂ results were nonsignificant. When these results were significant, the F-Snedecor test was applied separately to each group. The multiple comparisons between phases were tested by the Bonferroni method,¹⁴ considering the differences of phases for paired data.

RESULTS

The results of the descriptive statistics for all measurements at T₁, T₂, and T₃ in CHG and RME-CHG groups are shown in Table 2.

According to Hotelling's T² test (H₀₁, H₀₂, and H₀₃), the profiles of SNA and SN-PP angles showed no significant differences in both groups throughout the T₁, T₂, and T₃ phases (Table 3). For this reason, the F-Snedecor test was applied to the entire sample. For the entire sample (CHG + RME-CHG) the profile analysis between the phases showed a mean reduction of 2.9° in the SNA angle from T₁-T₂ and a mean increase of 0.9° from T₂-T₃ (Figure 2). The SN-PP angle

Table 3. Results of Hotelling's T², F Test, and P Values for the Hypotheses H₀₁, H₀₂, and H₀₃; Mean of Difference (D_{ij}), Standard Deviation of Difference Between Phases (SD_{ij}), and Confidence Interval for Multiple Comparisons Between Pretreatment (T₁), Posttreatment (T₂), and Postretention (T₃)^{*}

Measure (°)	H ₀₁		H ₀₂		H ₀₃		Comparison	d _{ij}	SD _{ij}	CI
	T ²	P	T ²	P	F	P				
SNA	3.49	0.19	2.23	0.14	187.35	0.000 ⁺	T ₁ -T ₂	2.9	1.8	[2.26; 3.54]
							T ₁ -T ₃	2.0	2.1	[1.26; 2.78]
							T ₂ -T ₃	-0.9	1.6	[-1.44; -0.31]
SN-PP	2.01	0.36	0.18	0.66	54.90	0.000 ⁺	T ₁ -T ₂	-1.6	1.9	[-2.29; -0.96]
							T ₁ -T ₃	-0.9	2.1	[-1.68; -0.19]
							T ₂ -T ₃	0.7	1.6	[0.11; 1.25]

* P < .05; 0.000⁺, approximately zero; CI, 95% confidence interval of Bonferroni; a, CHG group; b, CHG-RME group.

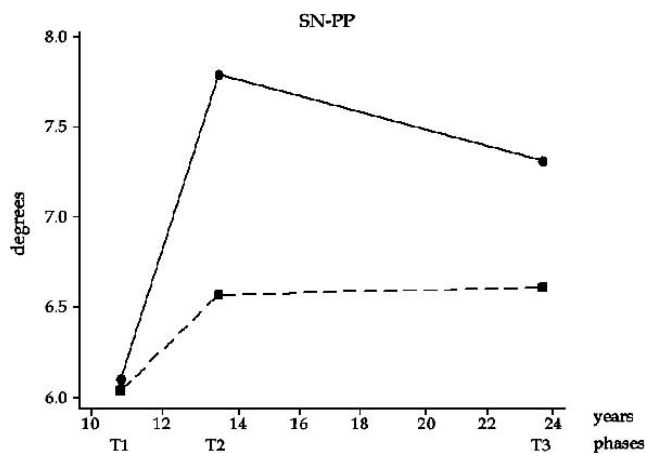


Figure 3. Mean profiles of SN-PP angle in pretreatment (T₁), post-treatment (T₂), and postretention (T₃) phases. —■— RME-Chg: rapid and slow maxillary expansion; —●— CHG: slow maxillary expansion.

showed a mean increase of 1.6° from T₁–T₂ and a mean decrease of 0.7° from T₂–T₃ (Figure 3). These mean differences of SNA and SN-PP angles between the treatment phases were statistically significant.

DISCUSSION

The profile of the SNA and SN-PP angles in the CHG and RME-CHG groups showed no significant differences at the T₁, T₂, and T₃ phases, thus demonstrating that both slow and rapid maxillary expansion produced similar short- and long-term anteroposterior and vertical changes in skeletal Class II correction. Although all patients presented with skeletal Class II, the option for rapid maxillary expansion was based on the severity of the transverse discrepancy.⁵ A comparison with the literature is troublesome because long-term follow-up studies on skeletal Class II patients treated with cervical headgear are scarce. Moreover, no study was found on skeletal Class II patients treated with cervical headgear in conjunction with a rapid maxillary expansion appliance.

Among the benefits of RME is the loosening of the circummaxillary sutures as part of the Class III correction with facemask therapy.¹⁵ In the RME-CHG group, a Kloehn cervical headgear was placed at the time of stabilization of the palatal appliance. Theoretically, due to the disruption of the hafting sutures, the entire maxilla would be displaced downward and backward more easily with a greater decrease in the SNA angle in the RME-CHG group. However, in the present investigation, both groups showed similar reductions in maxillary protrusion.

In the profile analysis between treatment phases of the entire sample, the SNA angle decreased from T₁–T₂ (2.9°) which is in agreement with previous studies.¹⁶

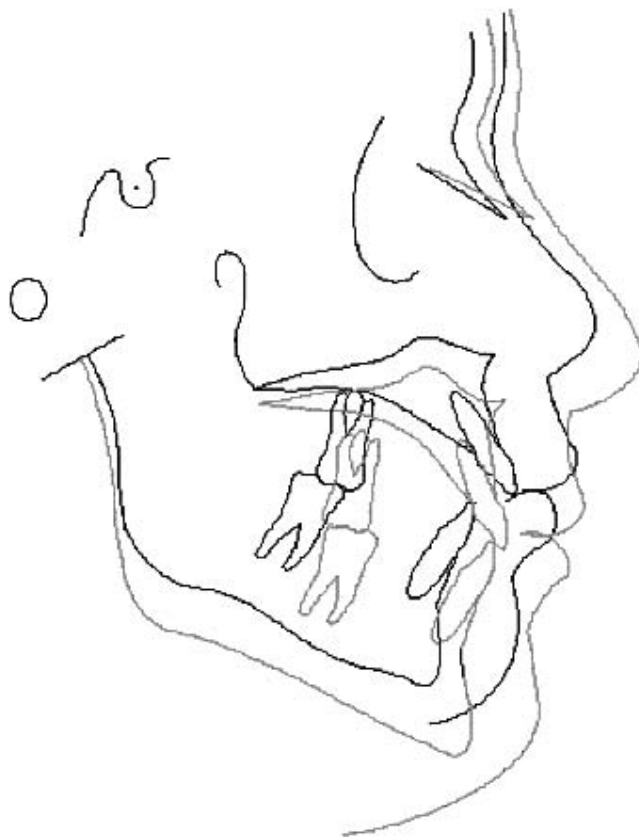


Figure 4. Superimposition of cephalometric tracings of a skeletal Class II patient treated with rapid followed by slow maxillary expansions showing the inclination of the palatal plane.

The SNA angle is expected to remain unchanged or even increase without treatment.¹⁷ Chung and Wong¹⁸ found that the SNA angle increased from ages 9 to 18 years in untreated skeletal Class II subjects. Although in support of the efficacy of Class II treatment with cervical headgear, some investigators found small differences in SNA reduction.^{19,20} Differences in results can be attributed to the types of appliances, treatment duration, daily hours of headgear wear, and amount of force applied. According to Riolo et al²¹ during normal growth, the SNA angle increases 0.4° in male patients and 0.3° in female patients from 10 to 13 years of age. Over the long-term, in the present investigation, the SNA angle increased 0.9°.

The effects of skeletal Class II correction in the SN-PP angle with slow and rapid maxillary expansions for the entire sample were statistically significant for T₁–T₂ with an increase of 1.7° and for T₂–T₃ with a decrease of 0.7°. Several studies observed similar changes in the SN-PP angle in patients treated with cervical headgear.^{22,23} During normal growth the palatal plane descends in a parallel manner to the cranial base.^{24,25} Other studies on untreated Class I patients

showed small increases in the SN-PP angle, but these changes were not clinically relevant.^{21,26}

The anterior descent of the PP probably occurred due to the posterior and inferior repositioning of maxillary growth by the action of cervical traction. Although the forces produced distally on the upper molars cause molars to erupt downward and backward, they inhibit the lowering of the posterior region of the maxilla, while the anterior region continues to move downward during growth (Figure 4).²⁷ Aspects such as the age of the patient at the beginning of treatment and the patient's compliance may have contributed to the SN-PP angle increase.

CONCLUSIONS

- Skeletal Class II treatment with slow and rapid maxillary expansions associated with cervical headgear was efficient and stable over the long-term.
- The profiles of the SNA and SN-PP angles throughout the pretreatment, posttreatment, and postretention phases were clinically equivalent with both slow and rapid maxillary expansion.

REFERENCES

- Baccetti T, Franchi L, McNamara JA Jr, Tollaro I. Early dentofacial features of Class II malocclusion: a longitudinal study from the deciduous through the mixed dentition. *Am J Orthod Dentofacial Orthop.* 1997;111:502–509.
- Zimring JF, Isaacson RJ. Forces produced by rapid maxillary expansion. *Angle Orthod.* 1965;35:178–186.
- Biederman W. Rapid correction of Class III malocclusion by palatal expansion. *Am J Orthod.* 1973;63:47–55.
- Haas AJ. Rapid expansion of the maxillary dental arch and nasal cavity by opening the mid-palatal suture. *Angle Orthod.* 1961;31:73–90.
- Haas AJ. Maxillary expansion: just the beginning of dentofacial orthopedics. *Am J Orthod.* 1970;57:219–255.
- Gianelly AA. *Bidimensional Technique: Theory and Practice.* New York, NY: GAC International Inc; 2000:121.
- Mills CM, Holman RO, Graber TM. Heavy intermittent cervical traction in Class II treatment: a longitudinal cephalometric assessment. *Am J Orthod.* 1978;74:361–379.
- Schudy FF. The control of vertical overbite in clinical orthodontics. *Angle Orthod.* 1968;38:19–39.
- Cook AH, Sellke TA, Begole EA. Control of the vertical dimension in Class II correction using a cervical headgear and lower utility arch in growing patients. *Am J Orthod Dentofacial Orthop.* 1994;106:376–388.
- Klein PL. An evaluation of cervical traction on the maxilla and the upper first permanent molar. *Angle Orthod.* 1957;27:61–68.
- Boecler PR, Riolo ML, Keeling SD, Tenhave TR. Skeletal changes associated with extraoral appliance therapy: an evaluation of 200 consecutively treated cases. *Angle Orthod.* 1989;59:263–270.
- Kirjavainen M, Kirjavainen T. Maxillary expansion in Class II correction with orthopedic cervical headgear. A postero-anterior cephalometric study. *Angle Orthod.* 2003;73:281–285.
- Thurrow RC. Cephalometric method in research and private practice. *Angle Orthod.* 1951;21:104–116.
- Johnson RA, Wichern DW. *Applied Multivariate Statistical Analysis.* 3rd ed. Englewood Cliffs, NJ: Prentice Hall; 1992:222.
- Turley PK. Orthopedic correction of Class III malocclusion: retention and phase II therapy. *J Clin Orthod.* 1996;30:313–324.
- Hubbard GW, Nanda RS, Currier GF. A cephalometric evaluation of nonextraction cervical headgear treatment in Class II malocclusions. *Angle Orthod.* 1994;64:359–370.
- Ricketts RM. The influence of orthodontic treatment on facial growth and development. *Angle Orthod.* 1960;30:103–133.
- Chung CH, Wong WW. Craniofacial growth in untreated skeletal Class II subjects: A longitudinal study. *Am J Orthod Dentofacial Orthop.* 2002;122:619–626.
- Caldwell S, Hyman F, Alan T, Timm TA. Maxillary traction splint: a cephalometric evaluation. *Am J Orthod.* 1984;85:376–384.
- Kirjavainen M, Kirjavainen T, Hurmerinta K, Haavikko K. Orthopedic cervical headgear with an expanded inner bow in Class II correction. *Angle Orthod.* 2000;70:317–325.
- Riolo ML, Moyers RE, McNamara JA Jr, Hunter WS. *An Atlas of Craniofacial Growth: Cephalometric Standards From The University School Growth Study.* Monograph 2, Craniofacial Growth Series. Ann Arbor, Mich: The Center for Human Growth and Development, The University of Michigan; 1974.
- Baumrind S, Korn EL, Isaacson RJ, West EE, Molthen R. Quantitative analysis of the orthodontic and orthopedic effects of maxillary traction. *Am J Orthod.* 1983;84:384–398.
- Cangialosi TJ, Meistrell ME, Leung MA, Ko JY. A cephalometric appraisal of edgewise Class II nonextraction treatment with extraoral force. *Am J Orthod.* 1988;93:315–324.
- Björk A. Sutural growth of the upper face studied by the implant method. *Acta Odontol Scand.* 1966;24:49–65.
- Enlow DH, Seong B. Growth and remodeling of the human maxilla. *Am J Orthod.* 1965;51:446–464.
- Nanda RS, Merrill RM. Cephalometric assessment of sagittal relationship between maxilla and mandible. *Am J Orthod Dentofacial Orthop.* 1994;105:328–344.
- Lima Filho RMA, Lima AL, Ruellas ACO. Longitudinal study of anteroposterior and vertical maxillary changes in skeletal Class II patients treated with Kloehn cervical headgear. *Angle Orthod.* 2003;73:187–193.