

# Comparison of Skeletal and Dental Morphology in Asymptomatic Volunteers and Symptomatic Patients with Unilateral Disk Displacement with Reduction

Ioanna K. Gidakou, DDS<sup>a</sup>; Ross H. Tallents, DDS<sup>b</sup>; Scott Stein, DMD<sup>c</sup>;  
Stephanos Kyrkanides, DDS, PhD<sup>d</sup>; Mark E. Moss, DDS, PhD<sup>e</sup>

**Abstract:** The purpose of this study was to evaluate the effect of unilateral disk displacement with reduction (UDDR) on the skeletal and dental pattern of affected individuals. There were 18 symptomatic female patients and 46 asymptomatic normal female volunteers. All study participants had bilateral high-resolution magnetic resonance scans in the sagittal (closed and open) and coronal (closed) planes to evaluate the temporomandibular joints. Linear and angular cephalometric measurements were taken to evaluate the skeletal, denture base, and dental characteristics of the two groups. Analysis of variance was used to compare the symptomatic with the control subjects. A few skeletal differences were found. There was an overall reduction in length of the anterior (S-Na) and posterior (S-Ba) cranial base measurements in the UDDR group. The cranial base angle was also increased. Both upper and lower dentures bases were repositioned. The posterior ramal height (Ar-Go) was shorter in the symptomatic group. This study showed that alterations in skeletal morphology may be associated with UDDR. The mechanisms that produce DD or the mechanisms that cause this skeletal alteration are yet to be clarified. This study suggests that subjects with UDDR may manifest altered craniofacial morphology. The clinician should be aware of this possibility, especially for growing patients. (*Angle Orthod* 2004;74:212–219.)

**Key Words:** Cephalometrics; Unilateral; Joint; Disk; Reducing; Morphology

## INTRODUCTION

Temporomandibular joint disorder (TMD) is a collective term embracing a number of clinical problems that involve

<sup>a</sup> Resident, Department of Dentistry, Division of Orthodontics, University of Rochester School of Medicine and Dentistry, Rochester, NY.

<sup>b</sup> Professor, Department of Dentistry, Division of Orthodontics and Prosthodontics, Program Director Temporomandibular Joint Disorders, University of Rochester School of Medicine and Dentistry, Rochester, NY.

<sup>c</sup> Clinical Instructor, Department of Dentistry, Division of Orthodontics, University of Rochester School of Medicine and Dentistry, Rochester, NY.

<sup>d</sup> Assistant Professor, Department of Dentistry, Assistant Chief of Division of Orthodontics, Craniofacial Research Core Coordinator, University of Rochester School of Medicine and Dentistry, Rochester, NY.

<sup>e</sup> Assistant Professor, Department of Dentistry and Community and Preventive Medicine, University of Rochester School of Medicine and Dentistry, Rochester, NY.

Corresponding author: Ross Tallents, DDS, 625, Elmwood Avenue, Eastman Dental Center, Rochester, NY 14620 (e-mail: ross.tallents@urmc.rochester.edu).

The University of Rochester Research Subjects Review Board reviewed and approved the present study.

Accepted: May 2003. Submitted: June 2002.

© 2004 by The EH Angle Education and Research Foundation, Inc.

the masticatory musculature, the temporomandibular joint (TMJ) and associated structures, or both.<sup>1</sup> Disk displacement with reduction (DDR) is frequently associated with a clicking sound, and DD without reduction (DDN) is often associated with the limitation of jaw opening.<sup>2</sup> Previous studies have suggested that DDN is a more advanced stage of pathology in the TMJ and may progress to osteoarthritis.<sup>3–6</sup>

Autopsy studies in both young and mature adults show DD in 10–32% of the general population.<sup>7,8</sup> Several studies have suggested that DD occurs in asymptomatic subjects with a prevalence ranging from 10% to 33%.<sup>9–15</sup> The reported high prevalence of DD in asymptomatic volunteers (AV) is not unique to the TMJ. Magnetic resonance imaging (MRI) studies of asymptomatic subjects in the knee, cervical spine, and lumbar spine indicate similar disease prevalences in asymptomatic subjects.<sup>16–22</sup> These studies demonstrate that DD can be present in patients without clinical signs and symptoms. On the other hand, it has been shown that not all TMJ pain, clicking, and limited jaw motion in symptomatic patients can be related to DD within the TMJ. Paesani et al<sup>23</sup> studied 115 patients with signs and symptoms of TMD and found that 78% had unilateral or bilateral DD (UDD or BDD) but 22% had bilaterally normal TMJs.

DD has been suggested to affect skeletal morphology. Nebbe et al<sup>24</sup> suggested that adolescent female patients presenting for orthodontic treatment with BDD show numerous angular and linear cephalometric differences compared with aged-matched female controls. Nebbe et al<sup>25</sup> and Trpkova et al<sup>26</sup> also demonstrated that associations exist between subjects with DD and craniofacial morphology in an adolescent sample of female orthodontic patients. Schellhas et al<sup>27</sup> and Dibbets et al<sup>28</sup> suggested that there are morphologic changes in children with DD and symptoms, respectively. Recently, Henrikson et al<sup>29</sup> demonstrated that subjects with Class II malocclusions have an increase in TMD symptoms compared with subjects with a normal occlusion. In fact, 87% of the Class II sample had a horizontal overlap of more than four mm, suggesting a sagittal growth discrepancy.

Brand et al,<sup>30</sup> Bosio et al,<sup>31</sup> and Gidakou et al<sup>32</sup> also suggested that there are skeletal changes associated with DD. Patients referred for orthognathic surgery have also shown a high prevalence of DD,<sup>5,33</sup> and animal studies have suggested that there are morphologic changes associated with surgically created DD.<sup>34-38</sup> UDD may be associated with skeletal asymmetry as shown by clinical<sup>39</sup> and animal studies.<sup>38,40</sup>

MRI was used in this study to validate the presence or absence of DD. Roberts et al<sup>41</sup> demonstrated that the ability to predict the presence or absence of DD in patients has a sensitivity and specificity of 59% and 38% for symptomatic normals, 60% and 66% for DDR, and 58% and 76% for DDN, respectively. This would suggest that the ability to predict DD is low and the number of false-positive and false-negative examinations is high. This study will evaluate AV and symptomatic subjects with UDD with reduction (UDDR) presenting with localized jaw joint pain for skeletal and dental morphologic changes.

## MATERIALS AND METHODS

The parent database included 46 Caucasian female AV and 202 Caucasian consecutive symptomatic female temporomandibular disorder patients who answered a solicitation posted at the University of Rochester and Eastman Department of Dentistry. The symptomatic TMD patients included 42 symptomatic but normal patients, 18 patients with UDDR, 12 with UDDN, 59 with BDDN, 32 with BDDR, and 29 with BDDN with degenerative joint disease.

This study included 46 Caucasian normal female AV and 18 Caucasian symptomatic age-matched women with UDDR included in this study.

The mean age of the AV subjects was  $28.3 \pm 6.7$  years, whereas the mean age of the symptomatic subjects was  $29.2 \pm 10.7$  years. All study participants were examined in the Division of Orthodontics and were not seeking orthodontic care. They read and signed an informed consent before the study initiation that was approved by the Research Subjects

Review Board of the University of Rochester School of Medicine and Dentistry.

The AV were examined by one investigator (RHT) and were accepted in the study after completion of the following:

- A TMJ subjective questionnaire documenting the absence of jaw pain, joint noise, locking, and positive history of TMD
- A clinical TMJ and dental examination for signs and symptoms commonly associated with TMD or internal derangement. All symptomatic subjects had localized jaw joint pain and pain on movement or when eating. Vertical opening and right and left mandibular movements were measured and recorded. The masseter, anterior, middle and posterior temporalis, and temporalis tendon area were digitally palpated. All AV demonstrated a maximal opening of at least 40 mm. The asymptomatic and symptomatic subjects were not blinded to the examiner. There were no volunteers with complete or removable dentures or fixed partial dentures. Nineteen percent of the asymptomatic subjects and 25% of the symptomatic patients had one or two missing posterior teeth. The prevalence of previous orthodontic treatment was 37% in the volunteers and 25% in the symptomatic TMD subjects.
- All study participants had bilateral high-resolution MRI scans in the sagittal (closed and open) and coronal (closed) planes to evaluate the TMJs as described by Katzberg et al<sup>42</sup> and Westesson et al.<sup>43</sup> Each study participant was classified as AV or symptomatic BDDR.
- All study participants had lateral cephalograms with the teeth in centric occlusion position and with Frankfort horizontal parallel to the floor. All cephalograms were taken at the Orthodontic Clinic on the same radiographic machine set for standardized exposure.

## Null hypothesis

There are no statistically significant differences among skeletal, denture base, and dental characteristics of symptomatic UDDR patients compared with a sample of individuals with bilateral normal asymptomatic TMJs.

## Cephalometric measurements

Figure 1 shows the cephalometric landmarks used. Tables 1 through 5 summarize the angular and linear cephalometric measurements used in this study. These measurements were categorized as cranial base measurements, profile analysis, denture base, dental pattern, and vertical relationship measurements. The examiner was blinded as to whether the films were from an AV or symptomatic TMD subject.

## Statistical method

The analysis of variance was used to reveal any statistically significant differences between the control group and

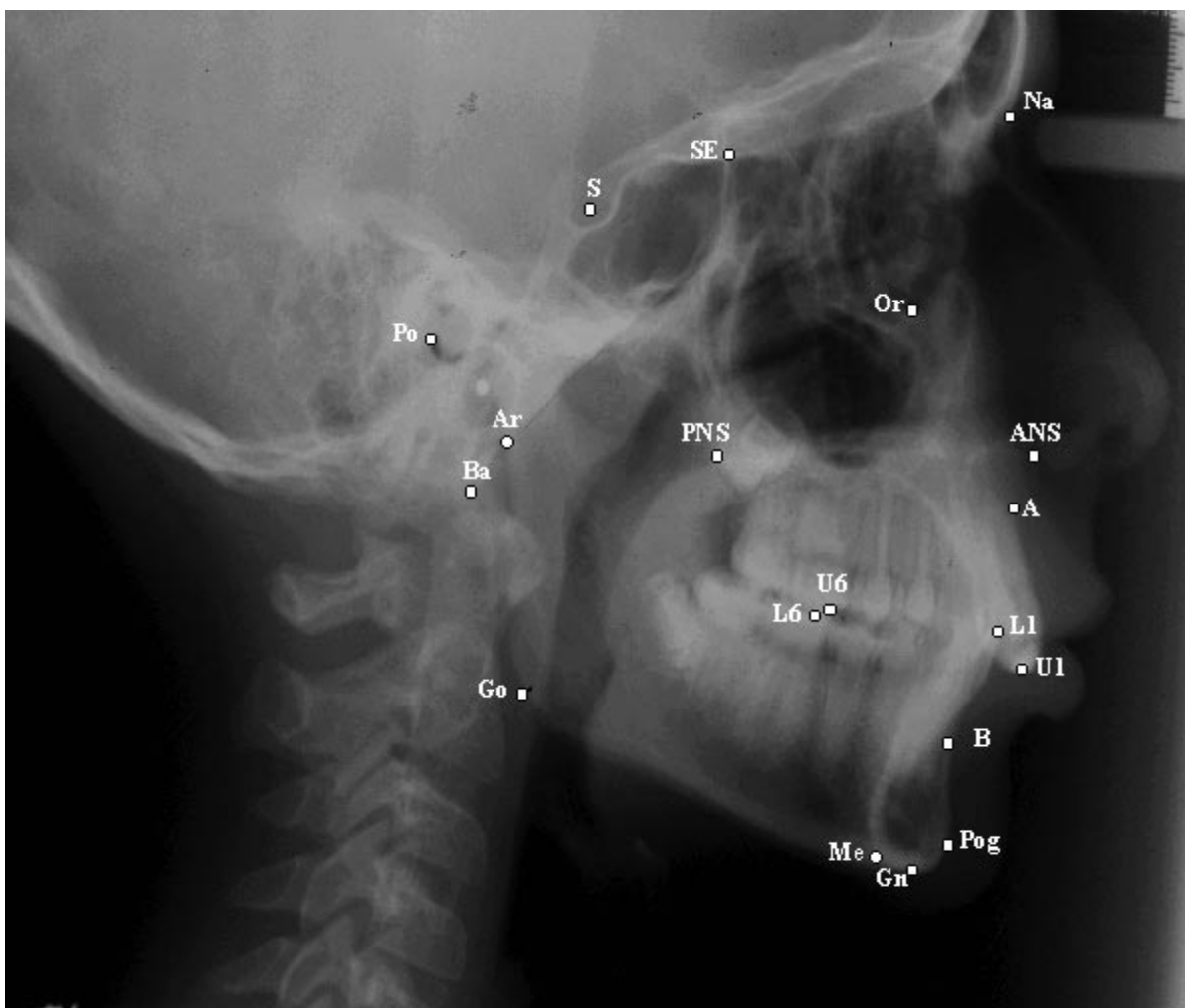


FIGURE 1. Cephalometric landmarks used.

the experimental group. All subjects were matched for age. The *P* value was calculated for each of the variables with a level of significance for each test established at .05. There was no power analysis performed because this would require preliminary data.

**Error of measurement**

Errors in landmark localization during tracing were evaluated by retracing 20 cephalograms in the experimental and control groups. The reliability of tracing, landmark identi-

TABLE 1. Cranial Base Measurements

Measurements	AV-N		UDDR	
	Mean	SD	Mean	SD
S-Na	73.1	3.3	71.1*	3.1
Ba-Na	110.1	4.7	107.6	3.8
Ba-S	47.2	2.5	45.2*	2.5
Ba-S-Na	131.7	5.1	134.6*	4.7

\* *P* ≤ .05; \*\* *P* ≤ .01; \*\*\* *P* ≤ .001.

TABLE 2. Profile Analysis

Measurements	AV-N		UDDR	
	Mean	SD	Mean	SD
FH to Na-Pg	89.2	3.1	88.7	2.7
FH to Na-A	90.7	3.0	90.2	3.7
Na-A-Pog	3.0	6.2	3.3	5.5

TABLE 3. Denture Base Measurements

Measurements	AV-N		UDDR	
	Mean	SD	Mean	SD
ANS-PNS	56.3	3.8	54.7	2.9
SNA	81.8	3.7	79.2***	4.5
SNB	79.2	3.7	76.4***	4.0
ANB	2.6	2.5	2.8	1.9
A-B to FP	-5.0	3.5	-5.3	2.7

\* *P* ≤ .05; \*\* *P* ≤ .01; \*\*\* *P* ≤ .001.

**TABLE 4.** Denture Pattern

Measurements	AV-N		UDDR	
	Mean	SD	Mean	SD
FH to OP	5.1	3.7	6.8	4.9
U1 to L1	128.2	8.4	131.0	12.5
U1 to PP	109.2	6.8	108.1	9.2
U1 to FH	110.7	6.9	110.2	8.0
U1 to S-Na	101.8	6.9	99.1	9.2
U1 to A-Pog	23.3	6.7	23.2	7.4
U1 perpendicular to A-Pog	7.4	2.1	7.5	3.0
L1 to MP	5.9	7.2	1.8	8.2
L1 to OP	25.1	6.9	22.1	7.9
L1 to A-Pg	27.7	4.4	25.7	6.5
L1 perpendicular to A-Pog	4.1	1.8	4.4	2.8
Overbite (perpendicular to FH)	2.9	1.7	2.7	1.6
Overjet (parallel to FH)	3.07	1.18	2.8	2.4

**TABLE 5.** Vertical Relationships

Measurements	AV-N		UDDR	
	Mean	SD	Mean	SD
MP to FH	24.4	4.9	27.0	5.6
S-Gn to FH	58.0	2.9	59.1	3.3
Na-ANS (UFH)	53.8	3.1	54.1	2.7
ANS-Me (LFH)	66.0	4.8	66.1	4.0
Na-Me (TFH)	119.8	5.5	120.2	5.4
UFH:TFH	44.9	2.4	45.0	1.6
SE-PNS	49.2	3.2	48.7	3.4
Ar-Go	47.9	5.1	44.2**	4.1
U6 perpendicular PP	23.5	1.9	23.7	2.5
U1 perpendicular PP	29.2	2.7	29.4	2.5
L6 perpendicular MP	32.4	2.4	31.1	1.7
L1 perpendicular MP	42.0	2.5	41.9	2.9
PP to OP	6.7	3.8	8.8	5.4
PP to MP	25.9	5.0	29.0	5.7
PP to FH	-1.1	3.5	-2.1	3.7
Ar-Go-Gn	126.5	5.6	128.2	5.5
Antigonial notch	171.7	7.6	173.5	6.4

\*  $P \leq .05$ ; \*\*  $P \leq .01$ ; \*\*\*  $P \leq .001$ .

fication, and analytical measurements had an intraclass correlation coefficient greater than 0.92.

## RESULTS

Tables 1 through 5 summarize the findings of the measurements. Table 1 demonstrates that there are cranial base differences between the two groups. The anterior (S-Na) and posterior (Ba-S) cranial base lengths were reduced for the UDDR group. The cranial base flexure was more obtuse in the symptomatic group. SNA and SNB were smaller in the UDDR group (Table 3). These two denture base measurements demonstrate that both the maxillary and the mandibular denture bases were retruded in the symptomatic group. The measurements of the vertical relationships showed a shorter ramal height in the UDDR subjects (Table 5). No significant differences were found in the profile analysis and the denture base measurements and the denture

pattern. The significant measurements are shown in Figures 2 through 4.

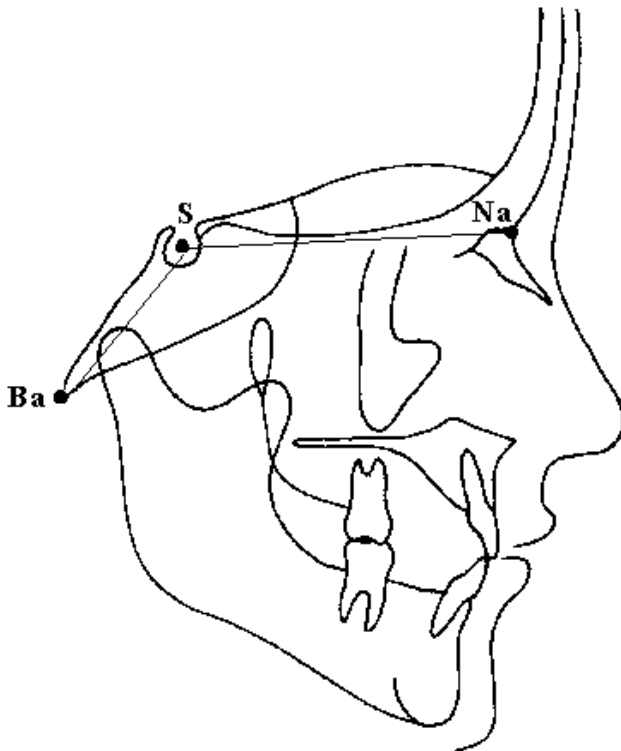
## DISCUSSION

There is quite a high prevalence of DD in the asymptomatic population. Westesson et al<sup>9</sup> found 15% of their AV to have UDD using TMJ arthrography. Tallents et al<sup>10</sup> in a study of evaluation of TMJ sounds in AV found that 24% had one or two joints with DD as diagnosed by MRI. Kircos et al<sup>15</sup> found a 32% prevalence of DD in AV. Ribeiro et al<sup>11</sup> found the prevalence of DD in asymptomatic children and young adults to be 34%, whereas 86% of the symptomatic temporomandibular disorder patients had DD. Their results showed that 13.8% had bilateral symptomatic but normal joints, 28% had UDD, and 58% had BDD. They suggested that DD is relatively common in AV (34%).

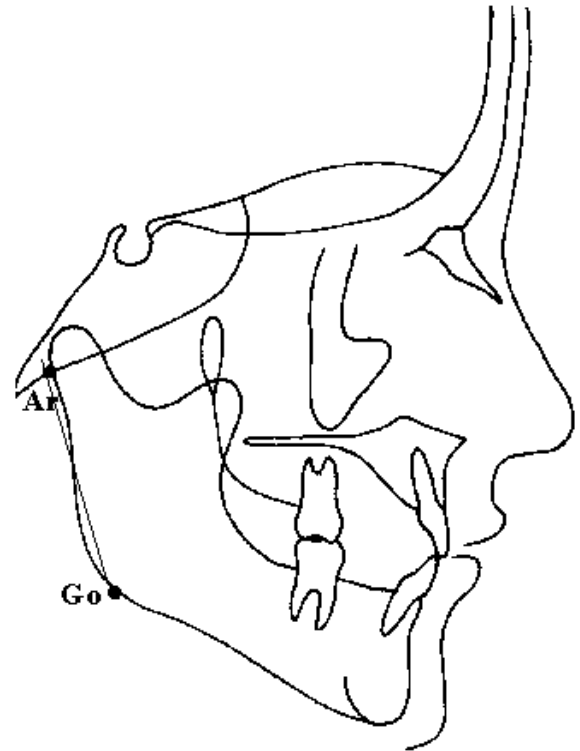
A high prevalence of DD in AV is not unique to the TMJ. MRI studies of asymptomatic subjects in the knee, cervical spine, and lumbar spine indicate similar disease prevalences in asymptomatic subjects in those body parts as well.<sup>16-21</sup> Brunner et al<sup>22</sup> showed that half the asymptomatic athletes included in the study had significant baseline knee MRI scan abnormalities. Oberg et al<sup>7</sup> macroscopically examined the right TMJs of 155 cadavers of different ages with respect to the shape, size, and appearance of the joint surfaces. They found that with increasing age, the number of joints with local changes in shape, remodeling, or arthritic changes of the articular surfaces increased. The arthritic changes were significantly more prevalent in women.

DD has been suggested to cause altered skeletal morphology.<sup>5,25-27,31,32</sup> In this study, we evaluated the effect of UDDR on the skeletal and dental pattern of the affected individuals. There were significant cranial base differences between the two groups. Both anterior (S-Na) and posterior (Ba-S) cranial base measurements were smaller in the UDDR patients. The cranial base flexure was more obtuse, as shown by the increased value of the Ba-S-Na angle. This agrees with Nebbe et al,<sup>25</sup> who found decreased Ba-Na length. In our study of UDDN and BDDR, both S-Na and Ba-Na measurements were smaller.<sup>32</sup> Thus, there are skeletal alterations in the cranial base of symptomatic patients with DD, with or without reduction.

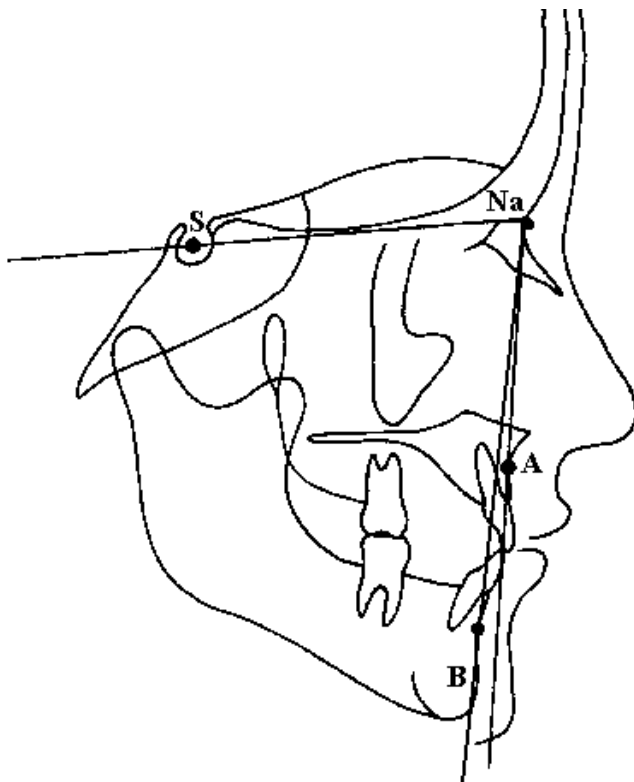
We found retrusion of the upper and lower denture bases (smaller SNA and SNB angles, respectively). This finding agrees with our previous studies on BDDR<sup>32</sup> and bilateral degenerative joint disease<sup>32</sup> (BDJD) patients, where both the previously mentioned angles were smaller compared with asymptomatic normal individuals. However, in the BDJD patients there was a significantly larger ANB angle because of a more retropositioned point B (I. K. Gidarakou et al, in preparation). Bosio et al<sup>31</sup> also found a smaller mean SNB angle in patients with BDD compared with AV. On the contrary, in our study of UDDN, we found no sig-



**FIGURE 2.** Significant measurements of the cranial base (S-Na, Ba-S, Ba-S-Na).



**FIGURE 4.** Significant measurements of the vertical relationships (Ar-Go).



**FIGURE 3.** Significant measurements of the denture base (SNA, SNB).

nificant differences for the SNA and SNB angles (I. K. Gidakou et al, in preparation).

There were also significant differences in the vertical relationships. The posterior ramal height (Ar-Go) was shorter in the symptomatic group. We did not distinguish the left from the right side, but we may attribute the shortness of the posterior ramal height to the DD. This agrees with our previous studies on BDDN, BDJD, and UDDN patients (I. K. Gidakou et al, in preparation). The previously mentioned groups with BDD or UDD (BDDN, BDJD, and UDDN) showed reduced ramal heights. These patients (UDDN, BDDN, and BDJD) showed more significant differences in addition to the reduced ramal height (I. K. Gidakou et al, in preparation). For example, the mandibular plane was steeper in all three groups of symptomatic patients. We can then speculate that the patients with UDDR exhibit the least vertical changes as compared with the patients with UDDN, BDDN, and BDJD because the alterations in their TMJs are not that severe. Dibbets et al<sup>28</sup> and Nebbe et al<sup>25</sup> have also reported shorter ramal heights in children and adolescents presenting with degenerative joint disease and DD, respectively. Animal models with DD also showed reduced ramal height. Shortening and flattening of the condylar head with loss of posterior height have been demonstrated in the growing rabbit after unilateral surgically created DD.<sup>38,40</sup> Legrell et al<sup>40</sup> found that rabbits with surgically created UDD exhibited a deviant growth pattern and mandibular asymmetry. They concluded that UDD can

cause mandibular asymmetry in growing rabbits, including shortening of the ramus and excessive vertical growth along the lower mandibular border and the gonial angle region. This agrees with the clinical study by Trpkova et al,<sup>26</sup> who investigated the amount of craniofacial asymmetry in female orthodontic patients with unilateral or bilateral TMJ DD compared with female controls without DD, using frontal radiographs. Women with BDD had significantly greater asymmetry in the vertical position of the antegonion. If the DD was more advanced on one side, then the ipsilateral ramus was shorter, resulting in significant asymmetry of the mandible. The authors concluded that a female patient with UDD or BDD may present with or develop a vertical mandibular asymmetry. Tallents et al<sup>39</sup> studied 12 consecutive patients presenting with facial asymmetry thought to represent unilateral condylar hyperplasia. However, half these patients were found to have UDD occurring on the short side. Therefore, the clinician should be aware of the possibility of the presence of DD in asymmetric patients.

Our study agrees with previous studies that have suggested that DD can affect skeletal morphology and symmetry. Link and Nickerson<sup>5</sup> and Schellhas et al<sup>27</sup> have suggested that there is a cause and effect relationship between DD and facial growth. Nebbe et al<sup>25</sup> have suggested that adolescent female patients presenting for orthodontic treatment with BDD show numerous angular and linear cephalometric differences compared with aged-matched female controls. There was an increased mandibular and palatal plane relative to sella-nasion, posterior rotation of the mandible, a decrease in Rickett's facial axis, reduced posterior facial height and ramal height, as well as a slight increase in middle anterior facial height and a decreased posterior cranial base height.<sup>25</sup> Schellhas et al<sup>27</sup> in their study of children 14 years or younger concluded that TMJ derangements are both common in children and may contribute to the development of retrognathia, with or without asymmetry. In cases of lower-face asymmetry, the chin was uniformly deviated toward the smaller or more degenerated TMJ. They proposed that in the growing facial skeleton, DD either retards or arrests condylar growth, which results in decreased vertical dimension in the proximal mandibular segment(s), with mandibular deficiency or asymmetry occurring ultimately.<sup>27</sup> Dibbets et al<sup>28</sup> showed that children with symptoms of dysfunction form a morphologically clearly recognizable group. Their profile was more Class II, and they had a shorter corpus and ramus and exhibited decreased posterior facial height. They concluded that TMJ dysfunction might be associated with the growth of the mandible.<sup>28</sup> Brand et al<sup>30</sup> indicated that patients with DD had significantly shorter maxillary and mandibular lengths compared with asymptomatic normal individuals with normal TMJs. That investigation did not distinguish between UDD and BDD and could not account for any asymmetries because the right and left landmarks in the cephalometric radiograph were averaged.

Increased prevalence of DD has been found in patients with mandibular retrognathia presenting for orthognathic surgery. Link and Nickerson<sup>5</sup> studied 39 patients referred for orthognathic surgery, 38 of whom were found to have DD before surgery. All their open-bite patients and 88% of the patients with Class II malocclusion had BDD. They suggested that DD may be a contributing factor in the development of dentofacial deformities and that new loading of deranged joints after orthognathic surgery may be a cause of a new arthrosis and skeletal relapse, suggesting a progression of TMJ pathology. They suggested that DD should be suspected in individuals with sagittal mandibular deficiency, vertical ramus deficiency, or a unilateral sagittal deficiency.

The high degree of association of DD with mandibular deficiency suggests that DD may have a role in causing these deformities. That is, loss of condylar height or growth secondary to the DD caused or worsened the horizontal or vertical ramus mandibular deficiency.<sup>5</sup> Schellhas et al,<sup>33</sup> in their retrospective study of 100 consecutive orthognathic surgery candidates found that DD was prevalent, especially in patients who exhibited change in their facial contour in the year before the evaluation. The degree of joint degeneration directly paralleled the severity of retrognathia. They concluded that TMJ DD is common in cases of mandibular retrusion and leads to the facial morphology in a high percentage of patients.

## CONCLUSIONS

The results of this study show that alterations in skeletal morphology may be associated with UDDR. This finding agrees with previous studies. The mechanisms by which DD is produced, or the mechanisms that cause that skeletal alteration, are yet to be clarified. We found altered skeletal morphology in our symptomatic sample with UDDR. Other studies have also demonstrated that DD may cause facial asymmetry. This study and the studies mentioned suggest that UDDR may affect the skeletal morphology, symmetry, and growth pattern of the affected individual. The clinician should be aware of these possibilities, especially while treating children and orthognathic surgery candidates.

## REFERENCES

1. Okesson JP. *Orofacial Pain. Guidelines for Assessment, Diagnosis and Management*. Carol Stream, Ill: Quintessence Publishing Co Inc; 1996: 116.
2. Katzberg RW, Westesson PL, Tallents RH, Drake CM. Orthodontics and temporomandibular joint disorders. *Am J Orthod Dentofacial Orthop*. 1996;109:515-520.
3. Westesson P-L, Rohlin M. Internal derangement related to osteoarthritis in temporomandibular joint autopsy specimens. *Oral Surg*. 1984;57:17-22.
4. Eriksson L, Westesson P-L. Clinical and radiologic study of patients with anterior disk displacement of the temporomandibular joint. *Swed Dent J*. 1983;7:55-64.
5. Link JJ, Nickerson JW Jr. Temporomandibular joint internal de-

- rangements in an orthognathic surgery population. *Int J Adult Orthod Orthognath Surg*. 1992;7:161-169.
6. Yamada K, Hiruma Y, Hanada K, Hayashi T, Koyama J, Ito J. Condylar bony change and craniofacial morphology in orthodontic patients with TMD symptoms: a pilot study using helical computed tomography and magnetic resonance imaging. *Clin Orthod Res*. 1999;2:133-142.
  7. Oberg T, Carlsson GE, Fajers CM. The temporomandibular joint. A morphometric study on a human autopsy material. *Acta Odontol Scand*. 1971;29:349-384.
  8. Solberg WK, Hansson TL, Nordstrom B. The temporomandibular joint in young adults at autopsy: a morphologic classification and evaluation. *J Oral Rehabil*. 1985;12:303-321.
  9. Westesson PL, Eriksson L, Kurita K. Reliability of a negative clinical temporomandibular joint examination: prevalence of disk displacement in asymptomatic temporomandibular joint. *Oral Surg Oral Med Oral Pathol*. 1989;68:551-554.
  10. Tallents RH, Hatala M, Katzberg RW, Westesson PL. Temporomandibular joint sounds in asymptomatic volunteers. *J Prosthet Dent*. 1993;69:298-304.
  11. Ribeiro RF, Tallents RH, Katzberg RW, Murphy WC, Moss ME, Magalhaes AC, Tavano O. The prevalence of disk displacement in symptomatic and asymptomatic volunteers aged 6 to 25 years. *J Orofacial Pain* 1997;11:37-46.
  12. Tallents RH, Katzberg RW, Murphy W, Proskin H. Magnetic resonance imaging findings in asymptomatic volunteers and symptomatic patients with temporomandibular disorders. *J Prosthet Dent*. 1996;75:529-533.
  13. Katzberg RW, Westesson PL, Tallents RH, Drake CM. Orthodontics and temporomandibular joint internal derangement. *Am J Orthod Dentofacial Orthop*. 1996;109:515-520.
  14. Morrow D, Tallents RH, Katzberg RW, Murphy WC, Hart TC. Relationship of other joint problems and anterior disk displacement in symptomatic TMD patients and in asymptomatic volunteers. *J Orofacial Pain* 1996;10:15-20.
  15. Kircos LT, Ortendhal DA, Mark A, Arakawa M. Magnetic resonance imaging of the TMJ disk in asymptomatic volunteers. *J Oral Maxillofac Surg*. 1987;45:852-854.
  16. Nagendak WG, Fernandez FR, Halburn LK, Teitge RA. Magnetic resonance imaging of meniscal degeneration in asymptomatic knees. *J Orthop Res*. 1990;8:311-312.
  17. Kornick J, Trefelner ME, McCarty S, Lang R, Lynch K, Jokl P. Meniscal abnormalities in the asymptomatic population in MR imaging. *Radiology* 1990;177:463-465.
  18. Boden SD, Davis DO, Dina TS, Staller DW, Brown SD, Vailas JC, Labropoulos PA. A prospective and blinded investigation of magnetic resonance imaging of the knee: abnormal findings in asymptomatic subjects. *Clin Orthop*. 1992;282:177-185.
  19. Shellock FG, Morris E, Deutsch AL, Mink JH, Kerr R, Boden SD. Hematopoietic marrow hyperplasia: high prevalence on MR images of the knee in asymptomatic marathon runners. *Am J Roentgenol*. 1992;158:335-338.
  20. Boden SD, McCowin PR, Davis DO, Dina TS, Mark AS, Wiesel S. Abnormal magnetic resonance scans of the cervical spine in asymptomatic subjects. *J Bone Joint Surg (Am)*. 1990;72:1174-1184.
  21. Boden SD, Davis DO, Dina TS, Patronas NJ, Wiesel SW. Abnormal magnetic resonance scans of the lumbar spine in asymptomatic subjects: a prospective investigation. *J Bone Joint Surg (Am)*. 1990;72:403-408.
  22. Brunner MC, Flower SP, Evancho AM, Allman FL, Apple DF, Fajman WA. MRI of the athletic knee. Findings in asymptomatic professional basketball and collegiate football players. *Invest Radiol*. 1989;24:72-75.
  23. Paesani D, Westesson PL, Hatala M, Tallents RH, Kurita K. Prevalence of temporomandibular joint internal derangement in patients with craniomandibular disorders. *Am J Orthod Dentofacial Orthop*. 1992;101:41-47.
  24. Nebbe B, Major PW, PrasadNGN. Adolescent female craniofacial morphology associated with advanced bilateral TMJ disk displacement. *Eur J Orthod*. 1998;20:701-712.
  25. Nebbe B, Major PW, PrasadNGN. Female adolescent facial pattern associated with TMJ disk displacement and reduction in disk length: part I. *Am J Orthod Dentofacial Orthop*. 1999;116:168-176.
  26. Trpkova B, Major P, Nebbe B, Prasad N. Craniofacial asymmetry and temporomandibular internal derangement in female adolescents: a posteroanterior cephalometric study. *Angle Orthod*. 2000;70:81-88.
  27. Schellhas KP, Pollei SR, Wilkes CH. Pediatric internal derangements of the temporomandibular joint: effect on facial development. *Am J Orthod Dentofacial Orthop*. 1993;104:51-59.
  28. Dibbets JMH, Van Der Wee LT, UildriksAKJ. Symptoms of TMJ dysfunction: indicators of growth patterns? *J Pedod*. 1985;9:265-284.
  29. Henrikson T, Ekberg E, Nilner M. Symptoms and signs of temporomandibular disorders in girls with normal occlusion and class II malocclusion. *Acta Odontol Scand*. 1997;55:229-235.
  30. Brand JW, Nielson KJ, Tallents RH, Nanda RS, CurrierGFC, Owen WL. Lateral cephalometric analysis of skeletal patterns in patients with and without internal derangement of the temporomandibular joint. *Am J Orthod Dentofacial Orthop*. 1995;107:121-128.
  31. Bosio JA, Burch JG, Tallents RH, Wade DB, Beck FM. Lateral cephalometric analysis of asymptomatic volunteers and symptomatic patients with and without temporomandibular joint displacement. *Am J Orthod Dentofacial Orthop*. 1998;114:248-255.
  32. Gidarakou IK, Tallents RH, Kyrkanides S, Stein S, Moss ME. Comparison of skeletal and dental morphology in asymptomatic volunteers and symptomatic patients with bilateral disk displacement with reduction. *Angle Orthod*. 2002;72:541-546.
  33. Schellhas KP, Piper MA, Bessette RW, Wilkes CH. Mandibular retrusion, temporomandibular joint derangement and orthognathic surgery planning. *Plastic Recon Surg*. 1992;90:218-232.
  34. Macher DJ, Westesson PL, Brooks SL, Hicks D, Tallents RH. Temporomandibular joint surgically created disk displacement causes arthrosis in the rabbit. *Oral Surg Oral Med Oral Pathol*. 1992;73:645-649.
  35. Qadan S, Macher DJ, Tallents RH, Kyrkanides S, Moss ME. The effect of surgically induced anterior disk displacement of the temporomandibular joint on the midface and cranial base. *Clin Orthod Res*. 1999;2:124-132.
  36. Tallents RH, Macher DJ, Rivoli P, Scapino R, Puzas JE, Katzberg WR. An animal model for meniscus displacement in the rabbit. *J Craniomandib Disord Facial Oral Pain* 1990;4:233-240.
  37. Legrell PE, Reidel J, Nylander K, Horstedt P, Isberg A. Temporomandibular joint condyle changes after surgically induced non-reducing disk displacement in rabbits: a macroscopic and microscopic study. *Acta Odontol Scand*. 1999;57:290-300.
  38. Hatala MP, Tallents RH, Spoon M, Subtelny JD, Kyrkanides S. Effect of surgically created disk displacement on mandibular asymmetry in the growing rabbit. *Oral Surg Oral Med Oral Pathol Oral Radiol Endod*. 1996;82:625-633.
  39. Tallents RH, Guay JA, Katzberg RW, Murphy W, Proskin H. Angular and linear comparisons with unilateral mandibular asymmetry. *J Craniomandib Disord Facial Oral Pain*. 1991;5:135-142.
  40. Legrell PE, Isberg A. Mandibular height asymmetry following experimentally induced temporomandibular joint disk displacement in rabbits. *Oral Surg Oral Med Oral Pathol Endod*. 1998;86:280-285.

41. Roberts CA, Katzberg WR, Tallents RH, Espeland MA, Handelman SL. The clinical predictability of internal derangements of the temporomandibular joint. *Oral Surg Oral Med Oral Pathol.* 1991;71:412-414.
42. Katzberg RW, Westesson PL, Tallents RH, Anderson R, Kurita K, Manzione JV, Totterman S. Temporomandibular joint: magnetic resonance assessment of rotational and sideways disk displacement. *Radiology.* 1988;169:741-748.
43. Westesson PL, Katzberg RW, Tallents RH, Sanchez-Woodworth RE, Svensson SA. Temporomandibular joint: comparison of MR images with creosctional anatomy. *Radiology.* 1987;164:59-64.