

# Maxillary Impacted Canine with Congenitally Absent Premolars

Maryam Saiar, DDS<sup>a</sup>; Joe Rebellato, DDS<sup>b</sup>

**Abstract:** Multiple treatment options are available to patients who have impacted canines in addition to congenitally absent premolars. Management options for impacted maxillary canines can include (1) continued observation, (2) extraction of the primary canine to aid spontaneous eruption, (3) uncovering and bonding of the impacted tooth and its eruption using orthodontic traction, (4) autotransplantation, and (5) extraction followed by prosthetic replacement. The options for the treatment of missing premolars can include the following: (1) maintaining the primary molars, (2) spontaneous space closure after early extraction of the primary molar, (3) autotransplantation, (4) prosthetic replacement, and (5) orthodontic space closure. In this case report, treatment of a patient with an impacted maxillary canine and agenesis of three second premolars will be presented. (*Angle Orthod* 2004;74:568–575.)

**Key Words:** Extraction; Impaction; Canine; Premolar; Anodontia; Adolescent

## INTRODUCTION

The most frequently absent teeth are third molars followed by mandibular second premolars. It has been reported that congenitally missing second premolars comprise between 60% and 72% of the total number of missing teeth excluding the third molars.<sup>1</sup> The incidence of lower second premolar agenesis is 2.5–4% depending on the population investigated.<sup>2,3</sup> According to Bergström,<sup>4</sup> mandibular premolar agenesis occurs bilaterally in 60% of the cases. Roelling reported the incidence of maxillary second premolar agenesis as 2.2%.

The etiology of tooth agenesis is largely unknown. Vastardis<sup>5</sup> presents supporting evidence of a genetic etiology for tooth agenesis. There are reports of associations of tooth agenesis and other congenital tooth anomalies to certain malocclusions.<sup>6</sup> Kjaer et al<sup>7</sup> suggested the division of tooth agenesis into nerve tissue–, oral mucosa–, and supporting tissue–related agenesis. They reported a concomitant occurrence of tooth agenesis and either deviant nerve canal courses or pathological conditions of supporting tissues.

Lindqvist<sup>8</sup> lists solutions to the problem of missing second premolar. One option is to maintain the deciduous teeth

until they are lost by exfoliation, extraction due to caries, root resorption, ankylosis, or infraocclusion. After growth ceases, prosthetic replacement can follow. Autotransplantation and orthodontic space closure are also alternatives. Another option is planned extraction of the deciduous second molars to allow for spontaneous space closure. It may be necessary to use orthodontic appliances to complete the space closure.

The prevalence of impacted maxillary canines is 1–2% in the general population.<sup>9,10</sup> The etiology of impaction is multifactorial. Some of the common causes are genetic predisposition, anomalies in maxillary lateral incisors, and inadequate arch space.<sup>5,11–13</sup> Regardless of the cause of the impaction, early treatment to prevent damage to the maxillary lateral incisor is recommended. Ericson and Kurol<sup>14</sup> showed that the amount of resorption noted using computed tomography scans is greater than that observed with routine radiographic imaging.

Ericson and Kurol<sup>15</sup> recommended early extraction of the primary canine to aid spontaneous eruption of the impacted permanent canine. Many authors have discussed surgical exposure and orthodontic movement at length. Pulpal and periodontal consequences are minimal.<sup>16</sup> In some instances, extraction of the impacted tooth is necessary. This is usually followed by prosthetic replacement.

## HISTORY

A Caucasian girl of 10 years three months old presented for an orthodontic consultation. Her family dentist had referred her for possible early orthodontic intervention. The patient reported no chief complaint. The patient's medical

<sup>a</sup> Resident in orthodontics, Mayo Clinic, Rochester, Minn.

<sup>b</sup> Consultant in Orthodontics and Assistant Professor, Mayo Clinic, Rochester, Minn.

Corresponding author: Joe Rebellato, DDS, Department of Orthodontics, Mayo Clinic, 200 First Street SW, Rochester, MN 55905 (e-mail: rebellato.giuseppe@mayo.edu).

Accepted: August 2003. Submitted: August 2003.

© 2004 by The EH Angle Education and Research Foundation, Inc.

history was noncontributory. No signs or symptoms of temporomandibular joint dysfunction were noted.

### DIAGNOSIS

Initial orthodontic records demonstrated a Class I mixed dentition malocclusion with moderate maxillary and mandibular arch crowding and agenesis of teeth 15, 35, and 45 (Figure 1). Analysis of the study models and intraoral photographs showed an increased overbite and tight overjet. Maxillary incisors were slightly retruded. Dental midlines were coincident. No crossbites were present. No extraoral or intraoral pathology was present. No gross asymmetries were noted. Facial photographs revealed a mesocephalic appearance. The patient had a convex profile. Lip competence at repose was noted. The patient's upper lip was short, and her mentolabial fold was shallow.

After discussing various treatment options with the family, a decision was made to extract teeth 75 and 85 to allow mesial drift of the lower permanent first molars. The extraction of maxillary teeth was postponed so that upper extraction space could be preserved for use at a later date.

An updated panoramic radiograph obtained 26 months later revealed tooth 23 to be impacted. Updated orthodontic records were obtained at that time (Figure 2). After discussing treatment options with the family, the decision was made to place partial orthodontic appliances and uncover and bond the palatally impacted tooth 23. Tooth 25 was not extracted until tooth 23 was erupted with evidence of no damage to the root of tooth 22. Once tooth 23 was successfully erupted into the dental arch (Figure 3), teeth 25, 55, and 65 were extracted, and the patient transitioned to full-appliance therapy.

### ETIOLOGY

The etiology of the second premolar agenesis along with the impaction of the maxillary canine may be in part due to genetic predisposition and crowding. There was no history of trauma or habits. There was no family history of similar developmental abnormalities.

### TREATMENT OBJECTIVES

Extractions of teeth 75 and 85 were done to allow mesial drift of the mandibular first molars. Maxillary extractions were postponed to preserve upper extraction space to help at a later date with the management of interarch relationships during full-appliance therapy.

The goal of the phase-I treatment was to aid the eruption of tooth 23. Once again, tooth 25 was not extracted until tooth 23 was erupted into the dental arch, with no adverse consequences to tooth 22. Should tooth 22 have undergone severe root resorption during the process of erupting the impacted canine, the option for substituting tooth 23 for tooth 22 would still have been available. Only after tooth

23 was successfully erupted were teeth 25, 55, and 65 extracted.

Phase-II treatment was done to close the remaining spaces, finish Class I molars and canines, reduce overbite, and maintain intercanine widths. It was also anticipated that the treatment would maintain acceptable facial balance.

### TREATMENT ALTERNATIVES

Consultations were held with the family and informed consent obtained at each of the three major stages in this patient's care (after initial diagnosis of premolar agenesis, after diagnosis of canine impaction, and before phase II). Options were presented to the family that focused primarily on how to manage the premolar agenesis and canine impaction.

Maintenance of the primary molars was discussed; however, it was the family's wish to avoid prosthetic restorations in the future, if possible; thus, the decision to extract teeth 75 and 85 was made.

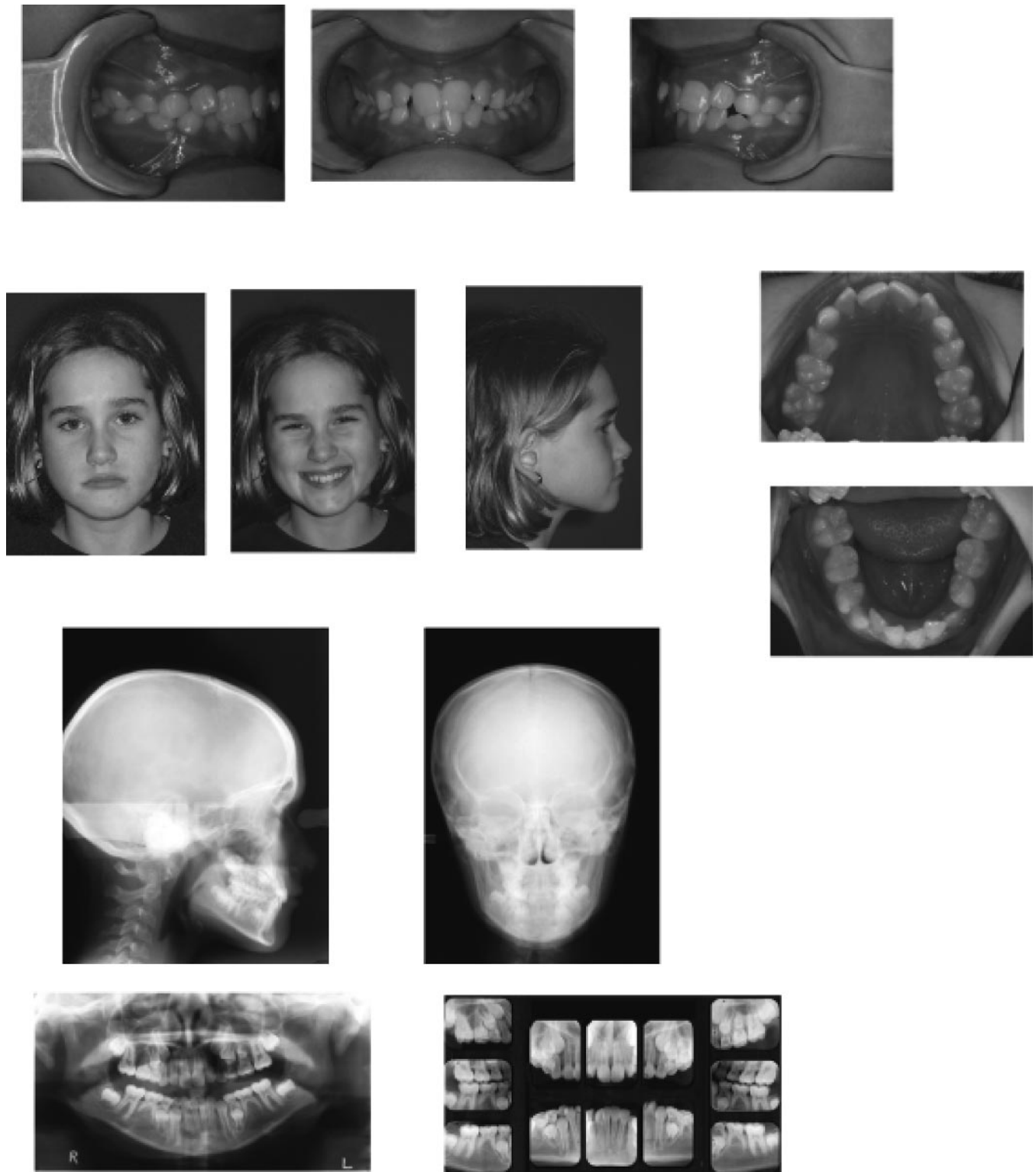
After diagnosis of the impacted canine, options were again presented to the family, which included extraction of the primary canine followed by monitoring. However, it was mutually agreed to proceed with phase I of treatment to surgically uncover and erupt tooth 23 into arch position.

At the end of phase I and before phase II, progress records were obtained, and options were again discussed with the family. The option of extracting teeth 55 and 65 but keeping tooth 25 and finishing with a Class III molar relationship on the left side and Class I on the right side was presented. However, tooth 25 appeared to be significantly delayed in its development (no root formation was yet present) and possibly malpositioned. In addition, the absence of development of lower third molars might leave tooth 27 unopposed and at risk for supraeruption in the future with a Class III molar finish on the left side. The decision to extract teeth 55, 65, and 25 was mutually agreed upon, and the patient transitioned to full orthodontic appliances.

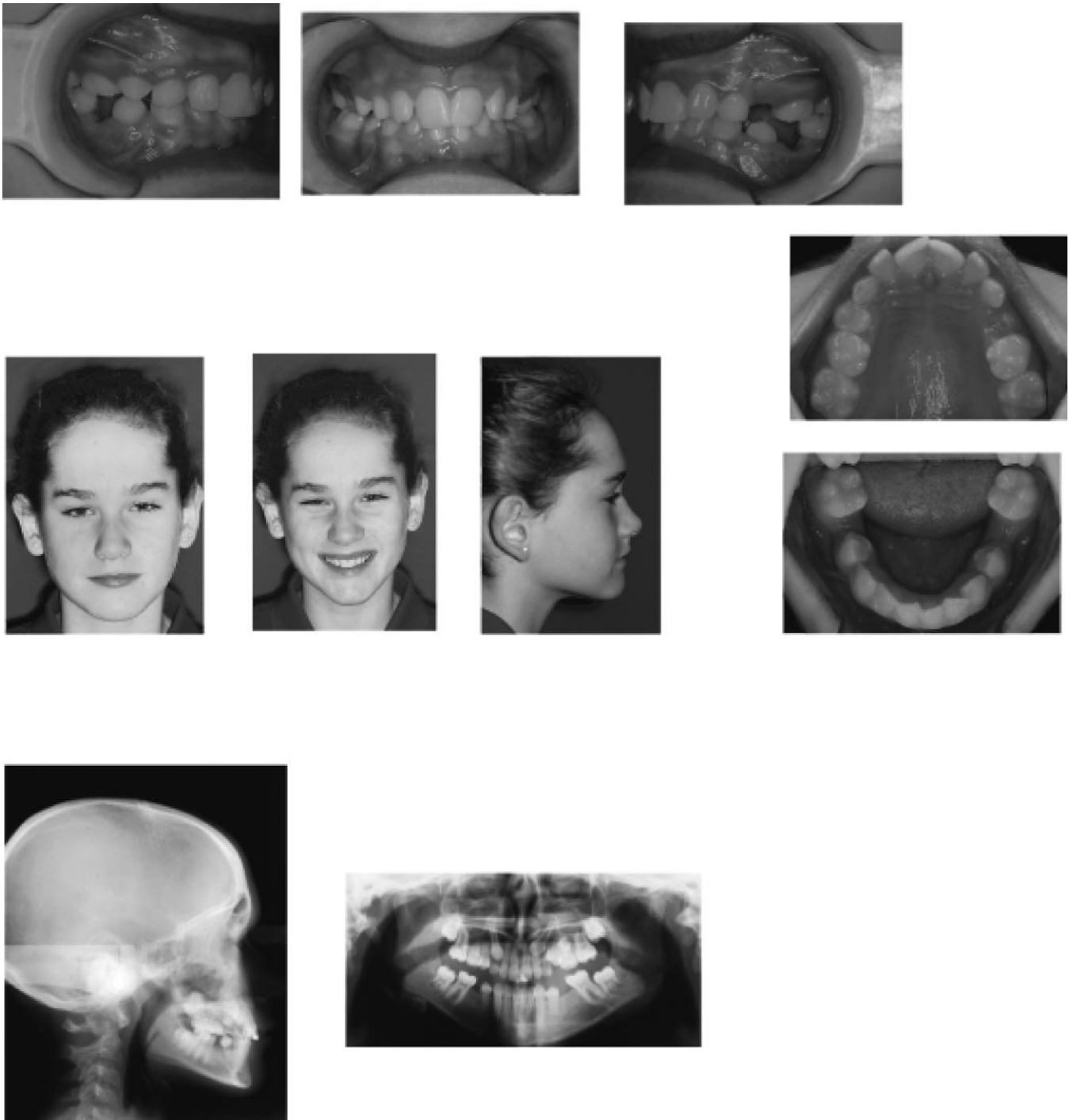
### TREATMENT PROGRESS

One year after teeth 75 and 85 were extracted, mesial drift of the mandibular first molars and partial spontaneous space closure were noted. However, a panoramic radiograph obtained two years after the initial extractions showed tooth 23 to be impacted. Records were updated at the age of 12 years four months (Figure 2). Treatment objectives and alternatives were presented, and informed consent was obtained.

Maxillary 2 × 4 preadjusted appliances along with a transpalatal arch were placed. Tooth 23 underwent a surgical uncovering procedure followed by bonding of an attachment. A 0.016 inch NiTi archwire was placed. The archwire was then changed to a 0.016 × 0.022 inch stainless steel. A 0.017 × 0.025 inch TMA wire segment was fab-



**FIGURE 1.** Pretreatment panoramic radiograph, lateral cephalometric radiograph, posterior-anterior cephalometric radiograph, full mouth series, pretreatment facial photographs, and intraoral photographs.



**FIGURE 2.** Initial progress panoramic radiograph, lateral cephalometric radiograph, facial photographs, and intraoral photographs.

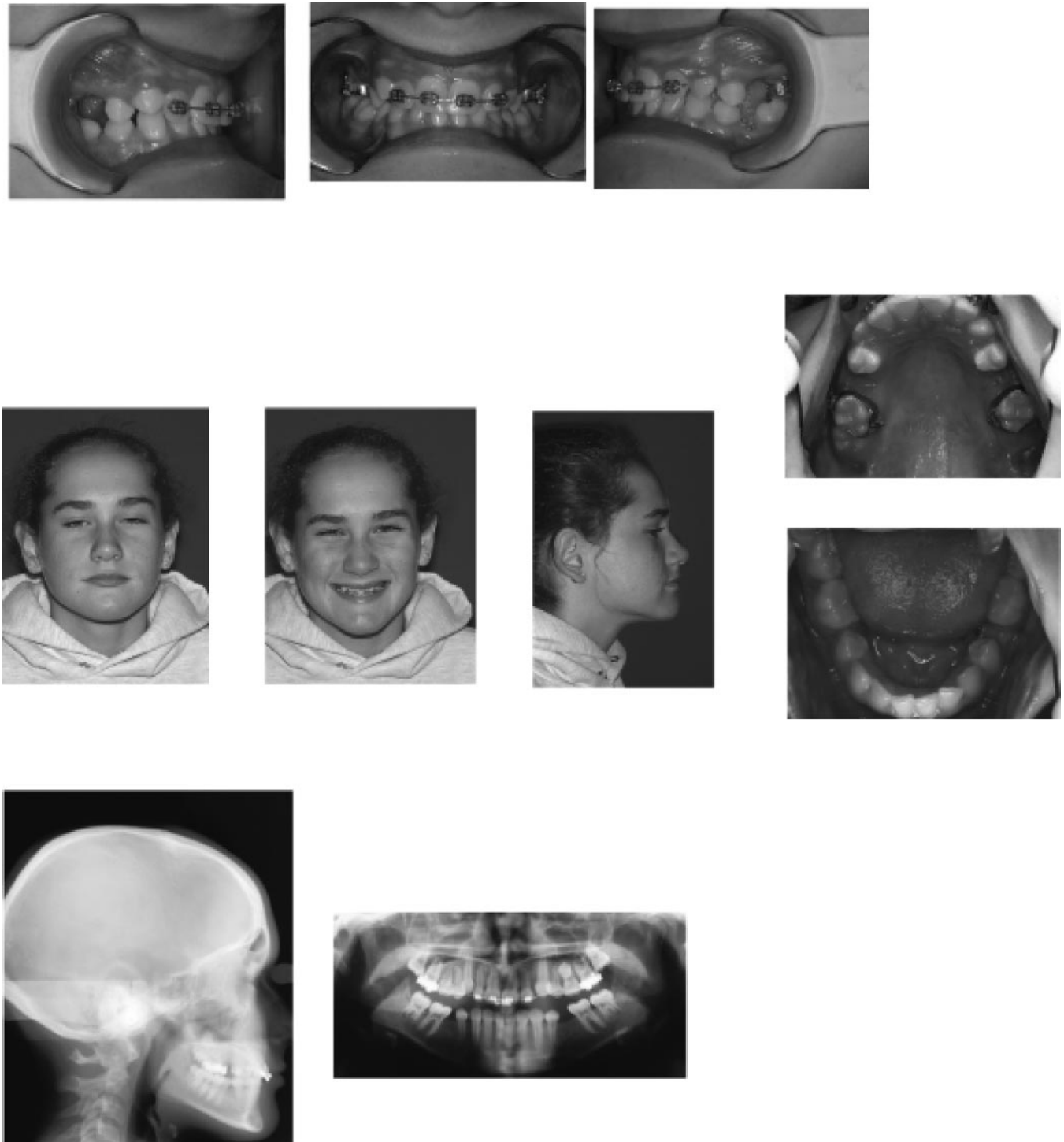
ricated into a cantilever spring to erupt tooth 23 occlusally and buccally. Once tooth 23 had erupted sufficiently, the patient was referred to have teeth 55, 65, and 25 extracted. Updated orthodontic records were obtained (Figure 3), and the rest of the dentition was bonded with appliances to proceed with space closure.

After final detailing, the appliances were removed followed by insertion of an upper Hawley retainer and bond-

ing of a 0.030-inch Blue Elgiloy wire retainer from mandibular canine to canine. Posttreatment records were obtained (Figure 4). Figure 5 shows superimposition of initial, initial progress, progress, and final cephalometric tracings.

**TREATMENT RESULTS**

Cephalometric superimposition revealed a downward and forward growth pattern. The maxillary and mandibular in-

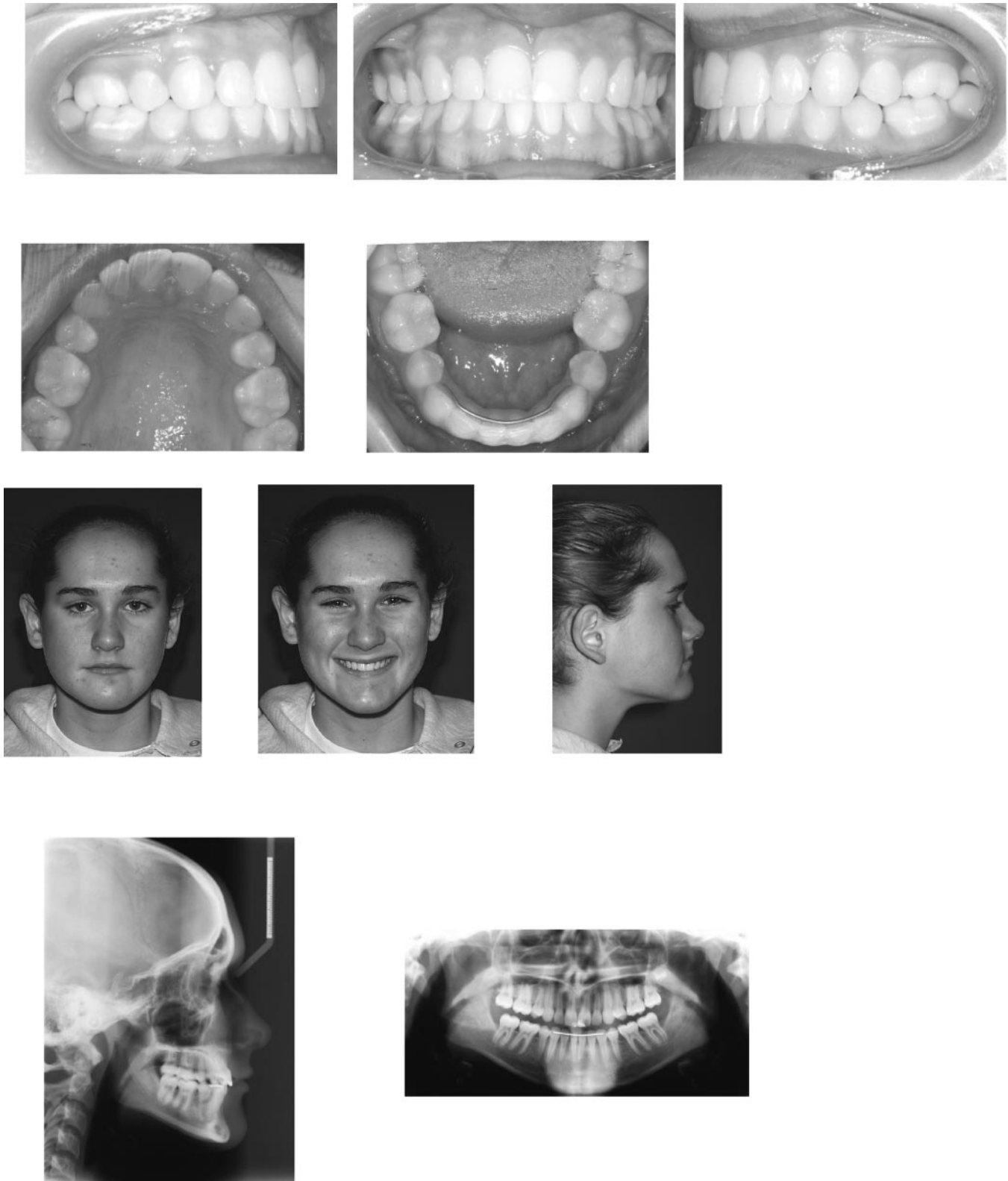


**FIGURE 3.** Progress panoramic radiograph, lateral cephalometric radiograph, facial photographs, and intraoral photographs.

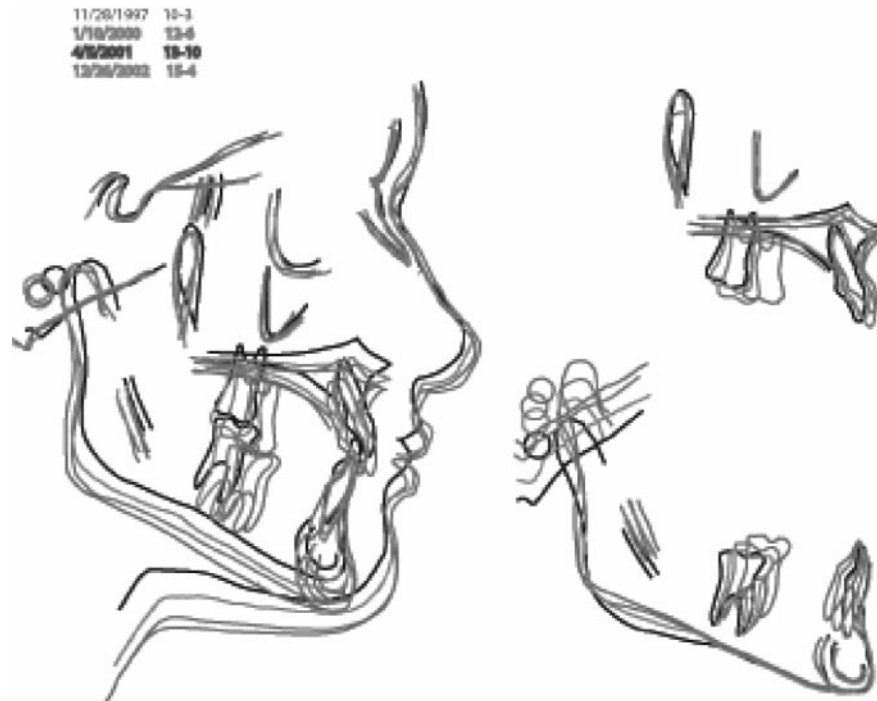
cisors were torqued, resulting in a decreased interincisal angle. The maxillary and mandibular molars underwent significant mesial drift, with minimal incisor retraction. Facial balance was maintained despite extractions, nasal growth, and increased pogonion projection due to the forward rotating growth pattern.<sup>17</sup>

Examination of the patient's final study models shows

bilateral Class I molar relationship. Ideal overbite and overjet were achieved. Slight space distal to the left mandibular first premolar opened one month after appliance removal. In retrospect, a different retainer design may have prevented the space from reopening. At a recent follow-up visit, it was noted that the space distal to the left mandibular premolar has decreased. We anticipate that the space will even-



**FIGURE 4.** Posttreatment facial photographs, intraoral photographs, panoramic radiograph, and lateral cephalometric radiograph.



**FIGURE 5.** Superimposed cephalometric tracings—initial: 10 years three months; initial progress: 12 years four months; progress: 13 years seven months; and final: 15 years four months.

tually close. The mandibular midline was deviated to the left of the maxillary midline by less than 1 mm. Inter canine and intermolar widths were maintained.

Review of the panoramic radiograph revealed that teeth 34 and 44 could have benefited from additional distal root tipping. The patient will be monitored for the eruption and possible future extraction of tooth 28.

## DISCUSSION

The problem of congenitally missing teeth is addressed differently depending on the patient's age, condition of the primary molars, and position of the teeth adjacent to the absent permanent tooth. Extraction of primary second molars in children aged 5–12 years with congenitally missing second premolars was investigated by Lindqvist.<sup>8</sup> He noted that spontaneous space closure occurred if extraction took place before completion of the mandibular first premolar root development and eruption of the second permanent molar. The diagnosis of second premolar agenesis cannot be made reliably before the patient is nine years old.<sup>2</sup> In this case report, the extraction of the mandibular primary second molars took place when the patient was 10 years old. There was partial spontaneous space closure by extractions performed at this age.

The option of maintaining primary second molars is a viable one. The patient needs to be informed that because of the shape and size of the retained primary molars, interdigtation will not be ideal. A study of long-term survival of primary second molars revealed that root resorption re-

duced with age.<sup>18</sup> This study also showed an association between infraocclusion of primary molars and tipping of the adjacent teeth. Infraocclusion, tipping of the adjacent teeth, or root resorption did not increase after the age of 20 years.

Surgical autotransplantation of third molars in the absent premolar sites has been described in the literature. Andreasen et al,<sup>19</sup> in their study of tooth survival subsequent to autotransplantation, showed a survival rate of 95–98%. The survival rate of autotransplanted teeth related closely to the stage of root development at the time of surgery. Teeth with incomplete root formation showed 96% pulp healing, whereas teeth with complete root formation only had 15% pulp healing. This patient's third molar agenesis precluded this option.

Replacing the congenitally absent premolars with implants or fixed partial dentures is another option. This may be a good option for patients with a low mandibular plane angle and no crowding or even spacing. In these cases, space closure is often contraindicated. The spaces need to be maintained, and implant placement needs to be performed after skeletal growth is complete. Once again, treatment direction was influenced by the family's desire to avoid prosthetic restorations.

Upon diagnosing the patient with an impacted maxillary canine, a decision was made to intervene with surgical uncovering and forced eruption rather than extracting the primary canine and monitoring for spontaneous eruption of the permanent canine. Ericson and Kuroi<sup>15</sup> reported that the

degree of the medial position of the maxillary canine relative to the adjacent lateral incisor plays a role in the severity of the impaction. The medial crown positions were divided into five sectors (1 = least amount of overlapping, and 5 = most amount of overlapping). Ten of the 46 canines in sectors 2, 3, 4, and 5 did not improve their position after extraction of primary canines. Examination of the January 2000 panoramic radiograph reveals tooth 23 to be in sector 4. Position of tooth 23 may have been corrected if we had extracted tooth 63. However, it was decided to proceed with treatment because the decision to extract tooth 25 depended on the successful eruption of tooth 23.

### CONCLUSIONS

Early diagnosis of tooth agenesis and canine impaction allows the orthodontist to present multiple treatment options to the patient and family. As observed in this case, space closure in select patients with congenitally absent teeth, with good patient cooperation, can lead to a good orthodontic result.

### REFERENCES

1. Svedmyr B. Genealogy and consequences of congenitally missing second premolars. *J Int Assoc Dent Child*. 1983;14:77–82.
2. Rolling S. Hypodontia of permanent teeth in Danish school children. *Scand J Dent Res*. 1980;88:365–369.
3. Grahnen H. Hypodontia in the permanent dentition. A clinical and genetical investigation. *Odontol Revy*. 1956; 7.
4. Bergström K. An orthopantomographic study of hypodontia, supernumeraries and other anomalies in school children between ages of 8–9 years. *Swed Dent J*. 1977;1:145–157.
5. Vastardis H. The genetics of human tooth agenesis; new discoveries for understanding dental anomalies. *Am J Orthod Dentofacial Orthop*. 2000;117:650–656.
6. Basdra EK, Kiokpasoglou MN, Komposch G. Congenital tooth anomalies and malocclusions: a genetic link? *Eur J Orthod*. 2001; 23:145–151.
7. Kjaer I, Kocsis G, Nodal M, Christensen L. Aetiological aspects of mandibular tooth agenesis—focusing on the role of nerve, oral mucosa, and supporting tissues. *Eur J Orthod*. 1994;16:371–375.
8. Lindqvist B. Extraction of deciduous second molar in hypodontia. *Eur J Orthod*. 1980;2:173–181.
9. Bass T. Observations on the misplaced upper canine tooth. *Dent Pract Dent Rec*. 1967;18:25–33.
10. Rayne J. The unerupted maxillary canine. *Dent Pract Dent Rec*. 1969;19:194–204.
11. Peck S, Peck L, Kataja M. The palatally displaced canine as a dental anomaly of genetic origin. *Angle Orthod*. 1994;64:249–256.
12. Becker A, Smith P, Behr R. The incidence of anomalous maxillary lateral incisors in relation to palatally-displaced cuspids. *Angle Orthod*. 1981;51:24–29.
13. Jacobs SG. The impacted maxillary canine. Further observations on aetiology, radiographic localization, prevention/interception of impaction, and when to suspect impaction. *Aust Dent J*. 1996;41: 310–316.
14. Ericson S, Kurol J. Resorption of incisors after ectopic eruption of maxillary canines: a CT study. *Angle Orthod*. 2000;70:415–423.
15. Ericson S, Kurol J. Early treatment of palatally erupting maxillary canines by extraction of the primary canines. *Eur J Orthod*. 1988; 10:283–295.
16. Woloshyn H, Artun J, Kennedy DB, Joondeph D. Pulpal and periodontal reactions to orthodontic alignment of palatally impacted canines. *Angle Orthod*. 1994;64:257–264.
17. Skieller V, Bjork A, Linde-Hansen T. Prediction of mandibular growth rotation evaluated from a longitudinal implant sample. *Am J Orthod*. 1984;86:359–370.
18. Bjerklin K, Bennett J. The long-term survival of lower second primary molars in subjects with agenesis of the premolars. *Eur J Orthod*. 2000;3:245–255.
19. Andreasen JO, Paulsen HU, Yu Z, Bayer T, Schwartz O. A long-term study of 370 autotransplanted premolars. Part II. Tooth survival and pulp healing subsequent to transplantation. *Eur J Orthod*. 1990;12:14–24.