

A Radiographic Evaluation of the Availability of Bone for Placement of Miniscrews

Marissa A. Schnelle, BA^a; Frank Michael Beck, DDS, MA^b; Robert M. Jaynes, DDS^c; Sarandeep S. Huja, DDS, PhD^d

Abstract: Monocortical screws are increasingly being used to enhance orthodontic anchorage. The most frequently cited clinical complication is soft tissue irritation. It is thus clinically advantageous for these miniscrews to be placed in attached mucosa. The purpose of this study was to (1) determine radiographically the most coronal interradicular sites for placement of miniscrews in orthodontic patients and (2) determine if orthodontic alignment increases the number of sites with adequate interradicular bone for placement of these screws. Sixty panoramic radiographs (n = 30 pretreatment, n = 30 posttreatment) of orthodontic patients were obtained from an archival database after Institutional Review Board approval. Selection criteria included minimal radiographic distortion and complete eruption of permanent second molars. Interradicular sites were examined with a digital caliper for presence of three and four mm of bone. If three or four mm of bone existed, then a vertical measurement from the cemento-enamel junction (CEJ) to first measurement was made. In addition, the magnification error inherent in panoramic radiographs was estimated. Ninety-five percent confidence intervals were calculated for the vertical distances from the CEJ to the horizontal bone location. Bone stock for placement of screws was found to exist primarily in the maxillary (mesial to first molars) and mandibular (mesial and distal to first molars) posterior regions. Typically, adequate bone was located more than halfway down the root length, which is likely to be covered by movable mucosa. Inability to place miniscrews in attached gingiva may necessitate design modifications to decrease soft tissue irritation. (*Angle Orthod* 2004;74:832–837.)

Key Words: Miniscrew; Anchorage; Bone; Panoramic radiograph; Orthodontics

INTRODUCTION

Anchorage control is critical in orthodontics. Multiple strategies have been developed to enhance anchorage.¹ However, these strategies may not be an option in adult patients with mutilated dentitions and in patients with craniofacial malformations. Also, other limitations of current methods of anchorage include the need for compliance and systems that cause unwanted reactions, such as extrusion of teeth. Endosseous implants placed for restorative needs can also be used for orthodontic anchorage. However, the

disadvantages of endosseous implants are high costs and typically the need for an edentulous space before placement.

Recently mini-implants, which are small screws typically used for craniofacial surgery applications, have been used to enhance anchorage.^{2–4} Advantages of this system include ease of insertion and removal of the screws, immediate/early loading, low cost, and adequate anchorage support for orthodontic tooth movement. Clinical reports demonstrate the viability of using miniscrews for skeletal anchorage to support a variety of orthodontic tooth movements.^{3,5–7} Because of the small screw size, ranging from 1.5–2 mm in diameter and 4–10 mm in length, these screws can potentially be placed in interradicular locations. In addition, a canine study suggests that these screws only partially osseointegrate, resulting in stability during treatment but still allowing for easy removal after completion of treatment.⁸

Potential complications with miniscrews in orthodontics are soft tissue irritation at the site of insertion, risk of infection, and premature loosening of the screw.⁴ To limit tissue irritation, a mucoperiosteal flap can be raised before screw insertion. After healing, the gingival tissue can be removed by a mucosal punch, and access through the head

^a College of Dentistry, The Ohio State University, Columbus, Ohio.

^b Associate Professor, Oral Biology, The Ohio State University, Columbus, Ohio.

^c Assistant Professor, Radiology Group, Section of Primary Care, The Ohio State University, Columbus, Ohio.

^d Assistant Professor, Section of Orthodontics, The Ohio State University, Columbus, Ohio.

Corresponding author: Sarandeep S. Huja, DDS, PhD, Section of Orthodontics, The Ohio State University, 4088E Postle Hall, 305 W. 12th Avenue, Columbus, OH 43210 (e-mail: huja.1@osu.edu).

Accepted: December 2003. Submitted: July 2003.

© 2004 by The EH Angle Education and Research Foundation, Inc.

of the screw is obtained.^{3,5,9} Also, a ligature wire can be tied to the screw head and then emerge from the soft tissue. However, depending on the mobility of the mucosa, soft tissue irritation may still occur. If screws are placed in attached mucosa, it is less likely that irritation will be a complication. It is unknown if sufficient interradicular divergence to place a miniscrew exists at the level of the buccal mucogingival junction.

Miniscrews placed in interradicular locations should not impinge on adjacent root structures. Strategies to prevent root damage include placement of the miniscrews from the lingual⁷ or at an angle and directed toward the apex.^{6,7} Published studies describe the site of insertion as midroot or at/beyond the root apex.^{3,5,10} Although this would possibly avoid root damage, it is likely miniscrew insertion site was beyond the mucogingival junction in these case reports. The purpose of this study was to (1) determine radiographically the most coronal interradicular sites for placement of screws in orthodontic patients and (2) determine if orthodontic alignment increases the number of sites with adequate interradicular bone for placement of these screws.

MATERIALS AND METHODS

After Institutional Review Board approval, both the pretreatment and posttreatment panoramic radiographs of 30 orthodontic patients were obtained from the archival database in the Section of Orthodontics. Selection criteria included minimal radiographic distortion or manifestation of positioning errors. Complete eruption of all second permanent molars was determined from the pretreatment orthodontic study models. A total of 14 interradicular sites were examined on each panoramic film (Figure 1a). The premolar region in the panoramic radiographs was not chosen because of radiographic distortion typical to this region. The diameter of screws used in clinical practice varies from 1.2 to two mm.^{4,8} Also, it is important not to damage the root structure and to have the screws surrounded by approximately one mm of bone between the screw and the periodontal ligament/root structures. Thus we chose to evaluate a range of bone availability at interradicular locations on the panoramic radiographs. We considered 3–4 mm as the minimum amount of bone required to place a screw in interradicular bone. We refer to the amount of bone available for placement of the screw as bone stock, a term typically used in the orthopedic literature to denote the quantity of bone available at the site of insertion of an implant.

At each selected interradicular location, the existence of three and four mm of bone stock was measured with a digital caliper (Model SC-6, Mitutoyo, Japan). Starting at the cementoenamel junction (CEJ), the caliper was moved apically on the radiograph until three or four mm of bone stock existed. This measurement was made horizontally and extended from the lamina dura of adjacent tooth roots at the most coronal location possible. If three or four mm of

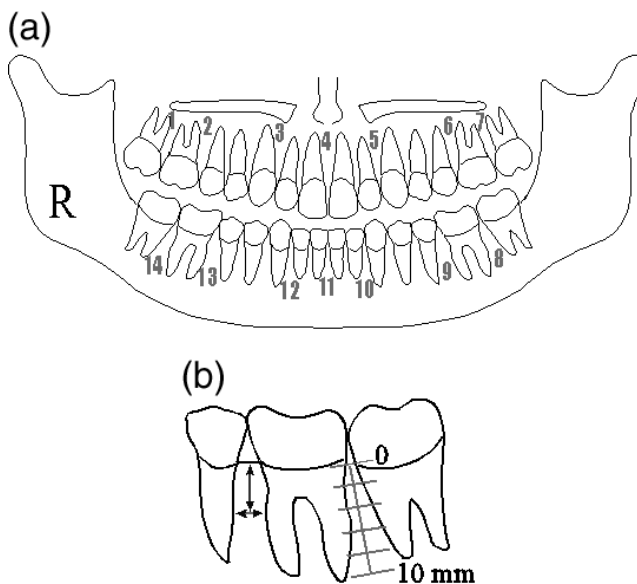


FIGURE 1. (a) Schematic of the panoramic radiograph and 14 locations at which measurements were made for three and four mm of bone stock. Premolar locations are not included because distortion exists in this region. (b) Schematic of horizontal and vertical measurements. The horizontal measurement was established at sites of three or four mm of bone at each of the 14 locations. The vertical measurement indicated the distance of the horizontal measurement from the cementoenamel junction (CEJ). Between the first and second molar is a 10-mm grid that is aligned to originate at the CEJ.

interradicular horizontal bone existed, then a second, perpendicular vertical measurement was made from the line connecting the CEJ of the teeth that bound the interdental space to the horizontal location (Figure 1b). For each of the three and four mm locations, 95% confidence intervals were calculated for the vertical distances found from the CEJ to the horizontal bone location. Based on the literature, we discussed the likelihood of the screw site being located on attached mucosa.

Measurement of intrarater agreement (error) for nominal and continuous measures

Before data collection, five panoramic radiographs were chosen to examine intrarater agreement for nominal (presence or absence of adequate bone) and continuous measures. First, on each of these films the existence of three or four mm of bone stock was determined at one anterior and one posterior site (between the maxillary centrals and mesial to the lower left first molar). If three or four mm of interdental bone measured mesiodistally existed, then the vertical distance from this horizontal line to the CEJ was measured (Figure 1b). Two weeks later the measurements were repeated. Intrarater agreement was assessed by the simple κ statistic (presence or absence of adequate bone). In addition, intraclass correlation coefficient was used to assess intrarater agreement in measuring the vertical dis-

tance ie, the point at which three or four mm of bone stock was established to the line connecting the CEJ of the interradicular space.

Measurement of magnification and distortion in panoramic radiographs

We desired to determine the magnification and distortion in the pretreatment and posttreatment radiographs. Because of the retrospective nature of this study, it was not possible to know the head position at the time the radiographs were taken. Changes in head position manifest as distortion and magnification in panoramic radiographs. We evaluated the magnification produced by our panoramic machine (Siemens, OP-10, Munich, Germany) on a dry skull and also compared the degree of horizontal magnification in the pretreatment and posttreatment radiographs.

Measurement of magnification on dry skull. A wire grid (~5 × 1 cm) embedded in a Plexiglas plate was secured to a dry skull in four locations. The grid consisted of three rows of 15 squares/row (2.5-mm sides). A panoramic radiograph was exposed with the grid positioned at the following locations on the dry skull: anterior maxilla, anterior mandible, posterior maxilla, and posterior mandible. To estimate the magnification, five vertical and five horizontal measurements were made on multiple squares in the center of the grid in each of the four films. The measurements obtained were compared with the actual size of the grid.

Comparison of magnifications in the pretreatment and posttreatment panoramic radiographs. Distortion and magnification are manifestations of head positioning errors on the panoramic radiograph. This served as the rationale for comparing magnifications on the two sets of panoramic radiographs. We considered this essential because we had no knowledge of head position in this retrospective study. However, we anticipated that standard techniques for obtaining radiographs were followed. Pretreatment and posttreatment models of five of 30 patients were selected. The mesiodistal width of five maxillary and five mandibular teeth were made on the dental casts with a digital caliper. The teeth measured were the maxillary and mandibular first molars and canines, maxillary right central incisor, and the mandibular left central incisor. Corresponding measurements were then made on the respective panoramic radiographs. Magnification on the panoramic radiograph was then calculated on the basis of the study model dimension. The differences in magnification between the pretreatment and posttreatment radiographs for each of the 10 teeth in the five paired radiographs were calculated. Dependent *t*-tests were used to evaluate for statistical differences in magnification of the pretreatment and posttreatment panoramic radiographs.

RESULTS

The results are presented in Table 1 and Figures 2 and 3. Table 1 lists the percent of instances with three or four

TABLE 1. Percent of Instances Among the 30 Radiographs That Three or Four mm of Bone Stock Was Available in Pretreatment and Posttreatment Panoramic Radiographs^a

Location	Three mm (%)	Confidence Interval (mm)	Four mm (%)	Confidence Interval (mm)
Pretreatment				
1	40.0	5.1/7.8	13.3	5.3/6.6
2	96.7	7.3/10.0	76.7	7.0/9.6
3	85.2	6.4/9.0	77.8	9.3/12.8
4	96.7	4.4/10.5	79.3	9.7/11.8
5	93.3	7.6/9.5	76.7	10.3/12.1
6	93.1	4.7/7.4	75.9	7.6/10.7
7	56.7	4.9/9.0	23.3	4.6/12.2
8	96.6	2.5/4.0	96.6	4.7/7.2
9	100	4.1/6.5	100	6.9/9.7
10	100	7.6/10.2	70.0	10.0/12.9
11	40.0	6.3/10.2	16.7	4.6/11.3
12	82.7	6.3/8.5	69.0	8.4/11.8
13	100	4.3/7.0	100	7.0/10.2
14	96.7	2.7/5.3	90.0	5.0/8.3
Posttreatment				
1	63.3	3.9/7.2	33.3	4.8/9.7
2	100	4.5/5.7	96.7	6.6/8.7
3	96.7	6.1/8.1	96.7	8.8/11.0
4	96.7	7.2/9.8	96.7	10.3/13.0
5	89.7	6.4/9.6	79.3	8.7/11.3
6	96.7	4.7/6.6	100	7.1/9.3
7	66.7	3.8/7.3	43.3	5.7/10.1
8	96.7	2.5/4.5	93.3	4.9/8.1
9	100	4.6/7.5	93.3	7.0/9.9
10	96.7	5.1/7.2	93.3	7.7/10.3
11	50.0	8.1/10.3	16.7	8.3/12.8
12	96.7	5.2/7.2	86.7	7.2/9.4
13	100	4.8/7.5	96.7	7.3/10.3
14	93.3	2.3/4.7	83.3	5.3/8.6

^a The 95% confidence intervals indicate the most coronal site (distance from the cemento-enamel junction) at which a screw could be placed.

mm of bone stock in each of 14 locations for the two sets of radiographs. In addition, the vertical distance from the CEJ is also reported in terms of a 95% confidence interval to represent the most coronal site at which three or four mm of bone stock was available. This 95% confidence interval is listed in Table 1 and represented by the shaded boxes in Figures 2 and 3.

Figures 2 and 3 indicate conservatively those locations of the 14 examined that consistently ($\geq 90\%$) had three or four mm of bone stock. For example, in the pretreatment radiograph, for the interradicular space between the mandibular left first and second molar (Figure 2a), the most coronal location for a three mm bone stock was at 2.5–4.0 mm (shaded area) from the level of the CEJ. Similarly, in the interradicular space between maxillary central incisors, three mm of bone stock was at 4.4–10.5 mm from the level of the CEJ.

In the pretreatment radiographs, nine of 14 interradicular locations consistently had three mm of bone stock. The

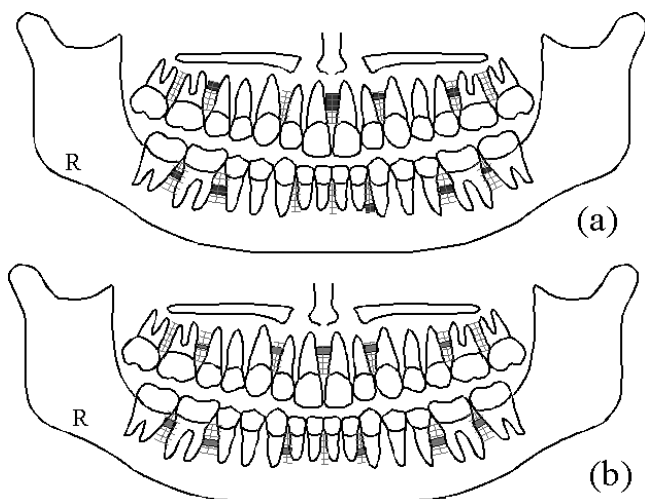


FIGURE 2. Schematic of panoramic film indicating location and sites at which three mm of bone stock was consistently ($\geq 90\%$ of the instances) available. (a) Pretreatment radiograph. Nine of 14 locations have three mm of bone available. (b) Posttreatment radiograph. Eleven of 14 locations have three mm of bone available.

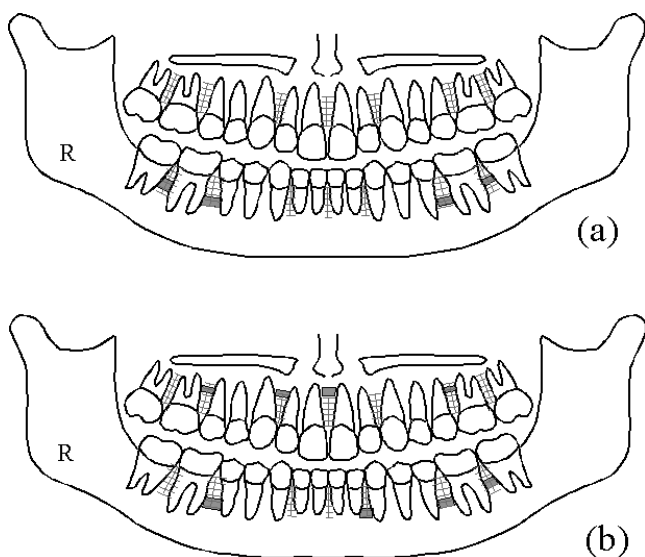


FIGURE 3. Schematic of panoramic film indicating location and sites ($\geq 90\%$ of the instances) for four mm of bone available. (a) Pretreatment radiograph. Four of 14 locations have four mm of bone available. (b) Posttreatment radiograph. Eight of 14 locations have four mm of bone available.

most coronal of these nine locations was between the mandibular first and second molars bilaterally and was at ~ 2.6 mm from the CEJ. The most coronal site for placement of a screw mesial to the first molar was at ~ 4.2 mm from the level of the CEJ. In all other instances, the bone stock was at greater than 4.5 mm from the CEJ. When locating four mm of bone stock, only four pretreatment interradicular locations were available, and all these mandibular locations were at sites greater than 4.5 mm from the CEJ.

In comparing the posttreatment radiographs with the pretreatment radiographs, the number of available interradicular locations increased from nine to 11 for the three mm group and from four to eight for the four mm group (Figures 2 and 3). It is likely that correcting axial inclinations of teeth would enable more interradicular locations to become available. However, there were minimal changes in the 95% confidence intervals between the pretreatment and posttreatment radiograph (Table 1).

The intrarater reliability was excellent, with simple κ being 1 and intraclass correlation coefficient being .967. Measurements made using the grid on a dry skull suggest that magnification was greater in the mandible than in the maxilla. Also, we found that the horizontal magnification was of the order of 2–6% in all regions except the posterior mandible where it was 22%. The differences in magnification between the pretreatment and posttreatment radiographs showed no statistically significant difference ($P > .05$) for each of the 10 teeth examined. The largest magnification difference between the pretreatment and posttreatment radiographs was 10.7% ($P = .2401$) for the maxillary right canine. The smallest magnification difference was 1.1% for the mandibular right molar ($P = .8535$).

As this is a retrospective radiographic study, the location of the mucogingival junction was not known for the patients whose radiographs were examined. We reviewed the literature^{11,12} to obtain normative values of the width of attached gingiva. The clinical implications of placing screws into attached gingiva or into the movable mucosa are further highlighted in the discussion.

DISCUSSION

One limitation of this study was the use of panoramic radiographs. This film can be used before orthodontic treatment to evaluate root alignment, evidence of root resorption, and possible pathology. However, vertical and horizontal magnifications are inherent in panoramic radiography. Vertical magnification in panoramic radiographs has been reported to be approximately 18–21%, whereas horizontal magnification is more unreliable.¹³ In addition, distortion is greater in certain regions (eg, midline and canine/premolar region). It would have been preferable to use periapical radiographs for a prospective study, but full-mouth radiographs are not routinely requested for our orthodontic patients. In addition, periapical radiographs also have inherent magnification estimated to be 5%.¹⁴

In studying the errors of our methods, we found that the intrarater reliability was excellent and, therefore, would not significantly affect our measurements. Our panoramic machine magnification was consistent with the findings of the Larheim and Svanaes study.¹³ When comparing the difference between the percent magnification measured in the pretreatment radiographs with the posttreatment radiographs, no significant ($P > .05$) differences were noted (av-

erage statistical power was 90% to detect a difference of $\pm 20\%$). Therefore, it is likely that the positioning error was negligible and comparisons could be made between the pretreatment and posttreatment radiographs used in this study.

In addition to magnification, another problem inherent to panoramic films is error in root angulation. Mckee et al¹⁵ examined mesiodistal tooth angulations using four different machines and found that the largest distortion of angulations in the maxillary teeth was an exaggerated root divergence between the canine and first premolar. The area distal to the canine was not included in our study. The largest difference in the mandible was an exaggerated convergence between the canine and lateral incisor.¹⁵ This suggests, for example, that we may have underestimated the bone stock mesial to the mandibular canine.

Three millimeters of bone stock existed primarily in the posterior regions mesial to the maxillary first molar and mesial and distal to the mandibular first molar. Similarly, four mm of bone stock existed primarily mesial and distal to the mandibular first molar.

The results of this study do not support the anecdotal claims that these screws can be placed predictably at bone sites covered with attached gingiva. At most locations, even after correcting for magnification errors, adequate bone for placement was located more than halfway down the root length, which typically would be covered by movable mucosa.¹¹ One possible exception was the distal of the mandibular first molars for three mm of bone stock. In this situation, placement at ~ 2.5 mm from the CEJ could possibly fall into the attached mucosa for healthy patients. Inability to place miniscrews in attached gingiva may necessitate design modifications to decrease soft tissue irritation and damage to root structure. For example, it may be advantageous to raise a mucoperiosteal flap, insert the screw, and have a rigid attachment that exits the mucosa and terminates in a more occlusal location.⁹ This is strategy similar to that used in retromolar implants¹⁶ where the transmucosal wire exits the tissue and limited or no irritation is clinically seen.

When comparing the posttreatment radiographs with the information from the pretreatment radiographs, we noted that there was a consistent increase in the number of available locations having the three or four mm of space. This may indicate that after orthodontic treatment and initial root alignment there may be an increase in sites available for miniscrew placement. If the practitioner knows that miniscrew anchorage will be needed, a periapical radiograph to examine the site for placement would reveal the amount of bone stock. The literature^{6,10} suggests that for anterior-posterior movements (eg, retraction of canines/incisors), the region mesial or distal to the molar is frequently a site for miniscrew placement. This is consistent with the findings of our study. It is also possible to separate the roots of teeth intentionally during the initial stages of orthodontic treatment to allow for placement of a miniscrew in an ideal

location. However, this will need to be balanced with an increase in treatment time.

CONCLUSIONS

The principal finding of this study is that the clinician should be aware that it may not be possible to place miniscrews in attached gingiva because of a lack of interradiolar bone at these sites. This may necessitate design modification in the screw head or placement techniques to decrease soft tissue irritation. We are able to suggest potential sites that orthodontic practitioners can further examine by periapical radiographs if skeletal anchorage is required.

ACKNOWLEDGMENTS

This investigation was partially supported by the National Institutes of Health, National Research Service Award T32 DE14320 from the National Institute of Dental and Craniofacial Research (MAS). The authors are grateful for access to the orthodontic archival database at The Ohio State University, College of Dentistry.

REFERENCES

1. Melsen B, Verna C. A rational approach to orthodontic anchorage. *Prog Orthod.* 1999;1:10–22.
2. Park YC, Lee SY, Kim DH, Jee SH. Intrusion of posterior teeth using mini-screw implants. *Am J Orthod Dentofacial Orthop.* 2003;123:690–694.
3. Kanomi R. Mini-implant for orthodontic anchorage. *J Clin Orthod.* 1997;31:763–767.
4. Costa A, Raffaini M, Melsen B. Miniscrews as orthodontic anchorage: a preliminary report. *Int J Adult Orthodon Orthognath Surg.* 1998;13:201–209.
5. Kanomi R, Takada K. Application of titanium mini-implant system for orthodontic anchorage. In: Davidovitch Z, Mah J, eds. *Biological Mechanisms of Tooth Movement and Craniofacial Adaptation.* 2000:253–258. Boston, Mass: Harvard Society for the Advancement of Orthodontics.
6. Park HS, Bae SM, Kyung HM, Sung JH. Micro-implant anchorage for treatment of skeletal class I bialveolar protrusion. *J Clin Orthod.* 2001;35:417–422.
7. Lee JS, Park HS, Kyung HM. Micro-implant anchorage for lingual treatment of a skeletal class II malocclusion. *J Clin Orthod.* 2001;35:643–647.
8. Ohmae M, Saito S, Morohashi T, et al. A clinical and histological evaluation of titanium mini-implants as anchors for orthodontic intrusion in the beagle dog. *Am J Orthod Dentofacial Orthop.* 2001;119:489–497.
9. Chung KR, Kim YS, Lee YJ. The miniplate with tube for skeletal anchorage. *J Clin Orthod.* 2002;36:407–412.
10. Park HS, Kyung HM, Sung JH. A simple method of molar uprighting with micro-implant anchorage. *J Clin Orthod.* 2002;36:592–596.
11. Lang NP, Loe H. The relationship between the width of keratinized gingiva and gingival health. *J Periodontol.* 1972;43:623–627.
12. Schroeder HE. Dental attachment apparatus: development and structure. In: Schroeder HE, ed. *Oral Structural Biology.* New York, NY: Thieme Medical Publishers Inc; 1991:230–265.
13. Larheim TA, Svanaes DB. Reproducibility of rotational panoramic radiography: mandibular linear dimensions and angles. *Am J Orthod Dentofacial Orthop.* 1986;90:45–51.
14. Larheim TA, Eggen S. Determination of tooth length with a

- standardized paralleling technique and calibrated radiographic measuring film. *Oral Surg Oral Med Oral Pathol.* 1979;48:374–378.
15. Mckee IW, Williamson PC, Lam EW, Heo G, Glover KE, Major PW. The accuracy of 4 panoramic units in the projection of mesiodistal tooth angulations. *Am J Orthod Dentofacial Orthop.* 2002;121:166–175.
16. Roberts WE, Helm FR, Marshall KJ, Gongloff RK. Rigid endosseous implants for orthodontic and orthopedic anchorage. *Angle Orthod.* 1989;59:247–256.