

# Comparison of Skeletal and Dental Morphology in Asymptomatic Volunteers and Symptomatic Patients with Bilateral Degenerative Joint Disease

Ioanna K. Gidarakou, DDS<sup>a</sup>; Ross H. Tallents, DDS<sup>b</sup>; Stephanos Kyrkanides, DDS, PhD<sup>c</sup>; Scott Stein, DMD<sup>d</sup>; Mark Moss, DDS, PhD<sup>e</sup>

**Abstract:** The purpose of this study was to evaluate the effect of bilateral degenerative joint disease (BDJD) on the skeletal and dental patterns of affected individuals. There were 29 symptomatic female patients and 46 asymptomatic normal female volunteers. All study participants had bilateral high-resolution magnetic resonance scans in the sagittal (closed and open) and coronal (closed) planes to evaluate the temporomandibular joints. Linear and angular cephalometric measurements were taken to evaluate the skeletal, denture base and dental characteristics of the two groups. Analysis of variance was used to compare symptomatic subjects with control subjects. There was an overall retrusion of the maxilla and mandible with a clockwise mandibular rotation. The upper and lower denture bases were retruded. The upper incisor was more protruded, whereas the lower incisor was more retroclined in the symptomatic group. The overjet was also increased. This study suggests that subjects with BDJD may manifest altered craniofacial morphology. Clinicians should be aware of this possibility, especially for patients who are growing children and orthognathic surgery candidates. (*Angle Orthod* 2003;73:71–78.)

**Key Words:** Joint; Skeletal; Degeneration, Alterations; Cephalometrics

## INTRODUCTION

Temporomandibular joint disorder (TMD) is a collective term embracing several clinical problems that involve the masticatory musculature, the temporomandibular joint (TMJ) and associated structures or both.<sup>1</sup> Disk displacement (DD) and osteoarthritis (OA) or degenerative joint disease (DJD) are often associated with TMJ pain. DD with reduction is frequently associated with a clicking sound and DD

without reduction is often associated with limitation of jaw opening.<sup>2</sup> In TMJ, OA can be recognized radiologically, surgically, and pathologically by findings such as mandibular condyle flattening, deformity and sclerosis, and osteophytes on the articular surface margins.<sup>3,4</sup> There is degeneration of the disk and areas of erosion of the articular cartilage of the condyle and temporal bone.<sup>3,4</sup> Females are more commonly affected.<sup>5–8</sup>

DD occurs in asymptomatic subjects with a prevalence ranging from 10–33%.<sup>9–14</sup> An even higher prevalence of DD was reported in preorthodontic adolescents by Kamelchuk et al<sup>15</sup> and Nebbe et al.<sup>16</sup> Therefore, presence of DD in autopsy studies should not be surprising. Autopsy studies in both young and mature adults show DD in 10–32% in the general population.<sup>6,17</sup>

Prevalence and distribution of DJD in the TMJ have been also documented in several autopsy<sup>6,7,18,19</sup> and clinical studies. Katzberg et al<sup>20</sup> suggested that degenerative arthritis may be present in young patients presenting with pain and dysfunction. Ogus<sup>21</sup> and Toller<sup>5</sup> reported that nearly one-third to half of the subjects they studied presented with OA before the age of 45.

In a general survey of orthopedic disorders internal derangement of joints was considered one main predisposing factor for the development of OA.<sup>22</sup> DD may progress to OA in the TMJ.<sup>19,23,24</sup> Also according to Yamada et al<sup>25</sup> there

<sup>a</sup> Resident, Department of Dentistry, Division of Orthodontics, University of Rochester School of Medicine and Dentistry.

<sup>b</sup> Professor, Department of Dentistry, Division of Orthodontics and Prosthodontics, Program Director Temporomandibular Joint Disorders, University of Rochester School of Medicine and Dentistry.

<sup>c</sup> Assistant Professor, Department of Dentistry, Division of Orthodontics, University of Rochester School of Medicine and Dentistry.

<sup>d</sup> Clinical Instructor, Department of Dentistry, Division of Orthodontics, University of Rochester School of Medicine and Dentistry.

<sup>e</sup> Assistant Professor, Department of Dentistry and Community and Preventive Medicine, University of Rochester School of Medicine and Dentistry.

Corresponding author: Ross H. Tallents, DDS, Department of Dentistry, Division of Orthodontics and Prosthodontics, Program Director Temporomandibular Joint Disorders, University of Rochester School of Medicine and Dentistry, 625 Elmwood Avenue, Rochester, NY 14620

(e-mail: ross\_tallents@urmc.rochester.edu).

Revised and Accepted: July 2002. Submitted: May 2002.

© 2003 by The EH Angle Education and Research Foundation, Inc.

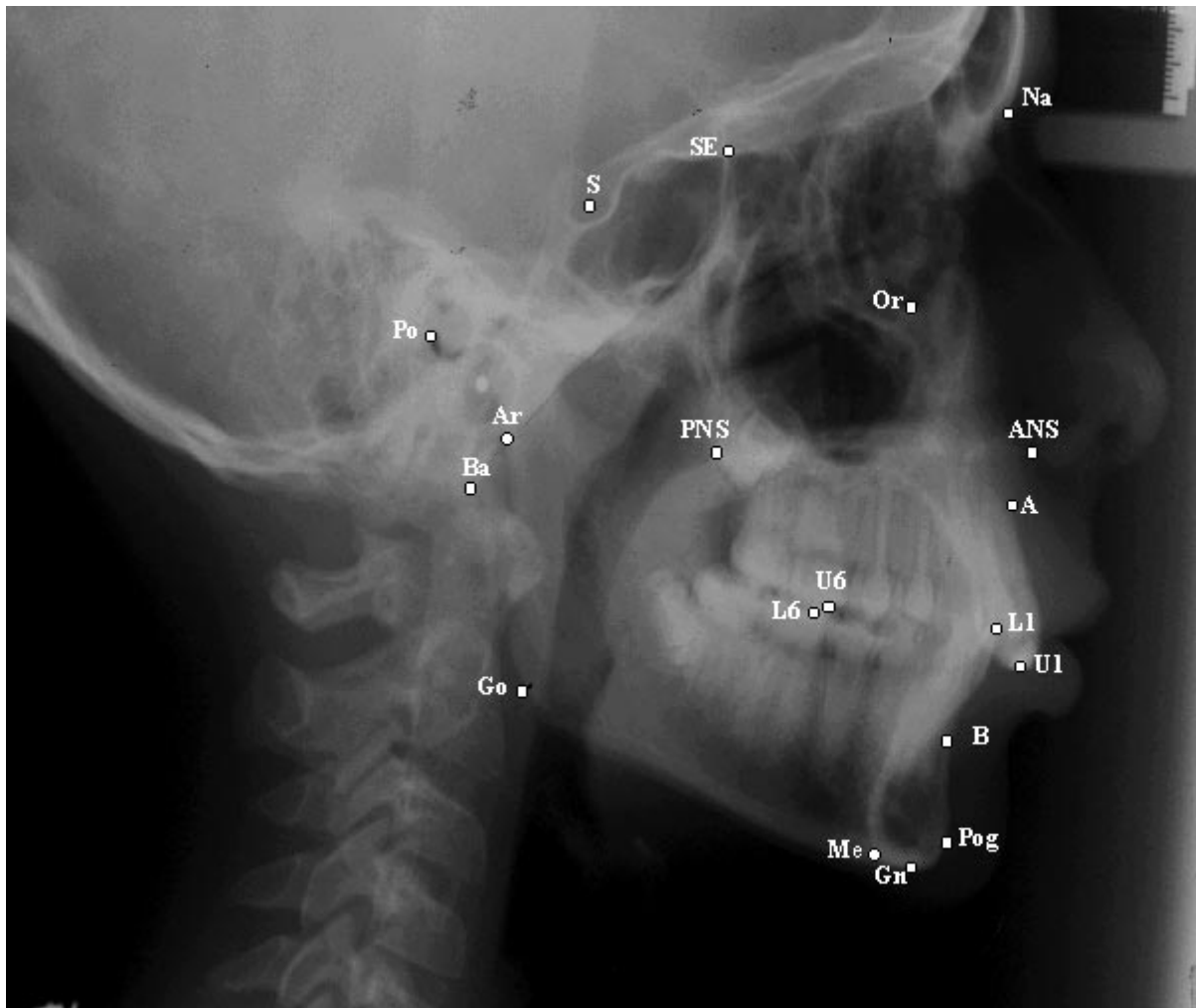


FIGURE 1. Cephalometric landmarks used.

is a correlation between degenerative changes and DD without reduction. On the other hand, joints without DD may show evidence of degenerative changes.<sup>26</sup>

DD affects skeletal morphology.<sup>24,27-35</sup> Animal studies revealed arthrotic changes associated with surgically created DD.<sup>36-40</sup> The relationship between deformed condyles and altered skeletal morphology has been reported in numerous studies.<sup>24,25,32,34,41-46</sup> Possible cytokine-driven mechanisms relating TMJ arthritis and skeletal changes were studied.<sup>47,48</sup>

This study will evaluate asymptomatic volunteers (AVs) and symptomatic bilateral degenerative joint disease (BDJD) subjects presenting with localized jaw joint pain for skeletal and dental morphologic changes.

## MATERIALS AND METHODS

There were 46 asymptomatic normal female volunteers (AV) and 29 patients with BDJD. The mean age was  $28.3 \pm 6.7$  for the AV, whereas the mean age of the symptomatic subjects was  $30.3 \pm 8.5$ . All study participants read and signed an informed consent before the study initiation

that was approved by the Research Subjects Review Board of the University of Rochester, School of Medicine and Dentistry.

All AVs answered a solicitation for examination and inclusion in the study. They were all examined by one investigator (Dr Tallents) and were accepted in the study after completion of the following.

1. A TMJ subjective questionnaire documenting the absence of jaw pain, joint noise, locking, and positive history of TMD.

2. A clinical TMJ and dental examination for signs and symptoms commonly associated with TMD or internal derangement. All symptomatic subjects had localized jaw joint pain and pain on movement or when eating. Vertical opening, right and left mandibular movements were measured and recorded. The masseter, anterior, middle and posterior temporalis, and temporalis tendon area were digitally palpated. All AVs demonstrated a maximal opening of at least 40 mm. The asymptomatic and symptomatic subjects were not blinded to the examiner.

**TABLE 1.** Cranial Base Measurements<sup>a</sup>

Measurements	AV-N		BDJD	
	Mean	SD	Mean	SD
S-Na (mm)	73.06	3.28	72.12	3.80
Ba-Na (mm)	110.1	4.66	108.4	5.59
Ba-S (mm)	47.18	2.54	45.76	3.63
Ba-S-Na (deg)	131.7	5.05	131.1	4.09

<sup>a</sup> *P* values equal to or less than .05 were considered significant. AV-N indicates asymptomatic volunteer with bilateral normal temporomandibular joints; BDJD, symptomatic TMD patient with bilateral degenerative joint disease.

**TABLE 2.** Profile Analysis

Measurements	AV-N		BDJD	
	Mean	SD	Mean	SD
FH to Na-Pg	89.18	3.10	84.00*	3.18
FH to Na-A	90.71	2.99	87.41*	2.61
Na-A-Pog	2.99	6.23	5.56	5.17

\* *P* values equal to or less than .05 were considered significant. AV-N indicates asymptomatic volunteer with bilateral normal temporomandibular joints; BDJD, symptomatic TMD patient with bilateral degenerative joint disease.

**TABLE 3.** Denture Base Measurements

Measurements	AV-N		BDJD	
	Mean	SD	Mean	SD
ANS-PNS	56.30	3.84	51.04*	5.44
SNA	81.81	3.74	78.43*	3.63
SNB	79.18	3.69	74.19*	3.53
ANB	2.64	2.52	4.38*	2.68
A-B to FP	-4.99	3.54	-5.81	5.45

\* *P* values equal to or less than .05 were considered significant. AV-N indicates asymptomatic volunteer with bilateral normal temporomandibular joints; BDJD, symptomatic TMD patient with bilateral degenerative joint disease.

3. All study participants had bilateral high-resolution magnetic resonance scans (MRIs) in the sagittal (closed and open) and coronal (closed) planes to evaluate the TMJs as described by Katzberg et al<sup>49</sup> and Westesson et al.<sup>50</sup> A detailed magnetic resonance assessment of both TMJs in all subjects was performed with a 1.5 T MR system (Signa scanner, General Electric Medical Systems, Milwaukee, Wis) using bilateral high-resolution 6-cm × 8-cm rectangular surface coils with the jaw in the closed, opened, and closed coronal positions. An initial axial localizer with a 52-second scanning time was performed with a repetition time (TR) of 400 milliseconds, a echo time (TE) of 16 milliseconds, a field of view (FOV) of 18 cm, a slice thickness of 3 mm and a 256 × 128 scanning matrix. These images were acquired to protocol paired orthogonal sagittal planes of both TMJs in the closed jaw position with a TR of 2000 milliseconds, TE of 19, and 80 milliseconds, 3-mm image slice thicknesses, FOV of 10 cm and a scanning

**TABLE 4.** Denture Pattern

Measurements	AV-N		BDJD	
	Mean	SD	Mean	SD
FH to OP	5.14	3.67	13.12*	6.04
U1 to L1	128.2	8.41	125.1	12.73
U1 to PP	109.2	6.81	109.0	10.43
U1 to FH	110.7	6.85	109.8	8.03
U1 to S-Na	101.8	6.87	101.8	8.11
U1 to A-Pog	23.30	6.70	29.06*	9.09
U1 perpendicular to A-Pog	7.38	2.06	8.47	3.32
L1 to MP	5.89	7.18	4.67	18.05
L1 to OP	25.10	6.92	20.33*	10.37
L1 to A-Pg	27.70	4.44	27.74	13.47
L1 perpendicular to A-Pog	4.14	1.84	3.47	3.25
Overbite (perpendicular to FH)	2.88	1.70	2.46	3.54
Overjet (parallel to FH)	3.07	1.18	4.69*	2.75

\* *P* values equal to or less than .05 were considered significant. AV-N indicates asymptomatic volunteer with bilateral normal temporomandibular joints; BDJD, symptomatic TMD patient with bilateral degenerative joint disease.

matrix of 256 × 192. These were followed by paired sagittal plane open jaw images with a TR of 1500 milliseconds and TEs of 19 and 80 milliseconds. The final imaging sequence was with the jaw closed and acquired coronal images of both TMJs with a TR of 2000 milliseconds and TEs of 19 and 80 milliseconds. The sagittal images were perpendicular to the long axis of the condyle, and the coronal images were obtained parallel to the long axis of the condyle. Two readers who used established criteria for DD and were blinded to the clinical information independently assessed the MR studies. The primary categories of the joint status that were tabulated were (1) normal disk position, (2) DD with reduction, and (3) DD without reduction with or without DJD. DJD was classified as joints having DD without reduction with deformed discs and flattening of the condylar head and/or osteophyte formation. Each study participant was classified as AV or symptomatic BDJD.

4. All study participants had lateral cephalograms with the teeth in centric occlusion position and with Frankfort horizontal parallel to the floor. All cephalograms were taken with a B.F. Wehmer cephalostat orientated with the Frankfort Horizontal parallel to the floor. The exposure was 77 kVp and 100 mAs with the distance of the film to the mid-sagittal plane to be at 11 cm.

**Null hypothesis**

There are no statistically significant differences between skeletal, denture base, and dental characteristics of symptomatic BDJD patients compared with a sample of individuals with bilateral normal asymptomatic TMJs.

**Cephalometric measurements**

Figure 1 shows the cephalometric landmarks used. Tables 1 through 5 summarize the angular and linear cephalometric

**TABLE 5.** Vertical Relationships

Measurements	AV-N		BDJD	
	Mean	SD	Mean	SD
MP to FH	24.36	4.91	34.48*	6.39
S-Gn to FH	58.02	2.92	64.03*	5.27
Na-ANS (UFH)	53.80	3.06	54.84	2.83
ANS-Me (LFH)	65.99	4.83	71.61*	6.76
Na-Me (TFH)	119.8	5.49	121.4	22.12
UFH:TFH	44.94	2.37	43.72*	2.75
SE-PNS	49.20	3.15	50.19	2.94
Ar-Go	47.86	5.11	44.47*	5.50
U6 perp PP	23.45	1.93	24.08	2.46
U1 perp PP	29.23	2.71	31.03*	2.57
L6 perp MP	32.37	2.40	33.49	4.28
L1 perp MP	41.97	2.49	42.03	4.09
PP to OP	6.65	3.80	14.99*	6.25
PP to MP	25.86	4.99	34.05*	7.21
PP to FH	-1.09	3.54	11.44*	16.79
Ar-Go-Gn	126.5	5.55	129.9 *	6.35
Antigonal notch	171.7	7.58	163.5 *	9.82

\* *P* values equal to or less than .05 were considered significant. AV-N indicates asymptomatic volunteer with bilateral normal temporomandibular joints; BDJD, symptomatic TMD patient with bilateral degenerative joint disease.

measurements generated from the cephalometric points. These measurements were categorized as cranial base measurements, profile analysis, denture base, dental pattern, and vertical relationship measurements.

### Statistical method

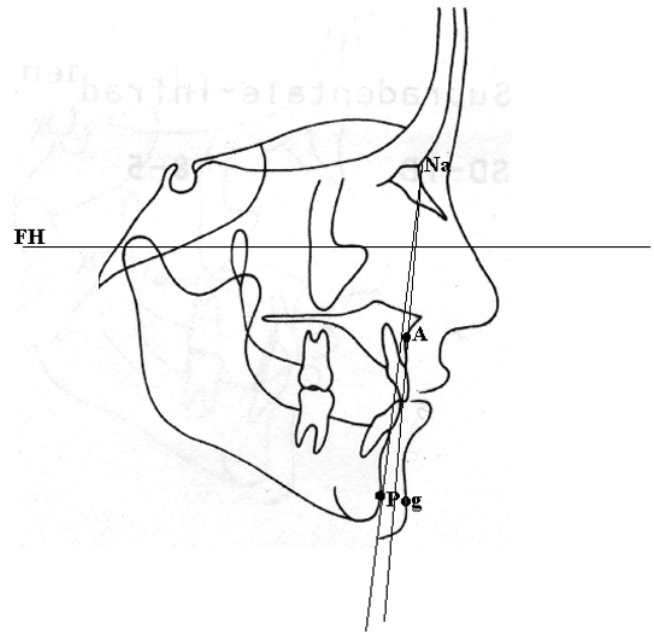
The analysis of variance was used to reveal any statistically significant differences between the control group and the experimental group. All subjects were females matched for age. The *P* value was calculated for each of the variables with a level of significance for each test established at .05.

### Error of measurement

Errors in landmark localization during tracing were evaluated by retracing 20 cephalograms in the experimental and control group. The reliability of tracing, landmark identification, and analytical measurements had an intraclass correlation coefficient greater than 0.92.

## RESULTS

Tables 1 through 5 summarize the findings of the measurements. The values in Table 1 demonstrate that there are no cranial base differences between the symptomatic and asymptomatic subjects. In the profile analysis, the facial plane angle (Na-Pog to FH) and Lande's angle (Na-A to FH) are reduced in the BDJD group (Table 2). The denture base measurements show a reduction in SNA and SNB angles. The ANB angle is increased because of a relatively more pronounced decrease of the SNB value compared



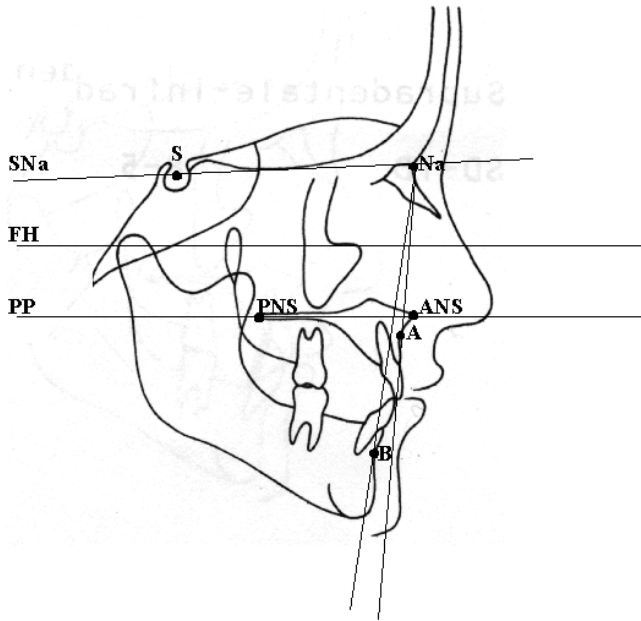
**FIGURE 2.** Significant measurements of the profile analysis (FH to Na-Pog [Facial Plane Angle], FH to Na-A [Lande's Angle]).

with the SNA reduction. Also, there is a reduction of the anteroposterior dimension of the maxilla as shown by the ANS-PNS measurement (Table 3). The dental characteristics demonstrated that the upper incisor is more protruded (U1 to A-Pog), the lower incisor is more retroclined (L1 to Occlusal Plane), and the overjet increased in the BDJD sample (Table 4). There is also an increased divergence of the occlusal plane to Frankfurt horizontal (FH to OP). Table 5 demonstrated the significant differences in the vertical pattern measurements. There is an increase in the mandibular plane angle, Y-axis (S-Gn to FH), and lower facial height (ANS-Me). Ramal height is decreased (Ar-Go). The upper incisor is supraerupted in the BDJD group (U1 to PP). There is an increased angle of the palatal plane to both the occlusal plane (PP to OP) and the mandibular plane (PP to MP). The gonial angle is increased as shown by the angle Ar-Go-Gn, and there is a pronounced antigonial notch on the lower mandibular border of the BDJD patients (Table 5). The significant measurements are shown in Figures 2 through 5.

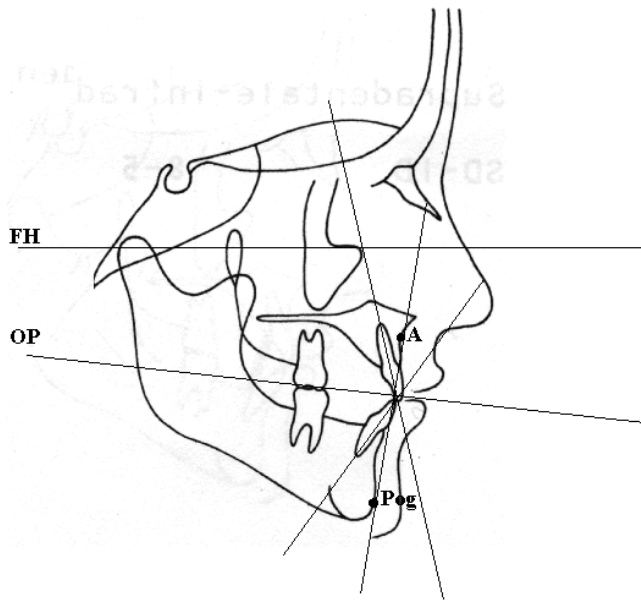
## DISCUSSION

DD is quite prevalent in the asymptomatic population. Autopsy studies in both young and mature adults show DD in 10–32% of the general population.<sup>6,17</sup> Tallents et al evaluated TMJ sounds in AVs and found that 24% had one or two joints with DD as diagnosed by MRI.<sup>10</sup> Ribeiro et al<sup>11</sup> found the prevalence of DD in asymptomatic children and young adults to be 34%, whereas 86% of the symptomatic temporomandibular disorder patients had DD. These studies





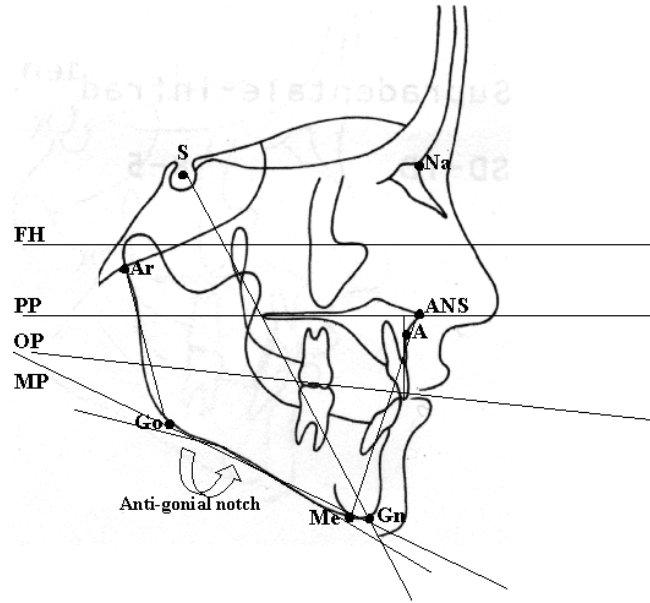
**FIGURE 3.** Significant measurements of the denture base (ANS-PNS, SNA, SNB, ANB).



**FIGURE 4.** Significant measurements of the denture pattern (FH to OP, U1 to A-Pog, L1 to OP, overjet).

suggest that DD is relatively common in AVs. Similar results (32%) in AVs were found by Kircos et al.<sup>14</sup>

OA is also quite common and might affect young as well as older individuals. Oberg et al<sup>6</sup> in an autopsy study found that with increasing age the number of joints with local changes in the shape, remodeling, or arthritic changes of the articular surfaces increased. The arthritic changes were significantly more prevalent in women. Prevalence and distribution of DJD in the TMJ have been documented in several other autopsy investigations.<sup>6,7,18</sup> Oberg et al<sup>6</sup> suggested



**FIGURE 5.** Significant measurements of vertical relationships (MP to FH, S-Gn to FH [Y-axis], ANS-Me [LFH], UFH:TFH, Ar-Go, U1 perpendicular to PP, PP to OP, PP to MP, PP to FH, Ar-Go-Gn [gonial angle], antgonial notch).

that arthrotic changes are relatively common (27%) in ages above 39 years but are rare in individuals below 40 years. Westesson et al<sup>19</sup> showed in an autopsy study that cadavers with DJD were slightly older (mean age 76) than those with normal articular surfaces (mean age 72). Thirty-nine percent of the 127 TMJ autopsy specimens studied were affected by OA.

Katzberg et al<sup>20</sup> demonstrated degenerative arthritis in 13 of 31 (42%) symptomatic children (8–16 years) presenting with pain and dysfunction. About 33% of the 130 patients with OA studied by Ogus<sup>21</sup> were under 40 years. Toller<sup>5</sup> also reported that almost 50% of patients with symptomatic osteoarthritis of the TMJ presented before the age of 45 years. These studies suggest that OA may begin/occur at a young age. This also would be supported by the studies of Ribeiro et al<sup>11</sup> and Nebbe et al<sup>16,44</sup> where DD was very common in children and young adults suggesting that some subjects are at risk for the degeneration of the joints.

OA seems to be correlated with DD<sup>19,23–25</sup> although Roberts et al<sup>26</sup> suggested that 10% of arthrographically diagnosed normal joints (without DD) showed some evidence of DJD.

DD and subsequent DJD causes facial asymmetry.<sup>24,29,30,31</sup> We evaluated the effect of BDDJ on the skeletal and dental patterns of the affected individuals. We found numerous dental and skeletal differences between the symptomatic subjects with BDDJ and the AV group.

We found that in the BDDJ group both the maxilla and the mandible are retropositioned in relation to the forehead (reduced Lande's and facial plane angles, respectively). One would expect that the mandible would be more posteriorly

positioned because of the condylar degeneration and the shortening of the ramal height. Chin retrusion in DJD patients also has been reported.<sup>41-43</sup>

The denture base measurements show a reduction in SNA and SNB angles. The ANB angle is increased because of a relatively more pronounced decrease of the SNB value compared with the SNA reduction. This suggests that the upper and lower denture bases are retruded in the BJD group with the mandibular denture base being relatively more repositioned than the maxillary denture base. This finding agrees with that of Yamada et al<sup>25</sup> who found a decreased ANB angle in their patients presenting with bilateral condylar changes such as osteophytes and erosion. Combined with the profile analysis measurements, it is evident that both upper and lower jaws and their denture bases are positioned more posteriorly in the symptomatic group. Also, there is a reduction of the anteroposterior dimension of the maxilla as shown by the ANS-PNS measurement (Table 3).

There were significant differences between the two groups in the dental measurements. The upper incisor is more protruded (U1 to A-Pog), whereas the lower incisor is more retroclined (L1 to occlusal plane) and as a result the overjet is increased in the BJD sample (Table 4). Yamada et al<sup>25</sup> also found a more retroclined lower incisor. The increase overjet can also be attributed to the backward mandibular rotation and the mandibular retrusion. There is also an increased divergence of the occlusal plane to Frankfurt horizontal (FH to OP) with a clockwise rotation of the occlusal plane.

Significant differences were found in the vertical pattern measurements. There is an increase in the mandibular plane angle, Y-axis (S-Gn to FH), gonial angle (Ar-Go-Gn), and lower facial height (ANS-Me). All these increased measurements suggest a clockwise rotation of the mandible. Ramal height is decreased (Ar-Go). Dibbets<sup>32</sup> reported similar skeletal deviations in growing children with temporomandibular dysfunction. These children had reduced ramal height, steeper mandibular plane, increased gonial angle, and increased lower facial height. He mentioned that the profile of these children was more Class II. Yamada et al<sup>25</sup> also reported increased lower facial height, reduced ramal height, and increased gonial angle, whereas Nickerson and Moystad<sup>46</sup> reported a steeper mandibular plane in their sample of patients with bilateral condylar remodeling. Schellhas et al<sup>41</sup> reported loss of posterior mandibular and facial height in patients with DJD. The reduced ramal height can be attributed to the condylar resorption and degeneration. Animal models with DD also show reduced ramal height. Shortening and flattening of the condylar head with loss of posterior height has been demonstrated in the growing rabbit after unilateral surgically created DD.<sup>40</sup>

The upper incisor is supraerupted in the BJD group (U1 to PP). This is possibly a dental compensation backwards to maintain positive overbite as the mandible rotates backwards. There

is an increased angle of palatal plane to both the occlusal plane (PP to OP) and the mandibular plane (PP to MP). There is also a pronounced antigonial notch on the lower mandibular border of the BJD patients. Dibbets<sup>32</sup> reported the formation of an antigonial notch in children with a deviant (flattened) contour of their condyles.

The present study showed mandibular retrusion and rotation, short ramal height, long lower anterior facial height, and compensatory adaptation in the upper and lower incisors in the BJD group. These results suggest that BJD produces a clockwise rotation of the mandible, a retrognathic appearance, and a vertical facial pattern. These features should alert the clinician when treating orthodontic or orthodontic/orthognathic patients. Although our symptomatic group consisted of adults, growing children may be at risk for developing DJD and exhibiting altered growth and skeletal morphology as suggested by Dibbets.<sup>32</sup>

Link and Nickerson<sup>24</sup> and Schellhas et al<sup>31</sup> suggested a cause and effect relationship between DD and facial growth. Nebbe et al<sup>29</sup> have suggested that adolescent female patients presenting for orthodontic treatment with bilateral DD show numerous angular and linear cephalometric differences compared with aged-matched female controls. There was an increased mandibular and palatal plane relative to sella-nasion, posterior rotation of the mandible, a decrease in Rickett's facial axis, reduced posterior facial height and ramal height, as well as a slight increase in middle anterior facial height. Schellhas et al<sup>31</sup> who evaluated children 14 years or younger concluded that TMJ derangements are both common in children and may contribute to the development of retrognathia, with or without asymmetry. Ninety-three percent of the retrognathic subjects were found to have DD, generally bilateral. They proposed that in the growing facial skeleton, DD either retards or arrests condylar growth, which results in decreased vertical dimension in the proximal mandibular segment(s) with ultimately mandibular deficiency and/or asymmetry. Bosio et al<sup>33</sup> suggested that symptomatic TMD patients with bilateral DD had a repositioned mandible indicated by a smaller mean SNB angle compared with AVs and symptomatic patients with no DD. Schellhas et al<sup>34</sup> in their retrospective study of 100 consecutive orthognathic surgery candidates found that DD was prevalent especially in patients who exhibited change in their facial contour in the year before the evaluation. The degree of joint degeneration directly paralleled the severity of retrognathia. These studies<sup>24,29,31,33,34</sup> have skeletal morphology findings similar to our study.

DD is common in AVs (33%) and patients presenting for orthodontic treatment (45%).<sup>15</sup> In some subjects, there may be a progression to DJD and that might accentuate existing skeletal and dental problems, such as open bite and increased overjet.<sup>42,44,45</sup> This may or may not be accompanied by pain.<sup>44</sup> Also, TMJ degeneration may result in acquired mandibular deformity as reported by Schellhas et al<sup>41</sup> and

Steward and Harris.<sup>45</sup> Although it is still not possible to accurately predict which joint will degenerate and when the degeneration process will begin, there are studies that focus on the molecular level of the degeneration process. Alstergren et al<sup>48</sup> reported that there is an association of IL-1 $\beta$  in the synovial fluid with pain and hyperalgesia in the TMJ region as well as an anterior open bite. IL-1 $\beta$  induces metalloproteinase production resulting in degradation of cartilage. Kubota et al<sup>47</sup> showed that IL-1 $\beta$  levels in synovial fluid of the TMJ have a positive correlation with OA changes. They also showed that the stromelysin (MPP3, a metalloproteinase) activity detected was greatly increased in patients with cartilage degradation. They suggested that both changes could be important markers of early bone deterioration in TMJs that is undetectable by radiographic imaging. Further studies are necessary to find the mechanism or mechanisms underlying the initiation of degenerative disease in the TMJ and other joints.

### CONCLUSIONS

The results of this study show that alterations in skeletal morphology may be associated with BDDJ. The mechanisms by which DJD is produced or that cause the reported skeletal and dental alterations are yet to be clarified. This study and other studies suggest that DJD may affect skeletal morphology. Clinicians should be aware of these possibilities, in particular for patients who are growing children and orthognathic surgery candidates, especially when the patient presents with retrognathic or asymmetric jaw relationships.

### REFERENCES

- Okesson JP. *Orofacial Pain. Guidelines for Assessment, Diagnosis and Management*. Carol Stream, Ill: Quintessence Publishing Co, Inc; 1996:116.
- Katzberg RW, Westesson PL, Tallents RH, Drake CM. Orthodontics and temporomandibular joint disorders. *Am J Orthod Dentofacial Orthop*. 1996;109:515-520.
- Wilkes CH. Internal derangement of the temporomandibular joint: pathologic variations. *Arch Otolaryngol Head Neck Surg*. 1989; 115:469-477.
- Schellhas KP. Internal derangement of the temporomandibular joint: radiologic staging with clinical, surgical and pathologic correlation. *Magn Reson Imaging*. 1989;7(5):495-515.
- Toller PA. Osteoarthritis of the mandibular condyle. *Br Dent J*. 1973;134:223-231.
- Oberg T, Carlsson GE, Fajers CM. The temporomandibular joint. A morphometric study on a human autopsy material. *Acta Odontol Scand*. 1971;29:349-384.
- Blackwood HJJ. Arthritis of the mandibular joint. *Br Dent J*. 1963;115(8):317-326.
- Kopp S. Subjective symptoms in temporomandibular joint osteoarthritis. *Acta Odontol Scand*. 1977;35:207-215.
- Westesson PL, Eriksson L, Kurita K. Reliability of a negative clinical temporomandibular joint examination: prevalence of disk displacement in asymptomatic temporomandibular joint. *Oral Surg Oral Med Oral Pathol*. 1989;68:551-554.
- Tallents RH, Hatala M, Katzberg RW, Westesson PL. Temporomandibular joint sounds in asymptomatic volunteers. *J Prosthet Dent*. 1993;69:298-304.
- Ribeiro RF, Tallents RH, Katzberg RW, Murphy WC, Moss ME, Magalhaes AC, Tavano O. The prevalence of disk displacement in symptomatic and asymptomatic volunteers aged 6 to 25 years. *J Orofacial Pain*. 1997;11:37-46.
- Tallents RH, Katzberg RW, Murphy W, Proskin H. Magnetic resonance imaging findings in asymptomatic volunteers and symptomatic patients with temporomandibular disorders. *J Prosthet Dent*. 1996;75:529-533.
- Morrow D, Tallents RH, Katzberg RW, Murphy WC, Hart TC. Relationship of other joint problems and anterior disk displacement in symptomatic TMD patients and in asymptomatic volunteers. *J Orofacial Pain*. 1996;10:15-20.
- Kircos LT, Ortendhal DA, Mark A, Arakawa M. Magnetic resonance imaging of the TMJ disk in asymptomatic volunteers. *J Oral Maxillofac Surg*. 1987;45:852-854.
- Kamelchuk L, Nebbe B, Baker C, Major P. Adolescent TMJ tomography and magnetic resonance imaging: a comparative analysis. *J Orofacial Pain*. 1997;11:321-327.
- Nebbe B, Major PW. Prevalence of TMJ disk displacement in a pre-orthodontic adolescent sample. *Angle Orthod*. 2000;7:454-463.
- Solberg WK, Hansson TL, Nordstrom B. The temporomandibular joint in young adults at autopsy: a morphologic classification and evaluation. *J Oral Rehabil*. 1985;12:303-321.
- Hansson T, Oberg T. Arthrosis and deviation in form in the temporomandibular joint. *Acta Odontol Scand*. 1977;35:167-174.
- Westesson P-L, Rohlin M. Internal derangement related to osteoarthritis in temporomandibular joint autopsy specimens. *Oral Surg*. 1984;57:17-22.
- Katzberg RW, Tallents RH, Hayakawa K, Miller TL, Goske MJ, Wood BP. Internal derangement of the temporomandibular joint: findings in the pediatric age group. *Radiology*. 1985;154:125-127.
- Ogus H. Degenerative disease of the temporomandibular joint in young persons. *Br J Oral Surg*. 1979;17:17-26.
- Adams JC. *Outline of Orthopaedics*. 9th ed. London, Churchill Livingstone; 1981:60-61.
- Eriksson L, Westesson P-L. Clinical and radiologic study of patients with anterior disk displacement of the temporomandibular joint. *Swed Dent J*. 1983;7:55-64.
- Link JJ, Nickerson JW Jr. Temporomandibular joint internal derangements in an orthognathic surgery population. *Int J Adult Orthod Orthognath Surg*. 1992;7:161-169.
- Yamada K, Hiruma Y, Hanada K, Hayashi T, Koyama J, Ito J. Condylar bony change and craniofacial morphology in orthodontic patients with TMD symptoms: a pilot study using helical computed tomography and magnetic resonance imaging. *Clin Orthod Res*. 1999;2:133-142.
- Roberts CA, Katzberg RW, Tallents RH, Espeland MA, Handelman SL. Correlation of clinical parameters to the arthrographic depiction of temporomandibular joint internal derangement. *Oral Surg Oral Med Oral Pathol*. 1988;66:32-36.
- Brand JW, Nielson KJ, Tallents RH, Nanda RS, Currier GFC, Owen WL. Lateral cephalometric analysis of skeletal patterns in patients with and without internal derangement of the temporomandibular joint. *Am J Orthod Dentofacial Orthop*. 1995;107: 121-128.
- Nebbe B, Major PW, Prasad NGN. Adolescent female craniofacial morphology associated with advanced bilateral TMJ disk displacement. *Eur J Orthod*. 1998;20:701-712.
- Nebbe B, Major PW, Prasad NGN. Female adolescent facial pattern associated with TMJ disk displacement and reduction in disk length: Part I. *Am J Orthod Dentofacial Orthop*. 1999;116:168-176.

30. Trpkova B, Major P, Nebbe B, Prasad N. Craniofacial asymmetry and temporomandibular internal derangement in female adolescents: a posteroanterior cephalometric study. *Angle Orthod.* 2000;70:81–88.
31. Schellhas KP, Pollei SR, Wilkes CH. Pediatric internal derangements of the temporomandibular joint: effect on facial development. *Am J Orthod Dentofacial Orthop.* 1993;104:51–59.
32. Dibbets JMH, Van Der Weele LT, Uildriks AKJ. Symptoms of TMJ dysfunction: indicators of growth patterns? *J Pedod.* 1985;9:265–284.
33. Bosio JA, Burch JG, Tallents RH, Wade DB, Beck FM. Lateral cephalometric analysis of asymptomatic volunteers and symptomatic patients with and without temporomandibular joint displacement. *Am J Orthod Dentofacial Orthop.* 1998;114(3):248–255.
34. Schellhas KP, Piper MA, Bessette RW, Wilkes CH. Mandibular retrusion, temporomandibular joint derangement and orthognathic surgery planning. *Plastic Recon Surg.* 1992;90:218–232.
35. Nebbe A, Major PW, Prasad NG, Grace M, Kamelchuk LS. TMJ internal derangement and adolescent craniofacial morphology: a pilot study. *Angle Orthod.* 1997;67(6):407–414.
36. Macher DJ, Westesson PL, Brooks SL, Hicks D, Tallents RH. Temporomandibular joint surgically created disk displacement causes arthrosis in the rabbit. *Oral Surg Oral Med Oral Pathol.* 1992;73:645–649.
37. Qadan S, Macher DJ, Tallents RH, Kyrkanides S, Moss ME. The effect of surgically induced anterior disk displacement of the temporomandibular joint on the midface and cranial base. *Clin Orthod Res.* 1999;2:124–132.
38. Tallents RH, Macher DJ, Rivoli P, Scapino R, Puzas JE, Katzberg WR. An animal model for meniscus displacement in the rabbit. *J Craniomandib Disord Facial Oral Pain.* 1990;4:233–240.
39. Legrell PE, Reidel J, Nylander K, Horstedt P, Isberg A. Temporomandibular joint condyle changes after surgically induced non-reducing disk displacement in rabbits: a macroscopic and microscopic study. *Acta Odontol Scand.* 1999;57:290–300.
40. Hatala MP, Tallents RH, Spoon M, Subtelny JD, Kyrkanides S. Effect of surgically created disk displacement on mandibular asymmetry in the growing rabbit. *Oral Surg Oral Med Oral Pathol Oral Radiol Endod.* 1996;82:625–633.
41. Schellhas KP, Piper MA, Omlie MR. Facial skeleton remodeling due to temporomandibular joint degeneration: an imaging study of 100 patients. *AJNR.* 1990;11:541–551.
42. Schellhas KP. Unstable occlusion and temporomandibular joint disease. *J Clin Orthod.* 1989;23:332–337.
43. Schellhas KP, Keck RJ. Disorders of skeletal occlusion and temporomandibular joint disease. *Northwest Dent.* 1989;68:35–42.
44. Nordahl S, Alstergren P, Appelgren A, Appergren B, Eliasson S, Kopp S. Pain, tenderness, mandibular mobility and anterior open bite in relation to radiographic erosions in temporomandibular joint disease. *Acta Odontol Scand.* 1997;5:18–22.
45. Stewart A, Harris M. Acquired anterior open bite and facial arthromyalgia: possible aetiology. *Br J Oral Maxillofac Surg.* 1996;34:174–180.
46. Nickerson JW, Moystad A. Observations on individuals with radiographic bilateral condylar remodeling. *Cranio.* 1982;1:21–37.
47. Kubota E, Iamamura H, Kubota T, Shibata T, Murakami K-I. Interleukin 1 $\beta$  and stromelysin (MMP3) activity of synovial fluid as possible markers of osteoarthritis in the temporomandibular joint. *J Oral Maxillofac Surg.* 1997;55:20–27.
48. Alstergren P, Ernberg M, Kuarnstrom M, Kopp S. Interleukin-1 $\beta$  in synovial fluid from the arthritic temporomandibular joint and its relation to pain, mobility and anterior open bite. *J Oral Maxillofac Surg.* 1998;56:1059–1065.
49. Katzberg RW, Westesson PL, Tallents RH, Anderson R, Kurita K, Manzione JV, Totterman S. Temporomandibular joint: magnetic resonance assessment of rotational and sideways disk displacement. *Radiology.* 1988;169:741–748.
50. Westesson PL, Katzberg RW, Tallents RH, Sanchez-Woodworth RE, Svensson SA. Temporomandibular joint: comparison of MR images with creosectional anatomy. *Radiology.* 1987;164:59–64.