

Comparison of Skeletal and Dental Morphology in Asymptomatic Volunteers and Symptomatic Patients with Normal Temporomandibular Joints

Ioanna K. Gidarakou, DDS^a; Ross H. Tallents, DDS^b; Stephanos Kyrkanides, DDS, PhD^c; Scott Stein, DMD^d; Mark E. Moss, DDS, PhD^e

Abstract: The purpose of this study was to evaluate the skeletal and dental pattern of symptomatic individuals (SN) with normal temporomandibular joints (TMJs). There were 42 symptomatic female patients with bilaterally normal TMJs and 46 asymptomatic normal female volunteers (AV). All study participants had bilateral high-resolution magnetic resonance scans in the sagittal (closed and open) and coronal (closed) planes to evaluate the TMJs. Linear and angular cephalometric measurements were taken to evaluate the skeletal, denture base, and dental characteristics of the two groups. ANOVA was used to compare the symptomatic subjects with the control subjects. There were no significant differences between the two groups besides the lower incisor being more retruded in the asymptomatic group. This study showed that there are no alterations in skeletal morphology in SN individuals compared with AV. (*Angle Orthod* 2003;73:116–120.)

Key Words: Joint; Skeletal; Alterations; Cephalometrics

INTRODUCTION

Temporomandibular disorder (TMD) is a collective term embracing a number of clinical problems that involve the masticatory musculature, the temporomandibular joint (TMJ) or associated structures. Temporomandibular disorders have been identified as a major cause of nondental pain in the orofacial region and are considered to be a subclassification of musculoskeletal disorders.¹ Although TMD was previously viewed as one syndrome, current research

supports the view that it is a cluster of related disorders in the masticatory system that has many common symptoms.² The most frequent presenting symptom is pain, usually localized in the muscles of mastication, preauricular area, or the TMJ. In addition to complaints of pain, patients with these disorders frequently have limited or asymmetric mandibular movement and TMJ sounds. These sounds are most frequently described as clicking, grating, or crepitus.¹ A general categorization of the intra-articular conditions can include disk displacement with reduction, disk displacement without reduction, and disk displacement without reduction with degenerative joint disease (DJD).

^a Resident, Department of Dentistry, Division of Orthodontics, University of Rochester School of Medicine and Dentistry, Rochester, NY.

^b Professor, Department of Dentistry, Division of Orthodontics and Prosthodontics, Program Director Temporomandibular Joint Disorders, University of Rochester School of Medicine and Dentistry.

^c Assistant Professor, Department of Dentistry, Assistant Chief of Division of Orthodontics, Craniofacial Research Core Coordinator, University of Rochester School of Medicine and Dentistry.

^d Clinical Instructor, Department of Dentistry, Division of Orthodontics, University of Rochester School of Medicine and Dentistry.

^e Assistant Professor, Department of Dentistry and Community and Preventive Medicine, University of Rochester School of Medicine and Dentistry.

Corresponding author: Ross H. Tallents, DDS, Department of Dentistry, Division of Orthodontics and Prosthodontics, Program Director Temporomandibular Joint Disorders, University of Rochester School of Medicine and Dentistry, 625 Elmwood Avenue, Rochester, NY 14620.

(e-mail: ross_tallents@urmc.rochester.edu).

Accepted: August 2002. Submitted: August 2002.

© 2003 by The EH Angle Education and Research Foundation, Inc.

Dibbets et al suggested that the prevalence of subjectively communicated symptoms of TMJ dysfunction appear to consistently increase with age, with a stabilization of the prevalence at young adulthood.³ Autopsy studies in both young and mature adults show disk displacement (DD) in 10–32% of the general population.^{4,5} Many studies found prevalence of DD in the general population ranging from 15% to 34%.^{6–11} All these studies demonstrate that DD can be present in patients without clinical signs and symptoms. The finding of a high prevalence of joint abnormalities in asymptomatic volunteers is not unique to the TMJ. Magnetic resonance imaging studies of other joints (cervical spine, lumbar spine, knee) in asymptomatic subjects indicate similar disease prevalences.^{12–18} On the other hand, not all TMJ pain, clicking, and limited jaw motion can be related to DD within the TMJ.¹⁹ Paesani et al²⁰ studied 115

patients with signs and symptoms of craniomandibular disorders. Of those, 78% had different stages of unilateral or bilateral DD and 22% had bilaterally normal TMJs. Dworkin et al suggested that patients' complaints are not related with the degree of pathology.²¹

The presence of DD has been suggested to affect the skeletal morphology. Nebbe et al have suggested that adolescent female patients presenting for orthodontic treatment with bilateral DD showed numerous angular and linear cephalometric differences compared with age-matched female controls.²² Another study investigated the amount of craniofacial asymmetry in female orthodontic patients with unilateral or bilateral TMJ DD compared with normal controls without DD using posteroanterior films. The authors suggested that a female patient with unilateral or bilateral DD might present with or develop a vertical mandibular deficiency.²³

This study will compare asymptomatic volunteers (AV) and symptomatic normal (SN) subjects presenting with localized jaw joint pain for skeletal and dental morphologic changes.

MATERIALS AND METHODS

Materials

There were 46 asymptomatic normal female volunteers (AV) and 42 symptomatic age-matched females with bilaterally normal joints (SN). The age range was 28.3 ± 6.7 y for the AV, whereas the mean age of the symptomatic subjects was 28.9 ± 10.7 y. All study participants read and signed an informed consent form before the study initiation that was approved by the Research Subjects Review Board of the University of Rochester, School of Medicine and Dentistry.

All asymptomatic volunteers answered a solicitation for examination and inclusion in the study. They were all examined by one investigator (Dr Tallents) and were accepted in the study following completion of:

1. A TMJ subjective questionnaire documenting the absence of jaw pain, joint noise, locking, and positive history of TMD.
2. A clinical TMJ and dental examination for signs and symptoms commonly associated with TMD or internal derangement. All symptomatic subjects had localized jaw joint pain and pain on movement or when eating. Vertical opening, right and left mandibular movements were measured and recorded. The masseter, anterior, middle, and posterior temporalis and temporalis tendon area were digitally palpated. All asymptomatic volunteers demonstrated a maximal opening of at least 40 mm. The asymptomatic and symptomatic subjects were not blinded to the examiner.
3. All study participants had bilateral high-resolution magnetic resonance scans (MRIs) in the sagittal (closed and

open) and coronal (closed) planes to evaluate the TMJs as described by Katzberg et al⁹ and Westesson et al.⁶ A detailed magnetic resonance assessment of both TMJs in all subjects was performed with a 1.5 T MR system (Signa scanner, General Electric Medical Systems, Milwaukee, Wis) using bilateral high resolution 6×8 cm rectangular surface coils with the jaw in the closed and opened sagittal positions and closed coronal positions. An initial axial localizer with a 52-second scanning time was performed with a repetition time (TR) of 400 milliseconds, a echo time (TE) of 16 milliseconds, a field of view (FOV) of 18 cm, a slice thickness of 3 mm, and a 256×128 scanning matrix. These images were acquired to protocol paired orthogonal sagittal planes of both TMJs in the closed jaw position with a TR of 2000 milliseconds, TEs of 19 and 80 milliseconds, 3-mm image slice thicknesses, FOV of 10 cm, and a scanning matrix of 256×192 . These were followed by paired sagittal plane open jaw images with a TR of 1500 milliseconds and TEs of 19 and 80 milliseconds. The final imaging sequence was with the jaw closed and acquired coronal images of both TMJs with a TR of 2000 milliseconds and TEs of 19 and 80 milliseconds. The sagittal images were perpendicular to the long axis of the condyle, and the coronal images were obtained parallel to the long axis of the condyle. The MR studies were independently assessed by two readers who used established criteria for DD and were blinded to the clinical information. Each study participant was classified as AV or SN.

4. All study participants had lateral cephalograms with the teeth in centric occlusion position. All cephalograms were taken with a B.F. Wehmer cephalostat orientated with the Frankfort Horizontal parallel to the floor. The exposure was 77 KVP and 100MAS with the distance of the film to the midsagittal plane to be at 11 cm. All cephalograms were taken on the same radiographic machine at the Orthodontic Clinic set for standardized exposure.

Null hypothesis

There are no statistically significant differences between skeletal, denture base, and dental characteristics of SN patients compared with a sample of individuals with bilateral normal asymptomatic TMJs.

Cephalometric measurements

Figure 1 shows the cephalometric landmarks used. Tables 1–5 summarize the angular and linear cephalometric measurements used in this study. These measurements were categorized as cranial base measurements, profile analysis, denture base, dental pattern, and vertical relationship measurements.

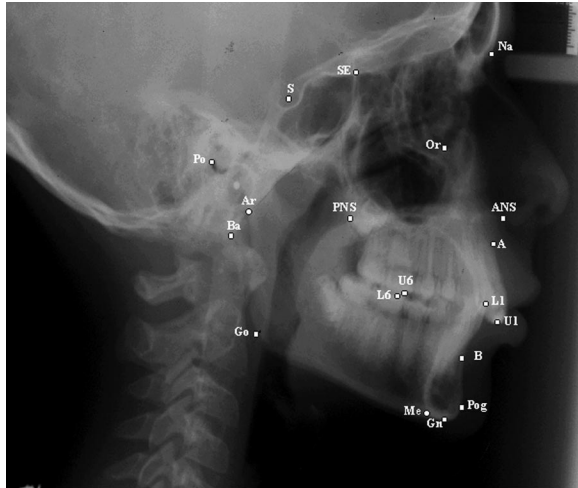


FIGURE 1. Cephalometric landmarks used.

TABLE 1. Cranial Base Measurements*

Measurements	AV-N ^a		SN	
	Mean	SD	Mean	SD
S-Na	73.06	3.28	72.05	2.90
Ba-Na	110.1	4.66	108.7	4.09
Ba-S	47.18	2.54	46.33	3.71
Ba-S-Na	131.7	5.05	132.7	5.69

* *P* values equal to or less than .05 were considered significant.

^aAV-N indicates asymptomatic volunteer with bilateral normal temporomandibular joints; SN, symptomatic TMD patient with bilateral normal joints.

Statistical method

The analysis of variance (ANOVA) was used to reveal any statistically significant differences between the control group and the experimental group. All subjects were matched for age. The *P* value was calculated for each of the variables with a level of significance for each test established at .05.

Error of measurement

Errors in landmark localization during tracing were evaluated by retracing 20 cephalograms in the experimental and control groups. The reliability of tracing, landmark identification, and analytical measurements had intraclass correlation coefficient greater than .92.

RESULTS

Tables 1–5 summarize the findings of the measurements.

From the tables above it can be seen that there are few significant differences between the experimental and control groups. The cranial base, skeletal profile, denture base, and vertical measurements showed no statistical differences. The lower incisor was more retruded in the SN group (Figure 2).

TABLE 2. Profile Analysis*

Measurements	AV-N ^a		SN	
	Mean	SD	Mean	SD
FH to Na-Pg	89.18	3.10	89.12	3.26
FH to Na-A	90.71	2.99	91.11	3.52
Na-A-Pog	2.99	6.23	4.06	5.70

* *P* values equal to or less than .05 were considered significant.

^aAV-N indicates asymptomatic volunteer with bilateral normal temporomandibular joints; SN, symptomatic TMD patient with bilateral normal joints.

TABLE 3. Denture Base Measurements*

Measurements	AV-N ^a		SN	
	Mean	SD	Mean	SD
ANS-PNS	56.30	3.84	56.41	4.09
SNA	81.81	3.74	81.48	3.51
SNB	79.18	3.69	78.43	3.27
ANB	2.64	2.52	3.05	2.22
A-B to FP	-4.99	3.54	-5.51	3.39

* *P* values equal to or less than .05 were considered significant.

^aAV-N indicates asymptomatic volunteer with bilateral normal temporomandibular joints; SN, symptomatic TMD patient with bilateral normal joints.

TABLE 4. Denture Pattern

Measurements	AV-N ^a		SN	
	Mean	SD	Mean	SD
FH to OP	5.14	3.67	4.47	4.45
U1 to L1	128.2	8.41	133.0	12.05
U1 to PP	109.2	6.81	108.6	8.02
U1 to FH	110.7	6.85	110.4	7.70
U1 to S-Na	101.8	6.87	100.8	7.62
U1 to A-Pog	23.30	6.70	23.44	8.38
U1 perpendicular to A-Pog	7.38	2.06	7.31	2.96
L1 to MP	5.89	7.18	2.33	6.78
L1 to OP	25.10	6.92	22.59	7.82
L1 to A-Pg	27.70	4.44	24.04*	5.73
L1 perpendicular to A-Pog	4.14	1.84	3.73	2.51
Overbite (perpendicular to FH)	2.88	1.70	2.69	2.30
Overjet (parallel to FH)	3.07	1.18	3.30	2.08

* *P* values equal to or less than .05 were considered significant.

^aAV-N indicates asymptomatic volunteer with bilateral normal temporomandibular joints; SN, symptomatic TMD patient with bilateral normal joints.

DISCUSSION

In an attempt to formulate an operational definition for TMD, Dibbets et al³ discriminated between subjective symptoms of the patient, objective symptoms (signs), and radiographic findings. His study involved 67 orthodontically treated children followed for a period of 15 years after the initiation of the orthodontic treatment. He concluded that only weak predictions of symptoms could be made from earlier signs and symptoms. Furthermore, pain occurring in the young adult occurred rather independent of other

TABLE 5. Vertical Relationships*

Measurements	AV-N ^a		SN	
	Mean	SD	Mean	SD
MP to FH	24.36	4.91	24.91	5.59
S-Gn to FH	58.02	2.92	58.39	3.77
Na-ANS (UFH)	53.80	3.06	52.84	3.08
ANS-Me (LFH)	65.99	4.83	67.00	5.29
Na-Me (TFH)	119.8	5.49	119.8	6.15
UFH: TFH	44.94	2.37	44.14	2.43
SE-PNS	49.20	3.15	48.45	3.79
Ar-Go	47.86	5.11	47.96	4.51
U6 perp PP	23.45	1.93	24.27	2.32
U1 perp PP	29.23	2.71	29.51	2.86
L6 perp MP	32.37	2.40	32.95	2.96
L1 perp MP	41.97	2.49	42.58	3.92
PP to OP	6.65	3.80	4.47	4.45
PP to MP	25.86	4.99	26.56	5.13
PP to FH	-1.09	3.54	-1.70	2.97
Ar-Go-Gn	126.5	5.55	127.3	4.98
Anti-gonial notch	171.7	7.58	171.5	9.25

* *P* values equal to or less than .05 were considered significant.

^a AV-N indicates asymptomatic volunteer with bilateral normal temporomandibular joints; SN, symptomatic TMD patient with bilateral normal joints.

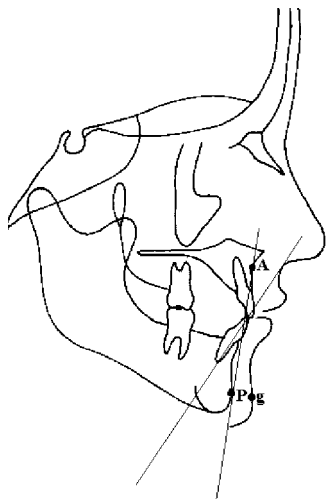


FIGURE 2. Significant measurements of the denture pattern (L1 to A-Pog).

complaints or objective signs of problems in the TMJ region.

The results of this study showed that there were no differences in the skeletal, denture base, and dental characteristics when AV individuals are compared with SN. Both groups exhibited normal disk position. Studies have shown that DD can affect skeletal symmetry. Nebbe et al²² have suggested that adolescent female patients presenting for orthodontic treatment with bilateral DD show numerous angular and linear cephalometric differences compared with aged-matched female controls, including increased mandibular and palatal planes relative to sella-nasion, posterior rotation of the mandible, a decrease in Rickett's facial axis,

reduced posterior facial height, and ramal height as well as a slight increase in middle anterior facial height and a decreased posterior cranial base height. Another study²³ investigated the amount of craniofacial asymmetry in female orthodontic patients with unilateral or bilateral TMJ DD compared with normal controls without DD using postero-anterior films. Females with bilateral DD had significantly greater asymmetry in the vertical position of the antegonion. If the DD was more advanced on one side, then the ipsilateral ramus was shorter, resulting in significant asymmetry of the mandible. The authors concluded that a female patient with unilateral or bilateral DD might present with or develop a vertical mandibular deficiency.

The results of this study suggest that pain in the TMJ can be present without any radiographic evidence (MRI) of DD. This agrees with Paesani et al²⁰ who studied 115 patients with signs and symptoms of craniomandibular disorders. Of those, 78% had different stages of unilateral or bilateral DD, but 22% had bilaterally normal TMJs. They also concluded that the structural difference between painful and nonpainful DD as seen in imaging studies is not yet clear. Another study suggested that patient complaints are not related to the degree of pathology.²¹ The authors suggested that TMD is a chronic pain condition that shares many features with other common chronic pain conditions. Most chronic pain patients seem to bear their condition adequately and thus maintain adaptive levels of psychosocial function. By contrast, a psychosocially dysfunctional segment of the chronic pain population appears unable to cope as well and demonstrate higher rates of depression, somatization, and health care use, even though persons in this segment are not different from their functional peers on the basis of observable organic pathology. Therefore, the only discriminative criterion between the two study groups, AV and SN, is pain. This agrees with the results in the present study because there were no dental or skeletal changes in the lateral cephalograms when the AV and the SN subjects were compared.

On the other hand, a high prevalence of internal derangement in asymptomatic volunteers has been suggested. Thus, presence of DD does not guarantee presence of symptoms. There is also a statistically significant higher prevalence of DD in symptomatic subjects. Westesson et al⁶ found 15% of their asymptomatic volunteers to have unilateral DD using unilateral TMJ arthrography. Tallents et al⁷ in a study of evaluation of TMJ sounds in asymptomatic volunteers found that 24% of them had one or two abnormal joints (DD) as diagnosed by MRI. Ribeiro et al⁸ found the prevalence of DD in asymptomatic children and young adults to be 34%. They suggested that 13.8% had bilateral symptomatic, normal joints, 28% had unilateral DD, and 58% had bilateral DD. They also suggested that DD is relatively common in asymptomatic volunteers and is highly associated with patients presenting with TMD (86%).

Another investigation compared the prevalence of DD in

76 asymptomatic volunteers and 102 symptomatic subjects using MRI. This study showed a high prevalence (33%) of internal derangement in asymptomatic volunteers and also a statistically significant higher prevalence (77%) in symptomatic subjects. The same conclusions can be drawn from other studies. Tallents et al¹⁰ compared MRI findings in 82 asymptomatic volunteers and 263 symptomatic patients. DD was observed in 33% of the asymptomatic volunteers and 84% of the symptomatic patients. Similar results (32%) in asymptomatic volunteers were found by Kircos et al.¹¹

The interesting finding of high prevalence of DD in asymptomatic volunteers is not unique to the TMJ. Magnetic resonance imaging studies of asymptomatic subjects in the knee, cervical spine, and lumbar spine indicate similar disease prevalences in asymptomatic subjects in these body parts as well.¹²⁻¹⁷ Brunner et al¹⁸ showed that half the number of asymptomatic athletes included in the study had significant baseline knee MRI scan abnormalities.

The absence of significant differences between the two groups studied should not come as a surprise. Neither of the subjects presented with DD that could potentially affect the craniofacial morphology. Pain can also be present with no obvious pathology in the TMJ region. The clinician should be aware of the prevalence of DD in asymptomatic subjects and also of the possibility of pain symptoms in patients with otherwise normal anatomy.

CONCLUSIONS

This study supports the contention that there are no significant morphologic changes as seen from the lateral cephalograms when asymptomatic normal volunteers and symptomatic normal subjects are compared.

REFERENCES

- Okeson JP. Orofacial pain: guidelines for assessment, diagnosis and management. *Quintessence Publishing Co.* 1996:116.
- Bell WE. TMD. Classification, diagnosis management, 3rd ed. Chicago: Year Book, 1990: 166-176, Griffiths RH. Report of the President's Conference on examination, diagnosis and management of TMD. *J Am Dent Assoc.* 1983;106:75-77.
- Dibbets JHM, Van Der Weele LTH. Prevalence of TMJ symptoms and x-ray findings. *Eur J Orthod.* 1989;11:31-36.
- Oberg T, Carlsson GE, Fajers CM. The temporomandibular joint: a morphometric study on a human autopsy material. *Acta Odontol Scand.* 1971;29:349.
- Solberg WK, Hansson TL, Nordstrom B. The temporomandibular joint in young adults at autopsy: a morphologic classification and evaluation. *J Oral Rehabil.* 1985;12:303-332.
- Westesson PL, Eriksson L, Kurita K. Reliability of a negative clinical temporomandibular joint examination: prevalence of disk displacement in asymptomatic temporomandibular joint. *Oral Surg Oral Med Oral Pathol.* 1989;68:551-554.
- Tallents RH, Hatala M, Katzberg RW, Westesson PL. Temporomandibular joint sounds in asymptomatic volunteers. *J Prosthet Dent.* 1993;69:298-304.
- Ribeiro RF, Tallents RH, Katzberg RW, Murphy WC, Moss ME, Magalhaes AC, Tavano O. The prevalence of disk displacement in symptomatic and asymptomatic volunteers aged 6 to 25 years. *J Orofacial Pain.* 1997;11(1):37-46.
- Katzberg RW, Westesson PL, Tallents RH, Drake CM. Orthodontics and temporomandibular joint internal derangement. *Am J Orthod Dentofacial Orthop.* 1996;109:515-520.
- Tallents RH, Katzberg RW, Murphy W, Proskin H. Magnetic resonance imaging findings in asymptomatic volunteers and symptomatic patients with temporomandibular disorders. *J Prosthet Dent.* 1996;75:529-533.
- Kircos LT, Ortendahl DA, Mark A, Arakawa M. Magnetic resonance imaging of the TMJ disk in asymptomatic volunteers. *J Oral Maxillofac Surg.* 1987;45:852-854.
- Nagendak WG, Fernandez FR, Halburn LK, Teitge RA. Magnetic resonance imaging of meniscal degeneration in asymptomatic knees. *J Orthop Res.* 1990;8:311-312.
- Kornick J, Trefelner ME, McCarty S, Lang R, Lynch K, Jokl P. Meniscal abnormalities in the asymptomatic population in MR imaging. *Radiology.* 1990;177:463-465.
- Boden SD, Davis DO, Dina TS, Staller DW, Brown SD, Vailas JC, Labropoulos PA. A prospective and blinded investigation of magnetic resonance imaging of the knee: abnormal findings in asymptomatic subjects. *Clin Orthop.* 1992;282:177-185.
- Shellock FG, Morris E, Deutsch AL, Mink JH, Kerr R, Boden SD. Hematopoietic marrow hyperplasia: high prevalence on MR images of the knee in asymptomatic marathon runners. *Am J Roentgenol.* 1992;158:335-338.
- Boden SD, McCowin PR, Davis DO, Dina TS, Mark AS, Wiesel S. Abnormal magnetic resonance scans of the cervical spine in asymptomatic subjects. *J Bone Joint Surg (Am).* 1990;72:1174-1184.
- Boden SD, Davis DO, Dina TS, Patronas NJ, Wiesel SW. Abnormal magnetic resonance scans of the lumbar spine in asymptomatic subjects: a prospective investigation. *J Bone Joint Surg (Am).* 1990;72:403-408.
- Brunner MC, Flower SP, Evancho AM, Allman FL, Apple DF, Fajman WA. MRI of the athletic knee. Findings in asymptomatic professional basketball and collegiate football players. *Invest Radiol.* 1989;24:72-75.
- Brand JW, Nielson KJ, Tallents RH, Nanda RS, Currier GFC, Owen WL. Lateral cephalometric analysis of skeletal patterns in patients with and without internal derangement of the temporomandibular joint. *Am J Orthod Dentofacial Orthop.* 1995;107:121-128.
- Paesani D, Westesson PL, Hatala M, Tallents RH, Kurita K. Prevalence of temporomandibular joint internal derangement in patients with craniomandibular disorders. *Am J Orthod Dentofacial Orthop.* 1992;101:41-47.
- Dworkin SF, Massoth, DL. Temporomandibular joint disorders and chronic pain. Disease or illness. *J Prosthet Dent.* 1994;72:29-38.
- Nebbe B, Major PW, Prasad NGN. Adolescent female craniofacial morphology associated with advanced bilateral TMJ disk displacement. *Eur J Orthod.* 1998;20:701-712.
- Trpkova B, Major P, Nebbe B, Prasad NGN. Craniofacial asymmetry and temporomandibular internal derangement in female adolescents: a posteroanterior cephalometric study. *Angle Orthod.* 2000;70(1):81-88.