

Long-term Results of Orthodontic Treatment of Impacted Maxillary Canines

Rozmary Mak D'Amico, DDS^a; Krister Bjerklin, DDS, PhD^b; Jüri Kuroi, DDS, PhD^c; Babak Falahat, DDS^d

Abstract: A total of 61 children who had 83 maxillary canines impacted were followed up for a mean of 3.5 years (range 1.1–10.9 years) after treatment to evaluate the long-term results of the treatments. In most of the children, the impacted maxillary canines had been surgically exposed and treated with fixed orthodontic appliances. In 11 cases, lateral incisors had been extracted because of extensive root resorption. The esthetic results as well as functional and periodontal conditions were evaluated. Only four of the 61 children were not satisfied with the esthetic result, whereas orthodontists judged only 56% of the results as esthetically acceptable on clinical evaluation and 57% as esthetically acceptable on color slides. The periodontal conditions and the occlusal function on sides with previously impacted canines and on sides with normally erupted canines, on the whole, were similar. Exceptions were pocket depths of the left lateral incisors and left canines, but these variables were significantly different mainly because of one patient. In lateral movements of the mandible, however, significant differences in contact pattern were found between sides with normally erupted canines and sides with impacted canines. Canine rise occurred more often on working sides with normally erupted canines than with impacted canines. (*Angle Orthod* 2003;73:231–238.)

Key Words: Canine; Canine retention; Maxillary retention; Orthodontic surgery; Esthetic

INTRODUCTION

The prevalence of impacted maxillary canines is 0.9–2.2%^{1–6} and, in most cases, the impacted canines are ectopically positioned. Eighty-five percent are palatal to the dental arch.^{7–9} However, in a recent study on 156 ectopically positioned canines, 50% were in a palatal or distopalatal position, 39% in a buccal or distobuccal position, and 11% apical to the adjacent incisor or between the roots of the central and lateral incisors.¹⁰ Different etiological factors in impacted maxillary canines like ectopic position of the tooth-germ, lack of space, lack of guidance, or genetic factors are mentioned in the literature.^{8,11,12}

In cases of impacted maxillary canines, resorption of the central or lateral incisor roots can be expected to be present

in almost 50% of the cases and to be three times as common in girls as in boys.^{10,13,14} Computed tomographic scanning is superior to other radiographic methods to examine bone destruction as well as resorption or small lesions on tooth roots.^{5,6,9,10,13,14} About 50% more resorptions are detected with computerized tomography (CT) compared with conventional radiographic methods that provide intraoral and panoramic radiographs.^{9,10,13} CT scanning is also valuable in determining the exact position of malposed maxillary canines.¹⁰

Ericson and Kuroi¹⁰ reported the use of a Siemens Somatome Plus CT-scanner (Siemens AG, Germany) for tomographs. Contiguous transverse CT scans with a slice thickness of two mm were exposed through the alveolar bone of the maxilla perpendicular to the long axis of the lateral maxillary incisors. Usually, 6–10 scans were obtained from the cervical region to the apex. Six images on the film were used. For a detailed description of the tomographic procedure and the accuracy of CT in imaging root resorptions on maxillary incisors, see Ericson and Kuroi.¹⁰

Orthodontic treatment after surgical exposure of the impacted canine is an often recommended treatment strategy.^{12,15,16} Several methods of surgical exposure have been presented.^{12,16} Another way to bring the canine into the correct position in the dental arch is autotransplantation.^{17–19}

Orthodontic movement or autotransplantation of canines

^a Department of Orthodontics, Institute for Postgraduate Dental Education, Jönköping, Sweden, and private practice in Bolzano, Italy.

^b Department of Orthodontics, Institute for Postgraduate Dental Education, Jönköping, Sweden.

^c Department of Orthodontics, Faculty of Odontology, Malmö University, Malmö, Sweden.

^d Department of Oral and Maxillofacial Radiology, Institute for Postgraduate Dental Education, Jönköping, Sweden.

Corresponding author: Krister Bjerklin, Department of Orthodontics, Institute for Postgraduate Dental Education, Hermansvägen 5, Box 1030, Jönköping, Sweden 55111.

Accepted: August 2002. Submitted: June 2002.

© 2003 by The EH Angle Education and Research Foundation, Inc.

TABLE 1. Distribution of the Children With Retained Maxillary Canines in the Three Groups Concerning Position and Cause of Incisor Resorption by the Retained Canines^a

	Group A— unilateral right	Group B— unilateral left	Group C— bilateral	Total
Buccally displaced				
Incisor resorption	4	4	4 (7)	12 (15)
No incisor resorption	3	1	7 (12)	11 (16)
Palatally displaced				
Incisor resorption	5	11	4 (6)	20 (22)
No incisor resorption	4	6	6 (9)	16 (19)
Central in the arch				
Incisor resorption	0	1	5 (7)	6 (8)
No incisor resorption	0	0	3 (3)	3 (3)
Total number	16	23	29 ^b	68 (83)

^a The figures in parentheses are the number of canines.

^b In seven cases, the two canines were displaced in different positions. The actual number of cases in C is 22 and in the entire study 61.

involves the surrounding tissues such as bone and gingival tissue. Occlusal guidance may also be affected by the shift in canine position. Resorbed incisors that are left in the dental arch may present a risk for long-term survival.

The aim of this study was to evaluate the long-term treatment effects in children treated for impacted maxillary canines, regarding esthetics as judged by both the patient and the orthodontist as well as the periodontal health, occlusal guidance, percussion sound, and vital response. Esthetics were assessed concerning color, tooth shape, and position in the dental arch. The aim was also to investigate whether, in unilateral cases, it was possible to identify which of the maxillary canines had been moved and whether it had originally been impacted in a buccal, central, or palatal position in the dental arch. Cases with and without resorption of the incisors were included.

MATERIALS AND METHODS

Starting subjects

The original material consisted of 107 children diagnosed with 156 impacted maxillary canines. The children had been consecutively chosen from the list of children referred to the orthodontic specialist clinic because of retained maxillary canines. The diagnosis had been established clinically, according to the normal clinical routines⁵ and radiographically, including CT scanning to investigate whether there were root resorptions on neighboring teeth.

Follow-up subjects

A total of 61 children, 23 boys and 38 girls, could be reached for the follow-up examination. They had 83 retained maxillary canines at their initial visit to the clinic at

TABLE 2. Distribution of Extracted Canines, Permanent Lateral Incisors and Surgically Exposed Permanent Canines

	Group A— unilateral right (n)	Group B— unilateral left (n)	Group C— bilateral (n)	Total
Extracted canines				
Right side	2	—	—	2
Left side	—	5	1	6
Extracted lateral incisors				
Right side	4	—	6	10
Left side	—	1	5	6
Extracted primary canines				
Right side	4	—	5	9
Left side	—	6	7	13
Surgically exposed canines				
Right side	8	—	8	16
Left side	—	10	7	17
Transplanted canines	—	1	4	5

the mean age of 12.8 years (SD 2.5). Thirty-one canines were buccally displaced, 41 palatally displaced, and 11 central in the dental arch (Table 1). The 39 normally erupted canines served as controls.

Resorption of the incisor roots could be seen in 35 of the 61 children, 12 boys and 23 girls. Forty-five canines could be related to resorption of nine central incisors and 40 lateral incisors.

Fifteen (48%) of the 31 buccally displaced canines were associated with resorption on incisors. Twenty-two (54%) of the 41 palatally displaced canines and eight (73%) of the 11 canines retained central in the arch had apparently caused incisal resorption of the adjacent incisor. The 61 subjects were divided into three groups (Table 1):

- A. The maxillary right canine had been impacted in an ectopic position and the left canine had erupted normally (16 children: six boys and 10 girls).
- B. The maxillary left canine had been impacted in an ectopic position and the right canine had erupted normally (23 children: seven boys and 16 girls).
- C. Both maxillary canines had been impacted in an ectopic position (22 children: nine boys and 13 girls).

In eight children, treatment consisted in extracting the ectopically positioned canine. Seven of these canines had been palatally displaced and one had been central in the arch. Four right lateral incisors and one left lateral incisor had been extracted in children with unilateral ectopic canines. In six children in group C, six right lateral incisors and five left lateral incisors had been extracted (Table 2). In three children, five canines had been transplanted to the correct position in the dental arch, bilaterally in two children and unilaterally in one (Table 2).

Eighteen children had 22 primary canines extracted. Four of these children needed no further orthodontic treatment.

Thirty-three of canines were surgically exposed (Table 2). Of the 61 children in the study, 52 had undergone orthodontic treatment with fixed appliances, three with removable appliances, and six children had not used any type of orthodontic appliance. The mean age at the start of treatment was 13.1 years (SD 1.70) and at the end of orthodontic treatment was 15.0 years (SD 1.71). Twenty-four of the 52 children treated with fixed appliances also used retention appliances, and the mean age at the end of the retention period was 16.8 years (SD 1.90).

At the follow-up, the patients had a mean age of 18.7 years (SD 4.24). For the treated cases, this was on average 3.5 years after orthodontic treatment was finished.

Methods

At the first visit, the patients had undergone a radiographic examination, including a CT scan, to determine whether there was any resorption of the incisors and, where appropriate, to define the location and the amount of the resorption.

Thirty-three maxillary canines had been surgically exposed and provided with a button and a silver chain extending through the surgical flap, which had been sutured back. An elastic thread had then been attached from the silver chain to the fixed orthodontic appliances. In some cases, premolars had been extracted to create space for the canines. At the follow-up, treatment was documented according to a predetermined protocol.

The canines were esthetically evaluated concerning tooth shape, tooth color, tooth position in the dental arch, and tooth inclination. Tooth shape was recorded as normal cusp or signs of wear more than 1.5 mm². Tooth color was registered as normal or differing, and tooth position was recorded as one of five conditions: normal, intrusion, mesial rotation, distal rotation, and intrusion in combination with mesial rotation. Inclination was registered as normal, lingual, or buccal. The opinions of both the orthodontists and the patients were evaluated. The patients were interviewed, and one of the authors (Dr Mak D'Amico) evaluated the esthetic results.

Furthermore, five orthodontists evaluated the treatment result esthetically from the follow-up color slides to see whether it was possible to distinguish between the normally erupted canine and the previously retained canine in groups A and B. The orthodontists recorded the treatment results as good, acceptable, or not good. Another purpose was to analyze whether it was possible to differentiate between canines that had been retained buccally, palatally, and in the middle of the dental arch. This overall analysis of the esthetic result was made without knowing which of the canines had been impacted. The result was judged as good, acceptable, or not good. Canine tooth position was registered as normal, palatally displaced, buccally displaced, ro-

tated, intruded, or extruded. The inclination of the canines was also evaluated.

The periodontal condition was examined by probing on six surfaces on each of the maxillary incisors and canines—mesiolingual, lingual, distolingual, distobuccal, buccal, and mesiobuccal—and on two surfaces on the adjacent premolar—mesiolingual and mesiobuccal. A pocket probe with mm marks Pcp15 (Hu-Friedy, Chicago, Ill) was used. The level of the attached gingiva was recorded buccally, mesiobuccally, and distobuccally on the canines—mesiobuccally on the first premolars and distobuccally on the lateral incisors. Presence of plaque and bleeding on probing were recorded according to Ainamo and Bay.²⁰ A maximum of four surfaces was recorded for each tooth.

Occlusal contacts in lateral excursions were evaluated by clinical examination of the mandibular movements. Occlusal contacts and interferences on the nonworking and working sides were registered during lateral excursions up to three mm. The contacts were registered using a thin (8 μ) plastic foil folded double (16 μ G-HM®, Hanel Dental GmbH, Germany). The subjects also answered a questionnaire on TMD symptoms and headaches. Headache more than twice a week was registered as frequent headache.

A percussion test was made on each tooth from the maxillary right premolar to the maxillary left premolar to record whether the sounds were normal or had signs of being ankylotic.

A vitality test with an Analytic technology model 2006 vitality scanner (Redmond, Wash., USA) was performed from the maxillary right canine to the maxillary left canine to test whether vitality response was normal.

Statistical methods

Statistical analyses were made to compare the three groups. An analysis of variance was used for the continuous variables and Pearson's chi-squared test for the categorized variables. The intraclass correlation coefficient (ICC) was used to test the methods.²¹

Method error study

The errors of measurements were estimated by duplicate determination of all measurements in 10 cases. The ICC found good agreement between the two measurements with coefficients between 0.63 and 0.96. The variables with the weakest ICCs were pocket depths for tooth 12 distobuccally, tooth 12 mesiopalatally, tooth 12 lingually, and tooth 11 distopalatally with ICCs between 0.63 and 0.67. For all the other variables, the coefficients were above 0.70.

RESULTS

Esthetic results

Only four patients were dissatisfied with the esthetic results of the treated maxillary canines. The clinical evalua-

TABLE 3. Maxillary Canine Position

	Unilaterally retained canines (%)	Bilaterally retained canines (%)	Normally erupted canines (%)
Normal position	44	52	53
Intrusion	13	6	3
Mesial rotation	39	36	30
Distal rotation	0	3	10
Intrusion and mesial rotation	4	3	3

TABLE 4. Maxillary Canine Inclination

Inclination	Unilaterally retained canines (%)	Bilaterally retained canines (%)	Normally erupted canines (%)
Normal	57	55	80
Lingual	13	0	0
Buccal	30	45	20

tion by the orthodontist rated the esthetic result as good in 57% of the patients, acceptable in 26%, and not good in 17%. There were no differences among the three groups.

The five orthodontists who evaluated color slides found treatment results to be good in 56%, acceptable in 36%, and not good in 8% of the previously retained canines.

When the five orthodontists were asked to decide whether the right or the left canine had been impacted in groups A and B, they correctly identified 35%, incorrectly identified 35%, and were undecided about 30% of the right maxillary canines. The corresponding figures for the left maxillary canines were 55%, 18%, and 27%.

These five orthodontists identified 48% of the treated canines that had been impacted buccally, 61% of the palatally displaced canines, and 9% of the canines that had been impacted centrally in the alveolar process. Thus, in groups A and B—the unilateral canine impaction cases—45% of the orthodontically treated sides could be identified by the five orthodontists at the follow-up 3.5 years after treatment had been completed.

Canines

The shapes of the cusp tips of 70% of the normally erupted and 68% of the previously impacted canines in groups A and B and 67% of the bilaterally positioned ectopic canines in group C were normal. The cusp tips of 30%, 32%, and 33%, respectively, of the canines showed signs of wear. There were no significant differences between the groups.

The color of 74% of the normally erupted canines in groups A and B was normal and abnormal in 26%. The corresponding figures for the unilaterally impacted canines in the same groups were 66% and 34%. In group C, the color of 50% of the bilaterally impacted canines was normal and of 50% abnormal. No significant differences between the groups could be seen.

TABLE 5. Pocket Depth on Maxillary Left Side and Probability of the Difference Between the Groups^a

Tooth surface	Group A		Group B		Group C		Significance
	Mean	SD	Mean	SD	Mean	SD	
23 ml	1.5	0.50	1.9	0.76	1.6	0.56	ns
23 l	1.2	0.37	1.3	0.43	1.5	0.54	ns
23 dl	1.5	0.65	1.6	1.12	1.3	0.46	ns
23 db	1.7	0.49	2.3	0.78	1.8	0.64	*
23 b	1.2	0.36	1.5	0.66	1.3	0.58	ns
23 mb	2.0	0.63	2.6	0.86	2.2	0.84	ns
22 ml	1.3	0.45	2.0	1.17	1.4	0.49	*
22 l	1.3	0.45	1.8	0.77	1.2	0.36	**
22 dl	1.2	0.40	2.0	1.06	1.7	0.46	*
22 db	1.8	0.39	2.0	0.77	1.9	0.59	ns
22 b	1.1	0.29	1.2	0.48	1.5	0.51	ns
22 mb	1.9	0.43	2.1	0.54	1.9	0.54	*
21 ml	1.5	0.50	2.0	0.85	1.7	0.45	ns
21 l	1.2	0.42	1.6	0.60	1.4	0.47	ns
21 dl	1.3	0.49	1.5	0.59	1.6	0.50	*
21 db	1.4	0.50	2.0	0.69	1.7	0.53	ns
21 b	1.3	0.46	1.6	0.59	1.4	0.50	ns
21 mb	1.8	0.56	2.2	1.10	1.9	0.85	ns

^a ml indicates mesiolingual; l, lingual; dl, distolingual; db, distobuccal; b, buccal; mb, mesiobuccal.

* $P \geq .05$; ns, not significant.

The position of 44% of the unilaterally impacted canines and 50% of the normally erupted canines in groups A and B was normal. In group C, the position of 52% of the previously impacted canines was normal. No significant differences between the groups were detected (Table 3).

The inclination of 57% of the previously impacted canines in groups A and B and 55% in group C was normal. The inclination of 80% of the normally erupted canines in groups A and B was normal (Table 4). The difference between the normally erupted canines in groups A and B and the previously impacted canines in groups A, B, and C was significant at the 5% level.

Periodontal conditions and sensibility

The evaluation of the periodontal conditions revealed no differences between the sides with normally erupted canines and the sides with impacted and treated canines in plaque index, gingival index, or in the width of the attached gingiva.

There, however, was a difference in pocket depth. On the right side there were no significant differences between the three groups, whereas the pocket depth on the left side was significantly (at the 5% level) deeper at the distobuccal surface of the impacted canines and at the mesiolingual, distolingual, and mesiobuccal surfaces of the left lateral incisors. Pocket depth was significantly (at the 1% level) deeper at the lingual surface of the left lateral incisors, as was the pocket depth at the distolingual surface of the left central incisors (Table 5).

A percussion test revealed that one right canine in group

TABLE 6. Occlusal Contact on the Working Side

	Group A—unilateral right (%)		Group B—unilateral left (%)		Group C—bilateral (%)	
	Right Side Ectopic	Left Side Normal	Right Side Normal	Left Side Ectopic	Right Side Ectopic	Left Side Ectopic
Cuspid protection	46	62	74	47	42	50
Group contact	54	38	16	53	58	39
No occlusal contact	0	0	10	0	0	11

TABLE 7. Contact Between the Jaws on the Working Side

	Working Side		
	Normally Erupted Canines— Unilateral (%)	Retained Canines	
		Unilateral (%)	Bilateral (%)
Cuspid protection	69	47	46
Group contact	25	53	49
No occlusal contact	6	0	5

C and three left canines in groups A and B had ankylotic sounds. None of these had been transplanted. One right lateral and one central incisors—in the same patient, group A—also gave an ankylotic sound. Only one left central incisor, in group C, gave an ankylotic sound.

The vital response of two canines on each side was reduced on electric stimulation. These four teeth belonged to group C and had been transplanted. One left and one right central incisor, also in group C, showed lowered vital response.

Headache

Eight patients reported frequent headache, one in group A, four in group B, and three in group C. No significant difference between the three groups was found.

Occlusion

During mandibular lateral excursions up to three mm to the right, there were significant differences between the groups at the 5% level. Canine protection was observed in 46% of the unilaterally impacted canines, in 42% of the bilaterally impacted canines, and in 74% of the normally erupted canines in group B. Fifty-four percent of group A, 58% of group C, and 16% of group B had group contacts (Table 6). When the mandible was moved up to three mm to the left, no significant differences in occlusal contacts were found between the groups.

In group A, 38% of the normally erupted canines had group contact and 62% had canine protection. Corresponding figures for the previously impacted canines in group B were 53% and 47% and in group C 39% and 50%. Eleven percent in group C had no contact (Table 6).

When the normally erupted canines in groups A and B were placed in one group, the previously impacted canines

TABLE 8. Contact Between the Jaws on the Nonworking Side

	Normally Erupted Canines— Unilateral (%)	Retained Canines	
		Unilateral (%)	Bilateral (%)
Occlusal contact	22	36	43
No occlusal contact	78	64	57

in groups A and B in another group, and group C in a third group, it was found that canine protection occurred more often on the working side in the first group (69%) compared with the second (47%) and the third (46%) groups (Table 7).

No significant differences were found on the nonworking side between the original groups (A, B, C) when the mandible was moved to the right or the left. When the mandible was moved to the right, occlusal contact on the nonworking sides was seen in 36% in group A, 26% in group B, and 42% in group C. When the mandible was moved to the left, 37% in group B, 44% in group C, and 15% in group A had occlusal contact on the nonworking sides.

If the normally erupted canines in groups A and B were placed in one group, the previously impacted canines in groups A and B in another group, and group C in a third group, as in Table 7, the first group differs significantly from the second and third groups at the 5% level on the nonworking side. Twenty-two percent of the sides with normal eruption, 36% of the sides with canines that had previously been impacted unilaterally, and 43% of the sides with canines that had previously been impacted bilaterally had occlusal contact on the nonworking side (Table 8).

DISCUSSION

Surgical exposure of the impacted canines and the use of fixed orthodontic appliances is the most frequently used treatment. In cases with severe root resorption on lateral incisors and a good position of the retained canines, extraction of the lateral incisor was performed (11 cases, Table 2). For different reasons, canines were removed in eight children. One of the main reasons for extraction of the canine was when there was a relatively small or no resorption on the lateral incisor and a bad position of the canine for extraction of the lateral incisor (Figure 1).

Eighteen children had had 22 primary canines extracted. Four of these children needed no further orthodontic treat-

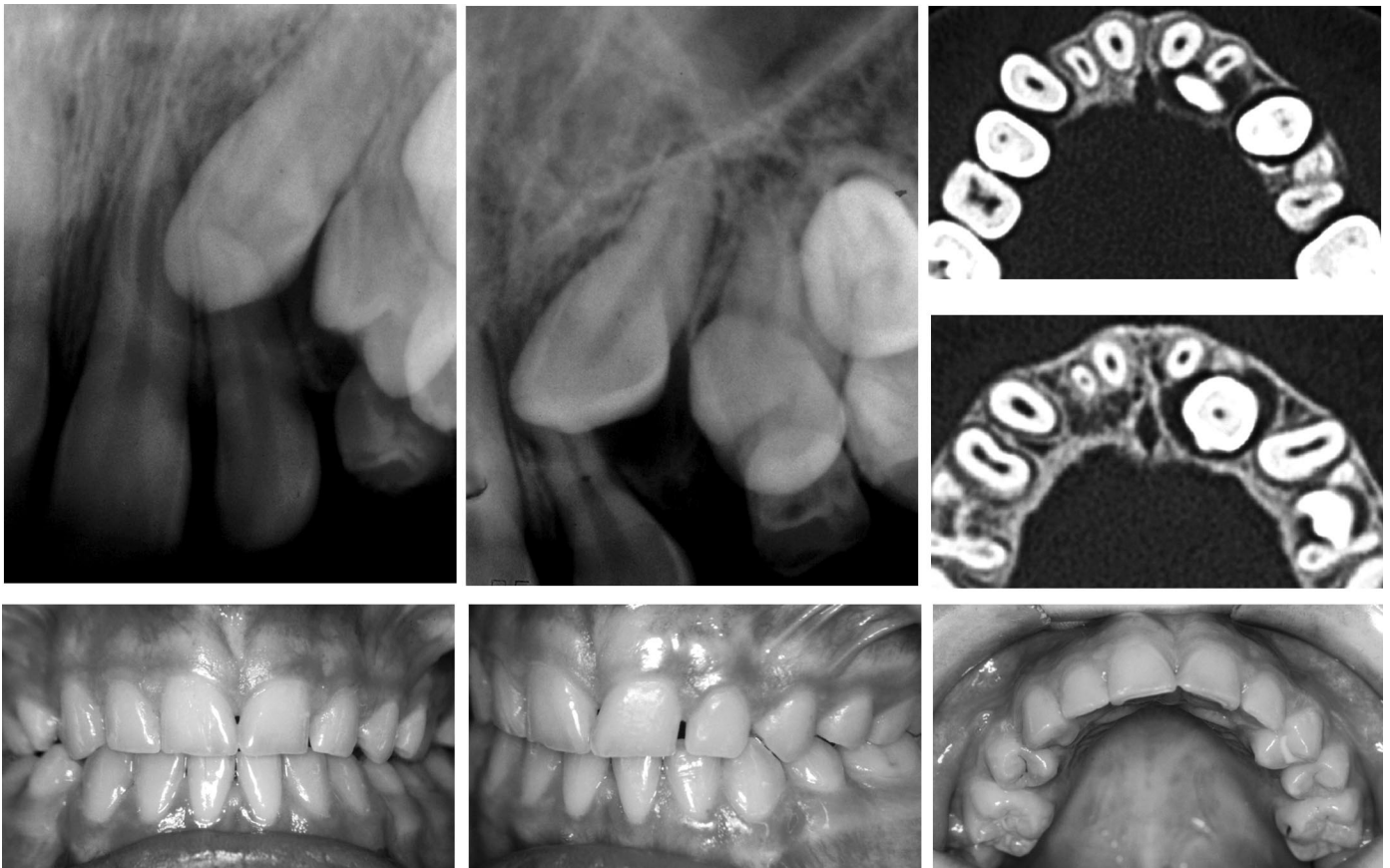


FIGURE 1. Patient with left maxillary canine retained palatal to the left lateral incisor and with a slight resorption on the lateral incisor. The inclination and position of the canine was not favorable for extraction of the lateral incisor or the first premolar (top). The canine was removed, and the situation 6 years after treatment (bottom).

ment. This represents a very small number when compared with the work of Ericson and Kurol,²² where they found almost 80% of spontaneous eruption of the formerly impacted canines. In that study, however, all canines were palatally displaced, but in this study most of the canines, where the primary canines had been extracted, were buccally displaced or central in the dental arch.

Most of the orthodontically and surgically treated canines were judged to be esthetically satisfactory. Four patients, however, were dissatisfied with the esthetic results. These were patients where lateral incisors had been extracted, and their canines were in contact with the central incisors. The patients were dissatisfied with the color of the canines. Four of the 11 patients (36%) with lateral incisors extracted were dissatisfied with the esthetic results. This is in accordance with the findings of Robertson and Mohlin²³, who found that 55% were dissatisfied and 45% satisfied with the color of the canines used to replace the lateral incisors.

No patient was disappointed with the shape, alignment, or inclination of the canines. Those cases where the orthodontist judged the result to be unacceptable, primarily concerned canines in the lateral incisor position where the

shape and color were not satisfactory. In a few cases, orthodontic treatment was judged to be incomplete.

The five orthodontists were able to identify 48% of the originally buccally impacted canines and 61% of the originally palatally impacted canines. Palatally displaced canines seem to be easier to identify (Figure 2). In only 35% of the cases in group A was it possible to state whether the right or the left canine had been impacted. This indicates a good treatment result. The difference between the right and the left sides in groups A and B can be explained by more palatally displaced canines on the left side, which were easier to identify.

Reduced vital response and ankylosis after orthodontic treatments of impacted maxillary canines were not judged to be complications because only four teeth each had these complications. All the teeth with reduced vital response had been transplanted, whereas none of the teeth with ankylotic sounds had been transplanted.

Periodontal conditions were almost always good. However, the pockets at six sites around the impacted canines in group B were significantly deeper than those at the same sites around the normally erupted canines in groups A and

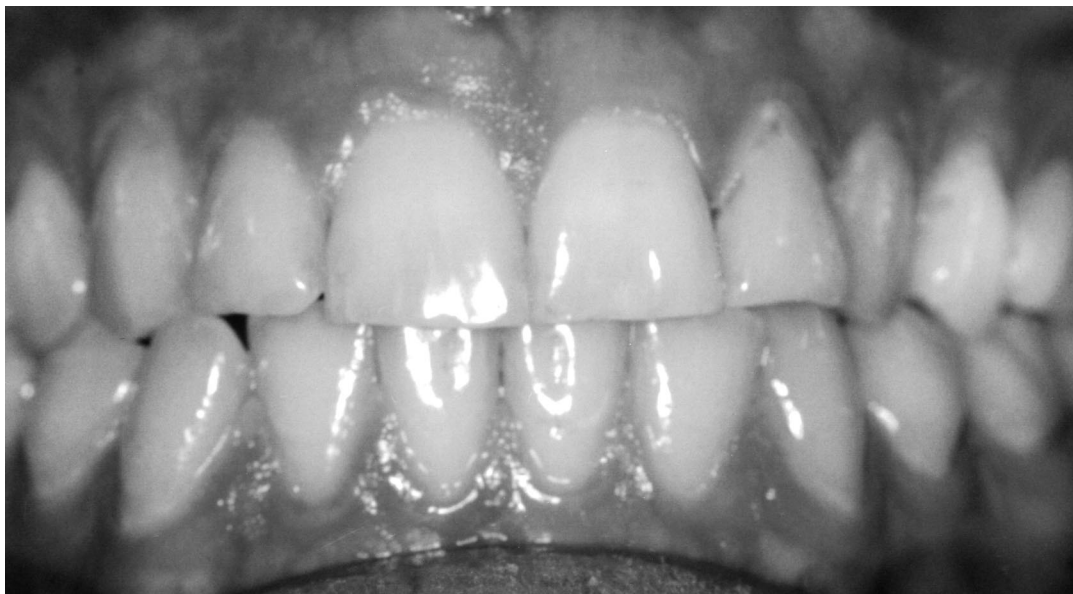

FIGURE 2. The maxillary canines have been palatally retained and are, five years after treatment, easy to identify as previously palatally retained canines.

B and the impacted canines in groups A and C. Three teeth (nos. 21, 22, 23) in group B were involved, and one patient caused this significant difference between the groups. In the other patients, the periodontal variables had normal values.

Canine protection occurred more often on sides with normally erupted canines than on sides with previously impacted canines (Table 7), perhaps because the impacted canines often had a more buccal or palatal inclination compared with the normally erupted canines (Table 4). Barwart et al,²⁴ however, found that the function in canines that had previously been palatally impacted was almost identical to that in spontaneously erupted canines.

A significant difference in canine protection was observed between the groups with normally and ectopically erupted canines when the mandible was moved to the right but not when the mandible was moved to the left. When the mandible was moved to the left, the frequency of canine protection for the normally erupted canine was lower and more similar to the ectopically erupted canine (Table 6). We have no explanation for this.

Our results on canine protection and group contacts on the working side during lateral movements were similar to those of Barwart et al.²⁴ It seems to be more difficult to attain a normal inclination in buccally impacted canines because 45% of the impacted canines in group C and 30% in groups A and B were buccally inclined. Twenty percent of the normally erupted canines were buccally inclined (Table 4). The eight subjects who stated that they had frequent headache also reported tenderness of masticatory muscles and in the temporomandibular joint area. Signs and symptoms of temporomandibular disorders are frequent in young individuals.²⁵ However, no correlation could be seen between patients who had no canine rise in lateral excursion

and frequent headache. This was also found by Ingervall and Mohlin²⁶ and Mohlin.²⁷

CONCLUSIONS

This study followed up 61 children who had undergone treatment for impaction of one or both maxillary canines. Thirty-five of these children also had resorption of the adjacent incisor. The follow-up took place on average 3.5 years after the completion of surgical and orthodontic treatment.

Four of the 61 children (6.5%) were dissatisfied with the esthetic result, whereas the orthodontist who clinically evaluated the children found a good result in 57% of the cases. When five orthodontists evaluated color slides of the patients, these specialists judged 56% to have a good esthetic result. These five orthodontists were able to identify only 48% of the maxillary canines that had been previously impacted unilaterally.

Shape, color, or position of the previously impacted canines did not differ from that of normally erupted canines. The inclination of the previously impacted canines, however, was significantly different from that of the normally erupted canines, leading to a less frequent canine guidance on the working side during lateral movements of the mandible.

ACKNOWLEDGMENT

We wish to express our thanks to Birgit Ljunqvist, PhD, for statistical advice.

REFERENCES

1. Dachi SF, Howell FV. A survey of 3874 routine full mouth radiographs. II. A study of impacted teeth. *Oral Surg Oral Med Oral Pathol.* 1961;14:1165-1169.

2. Thilander B, Jakobsson SO. Local factors in impaction of maxillary canines. *Acta Odontol Scand.* 1968;26:145–168.
3. Kramer RM, Williams AC. The incidence of impacted teeth. A survey at Harlem Hospital. *Oral Surg.* 1970;29:237–241.
4. Thilander B, Myrberg N. The prevalence of malocclusion in Swedish schoolchildren. *Scand J Dent Res.* 1973;81:12–20.
5. Ericson S, Kurol J. Longitudinal study and analysis of clinical supervision of maxillary canine eruption. *Community Dent Oral Epidemiol.* 1986a;14:172–176.
6. Ericson S, Kurol J. Radiographic assessment of maxillary canine eruption in children with clinical signs of eruption disturbance. *Eur J Orthod.* 1986b;8:133–140.
7. Rayne J. The unerupted maxillary canine. *Dent Pract.* 1969;19:194–204.
8. Jacoby H. The etiology of maxillary canine impactions. *Am J Orthod.* 1983;84:125–132.
9. Ericson S, Kurol J. Radiographic examination of ectopically erupting maxillary canines. *Am J Orthod Dentofacial Orthop.* 1987;91:483–492.
10. Ericson S, Kurol J. Resorption of incisors after ectopic eruption of maxillary canines. A CT study. *Angle Orthod.* 2000;70:415–423.
11. Becker A. Palatally impacted canines. In: Becker A, ed. *The Orthodontic Treatment of Impacted Teeth.* London: Martin Dunitz Ltd; 1998: chap 6 p 86.
12. Kurol J, Ericson S, Andreassen JO. The impacted maxillary canine. In: Andreassen JO, Petersson JK, Laskin DM, eds. *Textbook and Color Atlas of Tooth Impactions.* Copenhagen: Munksgaard; 1997: chap 6 pp 129–130.
13. Ericson S, Kurol J. Resorption of permanent incisors due to eruption of maxillary canines. A radiographic study. *Angle Orthod.* 1987;57:332–346.
14. Ericson S, Kurol J. Resorption of maxillary lateral incisors caused by ectopic eruption of the canines. An analysis of predisposing factors. *Am J Orthod Dentofacial Orthop.* 1988;94:503–513.
15. Andreassen GF. A review of the approaches to treatment of impacted maxillary cuspids. *Int J Oral Surg.* 1971;31:479–484.
16. Becker A, Shteyer A, Lustman J. Surgical exposure of impacted teeth. In: Becker A, ed. *The Orthodontic Treatment of Impacted Teeth.* London: Martin Dunitz Ltd; 1998: chap 3 pp 26–35.
17. Andreassen JO. Autotransplantation of canines. In: Andreassen JO, ed. *Atlas of Replantation and Transplantation of Teeth.* Copenhagen: Munksgaard; 1992: chap 6 pp 153–157.
18. Schatz JP, Joho JP. A clinical and radiologic study of autotransplanted impacted canines. *Int J Oral Maxillofac Surg.* 1993;22:342–346.
19. Berglund L, Kurol J, Kvint S. Orthodontic pretreatment for autotransplantation of palatally impacted maxillary canines. Case reports on a new approach. *Eur J Orthod.* 1996;18:449–456.
20. Ainamo J, Bay I. Problems and proposals for recording gingivitis and plaque. *Int Dent J.* 1975;25:229–235.
21. Schemper M. General derivation of intraclass correlation coefficients. *Biom J.* 1983;28:485–489.
22. Ericson S, Kurol J. Early treatment of palatally erupting maxillary canines by extraction of the primary canines. *Eur J Orthod.* 1988;10:283–295.
23. Robertsson S, Mohlin B. The congenitally missing upper lateral incisor. A retrospective study of orthodontic space closure versus restorative treatment. *Eur J Orthod.* 2000;22:697–710.
24. Barwart O, Schamberger D, Richter M, Ulmer H. Zur funktionellen Wertigkeit kieferorthopädisch eingereiteter retinierter Eckzähne. *Fortschr Kieferorthop.* 1994;55:104–110.
25. Henriksson T, Nilner M, Kurol J. Signs of temporomandibular disorders in girls receiving orthodontic treatment. A prospective and longitudinal comparison with untreated Class II malocclusions and normal occlusion subjects. *Eur J Orthod.* 2000;24:271–281.
26. Ingervall B, Mohlin B. Prevalence of symptoms of functional disturbances of the masticatory system in Swedish men. *J Oral Rehabil.* 1980;7:185–197.
27. Mohlin B. Prevalence of mandibular dysfunction and relation between malocclusion and mandibular dysfunction in a group of women in Sweden. *Eur J Orthod.* 1983;4:115–123.