

Palatally Displaced Canine Anomaly in Monozygotic Twins

Rosalia Leonardi, DMD, MSD^a; Sheldon Peck, DDS, MScD^b; Mario Caltabiano, MD, MSD^c; Ersilia Barbato, DMD, MSD^d

Abstract: The palatally displaced canine (PDC) anomaly is a tooth malposition occurring in 1% to 3% of most populations. From the results of family studies, the PDC phenotype appears to be under strong genetic influence. In this study we report monozygotic (MZ) twin girls with bilateral PDC expression. The finding of PDC anomaly in MZ twins—to our knowledge, the first such published case—lends further support to evidence of genetic control of the PDC anomaly. (*Angle Orthod* 2003;73:466–470.)

Key Words: Tooth eruption, ectopic; Canine, impacted; Tooth abnormalities; Twins, monozygotic; Genetics

INTRODUCTION

The maxillary canine tooth shows an unusual predisposition for palatal displacement and impaction. In 1% to 3% of most populations,^{1–4} the canine takes an ectopic developmental pathway palatally and is discovered impacted in the palatal bone or unerupted under the thick palatal mucosa. The palatally displaced canine (PDC) anomaly is found twice as often in females than in males and is approximately five times more prevalent in people of European descent than in Asians.⁵ Although found uncommonly in the general population, PDC is observed frequently in orthodontic samples.

From a growing body of scientific evidence, the PDC anomaly appears to have genetic origins. Mendelian family studies,^{6–10} epidemiological findings,¹¹ and meta-analysis⁵ of earlier reports strongly suggest that PDC is one of a constellation of genetically controlled dental anomalies—like tooth agenesis and tooth-size reduction—often seen occurring in combination and in families. Current research findings suggest that genes associated with hypodontia of posterior teeth—molars and premolars—may be associated with the genesis of PDC.¹²

Thus, expression of PDC in a set of monozygotic (MZ)

twins, although previously unreported in the scientific literature to our knowledge, would be an expected occurrence. Other discrete anomalies of tooth position, such as transposition of maxillary canine—first premolar and transposition of mandibular lateral incisor—canine, have been noted in identical twins.^{13,14} In this study we report MZ twin girls with bilateral PDC anomalies.

CASE REPORT

MZ female twins of 10.7 years of age (ES and DS) were presented for orthodontic treatment at the University of Catania dental clinics in southern Italy. The parents' chief complaint was protrusion of the maxillary and mandibular front teeth. Clinical examination revealed that the prepubertal Caucasian girls were in the late mixed dentition with similar Angle Class I malocclusions. Each had an overjet of 4.0 mm, an overbite of 3.5 mm, and coincident dental and facial midlines (Figure 1a,b). No arch length deficiencies were noted. The permanent teeth measured within the normal range of size, when compared with Caucasian odontometric values, and concordance of tooth size between the twins was discernable (Table 1).

Panoramic dental radiographs showed mesioangular palatal development of both unerupted maxillary permanent canines for each twin (Figure 2a,b). In twin ES a more severe left-side developing PDC phenotype was apparent. In twin DS a more severe right-side developing PDC phenotype was evident. Another notable radiographic feature was marked mesioangular ectopic eruption of the mandibular second molars in the case of each twin, despite the adequacy of arch space.

For both 10.7-year-old girls, interceptive treatment of the developing bilateral PDC condition was attempted according to the recognized method, extraction of the maxillary deciduous canine teeth.^{15–18} The children were then ob-

^a Associate Professor of Orthodontics, University of Catania, Catania, Italy.

^b Associate Clinical Professor of Oral and Developmental Biology (Orthodontics), Harvard School of Dental Medicine, Boston, Mass.

^c Dean of Catania Dental School and Professor of Orthodontics, University of Catania, Catania, Italy.

^d Associate Professor of Orthodontics, University of Rome "La Sapienza," Rome, Italy.

Corresponding author: Sheldon Peck, DDS, 1615 Beacon Street, Newton, MA 02468-1507 (e-mail: peckslam@att.net).

Accepted: November 2002. Submitted: September 2002.

© 2003 by The EH Angle Education and Research Foundation, Inc.

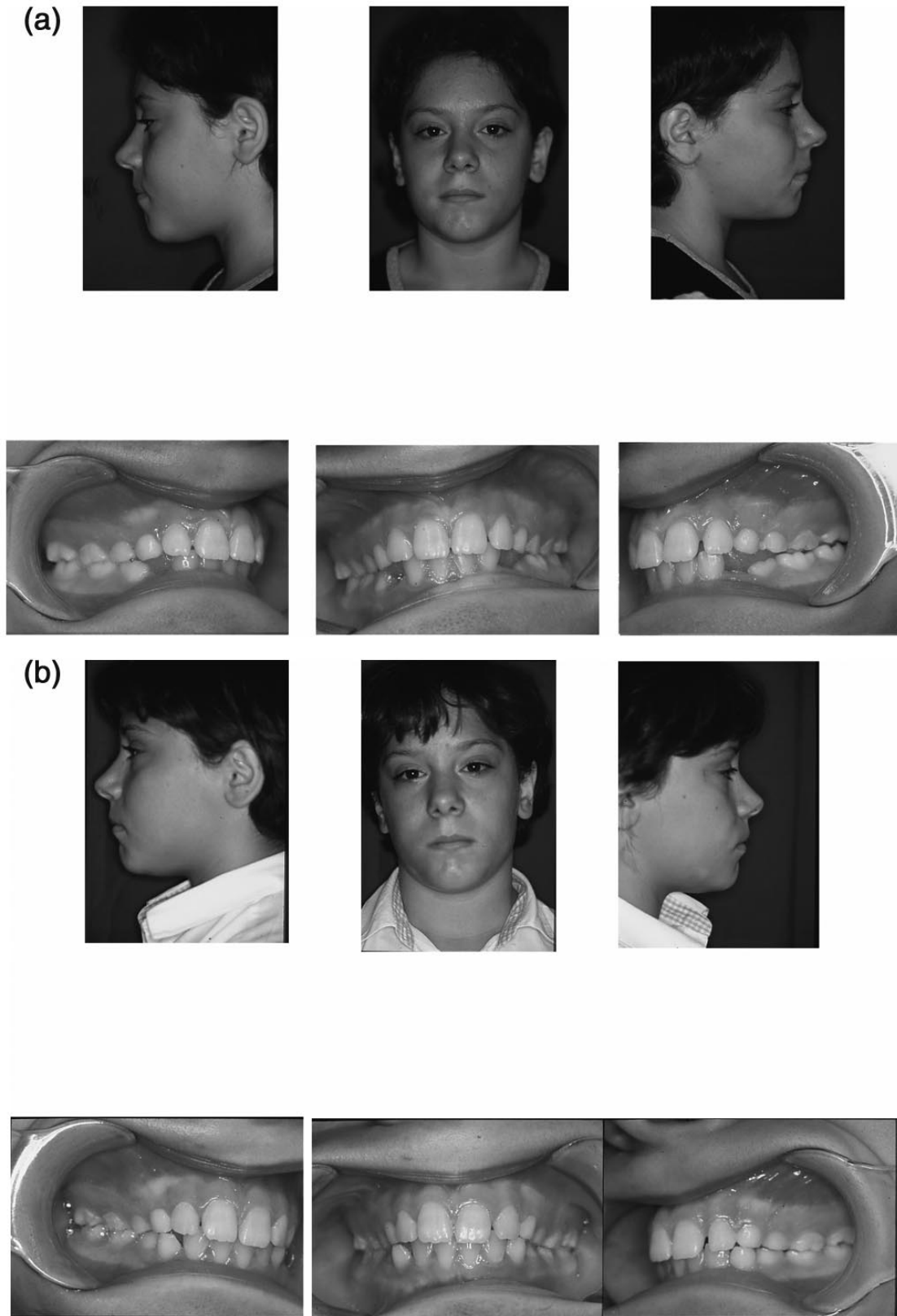


FIGURE 1. (a) MZ twin ES: initial photographs, at age 10.7 years. (b) MZ twin DS: initial photographs, at age 10.7 years.

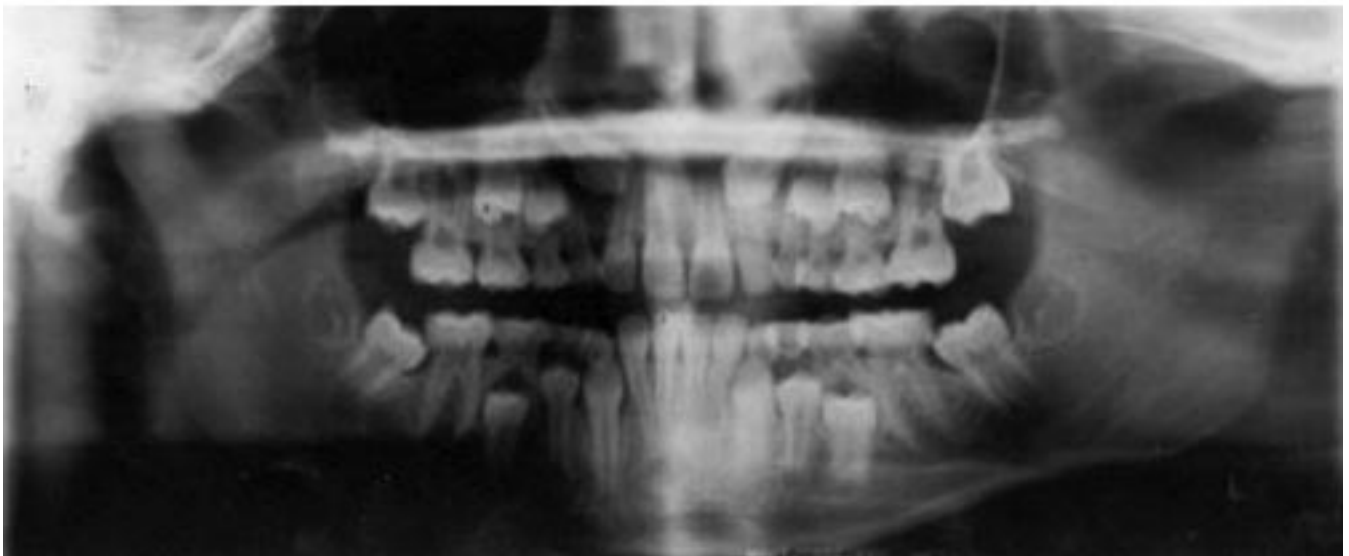
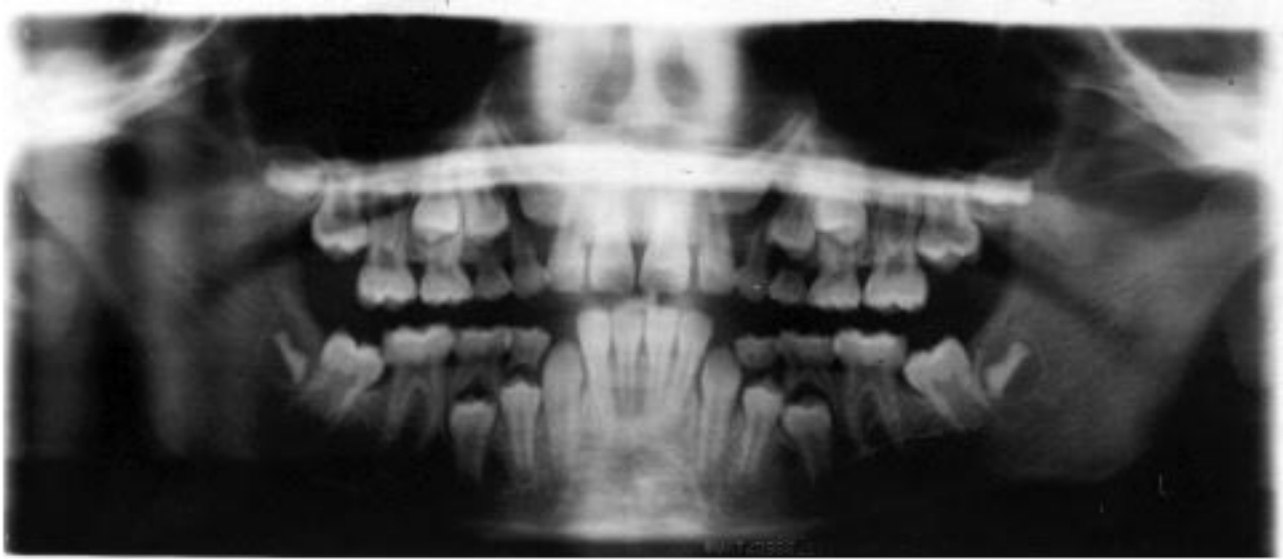
FIGURE 2. Panoramic radiographs, initial, at age 10.7 years. (a) MZ twin ES, (b) MZ twin DS.

served over a 15-month period, with only a facebow headgear in place for part of the time on the maxillary first molars to assure that no space loss occurred after extraction. Panoramic dental radiographs taken again at the age of 12 years indicated partial success of the PDC interception procedure: twin ES showed relatively normal eruption of the right maxillary canine and an impacted palatal displacement of the left one, whereas twin DS showed the left maxillary canine in nearly normal position and the maxillary right canine impacted palatally (Figure 3a,b). Thus, at this point,

a mirror imaging of palatally embedded canines was noted between the MZ twin girls.

Six months later, at age 12.5 years, corrective orthodontic treatment was planned for the twins, commencing with surgical exposure of the unerupted PDCs.

DISCUSSION

Since Francis Galton's classic paper¹⁹ of 1875, twin studies have been viewed as an ideal way to evaluate the in-

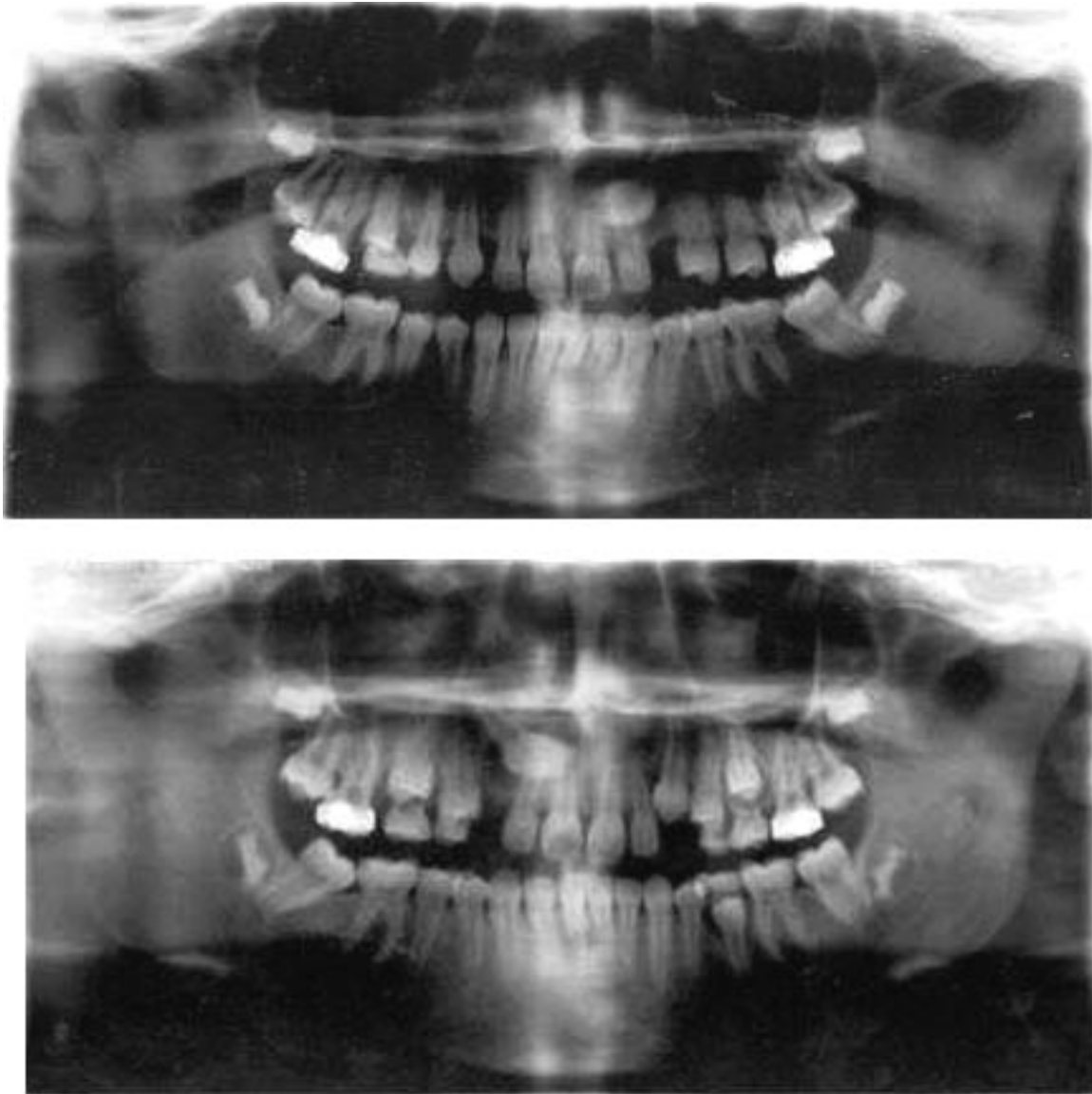


FIGURE 3. Panoramic radiographs, progress, at age 12.0 years. (a) MZ twin ES, (b) MZ twin DS.

TABLE 1. Monozygotic Twins with PDC Anomaly: Mesiodistal (MD) Crown Diameters of Permanent Teeth (in mm to the nearest 0.5 mm)

Tooth number (ISO two-digit system) ^a	MD diameter (mm)											
	16	15	14	13	12	11	21	22	23	24	25	26
Maxillary teeth												
Twin ES	11.0	7.0	7.0	8.0	7.0	8.5	8.0	7.5	8.5	7.0	7.5	10.5
Twin DS	10.0	6.5	6.5	—	7.0	8.0	8.5	7.0	8.0	6.5	6.0	10.0
Tooth number (ISO two-digit system)	46	45	44	43	42	41	31	32	33	34	35	36
Mandibular teeth												
Twin ES	11.0	7.0	7.0	7.0	6.0	5.5	5.5	6.0	7.0	7.5	7.5	11.5
Twin DS	11.0	7.0	7.0	7.0	6.0	5.5	5.5	6.0	7.0	7.5	7.5	11.5

^a ISO = International Organization for Standardization.

teraction between genetic (nature) and environmental (nurture) influences on a particular phenotype, including dentofacial variations.²⁰ Biologically, twinning results from a single fertilized ovum; so MZ twins are identical genetically. The chance that both MZ twins would express the same uncommon abnormality or condition as a random happening is highly unlikely.* Thus, it is reasonable that concordance of expression of an anomaly such as PDC in MZ twins may be a function or malfunction programmed into their genotype. To our knowledge, this is the first report of an unambiguous PDC anomaly in MZ twins.

The maxillary lateral incisors were present, well aligned, and of normal shape and size in both girls in this report. In fact, the mesiodistal crown measurements of all the erupted permanent teeth of the twins (Table 1) were uniformly average when compared with normative tooth-size data for Caucasians.²¹ Therefore, the empirical notion²² that PDC occurrence is under the mechanical control of a small, conical (peg shaped), or missing adjacent lateral incisor is not supported in this study.

The marked mesioangular malposition of the mandibular second molars observed in both girls may be worthy of further investigation. Earlier studies by Hoffmeister,²³ Bjerklin et al,²⁴ and Baccetti²⁵ have identified ectopic eruption of molars occurring as part of dental anomaly patterns. In addition, signs of enamel hypoplasia seen on some maxillary molars of both twins may be linked biologically to these related patterns of abnormal dental conditions.²⁵

REFERENCES

- Rohrer A. Displaced and impacted canines. *Int J Orthod Oral Surg.* 1929;15:1003–1020.
- Dachi SF, Howell FV. A survey of 3,874 routine full mouth radiographs. II. A study of impacted teeth. *Oral Surg Oral Med Oral Pathol.* 1961;14:1165–1169.
- Shah RM, Boyd MA, Vakil TF. Studies of permanent tooth anomalies in 7886 Canadian individuals. I. Impacted teeth. *J Can Dent Assoc.* 1978;44:262–264.
- Grover PS, Norton L. The incidence of unerupted permanent teeth and related clinical cases. *Oral Surg Oral Med Oral Pathol.* 1985;59:420–425.
- Peck S, Peck L, Kataja M. The palatally displaced canine as a dental anomaly of genetic origin. *Angle Orthod.* 1994;64:249–256.
- Racek J, Sottner L. Contribution to the heredity of retention of canine teeth [in Czech]. *Cesk Stomat.* 1977;77:209–213.
- Sottner L, Racek J. Determination of heritability of a characteristic. Model: retention of canines [in Czech]. *Cas Lék Cesk.* 1978;117:1060–1062.
- Sottner L. Our concept of inheritance of tooth retention from the aspect of molecular biology and genetics [in Czech]. *Cesk Stomat.* 1997;97:43–51.
- Pirinen S, Arte S, Apajalahti S. Palatal displacement of canine is genetic and related to congenital absence of teeth. *J Dent Res.* 1996;75:1346–1352.
- Peck S, Peck L. Palatal displacement of canine is genetic and related to congenital absence of teeth [commentary]. *J Dent Res.* 1997;76:728–729.
- Peck S, Peck L, Kataja M. Prevalence of tooth agenesis and peg-shaped maxillary lateral incisor associated with palatally displaced canine (PDC) anomaly. *Am J Orthod Dentofacial Orthop.* 1996;110:441–443.
- Peck S, Peck L, Kataja M. Concomitant occurrence of canine malposition and tooth agenesis: evidence of orofacial genetic fields. *Am J Orthod Dentofacial Orthop.* 2002;122:656–660.
- Peck L, Peck S, Attia Y. Maxillary canine—first premolar transposition, associated dental anomalies and genetic basis. *Angle Orthod.* 1993;63:99–109.
- Peck S, Peck L, Hirsh G. Mandibular lateral incisor-canine transposition in monozygotic twins. *ASDC J Dent Child.* 1997;64:409–413.
- Ericson S, Kurol J. Early treatment of palatally erupting maxillary canines by extraction of the primary canines. *Eur J Orthod.* 1988;10:283–295.
- Jacobs SG. Reducing the incidence of palatally impacted maxillary canines by extraction of deciduous canines: a useful preventive/interceptive orthodontic procedure. Case reports. *Aust Dent J.* 1992;37:6–11.
- Lindauer SJ, Rubenstein LK, Hang WM, Andersen WC, Isaacson RJ. Canine impaction identified early with panoramic radiographs. *J Am Dent Assoc.* 1992;123:91–97.
- Power SM, Short MBE. An investigation into the response of palatally displaced canines to the removal of deciduous canines and an assessment of factors contributing to favourable eruption. *Br J Orthod.* 1993;20:215–223.
- Galton F. The history of twins, as a criterion of the relative powers of nature and nurture. *J Anthropol Inst Great Britain Ireland.* 1875;5:391–406.
- Lauweryns I, Carels C, Vlietinck R. The use of twins in dentofacial genetic research. *Am J Orthod Dentofacial Orthop.* 1993;103:33–38.
- Moyers RE, van der Linden FPGM, Riolo ML, McNamara JA Jr. *Standards of Human Occlusal Development.* Vol. 28, Craniofacial Growth Series. Ann Arbor, Mich: Center for Human Growth and Development, University of Michigan; 1993:45.
- Becker A, Smith P, Behar R. The incidence of anomalous maxillary lateral incisors in relation to palatally displaced cuspids. *Angle Orthod.* 1981;51:24–29.
- Hoffmeister H. Undermining resorption of the second deciduous molar by the permanent molars as a microsymptom of hereditary dentition disorders [in German]. *Schweiz Monatsschr Zahnmed.* 1985;95:151–154.
- Bjerklin K, Kurol J, Valentin J. Ectopic eruption of maxillary first permanent molars and association with other tooth and developmental disturbances. *Eur J Orthod.* 1992;14:369–375.
- Baccetti T. A controlled study of associated dental anomalies. *Angle Orthod.* 1998;68:267–274.

*Using a prevalence rate of 2% for PDC, the probability that PDC would occur randomly in both members of a MZ twin pair would be one in 2500.