

# Growth Modification of the Rabbit Mandible Using Therapeutic Ultrasound: Is it Possible to Enhance Functional Appliance Results?

Tarek El-Bialy, BDS, MS Ortho, MS OSCI, Ortho Cert, PhD<sup>a</sup>; Iman El-Shamy, BDS, MS, PhD<sup>b</sup>; Thomas M. Graber, DMD, MSD, PhD, OdontDr, DSc, ScD, MD (Hon), FDSRCS (Eng)<sup>c</sup>

**Abstract:** Previous studies have shown that functional appliances can enhance mandibular growth when applied during the active growth period. However, besides patient compliance problems with bulky appliances and prolonged treatment demands, there is contradictory evidence that functional appliances have a significant long-term effect. Is there a method to enhance the growth response and improve the long-term success of functional appliances? Previous studies have also found that therapeutic ultrasound (US) can stimulate cartilage and bone growth. The objective of this study was to evaluate the effect of therapeutic US on condylar and mandibular growth in the rabbit model. Eight growing New Zealand male rabbits were chosen for this study. They received therapeutic US on one side of the mandible for 20 minutes/day for four weeks. Anthropometrical and histological evaluations revealed that US enhances mandibular growth by condylar endochondreal bone growth and consequently mandibular ramus growth. The significant results of this study support conducting a long-term study to evaluate the ultimate stability of the results obtained. Also, they suggest an extended research with a larger sample size and investigating the molecular basis of this stimulatory effect, together with forward posturing splints for optimal macroscopic and microscopic responses. (*Angle Orthod* 2003;73:631–639.)

## INTRODUCTION

Studies of the etiologic factors of Class II malocclusions recognize that most Class II malocclusions are a result of mandibular deficiency and not of maxillary excess.<sup>1</sup> Most Class II patients present with retrognathic mandibles and orthognathic maxillae.<sup>2</sup> Patients with mandibular deficiency and Class II malocclusion have a spectrum of esthetic, skeletal, and occlusal characteristics. For many patients, especially adults, optimal overall results are best obtained using a combined orthodontic-surgical approach.<sup>3</sup> However, treat-

ing such cases early while the patient is still growing, using mandibular propulsive functional appliances, can produce satisfactory improvement in the facial esthetics and minimizes the need for surgical intervention in many cases. But partial success is too often the ultimate result. Too often, the problem cannot be corrected satisfactorily for children by a combination of tooth movement and conventional growth modification methods alone.<sup>4</sup>

There is evidence that compensatory growth occurs at the temporomandibular joint, and especially the mandibular condyle, in response to altered occlusal function in young, growing animals.<sup>5–17</sup> Studies performed by McNamara<sup>1,12</sup> on monkeys and by Petrovic et al<sup>8</sup> on rats have shown that the condylar cartilage and bone in growing animals respond to the altered neuromuscular function induced by a protrusive appliance. These studies noted increased chondrocytic proliferation and subsequent bone deposition in a posterior and posterosuperior direction, so as to reposition the condyle within the mandibular fossa. Quantitative histological studies have clarified the time-dependent nature of the adaptive response, indicating that the initial large changes in cartilaginous proliferation are progressively diminished when restoration of functional equilibrium is obtained. Similar findings have been reported by Kiliaridis et al.<sup>14</sup>

The condylar cartilage of the mandible is classified as a secondary cartilage, in contrast to primary long-bone epiph-

<sup>a</sup> Lecturer, Department of Orthodontics, Tanta University, Tanta, Egypt, and at present, Assistant Professor and Clinic Director, Faculty of Dentistry, Department of Orthodontics, King Abdul Aziz University, Jeddah, Saudi Arabia.

<sup>b</sup> Associate Professor, Faculty of Dentistry, Department of Oral Pathology, Tanta University, Tanta, Egypt.

<sup>c</sup> Professor of Orthodontics, Kenilworth Dental Research Foundation, Chicago, IL.

Corresponding author: Tarek El-Bialy, BDS, MS Ortho, MS OSCI, Ortho Cert, PhD, Faculty of Dentistry, Department of Orthodontics, King Abdul Aziz University, PO Box 80215, Jeddah 21589, Saudi Arabia

(e-mail: telbially@hotmail.com).

Presented to the Saudi Dental Society meeting, Riyadh, Saudi Arabia, on January 4, 2003.

Accepted: January 2003. Submitted: November 2002.

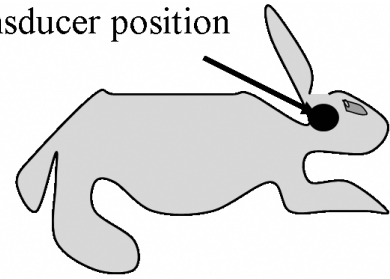
© 2003 by The EH Angle Education and Research Foundation, Inc.

yseal articular cartilages. Contrary to the epiphyseal articular cartilages, the condylar cartilage is not loaded by the weight of the body but by the repetitive and intermittent forces applied to the dentition during mastication.<sup>16</sup> A number of *in vitro* and *in vivo* studies have shown that biomechanical stimuli are necessary for normal growth of the secondary cartilage.<sup>17,18</sup> Also, mechanical loading triggers specific biochemical responses in mandibular condylar chondrocytes (Basdra et al.,<sup>19</sup> Ziros and Basdra<sup>20</sup>). Reducing the load on the mandibular condyle by reducing incisal contact has been shown to lead to a thinner cartilage layer than in controls.<sup>21</sup> It has been hypothesized that the mechanism of condylar-fossa growth modification with propulsive mandibular appliances, such as the Herbst and Twin-block that use displacement of the mandible, involves viscoelastic tissue extension forces to the condyle through several different attachments and transduction of forces radiating beneath the fibrocartilage of the glenoid fossa and condyle, inciting significant osteogenic responses from both the fossa and the condyle.<sup>22</sup>

Rabie et al<sup>23</sup> studied osteogenesis in the glenoid fossa in response to mandibular advancement at different time levels. They reported that mandibular protrusion resulted in the osteoprogenitor cells being oriented in the direction of the pull of the posterior fibers of the disk (viscoelastic pull) and also resulted in a considerable increase in bone formation in the glenoid fossa. They further studied the stimulatory effect of forward mandibular positioning on the expression of vascular endothelial growth factor (VEGF) and stimulation of bone formation in the glenoid fossa.<sup>24</sup> Maximum bone formation in the glenoid fossa was reached on day 21 of advancement (a week after the highest level of VEGF expression). This has been a long neglected reaction in the ultimate assessment of orthopedic guidance in Class II malocclusion correction.

Ultrasound (US), a form of mechanical energy that is transmitted through and into biological tissues as an acoustic pressure wave at frequencies above the limit of human hearing, is used widely in medicine as a therapeutic, operative, and diagnostic tool.<sup>25,26</sup> Therapeutic US, and some operative US, use intensities as high as one to three W/cm<sup>2</sup> and can cause considerable heating in living tissues. To take full advantage of this energy absorption, physical therapists often use such levels of US acutely to decrease joint stiffness, reduce pain and muscle spasms, and improve muscle mobility.<sup>27</sup> Low-intensity pulsed US (LIPUS) has been reported to be effective in liberating preformed fibroblast growth factors from a macrophage-like cell line (U937), and it enhances angiogenesis during wound healing.<sup>28</sup> Also, LIPUS has been reported to enhance bone growth into titanium porous-coated implants.<sup>29</sup> Recently, low-level therapeutic-pulsed US was used to enhance bone healing after fracture<sup>30,31</sup> and after mandibular distraction osteogenesis.<sup>32</sup> The molecular bases of the stimulatory effect of LIPUS on chondrocytes and on bone cells have been studied by many

## US transducer position



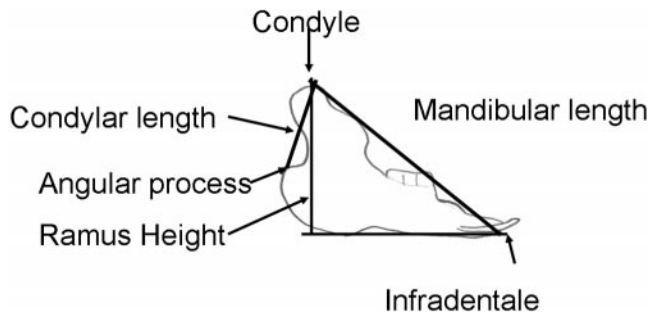
**FIGURE 1.** A schematic diagram showing the position of the ultrasound (US) transducer during US application.

authors.<sup>33–43</sup> The specific mechanisms by which US stimulation works on bone cell activities are still unknown. Ultrasound may generate some sort of mechanical force that acts on the bone cells, like shear stress, but this is not confirmed. However, both therapeutic and operative US subject tissue to power levels that are capable of causing considerable biological effects. The evidence of enhancement of metabolic processes is overwhelming.

## MATERIALS AND METHODS

The Research Committee at Tanta University, Faculty of Dentistry, approved the following protocol. Eight growing New Zealand male rabbits (10 weeks of age) were chosen for this study. Ultrasound was applied for 20 minutes/day for four weeks to the left of the mandible in each rabbit. The US was applied using a 2.5-cm lead zirconate–titanate transducer and consisted of a 200-microsecond burst of 1.5 MHz sine waves repeating at 1 kHz that delivered 30 mW/cm<sup>2</sup> incident intensity (Exogen Inc., West Caldwell, NJ).

The US transducer was attached securely to the surface of the mandible of each rabbit with Velcro straps, using a special sling tailored for the size of the rabbit's head. Figure 1 shows a schematic diagram of the position of the US transducer relative to the rabbits' heads. Ultrasound gel (Exogen) was used to couple the US energy between the transducer and the shaved skin surface. Ultrasound power was calculated using the technique described by Rooney<sup>44</sup> and has been discussed in detail previously.<sup>32</sup> Ultrasound was applied to all the animals while they were under sedation (Domitor 0.25 mg/kg *i.m.*; Pfizer, Espoo, Finland). After the application of US, the rabbits were awakened using Antisedan 1 mg/kg *i.m.* (Pfizer), so the rabbits could resume their regular activities. After four weeks, all animals were sacrificed by intravenous injection of 1 mL/kg sodium pentobarbitone (Vortech Pharmaceuticals, Dearborn, Mich), and the mandibles were surgically removed and divided at the symphyseal junction into 2 hemimandibles. All hemimandibles were radiographed with the following X-ray machine setting (65 kV<sub>p</sub> [peak kilovoltage], 300 mA, and 1/60 second). Each hemimandible was traced using acetate tracing paper, and three anatomic points were identified. Three anatomic parameters, two representing anteroposte-



**FIGURE 2.** Tracing of a hemimandible showing linear measurements taken to evaluate differential mandibular growth changes.

rior mandibular length and one representing mandibular ramus height, were evaluated on the tracing of each hemimandible. The points and plane and measurements are shown in Figure 2 and are listed below.

1. Measuring points

- Infradentale: most anterior point on alveolar process below the mandibular central incisor;
- Condylar point: most superior point on the mandibular condylar summit;
- Angular process: the most posterior contour on the mandibular ramus.

2. Planes and measurements

- Mandibular plane: a tangent to the inferior border of the mandible;
- Condylar height: the distance measured between the condylar point and the angular process;
- Ramus height: the perpendicular distance from condylar point to the mandibular plane;
- Mandibular height: the distance from condylar point to infradentale.

Two measurements were made of each parameter, and the mean was determined. Means and standard deviations were calculated for the three parameters that evaluated changes in the size of the rabbit mandibles. Student's *t*-tests for independent groups were performed, and a significance level of *P* < .05 was selected. Statistical analysis was done, using SPSS (version 10) software.

All hemimandibles were fixed in 10% buffered formalin for two weeks and then decalcified, using a solution containing 50% formic acid and 20% sodium citrate. The condylar head and necks were embedded in paraffin, and 6- $\mu$ m-thick sections were cut in the coronal plane and stained

with hematoxylin and eosin and with Masson Trichrome stain for light microscopy.

**RESULTS**

The mean and standard deviation of the three anthropometrical variables measured in this study are shown in Table 1. There was a significant increase in the mandibular ramus length condylar height and mandibular length in the US-treated hemimandibles compared with the untreated hemimandibles. Enlarged condyles and increased ramal height were clearly observed in the US-treated sides compared with the nontreated sides (Figure 3). Canting of the occlusal plane could also be seen.

**Histopathological results**

Tissue sections of the condyles of normal rabbits revealed a thin fibrous layer, which covered the articular surface, a thin fibrocartilaginous layer, and well-organized bony trabeculae with areas of marrow tissue (Figure 4).

The articular surfaces of the condyles of all control (normal) sides showed a dense fibrous layer, which covered a fibrocartilaginous layer, and thin arcades of calcified cartilage under which there were well-organized bony trabeculae, lined with inactive osteoblasts and encircled with wide areas of vascularized marrow tissue (Figures 5, 6).

Serial sections of all condyles of the US-treated group exhibited hyperplasia of the fibrocartilaginous layer, hypertrophy of the chondroblasts of the chondrogenic layers, and endochondral ossification (bone replacement) on the mineralized cartilaginous framework. Excessive bony trabeculae, lined with prominent active osteoblasts and dilated blood capillaries engorged with red blood cells, were also detected (Figures 7, 8).

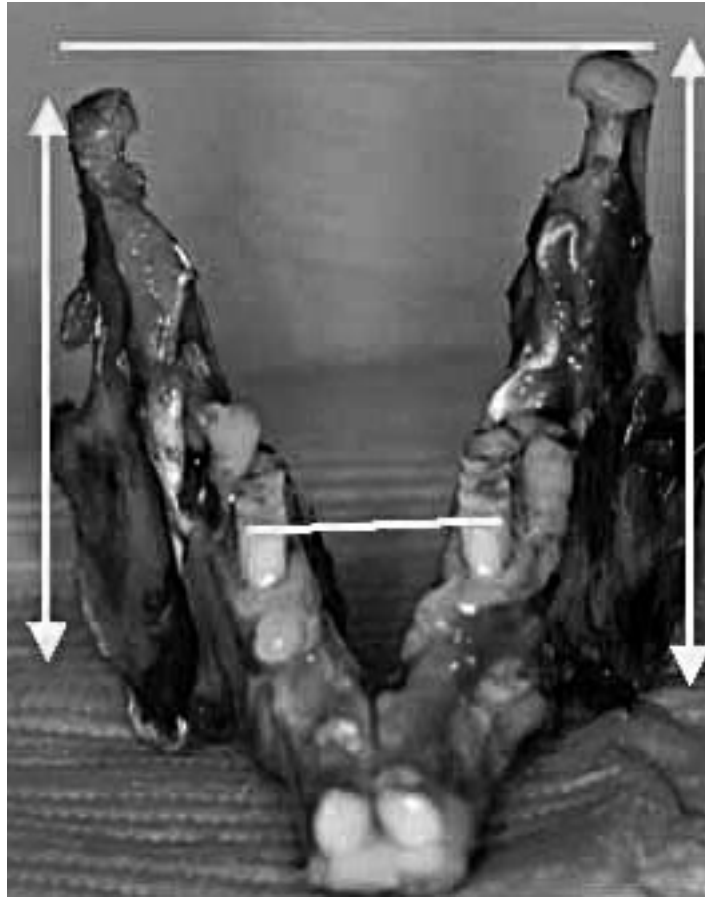
A deeper section toward the neck of the mandible showed marked ossification of newly formed bone, with highly vascularized marrow tissue (Figures 9, 10). There were areas of hemorrhage, congested and dilated blood capillaries, and a large number of multinucleated giant cells (MNGCs) (Figure 11).

Signs of remodeling, such as the presence of numerous resorption lacunae and MNGCs adjacent to these lacunae or distributed in the marrow tissue, were detected on the posterior and inferior sides of the US-treated condyles (Figure 12).

**TABLE 1.** Comparison of the Three Variables by *t*-test Between the Two Groups

	US <sup>a</sup>		No US		<i>P</i>
	Mean	SD	Mean	SD	
Ramus height	32.4	1.279323	29.5	1.118034	.003392
Condylar height	18.66667	0.752773	15.5	1.378405	.000588
Mandibular length	55.07333	1.327941	52.3	1.414313	.005711

<sup>a</sup> US indicates ultrasound.



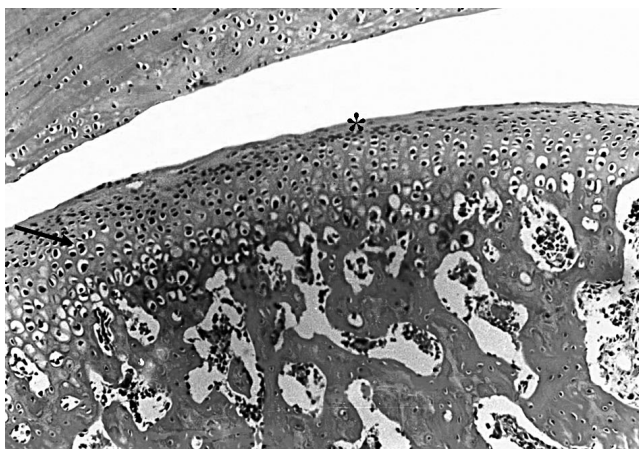
**FIGURE 3.** The dissected mandible immediately after sacrificing a rabbit. The difference in mandibular ramal height, the difference in the size of the mandibular condyles, and canting of the occlusal plane (right: normal, left: the ultrasound-treated condyle) can clearly be seen.

## DISCUSSION

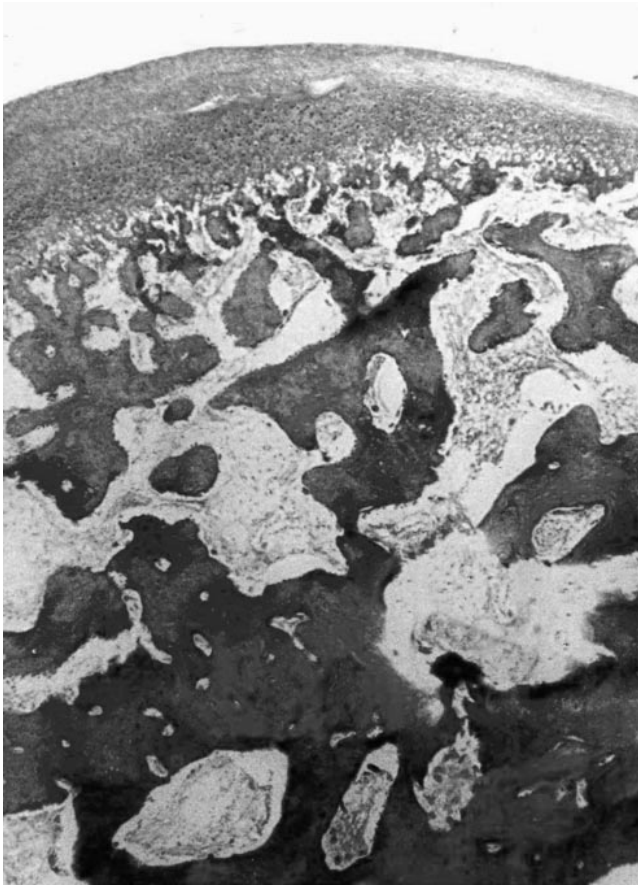This study was performed primarily to see if there is any stimulatory effect on condylar cartilage and on mandibular growth as a whole in growing rabbits. The rabbit model was chosen for this study because of the relatively large mandible and skull, which can allow the use of both right and left condyles as experimental and control sides, with unlikely possible transmission of LIPUS to the control side. This hypothesis is based on our previous study in which LIPUS was used to enhance bone formation during mandibular distraction osteogenesis in rabbits, where there was some stimulatory effect on the contralateral unexposed side.<sup>32</sup>

Our previous estimate was that LIPUS waves transmitted through the distracted mandibles would attenuate to about 12.2% of the intensity recorded on the treatment side when it reached the other side of the anterior part of the mandible (approximately two-cm thickness). However, the intercondylar distance has been reported to be about four cm,<sup>45</sup> producing negligible exposure to the condyle on the other side. This was verified mathematically as follows.

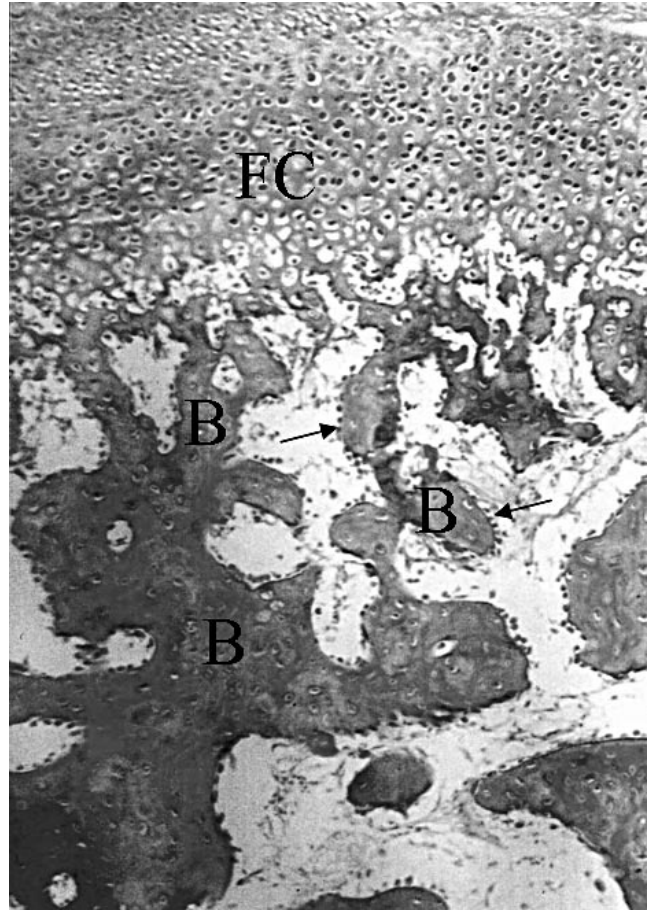
The pulsed US energy level will decrease exponentially with tissue penetration. It is suspected that the energy input



**FIGURE 4.** A photomicrograph of the articular surface of the condyle of a normal control, showing a thin fibrous covering with fibroblast-like cells (\*), proliferative zone, and hypertrophied chondrocytes (arrows) that extend into the lamellar bone. There are also wide spaces, including marrow tissue (H&E, 200 $\times$ ).



**FIGURE 5.** Photomicrograph of the articular surface of the condyle of a normal control showing a dense fibrous layer (\*) covering a fibrocartilaginous (FC) and thin arcades of calcified cartilage under which there are well-organized large areas of marrow tissue (Masson Trichome, 100×).



**FIGURE 6.** Higher magnification of the articular surface of a condyle of a normal control exhibiting fibrocartilaginous layer (FC) and bony trabeculae (B) that are lined with less prominent osteoblasts (arrows) and encircle delicate vascularized marrow tissue (Masson Trichome, 200×).

under direct treatment is substantially greater than under indirect treatment. An order-of-magnitude estimate of the degree of attenuation and relative dose strengths between the direct and indirect sides can be made on the basis of the following assumptions: (1) plane-wave propagation through one side of the jaw and mandible, through the soft tissues spanning the intercondylar distance and into the other side of the jaw and mandible (in reality, there will be additional loss due to scattering, especially with the presence of air regions); (2) only bone is spanning the intercondylar distance; and (3) pressure attenuation coefficient for the bone is  $\alpha_{\text{bone}} = 1 \text{ Np/cm}$  at 1 MHz (Goss et al<sup>45,46</sup>) (Np = neper; a neper equals 8.68 decibels [A decibel is a more common unit when relating the amplitudes of two signals]). The thickness of the skull bone spanning the intercondylar distance is estimated to be four cm.

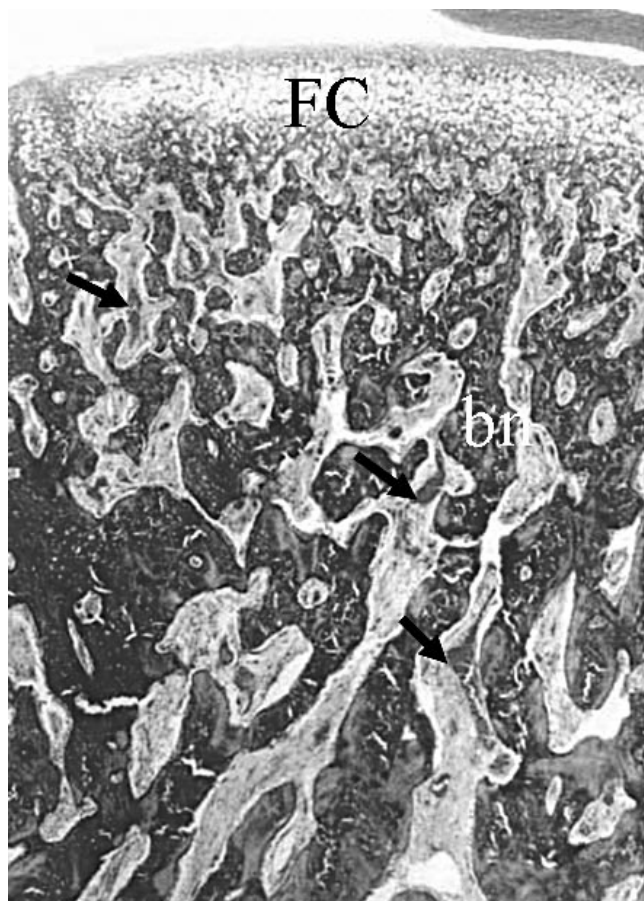
With these assumptions, the fraction of the intensity reaching the other side of the jaw would be

$$I/I_o = \exp[-2\alpha_{\text{bone}}d_{\text{bone}}] = \exp[-2(1)(4)] \\ = 0.000335$$

where  $I$  is the intensity at the other side, and  $I_o$  is the intensity incident on the first side. This is a very coarse estimate, which may be taken as an upper limit, but it shows 0.00035% of the energy getting to the other side. Pulsed US was applied for four weeks because it was reported that it has its greatest effect on stimulation of bone formation in the first two to three weeks of treatment.<sup>29</sup>

The linear measurements of condylar height, ramal height, and mandibular length were chosen because previous studies on mandibular growth in rabbits showed significant changes in the ramal height and mandibular length in guinea pigs stimulated by pulsating electromagnetic field (PEMF)<sup>16</sup> and on the rabbit condyles selectively inhibited by intra-articular papain injection.<sup>17</sup>

The mandibular condylar height was used here because of the evidence that, in many LIPUS-treated condyles, condylar necks were relatively longer than the untreated sides. The increased condylar length, ramal height, and mandibular length in the LIPUS condyles support the hypothesis that the mandibular condyle can be considered as the pri-

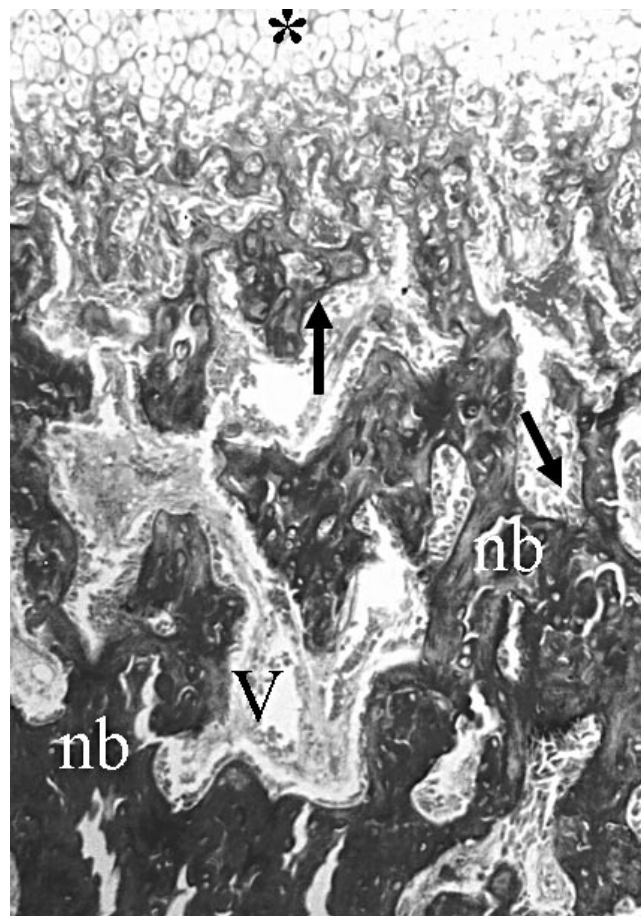


**FIGURE 7.** A photomicrograph of a condylar section, representing a LIPUS-treated group showing hyperplasia of the fibrocartilaginous layer (FC), hypertrophy of the chondroblasts, and excessive newly formed bony trabeculae (nb). Marked vascularity (arrows) is also observed (Masson Trichome, 100 $\times$ ). LIPUS, low-intensity pulsed ultrasound.

mary growth site of the mandible. This is in agreement with the finding of Tingey and Shapiro,<sup>17</sup> who used intra-articular papain to induce selective inhibition of condylar growth in the rabbit mandible. However, Gerling et al<sup>16</sup> used PEMF to stimulate mandibular growth in guinea pigs and concluded that it was not possible to significantly increase the size of the guinea pig mandible by using PEMF for 10 or 30 days.

In the present study, histological findings confirmed the enhanced linear measurements compared with the normal condyles and the control group, with a thicker fibrocartilaginous layer and hypertrophy of chondroblasts on the pulsed US side. These findings supported those of Parvizi et al,<sup>33</sup> who found that LIPUS stimulates proteoglycan synthesis in rat chondrocytes by increasing aggrecan gene expression.

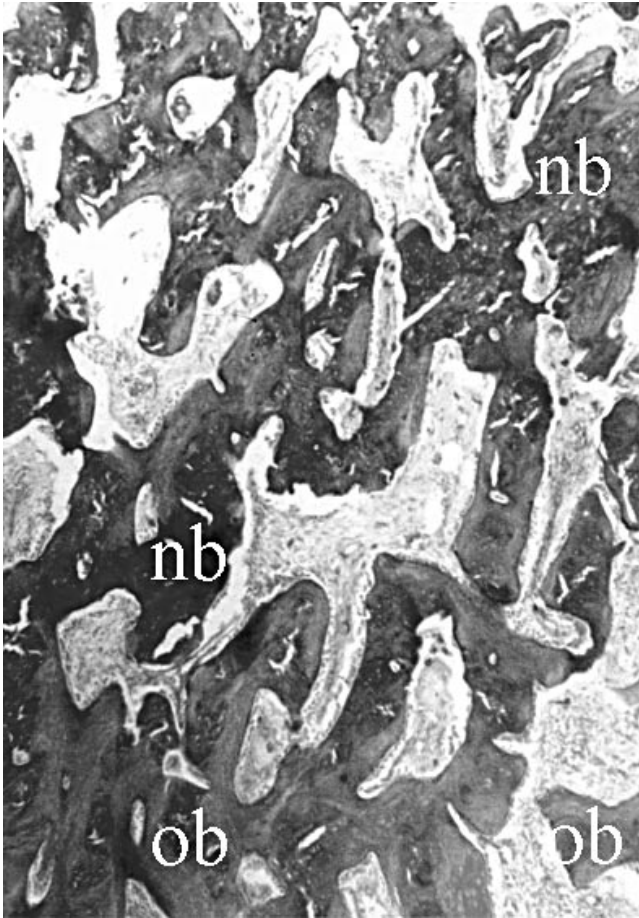
Excessive bone formation, lined with active osteoblasts, was detected in all LIPUS-treated condyles. This is in agreement with the previous research that suggested a stimulatory effect of LIPUS on the bone cells and osteogenesis



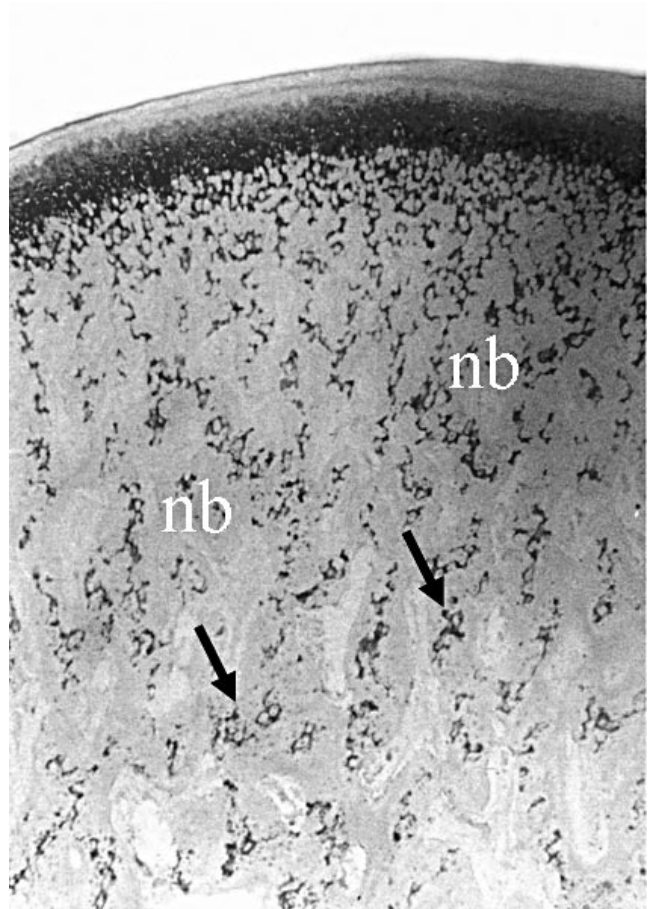
**FIGURE 8.** Higher magnification of the previous section in the LIPUS-treated group showing hypertrophy of the chondroblasts (\*) of the chondrogenic layer and endochondral ossification (bone replacement) on the mineralized cartilaginous framework and prominent active osteoblasts (arrows) at the peripheries of the newly formed bone. Also, in the same figure, markedly dilated blood vessels that are commonly engorged with blood cells (RBCs) are also seen (Masson Trichome, 200 $\times$ ). LIPUS, low-intensity pulsed ultrasound.

in UMR-106 cells.<sup>34</sup> It was also found that LIPUS has an enhanced anabolic effect on mouse bone marrow-derived stromal cell clone ST2 cells.<sup>35</sup>

It has been reported that the thermal effects of LIPUS probably can enhance osteogenesis by stimulation of the proliferation and differentiation of osteoprogenitor cells.<sup>36</sup> Other authors have reported on biological effects caused by the mechanical perturbation resulting from the pressure waves of US. These pressure waves may mediate biological activity directly by a mechanical deformation of the cell membrane or indirectly by an electrical effect caused by cell deformity because LIPUS changes the rates of influx and efflux of potassium ions in rat thymocytes.<sup>37</sup> Furthermore, it has been reported that the stimulatory effect of pulsed US on bone formation may be due to the increased secretion of prostaglandin E2<sup>38</sup> or may be related to increased secretion of growth factors<sup>39</sup> (or both), in addition to US exposure. Electric potential produced by pulsed US



**FIGURE 9.** A photomicrograph of a deeper extension (closer to the neck of the mandible) of the previous slide, showing marked ossification of newly formed bony trabeculae (nb) adjacent to the original old bone (ob) in the LIPUS-treated condyle (Masson Trichome, 100×). LIPUS, low-intensity pulsed ultrasound.

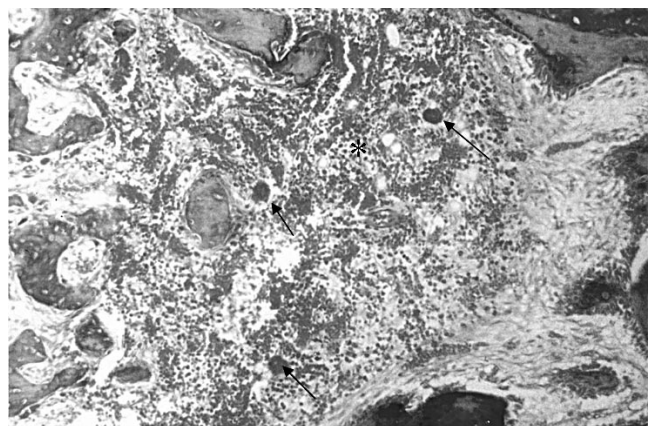


**FIGURE 10.** This section shows rapid osteogenesis and presence of a few cartilaginous tissues (arrows) that are still undergoing ossification along the whole thickness of the newly formed bone (nb) of the LIPUS-treated condyle (Toluidin blue, 100×). LIPUS, low-intensity pulsed ultrasound.

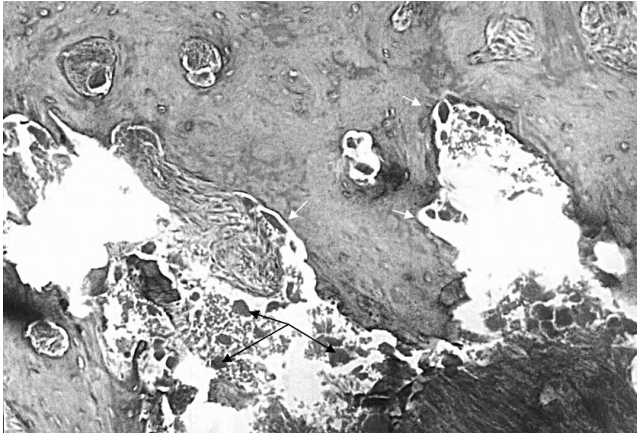
via the piezoelectric effect has also been found to increase bone formation and accelerate bone healing.<sup>40</sup>

Excessive formation of dilated blood capillaries, which are commonly engorged with red blood cells in the marrow tissue, was clearly observed in all tissue sections of the treated group. This is in agreement with the findings of Young and Dyson,<sup>28</sup> who concluded that the stimulatory effect of pulsed US on bone formation may be due to the increased formation of new blood vessels. Several studies have shown a reciprocal regulation and functional relationship between endothelial cells and osteoblasts, indicating that bone growth, bone repair, and bone remodeling are biological events that strictly depend on the rapid in-growth of new capillary blood vessels (angiogenesis).<sup>23,24</sup>

An important mediator of the angiogenic process involved in bone physiology is VEGF, which is a central regulator of angiogenesis, inducing endothelial cell migration and proliferation.<sup>23</sup> It was demonstrated that the expression of VEGF by bone cells stimulates the endothelial cells proximally located to express osteotropic growth factors.



**FIGURE 11.** A photomicrograph showing a central area with hemorrhage (\*) and dilated blood capillaries filled with blood cells (RBCs) and a number of multinucleated giant cells (arrows) in the LIPUS-treated condyles (Masson Trichome, 100×). LIPUS, low-intensity pulsed ultrasound.



**FIGURE 12.** A photomicrograph of the lower end of the LIPUS-treated condyle, showing signs of remodeling where there are numerous resorption lacunae and related osteoclasts (white arrows) at the peripheries of well-organized cancellous bone. Other multinucleated cells (black arrows) can also be detected in the marrow tissue (Mason Trichome, 100 $\times$ ). LIPUS, low-intensity pulsed ultrasound.

These factors could be directly involved in the process of bone formation. Rabie et al<sup>24</sup> also confirmed the stimulatory effect of forward mandibular positioning on the expression of VEGF and stimulation of bone formation. Consequently, the anthropometrical and histopathological findings of this study strongly support the potential of using LIPUS to enhance mandibular condylar growth.

### CONCLUSIONS

The daily use of low-intensity pulsed US for four weeks stimulates mandibular condylar growth and increases the mandibular condylar, ramal, and total mandibular heights in growing rabbits. Further studies are needed to test the long-term effects, the molecular biological bases, and quantitative histomorphometric analysis of this stimulatory effect with or without the use of functional appliances. A planned study will assess changes in the contiguous articular fossa structures.

### ACKNOWLEDGMENT

The authors thank Mr. Fathi Abd El Aziz, histology technician at the Oral Pathology Department, Faculty of Dentistry, Tanta University, Egypt, for his help in preparing and staining the histological sections.

Authors also wish to acknowledge Exogen Inc., West Caldwell, NJ, for supplying the ultrasound devices used in this research.

### REFERENCES

- McNamara JA. Components of Class II malocclusion in children 8–10 years of age. *Angle Orthod.* 1981;51:177–202.
- Graber TM, Rakosi T, Petrovic AC. *Dentofacial Orthopedic With Functional Appliances*. 2nd ed. Mosby -Year Book; 1997:19:421.
- Epker NB, Fish LC. The surgical-orthodontic correction of mandibular deficiency. Part I. *Am J Orthod Dentofacial Orthop.* 1983; 106:408–421.
- Proffit WR, White RP Jr. Who needs surgical-orthodontic treatment? *Int J Adult Ortho Orthognath Surg.* 1990;5:81–89.
- Baume LJ, Derichsweiler H. Is the condylar growth center responsive to orthodontic therapy? An experimental study in *Macaca mulatta*. *Oral Surg.* 1961;14:347–362.
- Charlier JP, Petrovic A, Herrmann-Stutzmann J. Effects of mandibular hyperpropulsion on the prechondroblastic zone of young rat condyle. *Am J Orthod.* 1969;55:71–74.
- Petrovic A. Mechanisms and regulation of mandibular condylar growth. *Acta Morphol Neerl-Scand.* 1972;10:25–34.
- Petrovic A, Stutzmann JJ, Oudet CL. Control processes in the postnatal growth of the condylar cartilage of the mandible. In: McNamara JA Jr., ed. *Determinants of Mandibular Form and Growth*. Monograph No. 4, Craniofacial Growth Series. Ann Arbor, Mich: Center for Human Growth and Development, The University of Michigan; 1975:101–154.
- Petrovic A, Stutzmann J, Gasson N. The final length of the mandible: is it genetically predetermined? In: Carlson DS, ed. *Craniofacial Biology*. Monograph No. 10, Craniofacial Growth Series. Ann Arbor, Mich: Center for Human Growth and Development, The University of Michigan; 1981:105–126.
- Stöckli PW, Willert HG. Tissue reactions in the temporomandibular joint resulting from anterior displacement of the mandible in the monkey. *Am J Orthod.* 1971;60:142–155.
- Adams CD, Meikle MC, Norwick KW, Turpin DI. Dentofacial remodeling produced by intermaxillary forces in *Macaca mulatta*. *Arch Oral Biol.* 1972;17:1519–1535.
- McNamara JA Jr. *Neuromuscular and Skeletal Adaptations to Altered Orofacial Function*. Monograph No. 1, Craniofacial Growth Series. Ann Arbor, Mich: Center for Human Growth and Development, The University of Michigan; 1972.
- McNamara JA Jr. Neuromuscular and skeletal adaptations to altered function in the orofacial region. *Am J Orthod.* 1973;64:578–606.
- Kiliaridis S, Engström C, Thilander B. The relationship between masticatory function and craniofacial morphology. I. A cephalometric longitudinal analysis in the growing rat fed a soft diet. *Eur J Orthod.* 1985;7:273–283.
- Kiliaridis S. Muscle function as a determinant of mandibular growth in normal and hypocalcaemic rat. *Eur J Orthod.* 1989;11: 298–308.
- Gerling JA, Sinclair PM, Roa RL. Effect of pulsating electromagnetic fields on condylar growth. *Am J Orthod Dentofacial Orthop.* 1985;211–223.
- Tingey TF, Shapiro PA. Selective inhibition of condylar growth in rabbit mandible using intra-articular papain. *Am J Orthod Dentofacial Orthop.* 1982;455–464.
- Peltomaki T, Kylamarkula S, Vinkka-Puhakka H, Rintala M, Kantomaa T, Ronning O. Tissue-separating capacity of growth cartilages. *Eur J Orthod.* 1997;19:473–481.
- Basdra EK, Huber LA, Komposch G, Papavassiliou AG. Mechanical loading triggers specific biochemical responses in mandibular condylar chondrocytes. *Biochim Biophys Acta* 1994;1222: 315–322.
- Ziros J, Basdra EK. Bone-specific transcriptional regulator Cbfa1 is a target of mechanical signals in osteoblastic cells. *J Biochem.* 2002;277:23934.
- Bouvier M. Effects of age on the ability of the rat temporomandibular joint to respond to changing functional demands. *J Dent Res.* 1988;67:1206–1212.
- Voudouris JC, Kuflinec MM. Improved clinical use of Twin-block and Herbst as a result of radiating viscoelastic tissue forces on the condyle and fossa in treatment and long-term retention: growth relativity. *Am J Orthod Dentofacial Orthop.* 2000;117: 247–266.
- Rabie ABM, Shum L, Chayanupatkul A. VEGF and bone for-



- mation in the glenoid fossa during forward mandibular positioning. *Am J Orthod Dentofacial Orthop.* 2002;122:202–209.
24. Rabie ABM, Zhao Z, Shen G, Hägg EU, Robinson W. Osteogenesis in the glenoid fossa in response to mandibular advancement. *Am J Orthod Dentofacial Orthop.* 2001;119:390–400.
  25. Maylia E, Nokes LD. The use of ultrasonics in orthopaedics—a review. *Technol Health Care.* 1999;7:1–28.
  26. Ziskin MC. Applications of ultrasound in medicine—comparison with other modalities. In: Rapacholi MH, Grandolfo M, Rindi A, eds. *Ultrasound: Medical Applications, Biological Effects, and Hazard Potential.* New York, NY: Plenum Press; 1987:49–59.
  27. Dyson M. Therapeutic applications of ultrasound. In: Nyborg WL, Ziskin MC, eds. *Biological Effects of Ultrasound.* New York, NY: Churchill Livingstone; 1985:121–133.
  28. Young SR, Dyson M. The effect of therapeutic ultrasound on angiogenesis. *Ultrasound Med Biol.* 1990;16:261–269.
  29. Tanzer ME, Harvey A, Kay P, Morton, Bobyn JD. Effect of non-invasive low intensity ultrasound on bone growth into porous-coated implants. *J Bone Joint Surg.* 1996;14:901–906.
  30. Abramovich A. Effect of ultrasound on the tibia of the young rat. *J Dent Res.* 1970;49:1182.
  31. Heckman JD, JB Ryaby J, McCabe JJ, Frey, Kilcoyne RF. Acceleration of tibial fracture-healing by non-invasive, low-intensity pulsed ultrasound. *J Bone Joint Surg.* 1994;76:26–34.
  32. El-Bialy TH, Royston TJ, Magin RL, Evans CA, Zaki AM, Frizzell LA. The effect of pulsed ultrasound on mandibular distraction. *Ann Biomed Eng.* 2002;30(10):1251–1261.
  33. Parvizi J, Wu CC, Lewallen DG, Greenleaf JF, Bolander ME. Low-intensity ultrasound stimulates proteoglycan synthesis in rat chondrocytes by increasing aggrecan gene expression. *J Orthop Res.* 1999;17:488–494.
  34. Warden SJ, Favalaro JM, Bennell KL, McMeeken JM, Ng KW, Zajac JD, Wark JD. Low-intensity pulsed ultrasound stimulates a bone-forming response in UMR-106 cells. *Biochem Biophys Res Commun.* 2001;286:443–450.
  35. Naruse K, Mikuni-Takagaki Y, Azuma Y, Ito M, Oota T, Kameyama K, Itoman M. Anabolic response of mouse bone-marrow-derived stromal cell clone ST2 cells to low-intensity pulsed ultrasound. *Biochem Biophys Res Commun.* 2000;268:216–220.
  36. Shui C, Scutt A. Mild heat shock induces proliferation, alkaline phosphatase activity, and mineralization in human bone marrow stromal cells and Mg-63 cells in vitro. *J Bone Miner Res.* 2001;16:731–741.
  37. Chapman IV, MacNally NA, Tucker S. Ultrasound-induced changes in rates of influx and efflux of potassium ions in rat thymocytes in vitro. *Ultrasound Med Biol.* 1980;6:47–58.
  38. Kokubu T, Matsui N, Fujioka H, Tsunoda M, Mizuno T. Low intensity pulsed ultrasound exposure increases prostaglandin E2 production via the induction of cyclooxygenase-2 mRNA in mouse osteoblasts. *Biochem Biophys Res Commun.* 1999;256:284–287.
  39. Ito M, Azumaa Y, Ohtaa T, Komoriyaa K. Effects of ultrasound and 1,25-dihydroxyvitamin D3 on growth factor secretion in co-cultures of osteoblasts and endothelial cells. *Ultrasound Med Biol.* 2000;26:161–166.
  40. Zorlu U, Tercan M, Ozyazgan I, Taskan I, Kardas Y, Balkar F, Ozturk F. Comparative study of the effect of ultrasound and electrostimulation on bone healing in rats. *Am J Phys Med Rehabil.* 1998;77:427–432.
  41. Nishikori T, Ochi M, Uchio Y, Maniwa S, Kataoka H, Kawasaki K, Katsube K, Kuriwaka M. Effects of low-intensity pulsed ultrasound on proliferation and chondroitin sulfate synthesis of cultured chondrocytes embedded in Atelocollagen gel. *J Biomed Mater Res.* 2002;59:201–206.
  42. Shimazaki A, Inui K, Azuma Y, Nishimura N, Yamano Y. Low-intensity pulsed ultrasound accelerates bone maturation in distraction osteogenesis in rabbits. *J Bone Joint Surg. Br.* 2000;82-B:1077–1082.
  43. Tsai CL, Chang WH, Liu TK. Preliminary studies of duration and intensity of ultrasonic treatments on fracture repair. *Chin J Physiol.* 1992;35:21–26.
  44. Rooney JA. Nonlinear phenomena. Chapter 6 in methods of experimental physics. Vol. 19. In: Edmonds PD, ed. *Ultrasonics.* New York, NY: Academic Press; 1981:299–353.
  45. Glattly AD, McKeown M. The growth of the rabbit skull in 3 dimensions—a radiographic cephalometric appraisal. *Anat. Anz. Jena.* 1982;151:105–118.
  46. Goss SA, Johnston RL, Dunn F. Comprehensive compilation of empirical ultrasonic properties of mammalian tissues. *J Acoust Soc Am.* 1978;64:423–457.
  47. Goss SA, Johnston RL, Dunn F. Compilation of empirical ultrasonic properties of mammalian tissues. II. *J Acoust Soc Am.* 1980;68:93–108.