

Transmigration of Mandibular Canines—A Review of the Literature and a Report of Five Cases

Simon Camilleri, MSc, LDSRCS (Eng), MOrth RCS (Eng)^a; Erica Scerri, BChD^b

Abstract: Transmigration of the mandibular permanent canine is a rare event, the etiology of which is not clear. We present five cases of transmigrated mandibular canines together with a review of the literature, a discussion of the etiology, and the treatment options. (*Angle Orthod* 2003;73:753–762.)

Key Words: Canine; Mandibular; Ectopic; Transmigration

INTRODUCTION

Failure of eruption of the mandibular canine is an unusual event. Shah et al¹ found eight unerupted mandibular canines in 7886 individuals. Grover and Lorton² found 11 impacted mandibular canines in 5000 individuals.

An unerupted tooth occasionally migrates to a location some distance away from the site in which it developed, but it usually remains within the same side of the arch. The mandibular permanent canine is the only tooth in the dental arch reported to migrate across the midline. Javid³ found one such case in 1000 students. In doing so, the tooth usually travels along the labial side of the incisor roots and migrates as far as the roots of the first molar on the opposite side.⁴

Ando et al⁵ were the first to use the term “transmigration.” This seems to be the most appropriate term.⁶ Tarsitano et al⁷ defined transmigration as the phenomenon of an unerupted mandibular canine crossing the midline. Javid³ expanded the definition to include cases in which more than half the tooth had passed through the midline. Joshi⁶ felt that the tendency of a canine to cross the barrier of the mandibular midline suture is a more important consideration than the distance traveled. Moreover, the stage of transmigration of the tooth at the time of examination is a determining factor in the distance traveled.

^a Associate Specialist in Orthodontics, Medical School, University of Malta, Guardamangia, Malta.

^b House Surgeon, School Dental Clinic, Triq Frangisk Saver Fenech, Floriana VLT, Malta.

Corresponding author: Simon Camilleri, MSc, LDSRCS (Eng), MOrth RCS (Eng), Medical School, University of Malta, Guardamangia, Malta
(e-mail: xmun@onvol.net).

Accepted: January 2003. Submitted: December 2002.

© 2003 by The EH Angle Education and Research Foundation, Inc.

REVIEW OF THE LITERATURE

Nodine⁸ has described the condition in prehistoric skulls. Thoma⁹ appears to have been the first to describe this anomaly in living patients. Subsequently, different authors have described cases of various transmigrated mandibular canines. With the advent of panoramic radiography, reports have been more frequent.^{3–7,10–32}

Migrated canines typically remain impacted.^{3,11,21,27,33–35} Infrequently, they may erupt ectopically at the midline²⁴ or on the opposite side of the arch.^{19,20,28,30} Occasionally, transmigrated teeth have erupted into the line of the arch and have been taken for supplemental canines.²⁰ Caldwell⁴ and Bruszt³⁰ provided neurological evidence that the canines did not develop in the region in which they were found but had migrated there from a position in or near their correct developmental site. Surgical removal of the tooth with an inferior dental nerve block on the migrated side caused pain. Once the contralateral side was blocked, pain ceased. This confirmed the origin of the tooth because it maintained its nerve supply from the original side.^{4,19,20,27,30,35} Furthermore, though both mandibular canines were found on the same side of the mandible, their morphology suggested that they belonged to opposite sides of the lower jaw because the teeth are mirror images of each other.^{19,20,27,30,32}

Ando et al⁵ demonstrated the transmigration of a mandibular canine across the mandibular symphysis to the opposite side of the dental arch by serial radiographs taken over several years. Greenberg and Orlian,²⁷ over a 30-month period, followed the transmigration of a normally positioned unerupted mandibular left canine to a position of horizontal impaction below the apices of the four incisors. Howard,³³ Kerr,²⁹ and Wertz²⁶ also cited cases where an apparently normal lower canine, for no apparent reason, tipped mesially and started to migrate across the lower incisors.

Clinical findings associated with transmigration of the canines include absence of mandibular canines in the dental

arch or abnormal retention of the mandibular primary canine.^{3,5,7,20,21,34} A few cases also involved congenitally missing mandibular lateral incisors^{22,33} and mandibular premolars.¹⁹

In most reports of transmigrated canines, the teeth were found in a horizontal position,^{3,11,31,34} below the apices of the erupted teeth, but semihorizontal and vertical transmigrated canines have also been reported.^{3,19,20,27,28,34} Transmigrated canines found labial to the roots of the incisors seem to be associated with increased proclination of the mandibular incisors.^{33,34}

The anomaly is properly diagnosed by radiographic evaluation, which is primarily based on the panoramic radiograph. Most transmigrated canines are asymptomatic, although follicular cyst formation and chronic infection with fistulization have been reported.³ Nodine⁸ reported that impacted and migrated mandibular canines are often discovered without having produced any apparent symptoms suggestive of their presence. Ando et al⁵ also reported that they had not observed any symptoms such as pain or oppression of the mandibular nerve owing to the transmigration of the canine in their patient.

Etiology of transmigrated mandibular canines

The etiology and exact mechanism of transmigration is still not clear, although a number of factors have been suggested. Tumors, cysts, and odontomas may cause malposition of teeth if they lie in the path of eruption of teeth.^{5,34} Other factors suggested by some authors^{5,11,34} as possible etiological factors are premature loss of deciduous teeth, retention of the deciduous canine, crowding, spacing, supernumerary teeth, and excessive length of the crown of the mandibular canines.

Howard³³ observed that those unerupted canines that lie between 25° and 30° in the midsagittal plane do not migrate across the mandibular midline. Those canines that lie between 30° and 95° tend to cross the midline. An overlap appears to exist between 30° and 50°. When the angle exceeds 50°, crossing the midline becomes a rule.³³

Javid³ and Joshi and Shetye¹⁶ suggested that the cause of transmigration may be an abnormally strong eruption force, which drives the canine through the dense symphyses. They also noted that the conical shape of the tooth aids its passage through the bone. These statements are invalid because by the time the canine does erupt ectopically, the mandible has long been a single bone, the symphyses having been thoroughly remodeled. Furthermore, ectopic second premolar teeth, which are certainly not conical, have also been reported to travel quite a long way.^{36,37}

Thoma,⁹ Fiedler and Alling,³⁸ Greenberg and Orlian,²⁷ and Wertz²⁶ reported cases in which a radiolucent area resembling a cystic lesion surrounded the transmigrated canine. However, it is difficult to say whether these pathological conditions were responsible for the transmigration or

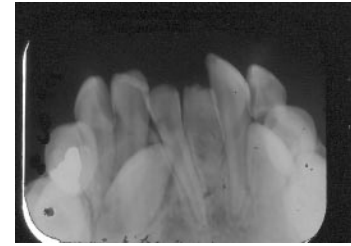


FIGURE 1. Case 1. Periapical view at age 10 showing 43 to be tipped mesially.

whether the pathological condition occurred after the migration of the canine.

Al-Waheidi³⁹ suggested that transmigrated canines are usually associated with a cystic lesion and that the presence of a cyst at the crown of the canine may facilitate the migration process. Other authors, such as Howard,³³ did not report that any cystic lesions were found during clinical examination of their patients. Al-Waheidi failed to state in his article whether the diagnosis of the dentigerous cyst was confirmed by histology. In any case, a cyst is an expansive lesion and is more likely to displace the tooth backward than facilitate forward movement.

Vichi and Franchi¹⁴ suggested that agenesis of the adjacent teeth, in particular the lateral incisor, may favor retention of the primary canine and that the excess of space in the dental arch may account for the absence of a correct guide for eruption. They observed proclination of the lower incisors, increased axial inclination of the unerupted canine, and an enlarged symphyseal cross-sectional area of the chin in nearly all their cases. They suggested that these factors could play an important role in the mechanism of transmigration. They further stated that the unerupted canine has the possibility of deviating from its normal developmental site, moving to a horizontal position, and migrating through the symphyseal bone only if enough space is available in front of the lower incisors.

Ando et al⁵ suggested the premature loss of teeth, inadequate space, and excessively large crowns as etiological factors. However, premature extraction of the deciduous canine is practiced in an attempt to correct the eruption of an ectopic permanent canine. Costello et al²⁵ and Joshi⁶ noted several cases where the deciduous canine had been retained.

Several cases of transmigrated canines occurred in conjunction with hypodontia and excess space.

The role of crowding and spacing in the etiology of ectopic canines is difficult to determine. However, transmigration has been reported to occur in both situations.

Joshi⁶ disagreed with the idea of lower incisor proclination and enlargement of the symphyses as etiologic factors. He believes that this is a consequence of canine migration, not a cause. Kerr²⁹ suggested that the increase in lower incisor proclination may be due to normal variations of incisor angulation during growth. Retention of primary canines does not seem to be an etiological factor and is more

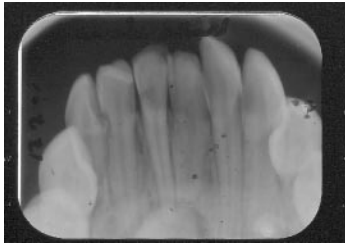


FIGURE 2. Case 1. Periapical view at age 11.5 showing 43 to have tipper further and submerged.

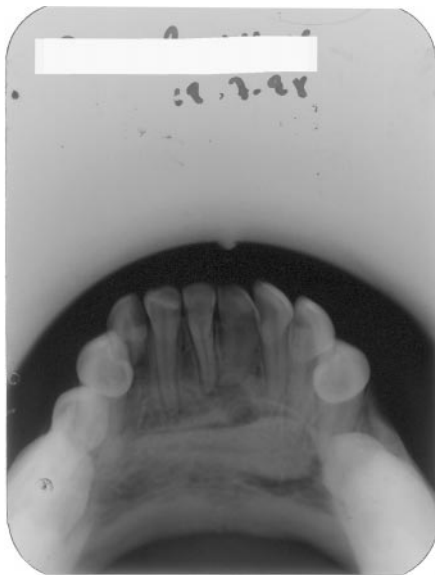

FIGURE 3. Case 1. Occlusal view showing 43 to have crossed the midline.

likely to be a result of failure of resorption of the root by the permanent canine.

Alaejeos-Algarra et al¹⁸ stated that canine tooth germs are located further from the normal site of eruption than are germs of other teeth. Although this is true of maxillary canines, it is not so in the mandible. An anomalous position of the tooth germ may also be involved in the pathogenesis of canine transmigration.¹⁹ However, all available evidence points to the tooth bud developing in its normal place and subsequently migrating to an ectopic position.

Mitchell¹⁵ and Nixon and Lowley⁴⁰ presented reports of cases in which the probable etiology of the displacement of a lower canine was a mandibular fracture through the developing crypt. Although the association of the trauma and the displacement of the lower left canine could be coincidental, this seems unlikely. This is particularly true given the corresponding developmental positions of the two mandibular canines at the time of the injury and the site of the fracture line through the crypt of the left mandibular canine. However, Ranta and Ylipaavalniemi,⁴¹ in a study on the effect of jaw fractures in children on the subsequent development of permanent teeth, found that teeth in which root formation had already started at the time of fracture appeared to erupt normally but exhibited shorter roots than unaffected contralateral teeth. This was presumably due to severance or impairment of the vascular supply to the pulp. None of the teeth in their study exhibited a deviant eruption path.

Both palatally displaced canines, hypodontia, enamel hypoplasia, and diminutive lateral incisors have a genetic etiology and are interrelated.⁴²⁻⁴⁴ It is not certain if there is a similar mechanism in the case of transmigration of the mandibular canine.

Peck⁴⁵ cited the role of genetics in the etiology of ectopic

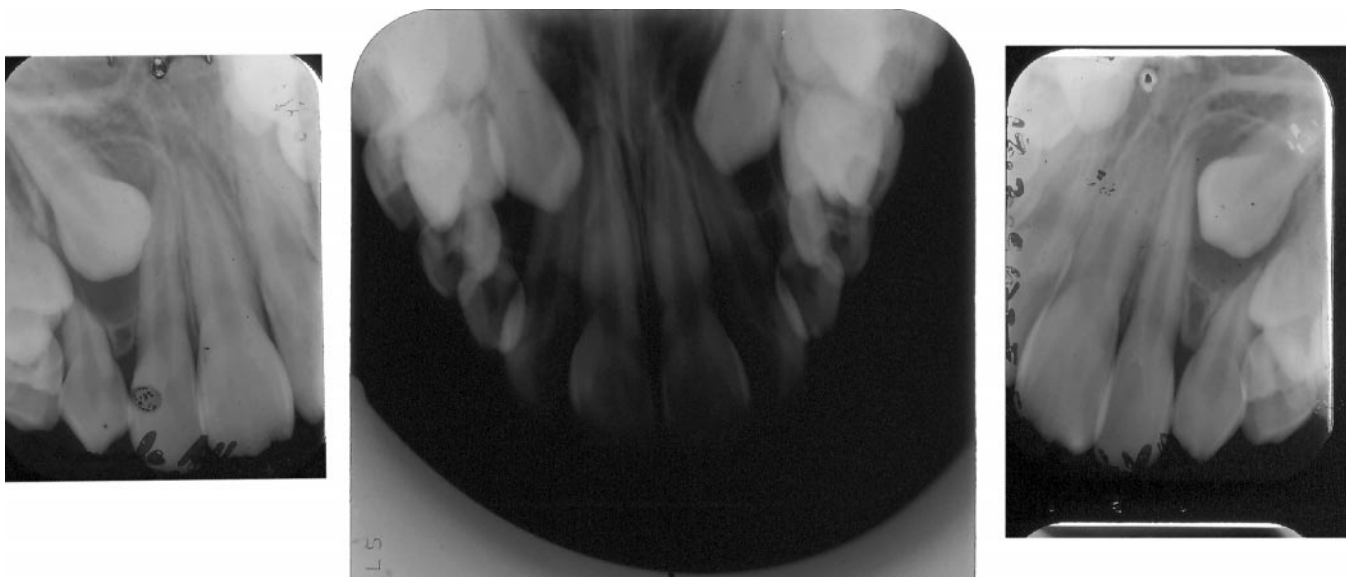


FIGURE 4. Case 1. Intraoral views showing palatal eruption pathways of 13 and 23.

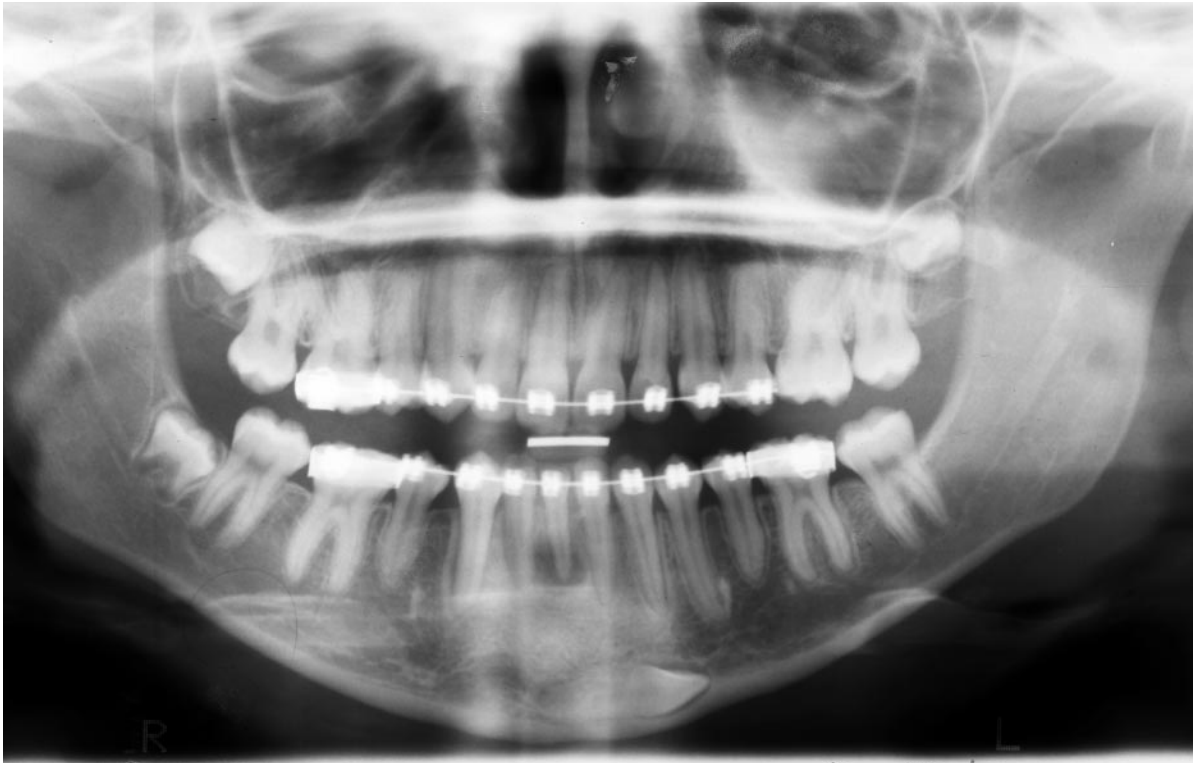

FIGURE 5. Case 1. Dental panoramic tomogram showing 43 in contact with lower border of the mandible.

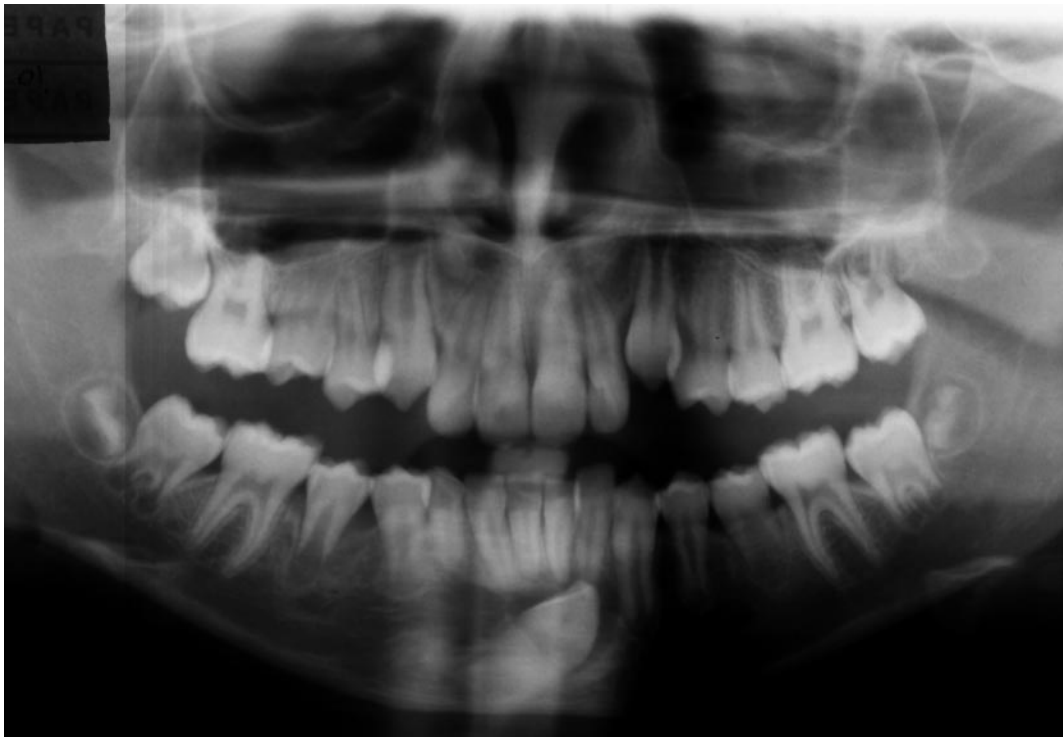


FIGURE 6. Case 2. Dental panoramic tomogram showing transmigration of 43.

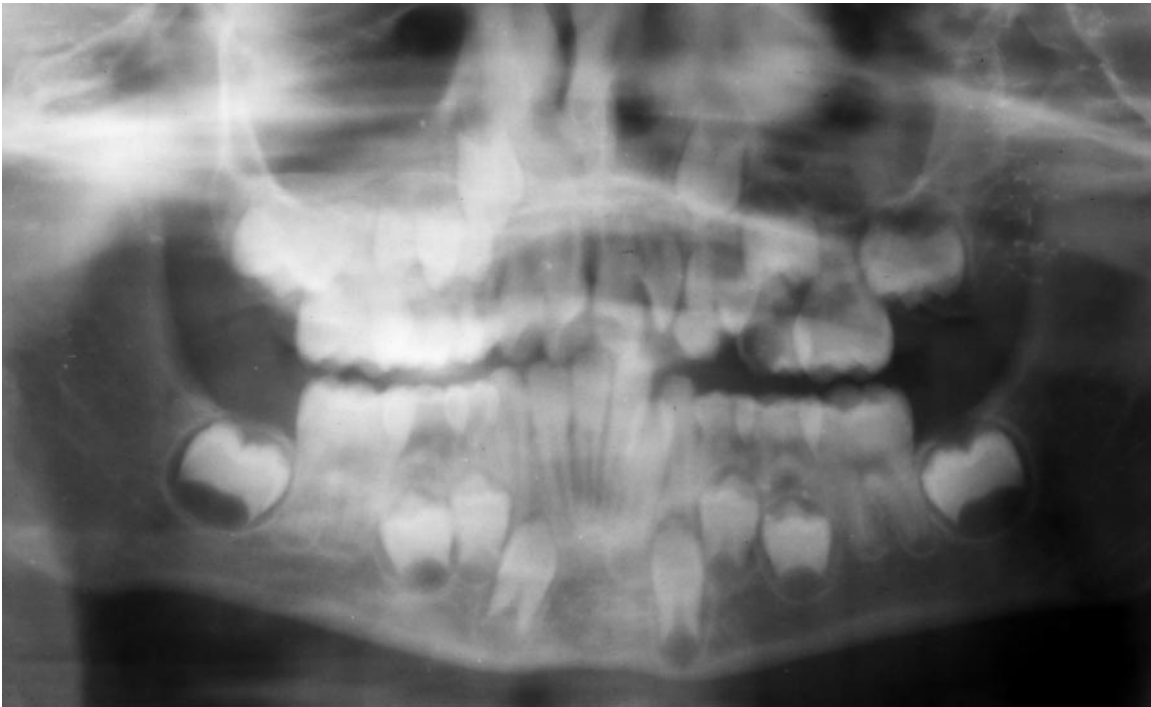

FIGURE 7. Case 2. Dental panoramic tomogram taken two years before Figure 6, showing no detectable abnormality of 43.

mandibular canines. He noted bilateral occurrences and the elevated occurrence of hypodontia and palatally displaced canines in the 12 cases of Vichi and Franchi¹⁴.

Kuftinec et al¹⁷ also reported a case with palatally displaced canines. The case presented by Kerr²⁹ also seems to have an ectopic maxillary canine, although no mention of this is made in the article.

Baccetti⁴³ has not associated hyperdontia with other dental anomalies, although the hereditary mode of transmission has been documented.^{46,47} Furthermore, Johnson⁴⁸ associated enamel hypoplasia, a hereditary defect, with hyperdontia. Howard³³ noted hypodontia in two of eight cases. He remarked that in both cases the missing tooth was on the contralateral side to the affected canine.

Shapira et al³⁴ described three cases of transmigration, one of which was accompanied by an odontoma. In this case, Shapira et al attributed the displacement of the canine directly to the presence of the odontoma.

Shapira and Kuftinec³⁵ reviewed 73 cases of transmigrated canines and reported that seven cases (9.5%) exhibited hypodontia, whereas five cases (7%) with odontomas were found. In three of these (4%), both anomalies were present. The figure for hypodontia, although high, is within the quoted range.^{49–51} The figures for hyperdontia⁵¹ and concomitant hypo-hyperdontia⁵² are higher than those quoted in the literature.

Unfortunately, Joshi⁶ did not give any information on hypodontia, hyperdontia, or any other inheritable dental anomaly in his presentation of a further 28 cases. However, one of the figures in his article displayed delayed devel-

opment of the lower second premolars, a feature associated with ectopic maxillary canines.⁵³

Taguchi et al¹⁰ presented a series of 15 cases, six of which exhibited hyperdontia. No mention of associated hypodontia is made; however, one figure clearly shows a missing lower lateral incisor with a fused predecessor. Taguchi et al¹⁰ mentioned odontomata as a cause of disturbance of eruption, reporting considerable improvement in the position of those canines associated with an odontoma, after removal of the same. However, the surgery itself could have had a beneficial effect, similar to the effect of extraction of primary canines or crown exposure on the eruption path of ectopic maxillary canines.

The cases where odontomas and failure of eruption of the lower canine were reported are reminiscent, in a minor way, of the dental anomalies in cleidocranial dysostosis, an inherited condition with defective osteoclast function.

Marks and Schroeder⁵⁴ attributed initiation and control of eruption to the dental follicle at the molecular level, with the coronal portion stimulating bone resorption and the apical portion stimulating deposition. They suggested that a regional disturbance in the dental follicle may lead to local defective osteoclastic function with an abnormal eruption pathway being formed. This is a plausible explanation for aberrant eruption of teeth.

Treatment of transmigrated mandibular canines

There are several treatment options proposed for unerupted mandibular canines.

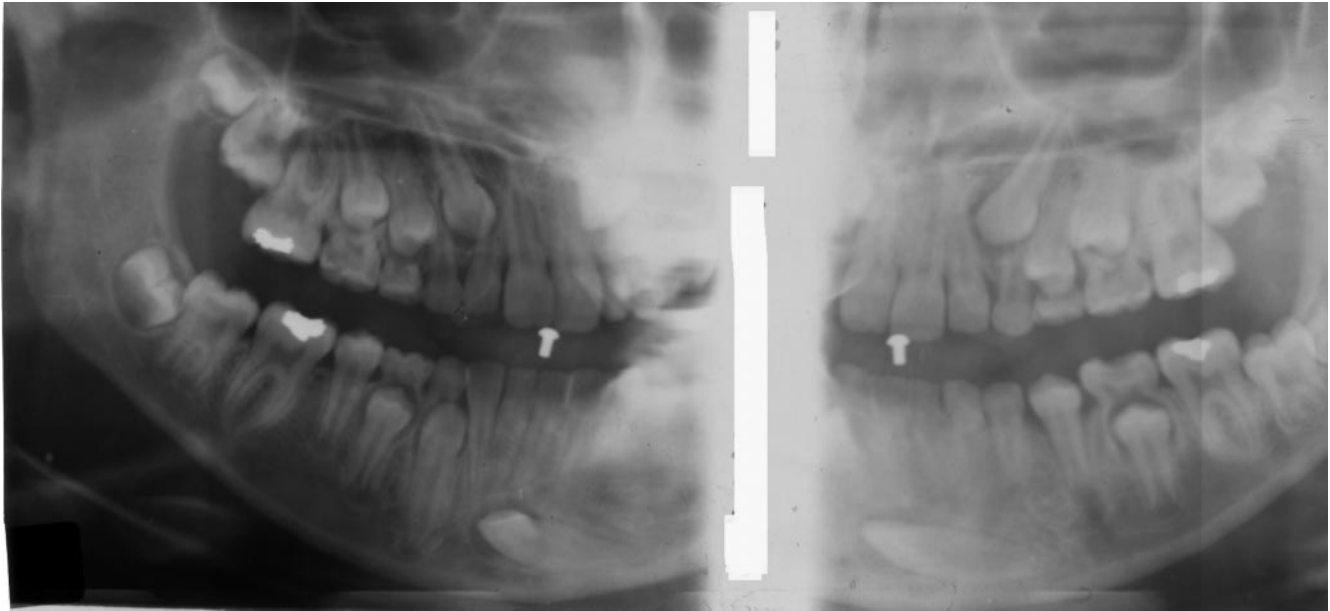


FIGURE 8. Case 3. Panorex showing ectopic positions of 13 and 33.

Surgical removal. Surgical extraction appears to be the most favored treatment for migrated canines, rather than a heroic effort to bring the tooth back to its original place. This is especially true when the mandibular arch is crowded and requires therapeutic extractions to correct the incisor crowding. Thoma⁹ stated that transmigrated canines usually have to be removed. Fiedler and Alling³⁸ also recommend the extraction of transmigrated canines.

Transplantation. If the mandibular incisors are in a normal position and space for the transmigrated canine is sufficient, transplantation may be undertaken. Howard³³ transplanted a transmigrated canine when there was enough space to accommodate the tooth.

Exposure and orthodontic alignment. Wertz²⁶ used orthodontic treatment to bring a labially impacted transmigrated canine into position. However, if the crown of such a tooth migrates past the opposite incisor area or if the apex is seen to have migrated past the apex of the adjacent lateral incisor, it might be mechanically impossible to bring it into place. Abbott et al²⁸ described the transposition of an incompletely erupted permanent right canine to a position between the permanent left canine and the left lateral incisor and indicated that the tooth was amenable to orthodontic treatment. They suggested that the premature extraction of first premolars should be avoided when radiographs demonstrate the presence of an overly mesially angulated unerupted canine that has begun to migrate labially across the incisors. In these cases, it may be impossible to bring the canine to its correct position.

Taguchi et al¹⁰ reported considerable improvement in the position of those canines associated with an odontoma, after removal of the odontoma and surgical exposure.

Observation. It has been advocated that an unerupted impacted tooth be removed as soon as convenient.²⁷ Other authors,²⁸ however, believe that symptomless, nonerupted teeth can be left in place. In these patients, a series of successive radiographs should be taken periodically. A progressive worsening of the position of the unerupted canine or suggestion of cystic change of the follicle should lead the clinician to consider the possibility of surgical extraction. The existence of pressure resorption of the roots of adjacent teeth, periodontal disturbances, or other possible foci for the spread of infection, prosthetic problems, malposition of the adjacent teeth, and neuralgic symptoms have been included as indications for surgical intervention in cases of impacted mandibular canines.¹¹

CASE REPORTS

Case 1

DA, an eight-year-old girl, presented complaining of unerupted lower central incisors. The lower lateral incisors were erupted and hypoplastic. The lower centrals erupted after exposure of the crowns but were also severely hypoplastic. The lower canines were noted to be palpable at age 10, with a note that 43 was further mesial than usual (Figure 1). A radiograph taken a year and a half later shows the lower left canine to be lying across the line of the arch (Figure 2). The position of the tooth rapidly deteriorated, and a radiograph taken another year later shows the tooth to have submerged and crossed the midline (Figure 3).

The upper canines were not palpable by age 11. Radiographs (Figure 4) show them to be palatal to the line of the arch. The upper deciduous canines were extracted, and

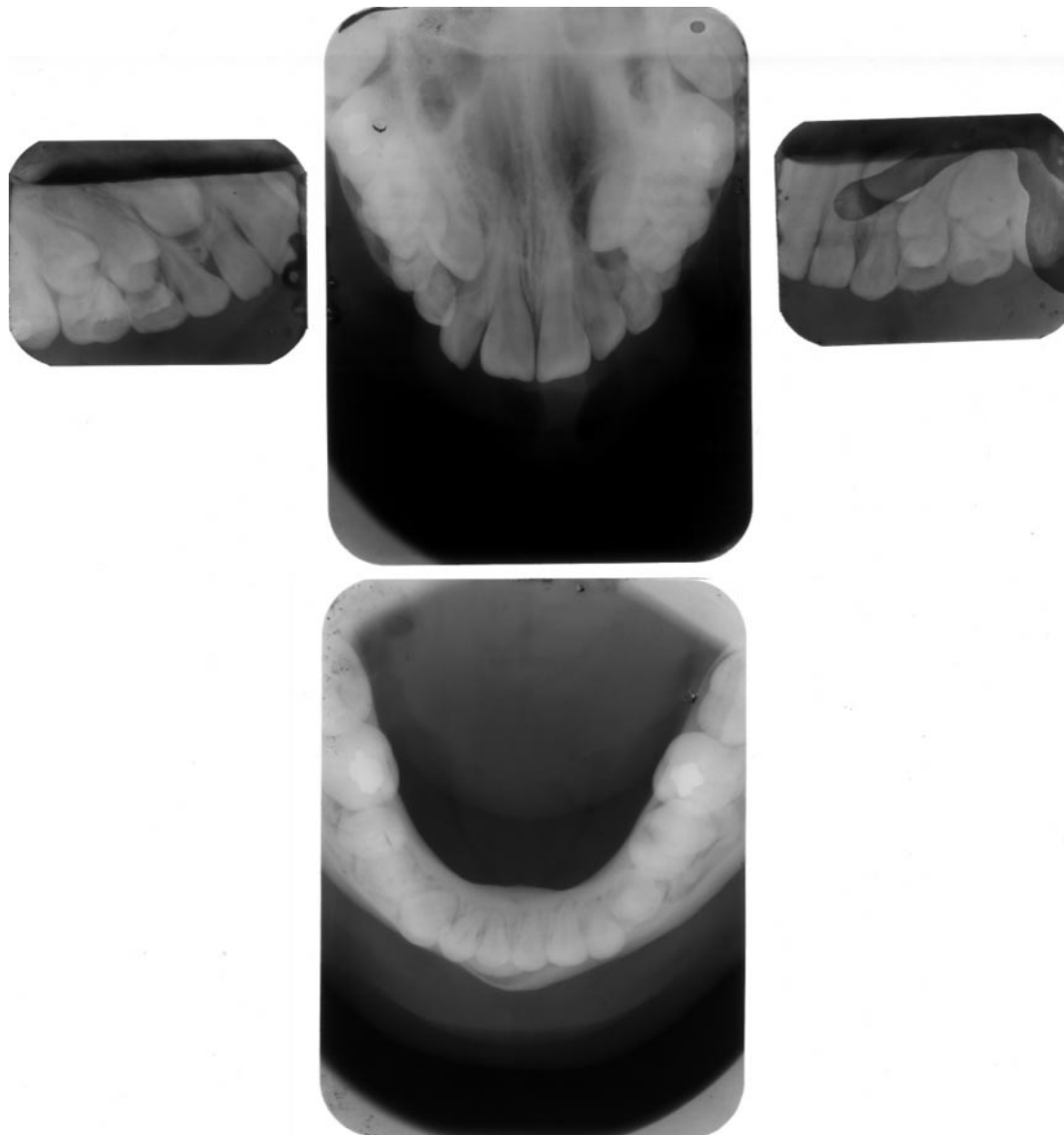


FIGURE 9. Case 3. Intraoral views showing ectopic positions of 13 and 33.

these teeth erupted uneventfully two years later into their correct positions.

As she required correction of mild crowding and a mild Class III malocclusion, it was decided to extract 15, 25, 31, and 83 in combination with fixed appliance treatment. Tooth 43 was nowhere near the apices of the incisors and was to be kept under observation.

A panoramic radiograph taken at age 16, before debonding shows it to have migrated as far as the canine of the opposite side. The follicle is small, shows no signs of cystic degeneration, and will be kept under radiographic control only. Tooth 41 is nonvital and will be root treated (Figure 5).

Examination of members of her immediate family (both parents and an older sister) shows no dental abnormalities.

Case 2

RC, a 12-year-old boy, referred by his health center for orthodontic treatment of an increased overjet. He was found to have an intact dentition, apart from a missing 43, which was subsequently found transmigrated on the radiograph (Figure 6). A panoramic radiograph, taken three years previously (Figure 7), shows no detectable abnormality of the tooth germ. He was referred for extraction of 14, 24, 43, and 83 under general anesthesia (GA) in preparation for orthodontic treatment to align the teeth and reduce the overjet. His family proved uncooperative, refusing to attend for further examination. His GA appointment was missed, and it subsequently transpired that he had sought private treatment elsewhere.

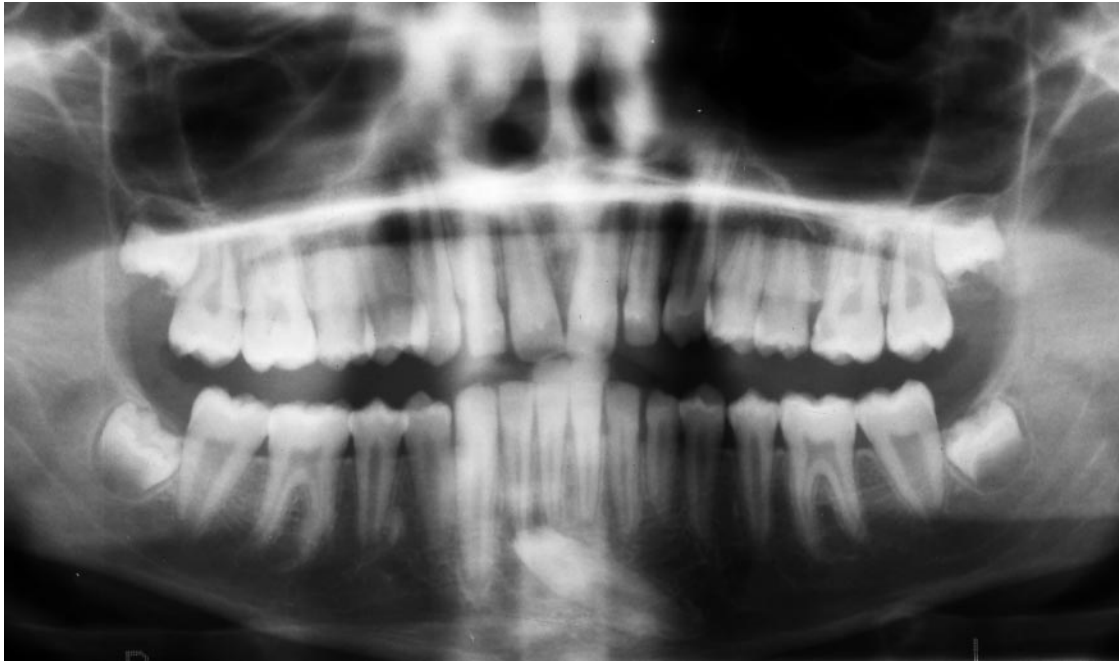

FIGURE 10. Case 4. Dental panoramic tomogram showing transmigrated 33.

Case 3

SF, a 13-year-old girl, was referred by her general dental practitioner (GDP), together with her younger sister, for treatment of her unerupted maxillary canines. She was in possession of a Panorex, taken one year previously (Figure 8). The clinical examination showed 15, 13, 23, 25, 33, and 43 unerupted. Tooth 13 was palpable very high in the buccal sulcus. Intraoral radiographs were taken (Figure 9) and she was referred back to her GDP for a fresh panoramic view.

Her 12-year-old sister also had a nonpalpable upper left maxillary canine. She was also referred for a panoramic radiograph. Unfortunately, the girls never returned for their follow-up appointment and were lost to recall.

Case 4

AB, a 14-year-old boy, was referred by his health centre for an orthodontic opinion regarding a missing lower canine tooth. He had an intact dentition, apart from a missing 33. Seven three was retained and firm. Numbers 12 and 22 were barrel-shaped, and 22 was diminutive with respect to its fellow.

The panoramic radiograph showed no further abnormality (Figure 10). Examination of members of his immediate family (parents and an older sister) showed no abnormality.

Case 5

GM, a 12-year-old boy, was referred by his health center for an orthodontic opinion regarding a delay in eruption of his upper anterior teeth. On examination, he was found to

have 12 and 22 unerupted, and 13, 23, and 43 not palpable in the sulcus. Numbers 36, 46, and 75 had been extracted four years previously.

The panoramic radiograph (Figure 11) showed the lateral incisors about to erupt and the canines high. Tooth 23 was suspiciously mesially inclined with the root apex further distal than its fellow. Tooth 43 was virtually horizontal in position, and 35 and 45 were erupting distally. The crown of the tooth had not yet crossed the midline, however, according to Howard's³³ criteria transmigration was to be expected.

Examination of members of his immediate family (parents, a 11-year-old sister, and a seven-year-old brother) showed no detectable abnormality. The parents were partly edentulous. The sister's dentition was developing normally. The brother will be kept under observation. He was referred for extraction of 43, 53, 63, and 84 under general anesthetic. A six-month review shows 12 and 22 to have erupted. The maxillary canines are not yet palpable and will be kept under observation together with 35 and 45.

DISCUSSION

In the five cases presented in this study, only one exhibited no other abnormality. The remainder had one or more inheritable anomaly also present. The commonest anomaly was ectopic eruption of other teeth, namely, the maxillary canines, although case 5 also had ectopic lower second premolars. None of the other members of the three families examined exhibited any dental anomalies themselves. This is not altogether surprising, given the rarity of this phenomenon. In fact, the sister in case 3 did have a nonpalpable

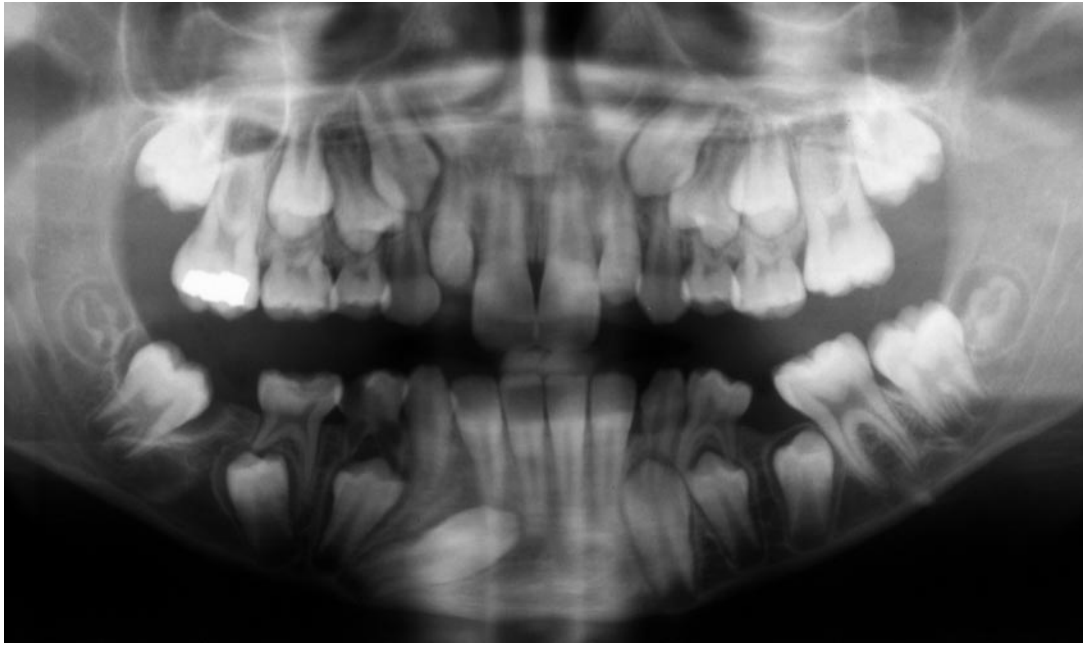


FIGURE 11. Case 5. Dental panoramic tomogram showing ectopic 43 and other eruption anomalies.

maxillary canine. Unfortunately, a follow-up radiographic evidence was not possible. Delayed dental development was evident in three of five cases, with dental age (as estimated by Nolla⁵⁵) lagging two years behind chronological age.

These cases provide further evidence that transmigration of the mandibular canine is associated with an increased prevalence of other inherited dental anomalies, supporting Peck's opinion⁴⁵ that the etiology of ectopic mandibular canines is genetic.

From the radiographs in cases 1 and 2, it can be seen that:

- Eruption initially appears normal.
- The tooth deviates for no apparent reason.
- The greatest amount of movement occurs during the pubertal age, where alveolar growth is at its maximum. This is also the case for normally erupting teeth. The direction of movement is usually mesial; however, distally and lingually ectopic canines are also seen.
- Occlusal movement of the tooth ceases. A mesial and apical path of movement is established, which worsens with time. As alveolar growth continues, the tooth becomes progressively buried.

The series presented by Ando et al⁵ Greenberg and Orlian,²⁷ Kerr,²⁹ and Wertz²⁶ showed a similar pattern of movement. The vast majority of ectopic teeth follow typical patterns, ie, lower canines tend to move mesially and buccally, lower premolars and lower incisors move distally, and upper canines move mesially and palatally.

This seems to suggest that the wrong region of the dental follicle is activated,⁵⁴ leading the tooth to “erupt” in the

wrong direction. In the case of transmigrated canines, the unobstructed direction of movement allows them to travel as far as the aberrant eruption pathway will carry them. However, there is no reason why their etiology should be any different from other ectopically erupting teeth.

CONCLUSIONS

Transmigration of the mandibular canine is a rare event. Its association with other inherited dental anomalies points to a genetic etiology, with a defect in the dental follicle metabolism “misdirecting” the eruption path from the normal vertical pattern to a mesial and apical pathway. Treatment is complicated and rarely leads to an ideal result.

REFERENCES

1. Shah RM, Boyd MA, Vakil TF. Studies of permanent tooth anomalies in 7,886 Canadian individuals. I: impacted teeth. *J Can Dent Assoc.* 1978;44:262–264.
2. Grover PS, Lorton L. The incidence of unerupted permanent teeth and related clinical cases. *Oral Surg Oral Med Oral Pathol.* 1985; 59:420–425.
3. Javid B. Transmigration of impacted mandibular cuspids. *Int J Oral Surg.* 1985;14:547–549.
4. Caldwell JB. Neurological anomaly associated with extreme malposition of a mandibular canine. *Oral Surg Oral Med Oral Pathol.* 1958;11:89–90.
5. Ando S, Aizawa K, Nakashima T, Sanka Y, Shimbo K, Kiyokawa K. Transmigration process of the impacted mandibular cuspid. *J Nihon Univ Sch Dent.* 1964;6:66–71.
6. Joshi MR. Transmigrant mandibular canines: a record of 28 cases and a retrospective review of the literature. *Angle Orthod.* 2001; 71:12–22.
7. Tarsitano JJ, Wooten JW, Burditt JT. Transmigration of nonerupt-

- ed mandibular canines: report of cases. *J Am Dent Assoc.* 1971; 82:1395–1397.
8. Nodine AM. Aberrant teeth, their history, causes and treatment. *Dent Items Interest.* 1943;65:440–451.
 9. Thoma KH. *Oral Surgery.* 2nd ed. St Louis, Miss: CV Mosby; 1952.
 10. Taguchi Y, Kuroi J, Kobayashi H, Noda T. Eruption disturbances of mandibular permanent canines in Japanese children. *Int J Paediatr Dent.* 2001;11:98–102.
 11. Miranti R, Levbarg M. Extraction of a horizontally transmigrated impacted mandibular canine: report of case. *J Am Dent Assoc.* 1974;88:607–610.
 12. Cowman SC, Wootton WR. Bilateral impaction of mandibular canines. *N Z Dent J.* 1979;75:113–114.
 13. Joshi MR, Daruwala NR, Ahuja HC. Bilateral transmigration of mandibular canines. *Br J Orthod.* 1982;9:57–58.
 14. Vichi M, Franchi L. The transmigration of the permanent lower canine. *Minerva Stomatol.* 1991;40:579–589.
 15. Mitchell L. Displacement of a mandibular canine following fracture of the mandible. *Br Dent J.* 1993;174:417–418.
 16. Joshi MR, Shetye SB. Transmigration of mandibular canines: a review of the literature and report of two cases. *Quintessence Int.* 1994;25:291–294.
 17. Kuflinec MM, Shapira Y, Nahlieli O. A case report. Bilateral transmigration of impacted mandibular canines. *J Am Dent Assoc.* 1995;126:1022–1024.
 18. Alaejos-Algarra C, Berini-Aytes L, Gay-Escoda C. Transmigration of mandibular canines: report of six cases and review of the literature. *Quintessence Int.* 1998;29:395–398.
 19. Kaufman AY, Buchner A, Gan R, Hashomer T. Transmigration of mandibular canine. Report of a case. *Oral Surg Oral Med Oral Pathol.* 1967;23:648–650.
 20. Pratt RJ. Migration of canine across the mandibular mid-line. *Br Dent J.* 1969;126:463–464.
 21. Black SL, Zallen RD. An unusual case of tooth migration. *Oral Surg Oral Med Oral Pathol.* 1973;36:607–608.
 22. Hebda TW, Underwood AE. Transposed mandibular canine. *Oral Surg Oral Med Oral Pathol.* 1980;50:197.
 23. Mehta DS, Mehta MJ, Mrgesh SB, Thakur S. Impactions of bilateral mandibular canines in criss-cross fashion. *J Indian Dent Assoc.* 1986;58:549–551.
 24. Brezniak N, Ben-Yehuda A, Shapira Y. Unusual mandibular canine transposition: a case report. *Am J Orthod Dentofacial Orthop.* 1993;104:91–94.
 25. Costello JP, Worth JC, Jones AG. Transmigration of permanent mandibular canines. *Br Dent J.* 1996;181:212–213.
 26. Wertz RA. Treatment of transmigrated mandibular canines. *Am J Orthod Dentofacial Orthop.* 1994;106:419–427.
 27. Greenberg SN, Orlan AI. Ectopic movement of an unerupted mandibular canine. *J Am Dent Assoc.* 1976;93:125–128.
 28. Abbott DM, Svirsky JA, Yarborough BH. Transposition of the permanent mandibular canine. *Oral Surg Oral Med Oral Pathol.* 1980;49:97.
 29. Kerr WJ. A migratory mandibular canine. *Br J Orthod.* 1982;9: 111–112.
 30. Bruszt P. Neurological anomaly associated with extreme malposition of a mandibular canine. *Oral Surg Oral Med Oral Pathol.* 1955;8:484–487.
 31. Stafne EC. Malposed mandibular canine. *Oral Surg Oral Med Oral Pathol.* 1963;16:1330.
 32. Bruszt P. On the migration of lower canines to the opposite side of the mandible. *Acta Morphol.* 1958;199–207.
 33. Howard RD. The anomalous mandibular canine. *Br J Orthod.* 1976;3:117–121.
 34. Shapira Y, Mischler WA, Kuflinec MM. The displaced mandibular canine. *ASDC J Dent Child.* 1982;49:362–364.
 35. Shapira Y, Kuflinec MM. Intraosseous transmigration of mandibular canines—review of the literature and treatment options. *Compend Contin Educ Dent.* 1995;16:1014–1018.
 36. Sutton PR. Migrating unerupted mandibular premolars: a case of migration into the coronoid process. *Oral Surg Oral Med Oral Pathol.* 1968;25:87–98.
 37. Orton HS, McDonald F. The eruptive potential of teeth: a case report of a wandering lower second premolar. *Eur J Orthod.* 1986; 8:242–246.
 38. Fiedler LD, Alling CC. Malpositioned mandibular right canine: report of case. *J Oral Surg.* 1968;26:405–407.
 39. Al-Waheidi EM. Transmigration of unerupted mandibular canines: a literature review and a report of five cases. *Quintessence Int.* 1996;27:27–31.
 40. Nixon F, Lowey MN. Failed eruption of the permanent canine following open reduction of a mandibular fracture in a child. *Br Dent J.* 1990;168:204–205.
 41. Ranta R, Ylipaavalniemi P. The effect of jaw fractures in children on the development of permanent teeth and the occlusion. *Proc Finn Dent Soc.* 1973;69:99–104.
 42. Bjerklin K, Kuroi J, Valentin J. Ectopic eruption of maxillary first permanent molars and association with other tooth and developmental disturbances. *Eur J Orthod.* 1992;14:369–375.
 43. Baccetti T. A controlled study of associated dental anomalies. *Angle Orthod.* 1998;68:267–274.
 44. Pirinen S, Arte S, Apajalahti S. Palatal displacement of canine is genetic and related to congenital absence of teeth. *Angle Orthod.* 1996;75:1742–1746.
 45. Peck S. On the phenomenon of intraosseous migration of nonerupting teeth. *Am J Orthod Dentofacial Orthop.* 1998;113:515–517.
 46. Brook AH. Dental anomalies of number, form and size: their prevalence in British schoolchildren. *J Int Assoc Dent Child.* 1974;5:37–53.
 47. Carton A, Rees RT. Mirror image dental anomalies in identical twins. *Br Dent J.* 1987;162:193–194.
 48. Johnson DB. Supernumerary lateral incisor teeth. *Br J Orthod.* 1974;1:149–157.
 49. Hunstadbraten K. Hypodontia in the permanent dentition. *ASDC J Dent Child.* 1973;40:115–117.
 50. Rolling S. Hypodontia of permanent teeth in Danish schoolchildren. *Scand J Dent Res.* 1980;88:365–369.
 51. Shah RM, Boyd MA, Vakil TF. Studies of permanent tooth anomalies in 7,886 Canadian individuals. II: congenitally missing, supernumerary and peg teeth. *J Can Dent Assoc.* 1978;44:265–268, 276.
 52. Gibson AC. Concomitant hypo-hyperodontia. *Br J Orthod.* 1979; 6:101–105.
 53. Becker A, Chaushu S. Dental age in maxillary canine ectopia. *Am J Orthod Dentofacial Orthop.* 2000;117:657–662.
 54. Marks SCJ, Schroeder HE. Tooth eruption: theories and facts. *Anat Rec.* 1996;245:374–393.
 55. Nolla CM. The development of the permanent teeth. *J Dent Child.* 1960;27:254–266.