

Production of Beta-HCG by Spermatic Cord Leiomyosarcoma: A Paraneoplastic Syndrome?

Case Report

SHIH-MING OU,* SHANG-SEN LEE,*
YI-JEN PENG,† LAI-FA SHEU,† NAI-SHUN YAO,‡
AND SUN-YRAN CHANG*

*From the *Division of Urology, Department of Surgery, the †Department of Pathology, and the ‡Division of Hematology/Oncology, Department of Internal Medicine, Tri-Service General Hospital, National Defense Medical Center, Taipei, Taiwan, Republic of China.*

Case Report

A 28-year-old man presented with a leiomyosarcoma of the spermatic cord after 3 weeks of increasingly painful swelling of the left upper hemiscrotum. The tumor was high-grade, Stage III pT2b N0 M0 (American Joint Committee on Cancer, 2002). A firm, nonreducible mass was palpable over the left upper hemiscrotum and distal inguinal canal. He denied any local trauma or unexpected weight loss and had no gynecomastia or vomiting. Four years before admission, he had undergone ipsilateral inguinal hernia repair, during which no tumor mass was noted. An ultrasonographic examination of the scrotum was performed using a linear 7.0 MHz transducer. This revealed an extratesticular, hypoechoic mass-like lesion extending cranially into the left inguinal canal. Color Doppler ultrasonography showed minimal vascularity. The left epididymis and testis were normal. The patient underwent en bloc resection, revealing a solid, round tumor measuring $6 \times 6 \times 4.5 \text{ cm}^3$, separate from the ipsilateral testis and epididymis. Pathology demonstrated a high-grade paratesticular leiomyosarcoma stemming from the spermatic cord (Figure 1A and B). Comprehensive studies did not show any metastases in the lungs, liver, or lymphatic system. Definitive therapy with radical inguinal orchiectomy and wide excision of surrounding soft tissue

confirmed a negative surgical margin of the initial en bloc resection.

Preoperative serum beta human chorionic gonadotropin (β -hCG) concentration was 43.88 ng/mL (immunoradiometric assay, CIS bio), whereas the postoperative β -hCG level decreased to normal (less than 0.15 ng/mL). Immunohistochemistry for β -hCG (DAKO, 1:200) revealed focal staining (Figure 1C) in the resected tumor. Two courses of systemic chemotherapy with regimen of BEP (bleomycin 30 mg day 2, 9, and 16; etoposide 100 mg/M² day 1 through day 5; cisplatin 20 mg/M² day 1 through day 5) were given as adjuvant therapy. Postoperatively, the patient has been free of recurrence or disease progression for 7 months.

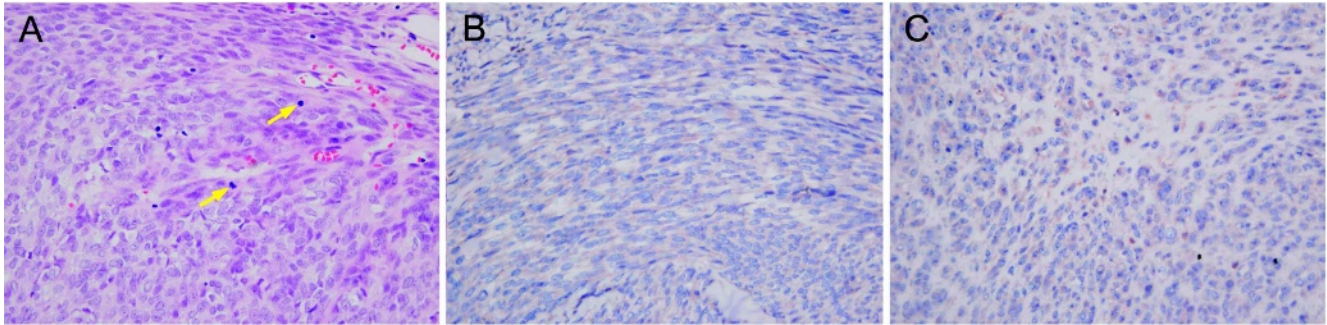
Most reports advocate radical inguinal orchiectomy with wide excision of the surrounding soft tissue as the standard treatment. Most distant metastases of spermatic cord leiomyosarcomas are either hematogenous to the lungs or liver, or pass via the lymphatic system to para-aortic lymph nodes. It appears that hematogenous metastasis is more frequent than lymphatic spread. Therefore, retroperitoneal lymph node dissection is not regularly recommended for patients with a spermatic cord leiomyosarcoma. Compared with surgery, the definite roles and therapeutic effects of adjuvant therapy, including chemotherapy and radiation therapy, are unknown. However, most physicians recommend radical surgery followed by radiation therapy or chemotherapy to achieve complete tumor regression. For this patient, we chose systemic chemotherapy rather than radiation therapy to abrogate any possibly hematogenous micrometastases after confirmation of a negative surgical margin. Cisplatin-based chemotherapy was used to treat the leiomyosarcoma, as there may also have been a syncytiotrophoblastic germ cell tumor with leiomyosarcoma differentiation.

Small intestine leiomyosarcomas that secrete β -hCG have been reported (Meredith et al, 1986). The female patient presented with hyperemesis gravidarum, a paraneoplastic syndrome caused by elevated level of serum β -hCG. HCG is a heterodimeric glycoprotein with a half-life of about 24–36 hours, assembled from 2 noncovalently linked α and β subunits which are encoded by 2 different genes. The α subunit of hCG is common to LH, FSH, and TSH. The β subunit of hCG

Correspondence to: Sun-Yran Chang, Division of Urology, Department of Surgery, Tri-Service General Hospital, National Defense Medical Center, No. 325, Sec 2, Cheng-Gung Rd, Nei-Hu, Taipei, Taiwan 114, Republic of China (e-mail: vins1023@ndmctsgh.edu.tw).

Received for publication April 12, 2006; accepted for publication June 1, 2006.

DOI: 10.2164/jandrol.106.000224



(A) Photomicrography of tumor reveals round to spindle nuclei with moderate atypia. Two mitotic figures are identified (arrows). H & E, reduced from 400 \times . (B) Actin, reduced from 400 \times . (C) Immunoreactivity of β -hCG, reduced from 400 \times .

confers hormonal specificity and serves as a tumor marker in the diagnosis and management of germ-cell tumors in men and of choriocarcinomas in women. Nongonadal cells producing β -hCG is associated with tumors of poor prognosis such as cancers of the lungs, pancreas, and liver. It may be secreted following metaplasia of the carcinomatous tissues into a tissue similar to poorly differentiated trophoblast cells.

Spermatic cord leiomyosarcomas with β -hCG secretion demonstrated by immunohistochemistry stain have been reported in the German literature (Seidl et al, 1998). In our patient, rapid normalization of β -hCG after tumor resection and positive immunohistochemistry stains of β -hCG in the resected tumor provide strong evidences of paraneoplastic secretion of β -hCG. To our knowledge, this has not been reported in the English medical literature. Because β -hCG could be a paraneoplastic manifestation in spermatic cord leiomyosarco-

mas, we recommend serum β -hCG as a biological marker to monitor and predict early recurrence in selective cases.

Acknowledgment

This study was supported in parts by the C. Y. Foundation for Advancement of Education, Sciences and Medicine.

References

- Meredith RF, Wagman LD, Piper JA, Mills AS, Neifeld JP. Beta-chain human chorionic gonadotropin-producing leiomyosarcoma of the small intestine. *Cancer*. 1986;58:131–135.
- Seidl C, Lippert C, Grouls V, Jellinghaus W. Leiomyosarcoma of the spermatic cord with paraneoplastic beta-hCG production [in German]. *Pathologie*. 1998;19:146–150.