

An Adult Case of Skeletal Open Bite with a Severely Narrowed Maxillary Dental Arch

Michiru Takeuchi, DDS^a; Eiji Tanaka, DDS, PhD^b; Daisuke Nonoyama, DDS^c;
Junko Aoyama, DDS^d; Kazuo Tanne, DDS, PhD^e

Abstract: Surgically assisted rapid maxillary expansion is proposed as an efficient approach for adult patients with transverse maxillary deficiency. This article reports the treatment of an 18-year, seven-month old male patient with an anterior open bite and a severely narrowed upper dental arch. A posterior crossbite was present on both sides. For the correction of the posterior crossbite, a lateral maxillary expansion of more than 8 mm was required. A surgically assisted rapid maxillary expansion with Le Fort I corticotomy and mandibular setback with a sagittal splitting ramus osteotomy were determined as the treatment plan. The total treatment time was 24 months including five months of post-surgical observation. After the treatment, an acceptable occlusion was achieved with a Class I molar relationship. The amount of actual maxillary expansion was 6.3 mm at the canines and 9.7 mm at the first molars. The relapse of the expansion was 0.9 mm and 0.1 mm at the corresponding regions two years after the surgically assisted maxillary expansion. It is emphasized that surgically assisted rapid maxillary expansion is a secure and efficient approach for achieving a desirable lateral maxillary expansion with stability in adult patients demonstrating transverse maxillary deficiency. Furthermore, it is suggested that longterm observation of the maxillary arch width after retention is of a great importance for the maintenance of the acceptable treatment outcome. (*Angle Orthod* 2002;72:362–370.)

Key Words: Surgically assisted rapid maxillary expansion; Transverse jaw discrepancy; Narrow maxillary arch; Two-stage surgery

INTRODUCTION

The etiology of open bite has already been described.^{1,2} Orofacial habits such as finger sucking, lip biting, and mouth breathing, and genetic factors are well known causes of open bite.^{1,2} In early orthodontic treatment, dentoalveolar open bite can easily be corrected by eliminating local environmental causes such as parafunctional habits. However, adult skeletal open bite cases are more difficult due to complicated problems and often require surgical correction.³

Skeletal open bite is characterized by various morphological features (ie, negative overbite, large mandibular plane angle, mesially inclined molar teeth, narrow maxillary dental arch, short ramus height and downward and backward rotation of the maxillomandibular skeleton).³ Among these characteristics, narrow maxillary dental arch, accompanied by a posterior crossbite, is a major problem because the relapse of the transverse maxillary dimension leads to the recurrence of posterior crossbite and an anterior open bite.

For the orthodontic treatment, various appliances have been designed to efficiently achieve lateral maxillary expansion. Rapid maxillary expansion has been used frequently for younger patients.^{4,5} However, if applied to adult patients, the possibility of successful palatal expansion is decreased because the sutures show a more interdigitated form and greater resistance to mechanical forces.⁶ For such cases, a surgically assisted rapid maxillary expansion would produce a better treatment result.

The purpose of this article is to present a case of adult skeletal open bite with a severely narrowed maxillary dental arch treated by means of a two-stage orthognathic surgery including a surgically assisted rapid maxillary expansion.

^a Clinical Associate, Orthodontic Clinic, Hiroshima University Dental Hospital, Hiroshima, Japan.

^b Associate Professor, Department of Orthodontics, Hiroshima University Faculty of Dentistry.

^c In private practice, Higashi-Hiroshima, Japan.

^d Graduate student, Department of Orthodontics, Hiroshima University Faculty of Dentistry, Hiroshima, Japan.

^e Professor and Chairman, Department of Orthodontics, Hiroshima University Faculty of Dentistry, Hiroshima, Japan.

Corresponding author: Michiru Takeuchi, Clinical Associate, Department of Orthodontics, Hiroshima University Faculty of Dentistry, 1–2–3 Kasumi, Minami-ku, Hiroshima 734–8553, Japan (e-mail: michiru@hiroshima-u.ac.jp).

Accepted: February 2002. Submitted: June 2001.

© 2002 by The EH Angle Education and Research Foundation, Inc.

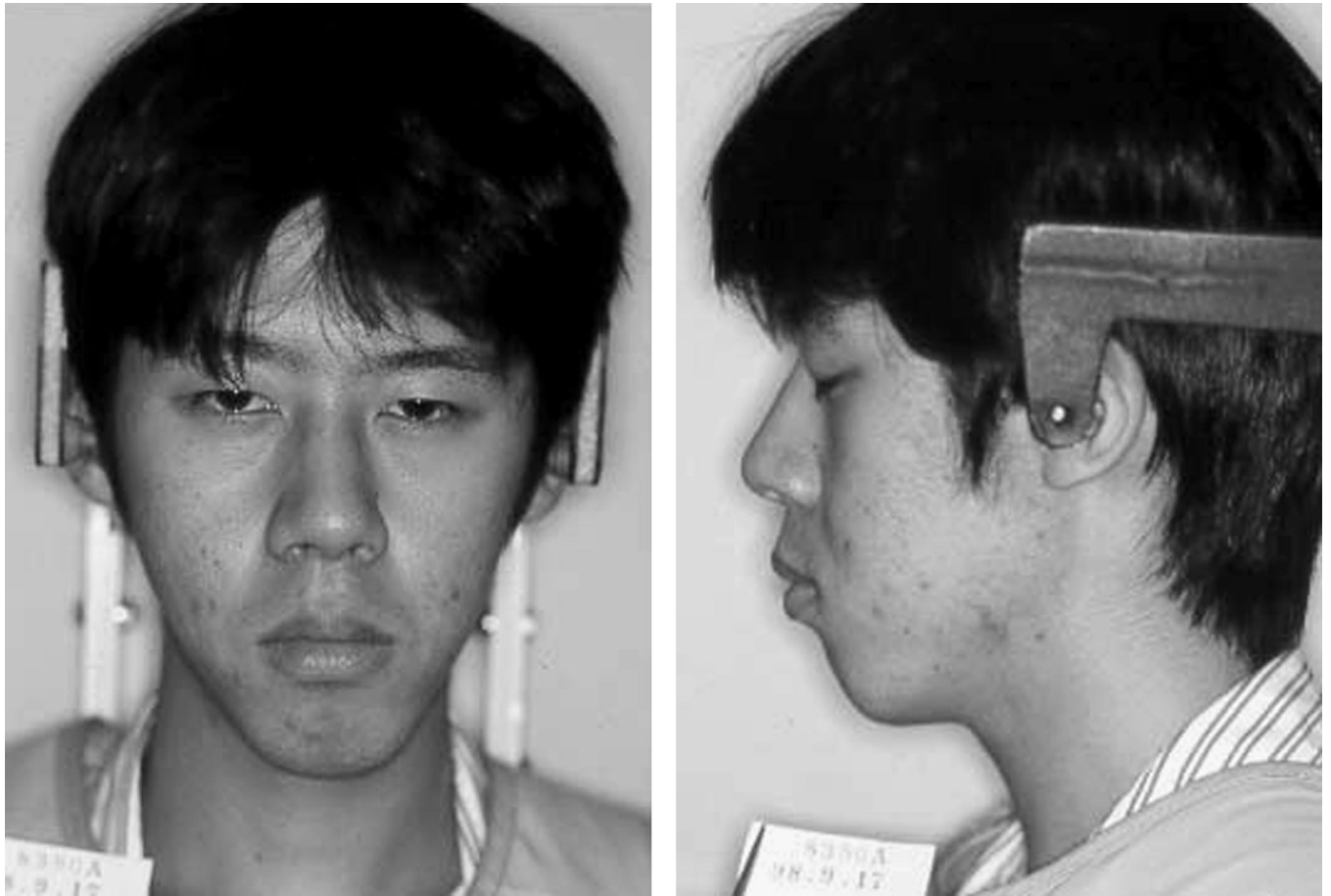

FIGURE 1. Facial photographs before treatment (18y7m).

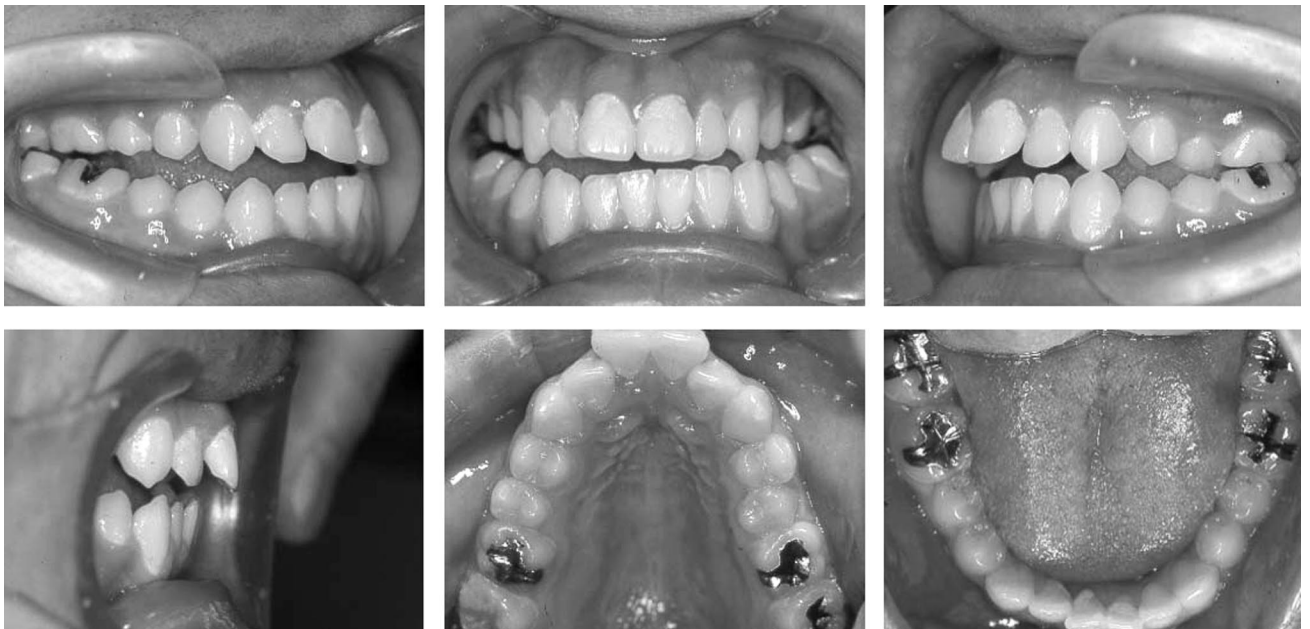


FIGURE 2. Intraoral photographs before treatment (18y7m).

ARCH FORM

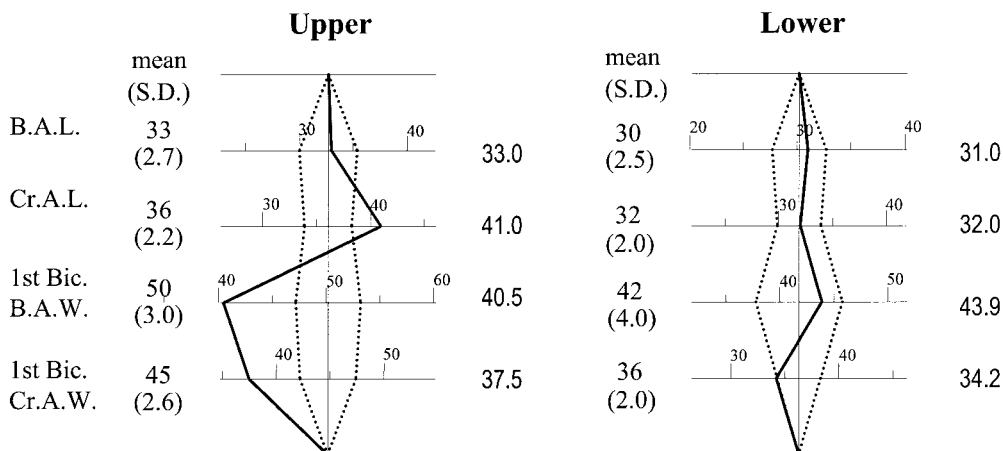


FIGURE 3. Basal and coronal arch widths before treatment (18y7m).

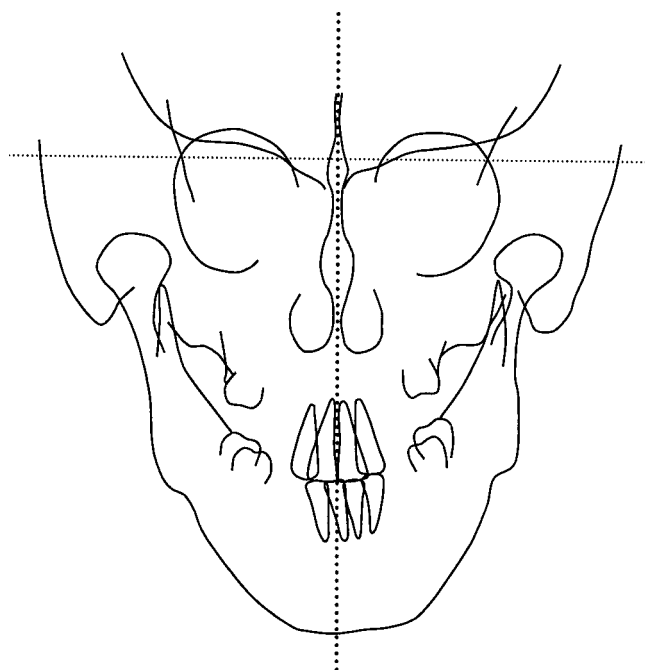


FIGURE 4. PA cephalogram tracing before treatment (18y7m).

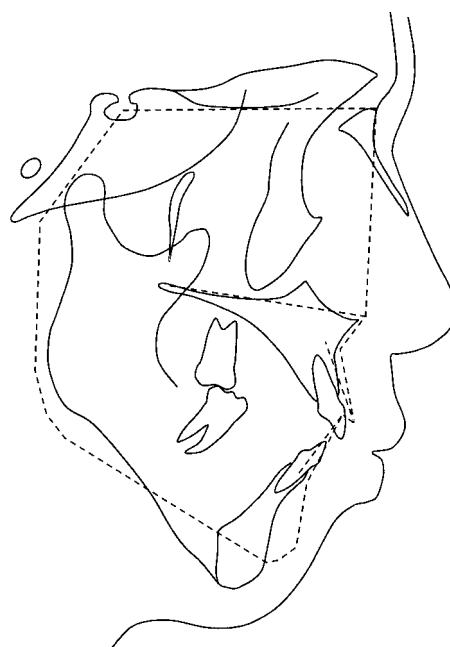


FIGURE 5. Lateral cephalogram tracing before treatment (solid line) superimposed with the mean profilogram (dotted line) (18y7m).

CASE REPORT

An 18-year, seven-month-old male patient had an anterior open bite and a severely narrowed upper arch (Figure 1). He complained of occlusal and masticatory disturbances due to the anterior open bite. The molar relationship was Class III on the right side and Class I on the left side (Figure 2). Overjet and overbite were +6.1 mm and -3.0 mm, respectively. A posterior crossbite was present on both sides and an open bite was present from the anterior to the premolar regions. The maxillary dentition exhibited a narrow V-shaped dental arch. From the model analysis, basal and

coronal arch widths of the upper dentition were below the normal range of Japanese men, whereas both arch widths of the lower dentition were almost normal⁷ (Figure 3). The mandibular midline shifted to the left by 2.0 mm, whereas the maxillary midline was almost coincident to the facial one⁸ (Figure 4). Periodontal problems and temporomandibular joint disorders were not found.

Cephalometric analysis indicated the features of a skeletal open bite (Figure 5). The mandibular plane and gonial angles were larger than normal, although the cant of the palatal plane was within the normal range. The mandible

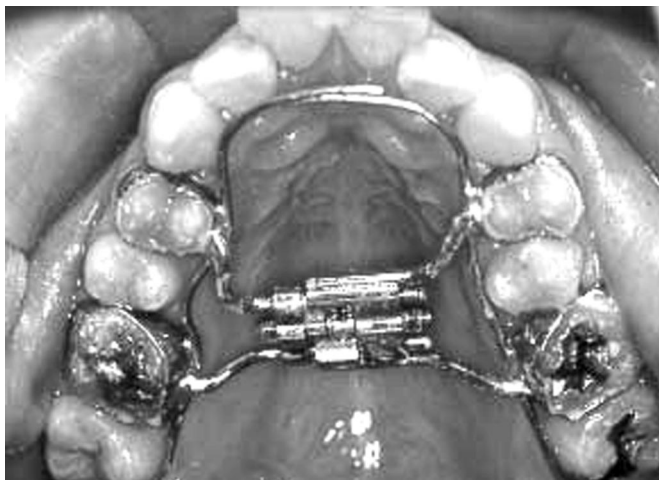


FIGURE 6. Rapid maxillary expansion appliance in place before the first operation.

exhibited a backward and downward rotation. The labiolingual inclinations of the maxillary and mandibular incisors were within the normal range.⁹

From these findings, this case was diagnosed as a skeletal open bite with a severely narrowed upper arch. Because of the severity of the skeletal open bite and narrow upper arch, a combined orthodontic-surgical approach was indicated to achieve acceptable results in esthetic and functional aspects. The treatment plan was defined as follows:

- Surgically assisted rapid maxillary expansion by the use of a Le Fort I maxillary corticotomy;
- Presurgical tooth alignment with multibracket appliances in both dentitions;

- Sagittal splitting ramus osteotomy to correct the backward and downward rotation and lateral shift of the mandible;
- Post-surgical orthodontic treatment with multibracket appliances; and
- Retention using lingually bonded retainers in both dentitions and a wrap-around type retainer on the upper arch.

Treatment procedures

A rapid maxillary expansion appliance was placed on the upper arch (Figure 6), and a Le Fort I maxillary corticotomy was performed. Before surgery, the maxillary dental arch widths were 30.7 mm at the canines and 46.1 mm at the first molars. One day after the surgery, lateral expansion of the maxilla was initiated by use of a jackscrew. The expansion rate was 1.0 mm/day, and the total amount of expansion was 10.0 mm (Figure 7). Model analysis demonstrated that the amount of expansion was 7.2 mm at the canines and 9.8 mm at the first molars.

Three months after the lateral expansion, new bone formation was confirmed in the midpalatal suture from the occlusal radiograph (Figure 8). Furthermore, judging from the lateral cephalograms, downward and forward growth of the mandible did not occur in the six-month period following the first visit (Figure 9). Five months after the lateral expansion, 0.018" × 0.025" edgewise appliances were placed and presurgical orthodontic treatment with multibracket appliances was initiated. A precision lingual arch appliance was placed on the maxillary first molars to maintain the result of maxillary expansion.

One year after initiating presurgical orthodontic treat-

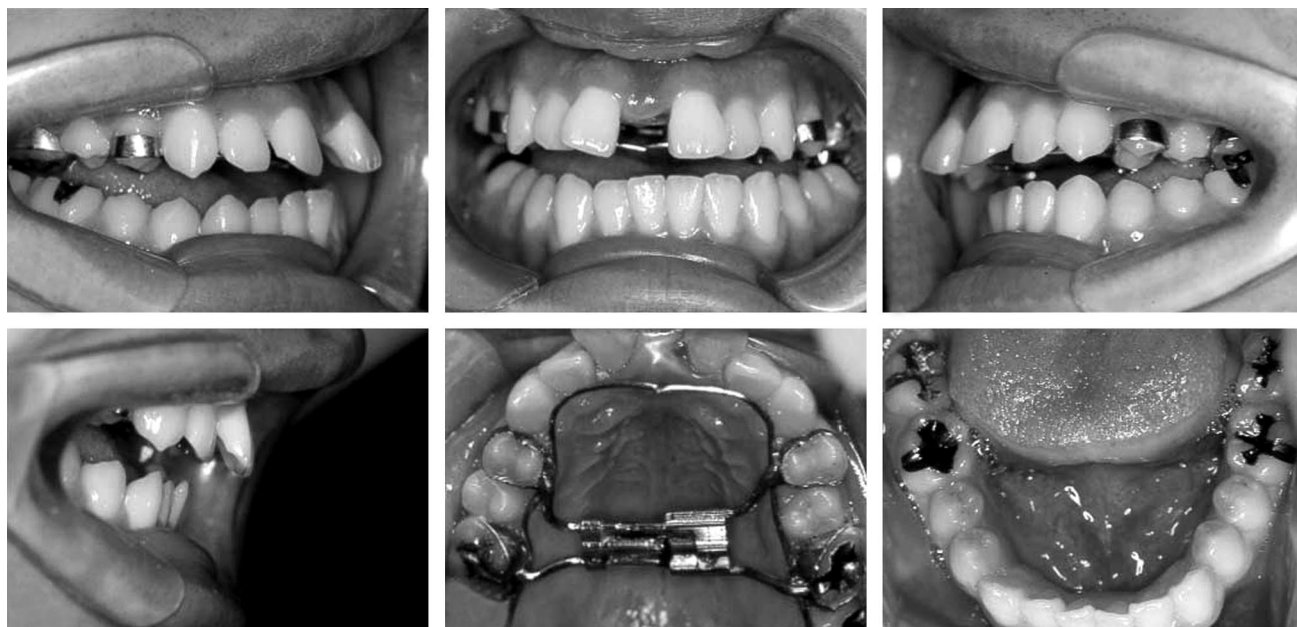


FIGURE 7. Intraoral photographs after lateral expansion of the upper arch (18y10m).

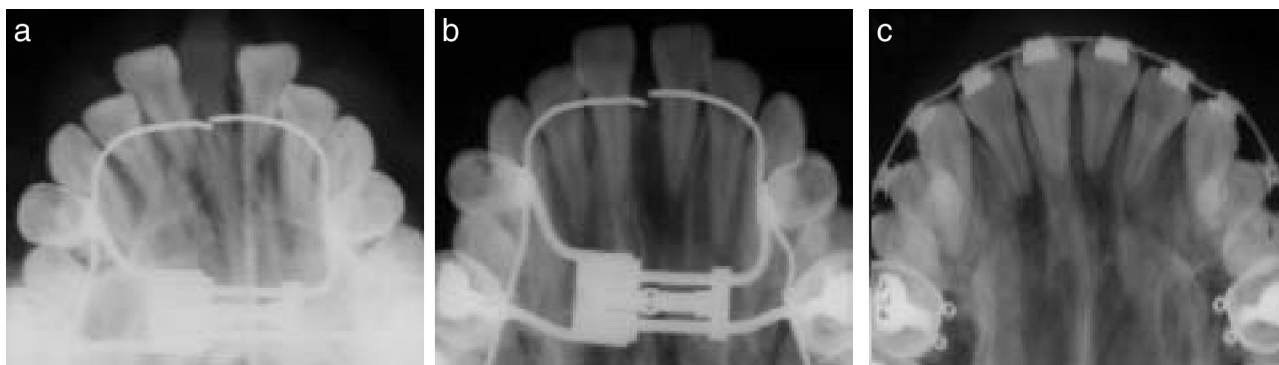

FIGURE 8. Occlusal radiographs during treatment: (a) Immediately after the maxillary expansion (18y10m); (b) 3 months after the maxillary expansion (19y0m); (c) 14 months after the maxillary expansion (20y0m).



FIGURE 9. Superimposition of mandible between first visit (solid line, 18y7m) and three months after the first operation (dotted line, 19y1m).

ment (Figure 10), a bilateral sagittal split ramus osteotomy (SSRO) was performed to correct the anterior open bite and the lateral shift of the mandible. The amount of mandibular setback was approximately 4.0 mm on the right side and -1.2 mm on the left side. Six transosseous screw-pins (18 mm, 20 mm) were used to fix the proximal and distal bone segments. Intermaxillary fixation was performed between the upper and lower arch wires for 15 days. After six months of post-surgical orthodontic treatment, an acceptable and stable occlusion was achieved and the multibracket appliances were removed. Immediately after the removal, a wrap-around type retainer was placed on the upper dentition and lingually bonded retainers were placed on both dentitions.

Treatment results

Overall facial balance was improved. The lower facial height was decreased and the lips showed less tension in a mouth-closed posture, although a slight facial asymmetry remained (Figure 11). Acceptable overjet and overbite and a Class I molar relationships were achieved (Figure 12). Basal and coronal arch widths of the upper dentition were within the normal range⁷ (Figure 13). The maxillary arch widths were 37.0 mm at the canines and 55.8 mm at the first molars. The relapse of expansion was 0.9 mm (12.5%) and 0.1 mm (1.0%) at the corresponding regions. Cephalometric analysis indicated desirable and expected skeletal and dentoalveolar changes (Figure 14). The mandibular plane and gonial angles were decreased, but still larger than normal. The mandible exhibited a backward and upward rotation.

One year and seven months after the second operation, an acceptable occlusion was maintained without recurrence of the anterior open bite, indicating a longterm stability of the occlusion. Cephalometric analysis indicated a slight counter-clockwise rotation of the mandible without any substantial relapse in the skeletal and dental relationships (Figure 15).

DISCUSSION

This patient exhibited a long face with a severely narrowed maxillary dental arch. Considerable palatal expan-



FIGURE 10. Mounted study model before the second operation (20y3m).

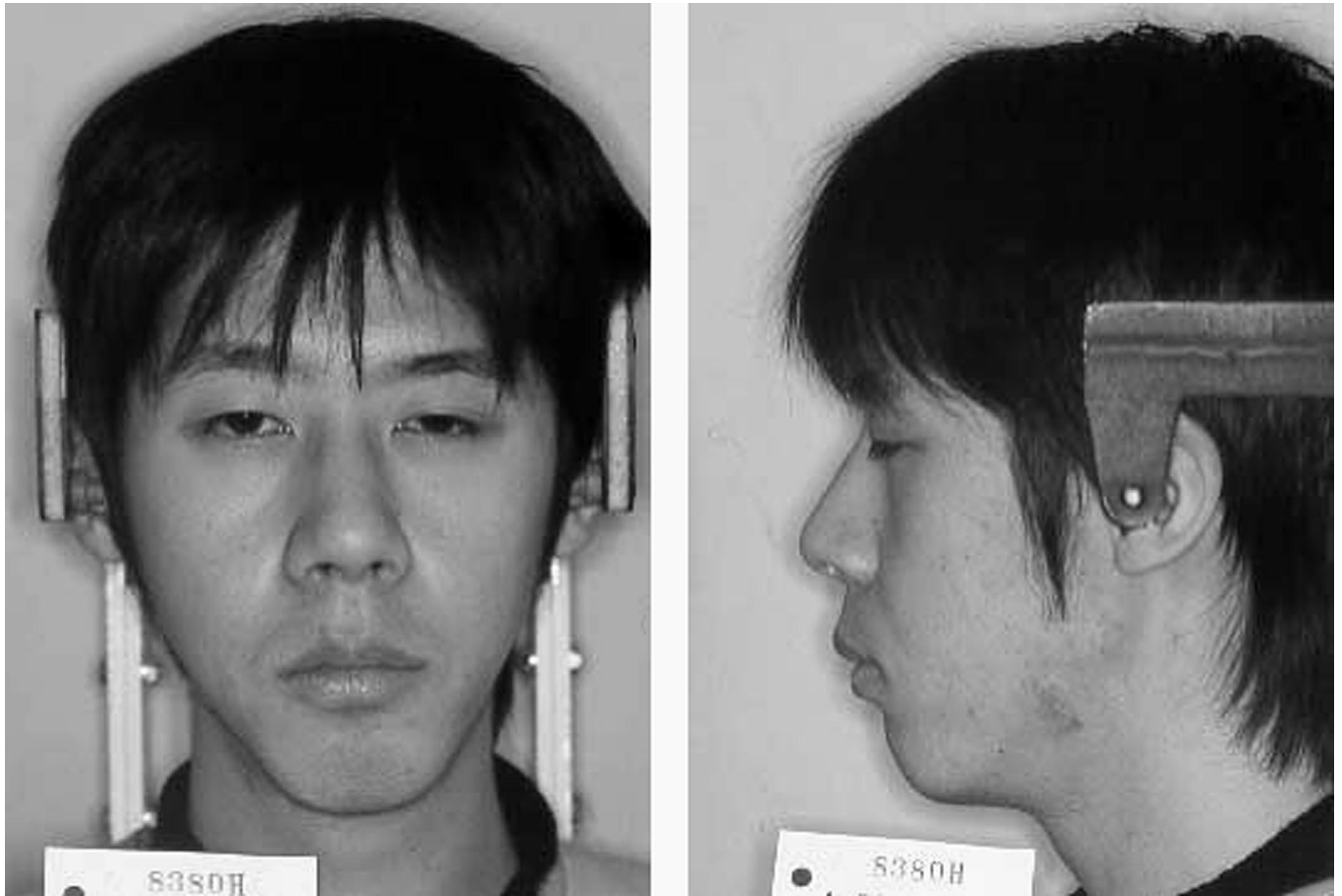

FIGURE 11. Facial photographs after treatment (20y10m).

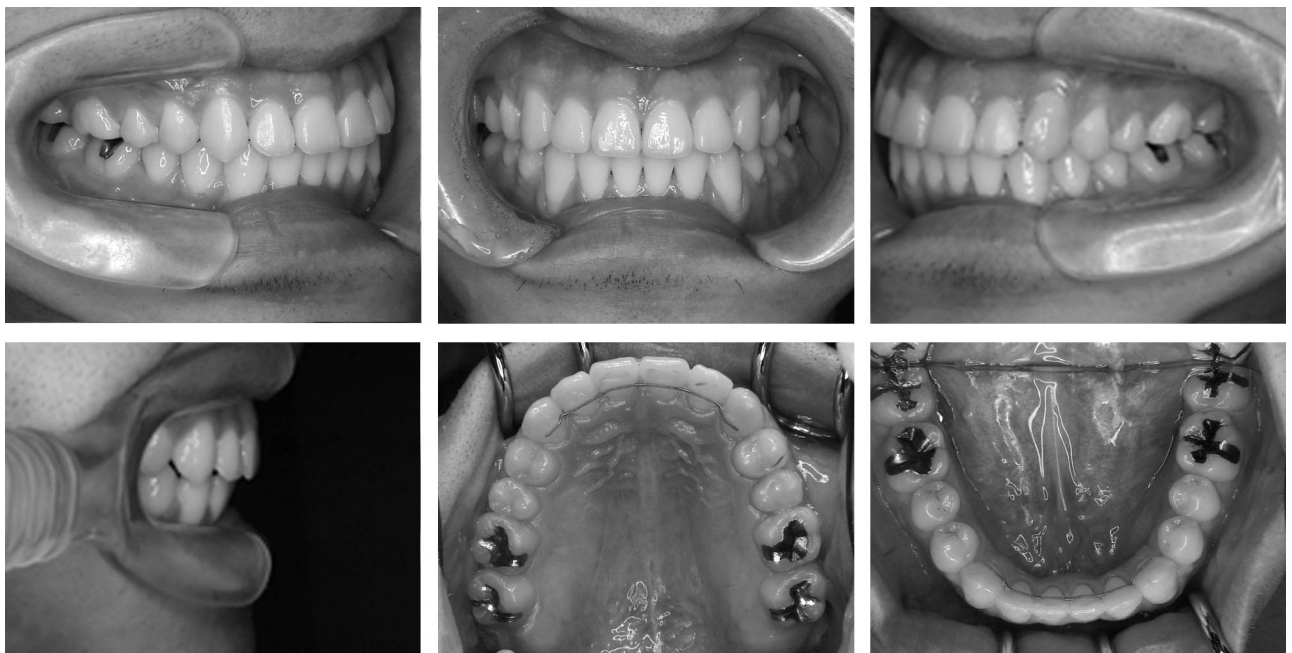

FIGURE 12. Intraoral photographs after treatment (20y10m).

ARCH FORM

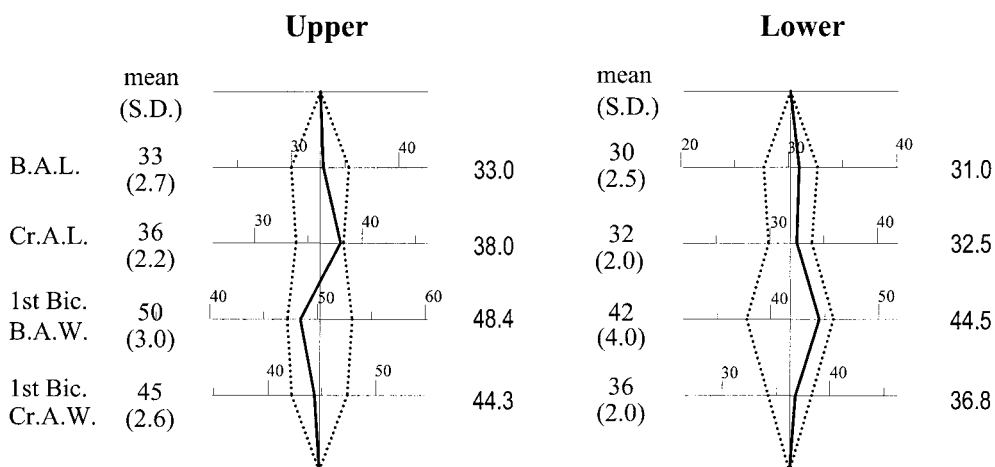


FIGURE 13. Basal and coronal arch widths after treatment (20y10m).

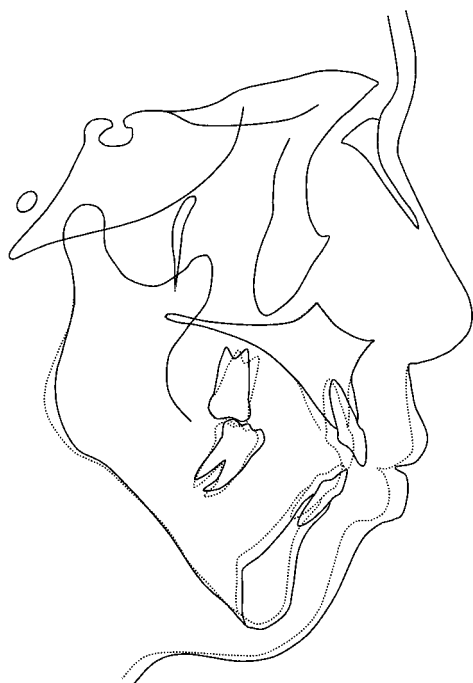

FIGURE 14. Superimposition of the lateral cephalogram tracings before (solid line, 18y7m) and after (dotted line, 20y10m) treatment.

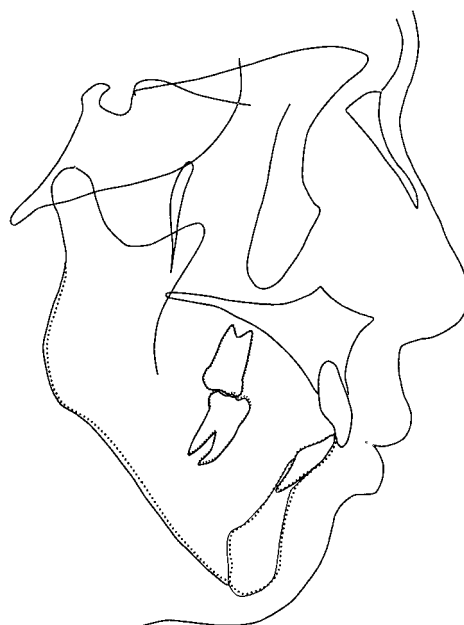


FIGURE 15. Superimposition of the lateral cephalogram tracings after treatment (solid line, 20y10m) and 1.5 years after the second operation (dotted line, 21y10m).

sion was indicated to improve the posterior crossbite. For an adult patient with a severe transverse maxillary deficiency, it is difficult to achieve a successful palatal expansion without osteotomy. On the other hand, a surgically assisted rapid maxillary expansion significantly reduces the resistance of the midpalatal suture to a mechanical expansion force and makes it easier to widen the palate.^{10,11}

A surgically assisted rapid maxillary expansion with a Le Fort I corticotomy has been proposed as an efficient approach for adult patients with transverse maxillary deficiencies.^{10,11} Adult patients with a long face syndrome have

a narrow maxilla with both transverse and vertical discrepancies in the maxillomandibular skeleton. They may be treated with either two-jaw surgery including multisegmental maxillary osteotomy or only one stage surgery.⁶ In this case the transverse and vertical problems can be improved by the upward and lateral positioning of the posterior segments of the maxilla. However, adequate bone thickness of 3 to 5 mm is required between teeth for a multi-segmental osteotomy,⁶ and if the space cannot be achieved, several teeth must be extracted to make space for an interdental osteotomy. Furthermore, the conventional Le Fort I osteotomy is much less complicated than a 2- or 3-piece Le

Fort I osteotomy and the incidence of complications would be reduced. With these considerations, a two-stage surgery including the Le Fort I corticotomy and the subsequent sagittal splitting ramus osteotomy were performed for the treatment of the present case.

The surgically assisted rapid maxillary expansion, as the first-stage surgery, produced 7.2 mm of expansion at the canines and 9.8 mm at the first molars. The relapse of the expansion was 0.9 mm (12.5%) and 0.1 mm (1.0%) at the corresponding regions two years after the maxillary expansion. The stability of surgically assisted rapid maxillary expansion was examined in previous studies.¹²⁻¹⁴ Bays and Greco¹² evaluated the relapse of palatal expansion after surgically assisted rapid maxillary expansion in 19 patients with a mean age of 30, and showed a mean relapse rate of 8.8% at the canines, and 7.7% at the molars. Stromberg and Holm¹³ and Pogrel et al¹⁴ also reported a mean relapse rate of 4% to 17% at the both canine and molar regions one to three years after surgically assisted maxillary expansion. The results in this case are similar to those of the previous studies.¹²⁻¹⁴

On the other hand, Phillips et al¹⁵ evaluated the stability of maxillary expansion with segmental Le Fort I osteotomies in a smaller cohort of 39 adult patients and reported a higher relapse rate of 49% at the second molars and 30% at the first premolars. The relapse rate was greater at the posterior teeth than at the anterior teeth and much higher than in previous studies.¹²⁻¹⁴ Furthermore, for the prevention of the relapse, they recommended over expansion at surgery, maintaining the occlusal splint for six weeks after surgery, and using a lingual arch wire or an auxiliary labial arch wire during the post-surgical orthodontic treatment. Thus, they suggested that surgically assisted rapid maxillary expansion appears to be the preferred procedure for adult patients with skeletal problems limited to the transverse dimension.¹⁵

Berger et al¹⁶ also examined and compared the dental and skeletal changes after orthopedic maxillary expansion and surgically assisted rapid maxillary expansion. They demonstrated that the surgical and nonsurgical techniques exhibited similar results, although the surgical group maintained a greater amount of expansion.

It is well accepted that even after the mechanical retention the expanded upper dental arch has a strong tendency to return to its original form.¹⁷ In the present case, we did not remove the rapid maxillary expansion appliance for five months after surgical expansion and used a lingual arch appliance throughout the post-surgical treatment. This case demonstrated a much more stable result than the previous report.¹⁵ The results of the present case indicate that surgically assisted rapid maxillary expansion is an efficient approach for achieving a secure expansion of the maxillary arch in adults. However, we recommend the use of a lingual arch appliance or auxiliary labial arch wire to maintain the molar width during post-surgical orthodontic treatment and

longterm observation of maxillary arch width after the retention.

The surgical correction of skeletal open bite is difficult and its treatment outcome is less stable than surgical cases without skeletal open bite. The stability of skeletal open bite correction is dependent upon favorable neuromuscular adaptation to maintain the mandible in the new position.¹⁸ From this viewpoint, a bimaxillary osteotomy or a Le Fort I intrusion osteotomy with mandibular autorotation is recommended for correction of skeletal open bites. Meanwhile, the correction of skeletal open bite by SSRO alone is considered to induce considerable relapse due to the clockwise rotation of the mandibular body with lengthening of the suprahyoid muscles.¹⁸ However, Oliveira and Bloomquist¹⁹ reported on the stability of the bilateral SSRO and rigid internal fixation in the closure of anterior open bite, and indicated that this surgical procedure was a relatively stable for the correction of anterior open bites. In the present case, the mandible was moved 4.0 mm backward with a counter clockwise rotation of 2.5 degrees at surgery. Therefore, the lengthening of suprahyoid muscles after surgery was slight, so that the stability of the open bite correction obtained was present 1.5 years after the second operation. In addition, Hoppenreijns et al²⁰ suggested that the considerable relapse of transverse dimension was associated with recurrence of open bite after surgery irrespective of the surgical procedure. In the present case, we conducted a careful observation and rigid retention of the transverse dimension of the maxilla throughout treatment, which may produce good stability of open bite correction.

REFERENCES

1. Subtelny JD, Sakuda M. Open-bite: diagnosis and treatment. *Am J Orthod.* 1964;50:337-358.
2. Proffit WR, Ackerman JL. Diagnosis and treatment planning in orthodontics. In: Graber TM, Vanarsdall RL, eds. *Orthodontics. Current Principles and Techniques.* 2nd ed. St Louis, Mo: Mosby Year Book Inc; 1994: 1-95.
3. Miyajima K, Iizuka T. Treatment mechanics in Class III open bite malocclusion with Tip Edge technique. *Am J Orthod Dentofacial Orthop.* 1996;110:1-7.
4. Handelman CS, Wang L, BeGole EA, Haas AJ. Nonsurgical rapid maxillary expansion in adults: report on 47 cases using the Haas expander. *Angle Orthod.* 2000;70:129-144.
5. Ladner PT, Muhl ZF. Changes concurrent with orthodontic treatment when maxillary expansion is a primary goal. *Am J Orthod Dentofacial Orthop.* 1995;108:184-193.
6. Proffit WR, White RP Jr. Crossbite and open-bite problems. In: Proffit WR, White RP Jr, eds. *Surgical-Orthodontic Treatment.* St Louis, Mo: Mosby Year Book Inc; 1991:550-584.
7. Otsubo J. A study of the tooth material in Japanese adults of normal occlusion, its relationship to coronal and basal arches [in Japanese]. *J Jpn Orthod Soc.* 1957;16:36-46.
8. Sassouni V. *Orthodontics in Dental Practice.* 1st ed. St Louis, Mo: Mosby; 1971:325-355.
9. Wada K, Otani S, Sakuda M. Morphometric analysis in maxillary protrusion. In: Yamauchi K, Sakuda M, eds. *Maxillary Protrusion* [in Japanese]. Tokyo: Ishiyaku Pub Co; 1989:95-130.

10. Alpern MC, Yurosko JJ. Rapid palatal expansion in adults with and without surgery. *Angle Orthod.* 1987;57:245–263.
11. Glassman AS, Nahigian SJ, Medway JM, Aronowitz HI. Conservative surgical orthodontic adult rapid palatal expansion: sixteen cases. *Am J Orthod.* 1984;86:207–213.
12. Bays RA, Greco JM. Surgically assisted rapid palatal expansion: an outpatient technique with long-term stability. *J Oral Maxillofac Surg.* 1992;50:110–115.
13. Stromberg C, Holm J. Surgically assisted, rapid maxillary expansion in adults. A retrospective long-term follow-up study. *J Craniomaxillofac Surg.* 1995;23:222–227.
14. Pogrel MA, Kaban LB, Vargervik K, Baumrind S. Surgically assisted rapid maxillary expansion in adults. *Int J Adult Orthodon Orthognath Surg.* 1992;7:37–41.
15. Phillips C, Medland WH, Fields HW Jr, Proffit WR, White RP Jr. Stability of surgical maxillary expansion. *Int J Adult Orthodon Orthognath Surg.* 1992;7:139–146.
16. Berger JL, Pangrazio-Kulbersh V, Borgula T, Kaczynski R. Stability of orthopedic and surgically assisted rapid palatal expansion over time. *Am J Orthod Dentofacial Orthop.* 1998;114:638–645.
17. Vardimon AD, Brosh T, Spiegler A, Lieberman M, Pitaru S. Rapid palatal expansion: Part 1. Mineralization pattern of the mid-palatal suture in cats. *Am J Orthod Dentofacial Orthop.* 1998;113:371–378.
18. Kahnberg KE, Widmark G. Surgical treatment of the open bite deformity. Surgical correction of combined mandibular prognathism and open bite by oblique sliding osteotomy of the mandibular rami. *Int J Oral Maxillofac Surg.* 1988;17:45–48.
19. Oliveira JA, Bloomquist DS. The stability of the use of bilateral sagittal split osteotomy in the closure of anterior open bite. *Int J Adult Orthodon Orthognath Surg.* 1997;12:101–108.
20. Hoppenreijts TJ, Freihofer HP, Stoelinga PJ, Tuinzing DB. Stability of orthodontic-maxillofacial surgical treatment of anterior open bite deformities [in Dutch]. *Ned Tijdschr Tandheelkd.* 2001;108:173–178.