

Case Report: Orthodontic and Dentofacial Orthopedic Considerations in Apert's Syndrome

R. David Ryneerson, DDS, MS

Abstract: Apert's syndrome is a developmental malformation characterized by: craniosynostosis, a cone-shaped calvarium, midface hypoplasia, pharyngeal attenuation, ocular manifestations, and syndactyly of the hands and feet. The prodromal characteristic for the typical craniofacial appearance is early craniosynostosis of the coronal suture, the cranial base, and an agenesis of the sagittal suture. These craniofacial characteristics predispose the patient to maxillary transverse and sagittal hypoplasia with concomitant dental crowding, a maxillary pseudocleft palate, and a skeletal and dental anterior open bite. This is a case report of an Apert's syndrome patient with a discussion of the orthodontic and dentofacial orthopedic considerations that influenced the treatment plan. (*Angle Orthod* 2000;70:247-252.)

Key Words: Apert's syndrome; Craniosynostosis; Midface hypoplasia; Pseudocleft palate

INTRODUCTION

Amongst the group of developmental malformations characterized by craniosynostosis, Apert's syndrome or acrocephalosyndactyly is distinct in that Apert's exhibits a cone-shaped head along with syndactyly or webbing of the hands and feet.¹ According to Cohen^{2,3} the incidence of Apert's syndrome is about 15 per 1,000,000 live births. The inheritance of Apert's syndrome is autosomal dominant with the locus of a mutation of *FGFR2* on chromosome 10q.^{1,4} Suture progenitor cells with fibroblast growth factor receptor's (*FGFR2*) that have undergone a mutation cannot transduce signals from extracellular fibroblast growth factors (FGFs). Therefore these cells do not receive the signal to produce the necessary fibrous material essential for a normal calvarial suture.⁴ In addition, histology reveals that normal calvarial sutures are, in part, fibrous joints between intramembranous bones.⁵

Typical clinical characteristics of Apert's syndrome

Craniosynostosis. The newborn infant with Apert's syndrome exhibits a fused coronal suture and an agenesis of the sagittal and metopic sutures which results in a wide defect extending from the glabella to the posterior fonta-

nelle. Within 2 to 4 years of age the sagittal and metopic suture defect becomes obliterated by the coalescence of interspersed bony islands, but without the formation of a proper suture.¹ Additionally, the spheno-occipital and spheno-ethmoidal synchondroses and the fronto-ethmoidal suture fuse early, resulting in a severely shortened posterior cranial base and a relatively short anterior cranial base with a resultant hypoplastic midface.⁶

Midface hypoplasia. The calvarial coronal synostosis and the sagittal and metopic suture agenesis coupled with the early synostosis of the cranial base result in a hypoplastic midface and a vertically accentuated craniofacial complex. Consistent with the observation of midface hypoplasia, the maxilla also exhibits a transverse hypoplasia and pseudocleft palate along with its hypoplastic sagittal position and its anteriorly tipped up palatal plane.⁶

Typical dental findings. The most readily observed dental malrelationships are a severe maxillary anterior open bite and a severely crowded and retrusive maxillary arch due to the constricted secondary palate. According to Avantaggiato et al,⁶ the mandibular skeletal and dental measurements in their sample seemed to indicate a smaller than normal and retrognathic mandible. As a result, dental crowding is commonly present in the mandibular arch. The skeletal Class III, therefore, is not the result of a prognathic mandible, but is due to the sagittal maxillary hypoplasia.

Pharyngeal attenuation. The characteristic pharyngeal attenuation appears to be partly the result of early synostosis of the spheno-occipital synchondrosis. This precipitates an especially short posterior cranial base with a resultant reduction of pharyngeal height.⁶ The nasal height and depth are also decreased.⁷ Cohen¹ observed that cervical fusions occur in about 68% of Apert's patients which

Private Practice in Moreno Valley, California and Associate Professor of Orthodontics, Department of Orthodontics, School of Dentistry, Loma Linda University, Loma Linda, California.

Corresponding Author: R. David Ryneerson, DDS, MS, 11401 Heacock Street, Suite 300, Moreno Valley, CA 92557 (e-mail: dryneerson@sd.llu.edu).

Accepted: October 1999. Submitted: August 1999.

© 2000 by The EH Angle Education and Research Foundation, Inc.

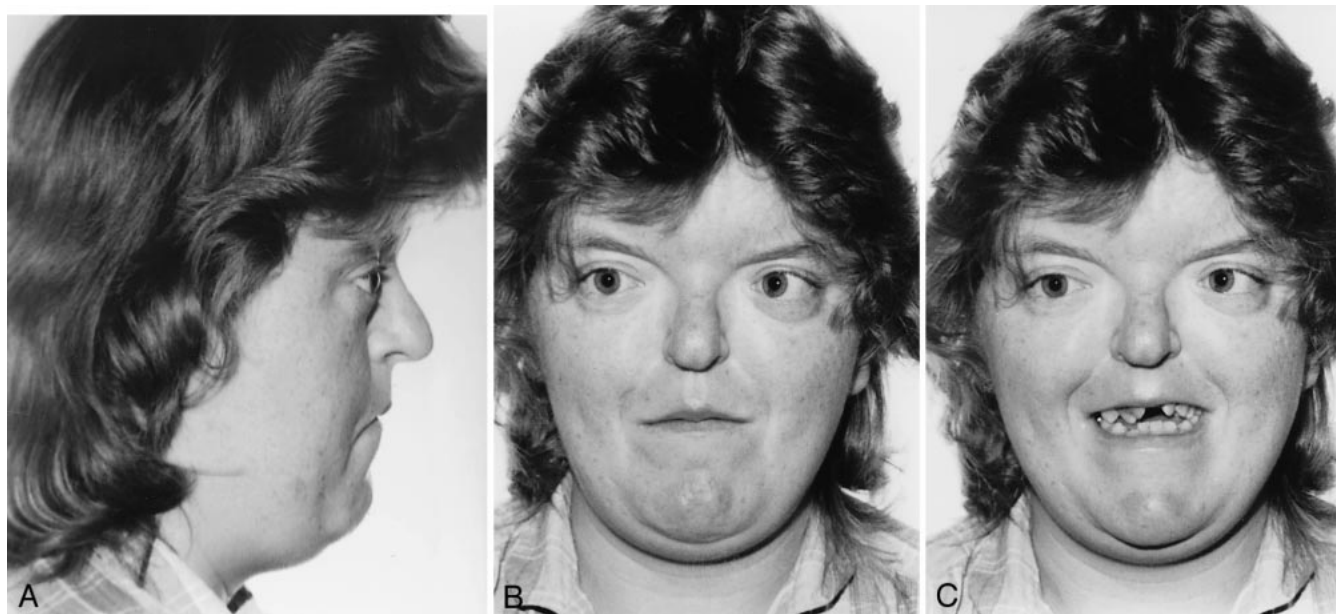

FIGURE 1. Pretreatment patient records. (A) Lateral face. (B) Frontal face. (C) Smiling frontal face. (D) Maxillary occlusal view. (E) Mandibular occlusal view. (F) Panoramic radiographic view. (G) Right-side lateral dental occlusion. (H) Left-side lateral dental occlusion. (I) Frontal dental occlusion.

minimizes neck flexibility. The nasopharyngeal and oropharyngeal attenuation coupled with a potentially inflexible neck compound an already problematic airway.⁸ It becomes readily apparent that Apert's individuals become mouth breathers of necessity due to a reduced airway patency with the subservient resultant issue of an anterior open bite.

Ocular manifestations. From an ophthalmology point of view, the Apert's patient exhibits ocular proptosis due to midface hypoplasia which renders shallow orbits. Apert's ocular features also include hypertelorism.⁶

Syndactyly of hands and feet. One of the key features of Apert's syndrome (acrocephalosyndactyilia) is syndactyly or webbing of the fingers and toes. The digits are usually separated surgically, however, there can be limited mobility of some fingers due to progressive ossification of interphalangeal joints due to segmentation of the embryonic phalanges.¹

CASE REPORT

A 21-year-old Caucasian female in good general health presented with the typical skeletal and dental findings of Apert's syndrome, including severe maxillary and mandibular dental crowding, ectopic teeth, anterior open bite, poor oral hygiene, and carious lesions (Figure 1). Her face had a cephalometric dolichofacial pattern and she had a Class III right canine, Class I left canine, an anterior open bite with partial anterior and posterior crossbite, and severe maxillary and mandibular arch length discrepancies. Her maxilla showed sagittal and transverse hypoplasia with a pseudocleft palate; her mandible was within normal limits

in the transverse and sagittal planes. The maxillary denture had moderate protrusion, palatally placed maxillary right lateral incisor and left and right second premolars, facially placed maxillary left central incisor, and severe dental crowding and carious lesions. The mandibular denture had impacted left and right second and third molars and severe dental crowding and carious lesions. She had an overbite of -10 mm on the anterior open bite, and an overjet of $+8$ mm due to ectopia and rotation of the left and right central incisors. The ALD showed a -12 mm mandibular arch length discrepancy. The lower midline was essentially in line with the cupid's bow of the upper lip; the upper midline was to the right. Her facial esthetics were as follows: LL/EP = -8 mm; straight profile; hypoplastic infraorbital and malar regions; severe anterior open bite, exophthalmia, hypertelorism, frontal bossing, some strain with lip competence.

Treatment Objectives

The treatment objectives were: (1) improve the patients oral hygiene and periodontal health; (2) restore the carious teeth where possible and extract the nonrestorable carious teeth; (3) alleviate the maxillary and mandibular dental crowding and level and align teeth; (4) perform multisegmental LeFort I maxillary osteotomy to correct the skeletal transverse discrepancy and skeletal open bite; (5) obtain right and left Class I canine with coincident midlines and ideal overbite and overjet; (6) obtain right Class III molar and a Class I relationship with the left buccal segments of teeth; and (7) perform an autogenous bone graft from the

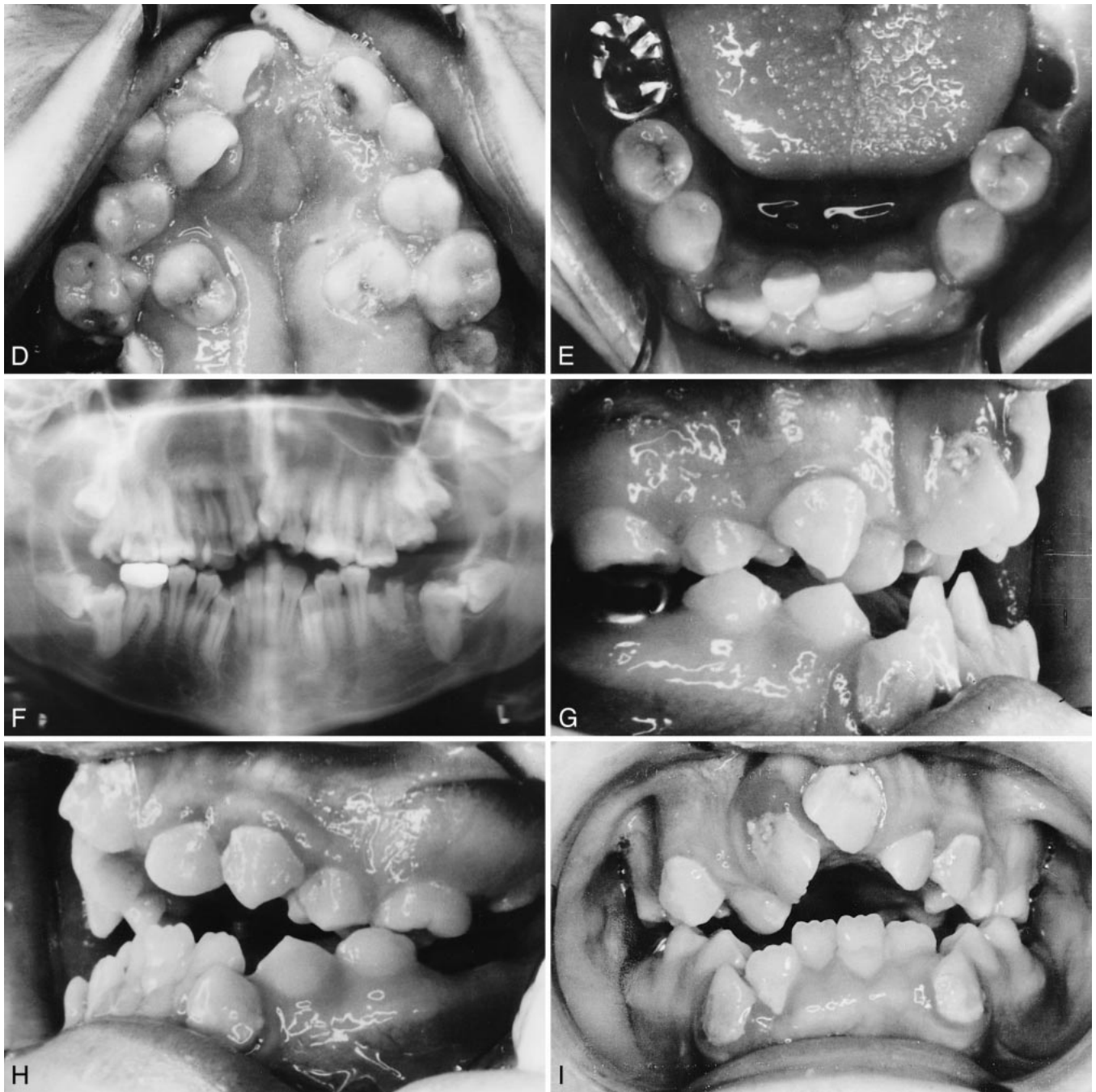


FIGURE 1. Continued.

iliac crest to the infraorbital, malar, and nasal alar base regions to aid in masking the appearance of midface hypoplasia.

Treatment Plan

1. Pre-orthodontic restorative and periodontal therapy to enhance her oral health.
2. An orthognathic surgical consult due to her severe dentoskeletal discrepancies.
3. Extract maxillary second molars and mandibular left first molar due to nonrestorable caries; extract the lower right first premolar due to arch length deficiency; extract the lower third molars due to horizontal bony impaction.
4. Band and bond both arches using .018" × .025" edge-wise appliances; distalizing the maxillary first molars to

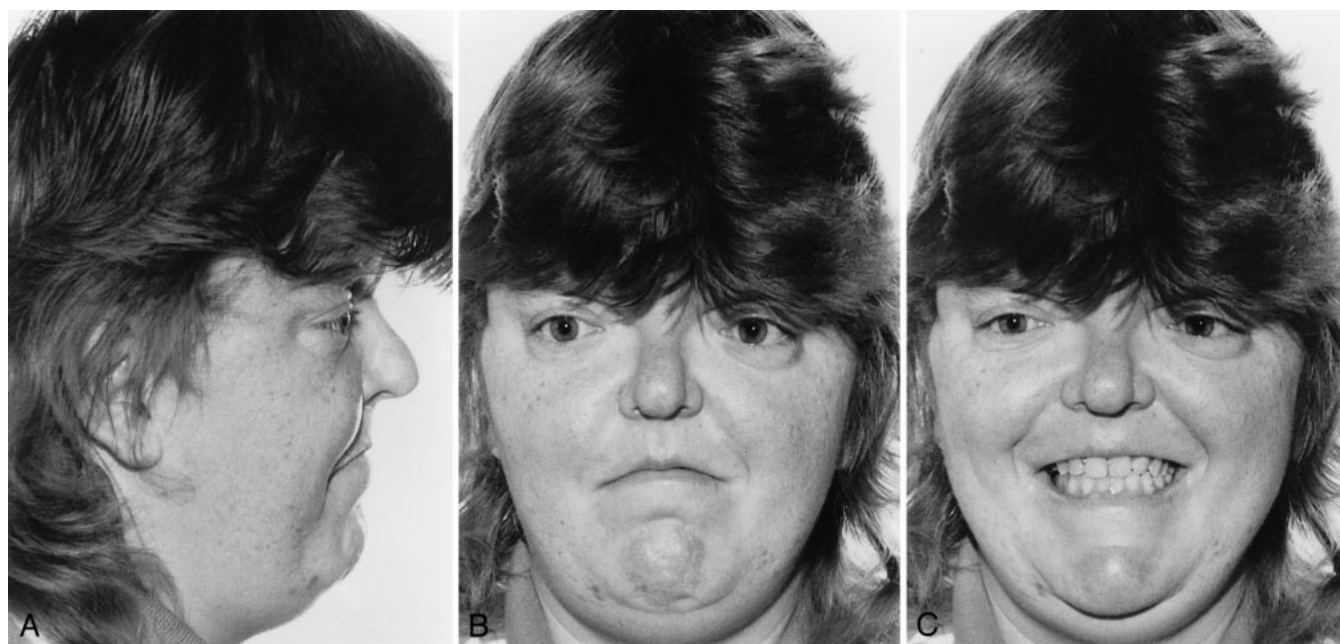

FIGURE 2. Post-treatment patient records. (A) Lateral face. (B) Frontal face. (C) Smiling frontal face. (D) Maxillary occlusal view. (E) Mandibular occlusal view. (F) Panoramic radiographic view. (G) Right side lateral dental occlusion. (H) Left-side lateral dental occlusion. (I) Frontal dental occlusion.

create space for the second premolars; create space for mandibular canines and maxillary incisors; level and align both arches.

5. After leveling and aligning, a multisegmental LeFort I maxillary osteotomy to address the transverse, sagittal and coronal skeletal discrepancies.
6. Following orthognathic surgery; continued orthodontics to harmonize the occlusion.
7. Retain using maxillary and mandibular Hawley-type retainers.

Treatment Progress

Treatment was initiated January 5, 1988, by banding and bonding using a fully programmed .018" × .025" edgewise bracket appliance. Early in the treatment, the maxillary second molars and the mandibular left first molar were extracted due to extensive carious lesions. In addition, the mandibular third molars and mandibular right first premolar were also extracted. The maxillary first molars were distalized using open coil springs, followed by bracketing of the lingually placed second premolars and positioning them in the maxillary arch. Both arches were leveled and aligned and all spaces were closed. Periodic progress records were obtained to evaluate the orthodontic treatment prior to orthognathic surgery. After 43 months of presurgical orthodontics, the patient underwent a LeFort I multisegmental maxillary osteotomy, to alleviate the transverse, sagittal, and coronal skeletal discrepancies. At the time of orthognathic surgery an autogenous bone graft was performed us-

ing the iliac crest as the donor site and the infraorbital, malar and nasal alar bone regions as the recipient site. The postsurgical orthodontics took about 15 months and included elastomeric materials to close spaces in the sagittal plane and to improve the occlusion in the coronal plane. The total treatment time was 4 years and 10 months.

RESULTS

This patient presented with acrocephalosyndactylia and a successful result was dependent upon a combined orthodontics and orthognathic surgery. The multisegmental LeFort I maxillary osteotomy performed by Dr Dale Stringer of Riverside, California, allowed for an orthopedic correction of the transverse discrepancy. The LeFort I also corrected the coronal discrepancy by the impaction of the maxilla posteriorly and the extrusion of the segmentalized premaxilla anteriorly. This procedure facilitated the correction of the anterior skeletal and dental open bite, and allowed for the autorotation of the mandible. The initial anterior open bite, which was greater than 1 cm, was resolved to a vertical overlap of +3 mm (Figure 2). The maxillary and mandibular incisors finished within normal limits to A/Po, with +3 mm and -1 mm, respectively. The interincisal angle was changed from a relatively acute 114° to a more normal 127°. The mandibular plane angle changed from 27° to 26° due to the maxillary impaction that allowed for the very slight autorotation of the mandible. The lower face height changed from a pre-

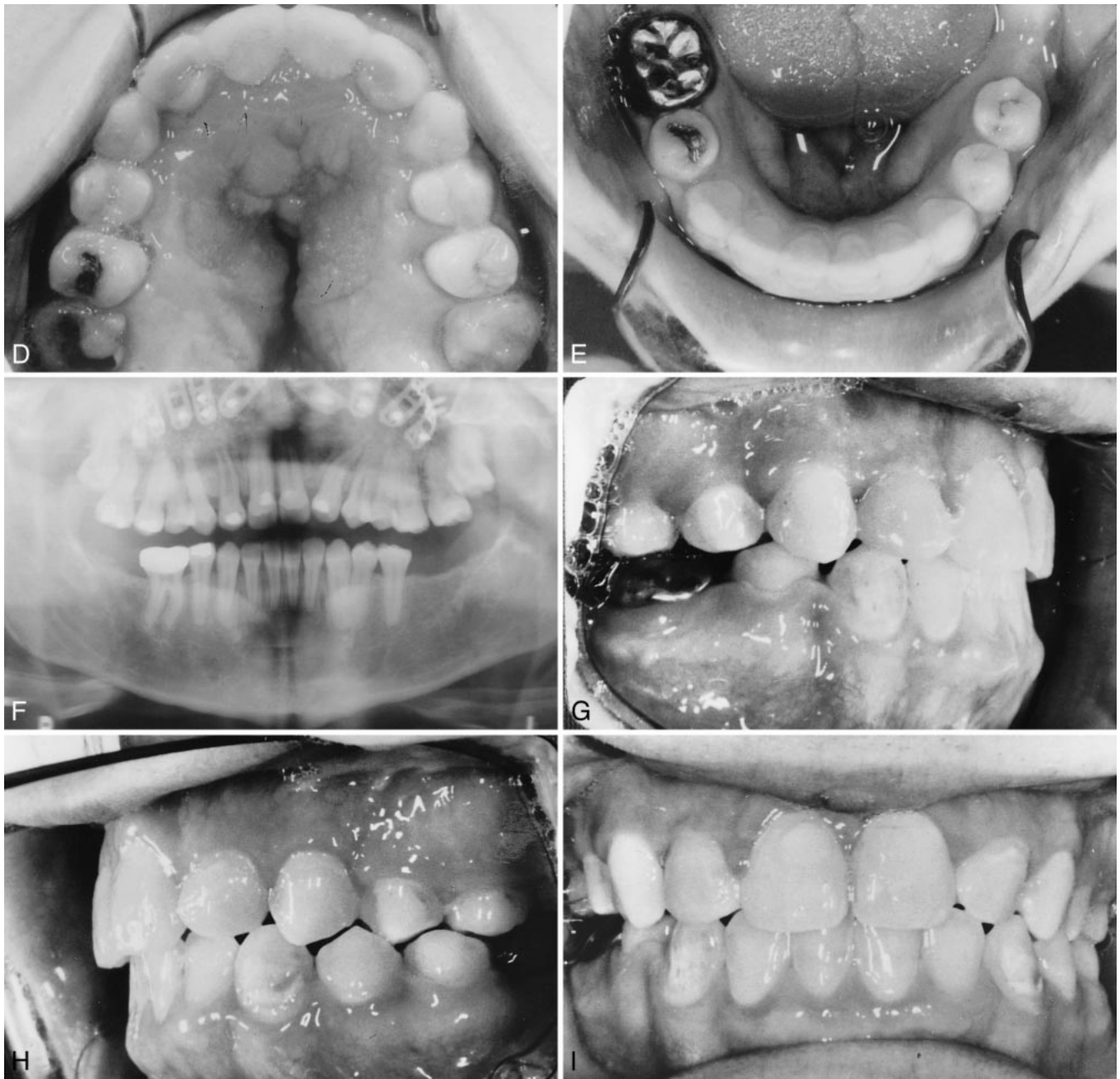


FIGURE 2. Continued.

treatment value of 70° to a posttreatment value of 63° (Figure 3).

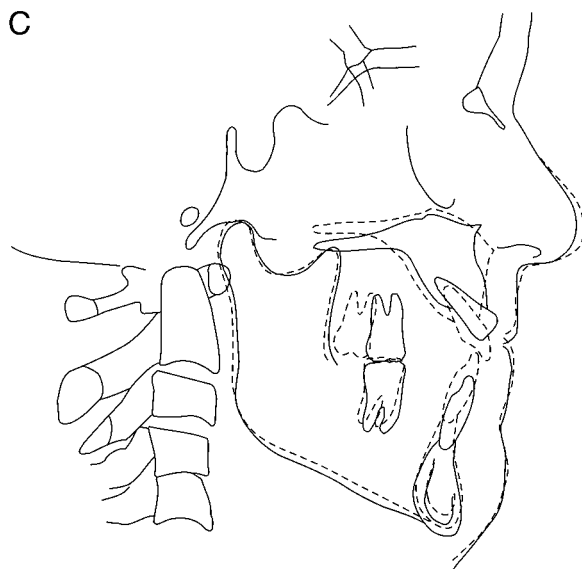
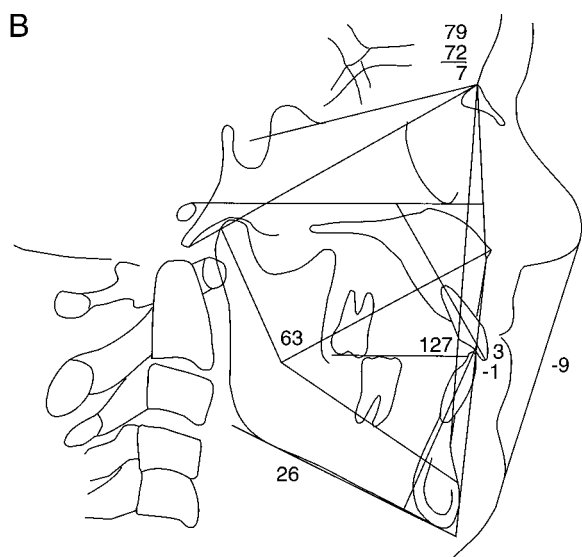
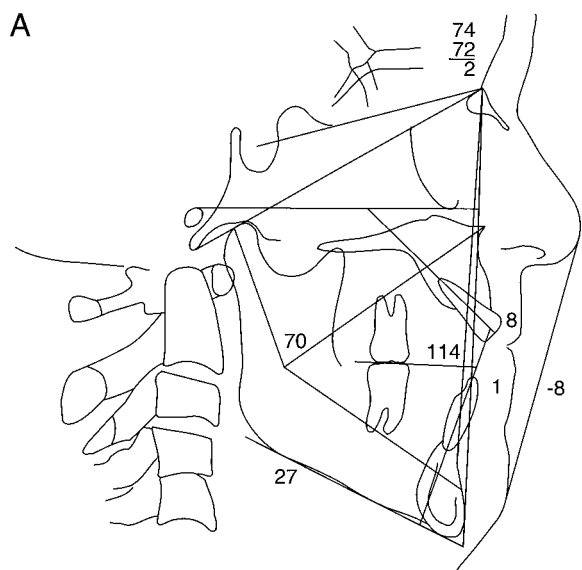
The occlusion immediately after appliance removal exhibited a planned Class III molar on the right. The left buccal segments were in Class I, however, the mandibular left first molar was extracted due to extensive dental caries. The maxillary canines were Class I and the incisor midlines were coincident with each other and with the cupid's bow of the upper lip.

The autogenous bone graft from the patient's iliac crest to the infraorbital, malar and nasal alar base regions mini-

mized the exophthalmic and midface hypoplasia appearance. The patients overall dentofacial appearance and masticatory function was improved.

Maxillary and mandibular Hawley-type retainers were placed immediately after orthodontic treatment was completed.

This case study demonstrates that a patient with Apert's syndrome can benefit by a combined orthodontic and orthognathic surgical treatment plan designed to aid in ameliorating some of the untoward affects of this syndrome. The resultant improvement in appearance and function of



this patient's dentoskeletal structures, along with her pleasant smile, attests to the efficacy of a combined orthodontic and orthognathic surgical treatment plan.

REFERENCES

1. Cohen MM Jr, Kreiborg S. An updated pediatric perspective on the Apert syndrome. *Am J Dis Child.* 1993;147:989-993.
2. Cohen MM Jr, Kreiborg S. New indirect method for estimating the birth prevalence of the Apert syndrome. *Int J Oral Maxillofac Surg.* 1992;21:107-109.
3. Cohen MM Jr, Kreiborg S, Lammer EJ, et al. Birth prevalence study of the Apert syndrome. *Am J Med Genet.* 1992;42:655-659.
4. Wilkie AO, Wall SA. Craniosynostosis: novel insights into pathogenesis and treatment. *Current Opin Neurol.* 1996;9:146-152.
5. Cohen MM Jr. Sutural biology and the correlates of craniosynostosis. *Am J Med Genet.* 1993;47:581-616.
6. Avantaggiato A, Carinci F, Curioni C. Apert's syndrome: cephalometric evaluation and considerations on pathogenesis. *J Craniofac Surg.* 1996;7:23-31.
7. Van der Meulen J, Mazzola R, Sticker M, et al. Classification of craniofacial malformation. In: Stricker M, van der Meulen J, Raphael B, et al, eds. *Craniofacial Malformations.* Edinburgh: Churchill Livingstone; 1990:254-258.
8. Kreiborg S, Barr M Jr, Cohen MM Jr. Cervical spine in the Apert syndrome. *Am J Med Genet.* 1992;43:704-708.

←
FIGURE 3. Tracings of cephalometric radiographs. (A) Tracing of pretreatment radiograph. (B) Tracing of post-treatment radiograph. (C) Pretreatment and post-treatment tracings superimposed.