

# Long-Term Prognosis of BSSO Mandibular Relapse and its Relation to Different Facial Types

Kenji Yoshida, DDS, PhD<sup>a</sup>; Gladys A. Rivera, DDS<sup>b</sup>; Naoko Matsuo, DDS<sup>a</sup>;  
Makoto Takaishi, DDS<sup>a</sup>; Hiroshi Inamoto, DDS, PhD<sup>c</sup>; Kenichi Kurita, DDS, PhD<sup>a</sup>

**Abstract:** The bilateral sagittal split osteotomy (BSSO) has evolved into an effective and preferred surgical procedure for mandibular setbacks. As with all surgical procedures designed to setback the mandible, relapse occasionally occurs after BSSO procedures. Several factors have been suggested to play a contributory role in this relapse. The present study was performed to determine the stability of the mandibular position over the course of long-term observation. Different facial patterns that could potentially be used as predictors of relapse were examined. The study included cases of skeletal mandibular prognathism, with the patient in each case having undergone surgical correction involving a BSSO at least 5 years prior to the study. Lateral cephalograms were analyzed in order to classify facial patterns. Angular and linear cephalometric measurements, consisting of SN-Pogonion angle, SN-occlusal plane angle, and Pogonion depth and height, were compared at 1 year postoperatively and at the long-term follow-up. A significant correlation between facial type and relapse pattern was confirmed at the long-term assessment of prognosis. (*Angle Orthod* 2000;70:220–226.)

**Key Words:** Long-term prognosis; Bisagittal splitting osteotomy; Relapse; Rickett's facial pattern

## INTRODUCTION

Intraoral sagittal splitting osteotomy of the mandibular ramus was first introduced by Trauner and Obwegeser<sup>1</sup> in 1957 and the technique is now widely used to correct mandibular prognathism. Modifications for controlling the segments and the methods of fixation are well documented.<sup>2–4</sup> However, variations in skeletal stability following mandibular setback procedures remains to be clarified.<sup>5</sup>

The etiology of relapse following mandibular bilateral sagittal split osteotomy (BSSO) is influenced by multiple factors. These factors include the action of paramandibular connective tissue such as muscles in the periosteum, the magnitude of setback at surgery and the method of bone fixation. In addition, Kobayashi et al<sup>6</sup> pointed out the importance of proper intermaxillary fixation (IMF) in order to obtain stable occlusion after surgery. Martis<sup>7</sup> reported a 1

mm or less relapse in many of his patients which he attributed to conservative reflection of soft tissues and reduced disturbance of the pterygomandibular sling.

Moreover, altered activity and the resulting failure of masticatory muscles to adapt to the repositioned segments has also been thought to contribute to relapse. Continued condylar growth<sup>8</sup>, rotation or distraction of the proximal segment during fixation causing an alteration in the position of the condyle,<sup>9,10</sup> and positional changes of the tongue due to reduced space after surgery have also been cited.<sup>11</sup>

In the present study, mandibular relapse was examined in relation to different facial patterns. Rickett's facial patterns were used as the reference for classifying facial types into 3 fundamental patterns: dolico-facial, mesio-facial and brachio-facial or a subtype (Figures 1 and 2).<sup>12–13</sup>

Based on the results of these analyses, we attempted to determine typical patterns during long-term follow-up and whether a relationship exists between facial patterns and mandibular relapse.

## MATERIALS AND METHODS

Fifteen patients were enrolled in the study, including 2 males and 13 females in whom skeletal Class III malocclusion was corrected in combination with orthognathic surgery. All patients were available for long-term follow up at the First Department of Oral & Maxillofacial Surgery, School of Dentistry, Aichi-Gakuin University. Open bites and asymmetrical cases were excluded from the study.

<sup>a</sup> First Department of Oral and Maxillofacial Surgery, School of Dentistry, Aichi-Gakuin University, Nagoya 464–8651, Japan.

<sup>b</sup> University of East Philippines. Formerly visiting researcher, First Department of Oral and Maxillofacial Surgery, School of Dentistry, Aichi-Gakuin University, Nagoya 464–8651, Japan.

<sup>c</sup> Department of Oral and Maxillofacial Surgery, Tajimi Municipal Hospital, Tajimi 507–0042, Japan.

Corresponding author: Kenji Yoshida, DDS, PhD, 2–11 Suemori-dori Chikusa-ku Nagoya 464–8651, Japan (e-mail: kenji@dpc.aichi-gakuin.ac.jp).

Accepted: January 2000. Submitted: October 1999.

© 2000 by The EH Angle Education and Research Foundation, Inc.

## FACIAL PATTERN

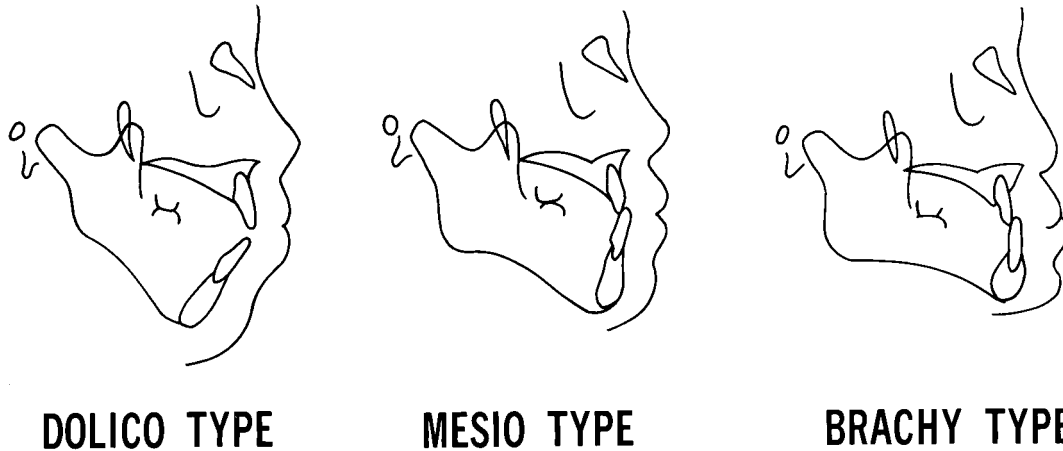
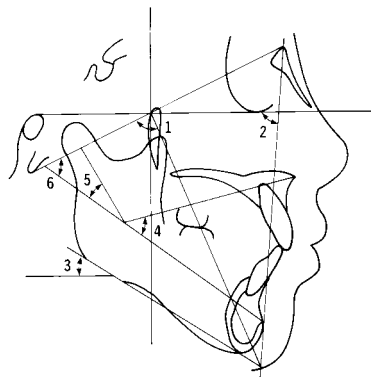


FIGURE 1. Facial pattern classification of 15 cases.

### MEASUREMENTS OF HARD AND SOFT TISSUE IN LATERAL CEPHALOGRAMS



- 1 FACIAL AXIS
- 2 FACIAL DEPTH
- 3 MANDIBULAR PLANE ANGLE
- 4 LOWER FACIAL HEIGHT
- 5 MANDIBULAR ARC
- 6 TOTAL FACIAL HEIGHT

FIGURE 2. Measurements of hard and soft tissue in lateral cephalograms.<sup>12,13</sup> Each parameter is measured as the size of the angle.

Mean age at the time of surgery was 22 years and 1 month for males and 20 years and 9 months for females. All patients ranged in age from 17 to 29 years.

The same orthodontist performed pre- and postoperative orthodontic treatment for all cases. Two experienced surgeons performed a conventional BSSO mandibular setback following the same surgical technique with patients under general anesthesia. Intraosseous wire fixation was used to

secure the proximal and distal segments of the mandible. An IMF with steel wires and acrylic occlusal splints was kept in place for 7 weeks in all cases.

The patients were given a chin cap to wear at night for 6 months to pull the mandible upward and backward with a force of 300 to 400 gr. The acrylic occlusal splints were removed at the time of the IMF removal. Postoperative orthodontic treatment was complete within 1 year and a few months in all cases.

A few experienced radiotechnicians, trained in standardized techniques, exposed cephalograms from a lateral view using the same equipment. For this procedure, the patient's teeth were in occlusion, the lips in a relaxed position, and the midsagittal plane was parallel to the film. The focal distance was 170 cm and the distance between the film and the midsagittal plane was 15 cm.

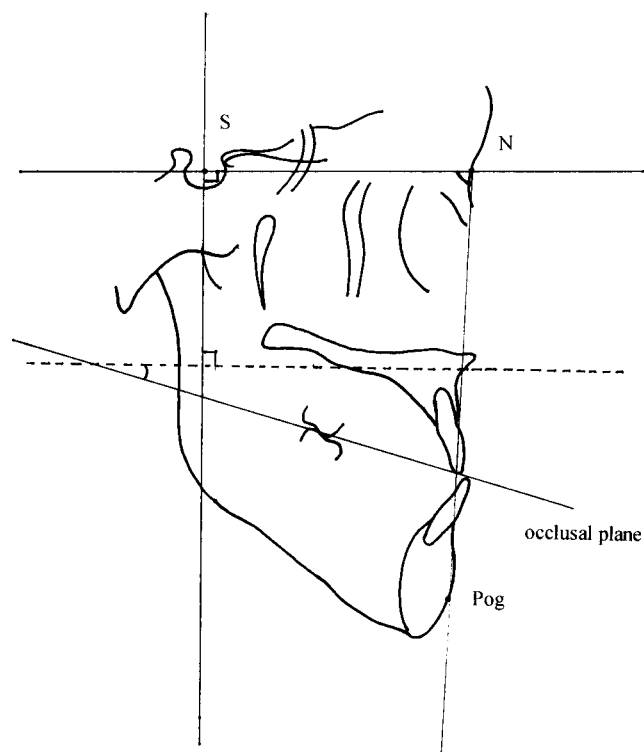
Cephalometric data were obtained preoperatively, immediately after surgery, 1 year postoperatively, and during the 5- to 12-year follow-up period. The average follow-up period was 10.3 years.

#### Classification of the fifteen cases into different facial patterns

Based on analysis of preoperative lateral cephalograms, each case was classified according to Ricketts' method of facial types into 3 fundamental patterns: doliofacial, mesiofacial, and brachiofacial or a subtype (Figures 1 and 2).<sup>12-13</sup> All of the patients were Japanese so the standard Japanese data for Ricketts' method, reported by Nezu et al,<sup>14</sup> were used for the classification of facial types.

#### Examination of mandibular relapse in relation to different facial patterns

In this study, additional parameters related to angular and linear cephalometric measurements were identified on lat-



**FIGURE 3.** Angular and linear measurement points to evaluate changes in the mandibular position: SN-Pogonion angle, Pogonion depth, Pogonion height, and SN-occlusal plane angle.

eral radiographs to evaluate the mandibular position: (1) SN-Pogonion angle—the angle between the sella-nasion line and the nasion-Pogonion line, (2) SN-occlusal plane angle—the angle between the sella-nasion line and the occlusal plane, (3) Pogonion height—the perpendicular distance of Pogonion to the sella-nasion line, and (4) Pogonion depth—the perpendicular distance from Pogonion to a perpendicular to the nasion-sella line at sella (Figure 3).

All cephalometric tracings and measurements were performed by a single examiner who traced each radiograph on an acetate sheet (Orthotrace, Rocky Mountain/ Morita, Osaka Japan). The tracings were placed on a Summagraphic digitizing tablet, with a resolution of 0.1 mm, and digitized. All measurements were made using the Cephalo Analyser™ Software System (Yasunaga Laboratory Computer System/Orthodontic Processing, Fukui, Japan).

Measurements were taken at each time period to study the change in mandibular position. The degree of change in SN-Pogonion angle, Pogonion depth, Pogonion height and SN-occlusal plane angle at 1 year postoperatively and at the long-term follow-up were compared among different facial type groups using the Student's *t*-test.

**RESULTS**

Eight cases were classified as either mesiofacial or one of its subtypes (mesiodolico or mesio-brachio), while 7 were

**TABLE 1.** Changes in SN-Pogonion Angle, Pogonion Depth, Pogonion Height and SN-occlusal Plane Angle in 15 Cases 1 year Postoperatively and at Long-Term Follow-up

	SN Pog Angle (degrees)	Pog Depth (mm)	Pog Height (mm)	SN-occlusal Plane Angle (degrees)
<b>Mesiofacial</b>				
Case 1	-1.5	-2.0	+1.5	+1.0
Case 2	-1.0	-2.0	+1.0	+1.5
Case 3	-0.5	-1.0	0.0	+0.5
Case 4	0.0	0.0	0.0	0.0
Case 5	-1.0	-1.5	+1.0	+1.0
Case 6	-1.0	-1.0	+1.0	0.0
Case 7	-1.0	-1.0	0.0	0.0
Case 8	0.0	0.0	0.0	0.0
<b>Brachiofacial</b>				
Case 9	+1.0	+2.0	-1.5	-1.5
Case 10	+1.5	+3.5	-2.0	-1.5
Case 11	0.0	0.0	0.0	0.0
Case 12	0.0	0.0	0.0	0.0
Case 13	+1.5	+3.5	-2.0	-2.0
Case 14	+0.5	+0.5	-0.5	-1.0
Case 15	+2.0	+3.5	-2.0	-2.0

**TABLE 2.** Changes in SN-Pogonion angle: A Significant Difference was Observed in the Change in the Movement Between the Mesiofacial Group and Brachiofacial Group<sup>a</sup>

Group	Change in the SN-Pogonion Angle (degree)			
	n	Mean	SE	SD
Mesiofacial	8	-0.75	0.19	0.54
Brachiofacial	7	0.93	0.30	0.79

<sup>a</sup> n indicates number of patients; SE, standard error of mean; and SD, standard deviation.

classified as brachiofacial. No dolico facial patterns were seen among the 15 cases in which long-term follow-up was available (Table 1).

Cases classified preoperatively as mesio, mesiodolico or mesio-brachio had a greater tendency during long-term observation to show a decrease in SN-Pogonion angle (mean  $-0.75^\circ \pm 0.54^\circ$ ) and Pogonion depth (mean  $-1.06^\circ \pm 0.78$  mm) (Tables 2 and 3), an increase in Pogonion height (mean  $0.56$  mm  $\pm 0.62$  mm) and SN-occlusal plane angle (mean  $0.50^\circ \pm 0.60^\circ$ ) (Tables 4 and 5). This trend negative change in the SN-Pogonion angle and Pogonion depth indicated a posterior clockwise movement of the mandible. An increase in facial height also was evident with a concomitant increase in Pogonion height.

In the brachiofacial pattern, the SN-Pogonion angle (mean  $0.93^\circ \pm 0.79^\circ$ ) and Pogonion depth (mean  $1.86 \pm 1.68$  mm) increased (Tables 2 and 3), while Pogonion height (mean  $-1.14$  mm  $\pm 0.95$  mm) and SN-occlusal plane angle (mean  $-1.14^\circ \pm 0.85^\circ$ ) decreased (Tables 4 and 5). The position of the mandible changed in an upward anterior manner indicating a tendency towards regression.

The significance of these findings between mesio-, me-

**TABLE 3.** Changes in Pogonion Depth. A Significant Difference was Observed in the Change in the Movement Between the Mesiofacial Group and Brachiofacial Group<sup>a</sup>

Group	Change in the Pogonion Depth (mm)			
	n	Mean	SE	SD
Mesiofacial	8	-1.06	0.27	0.78
Brachiofacial	7	1.86	0.63	1.68

<sup>a</sup> n indicates number of patients; SE, standard error of mean; and SD, standard deviation.

**TABLE 4.** Changes in Pogonion Height: A Significant Difference was Observed in the Change in the Movement Between the Mesiofacial Group and Brachiofacial Group<sup>a</sup>

Group	Change in the Pogonion Height (mm)			
	n	Mean	SE	SD
Mesiofacial	8	0.56	0.22	0.62
Brachiofacial	7	-1.14	0.36	0.95

<sup>a</sup> n indicates number of patients; SE, standard error of mean; and SD, standard deviation.

**TABLE 5.** Changes in SN-Occlusal Plane Angle: A Significant Difference was Observed in the Change in the Movement Between the Mesiofacial Group and Brachiofacial Group.

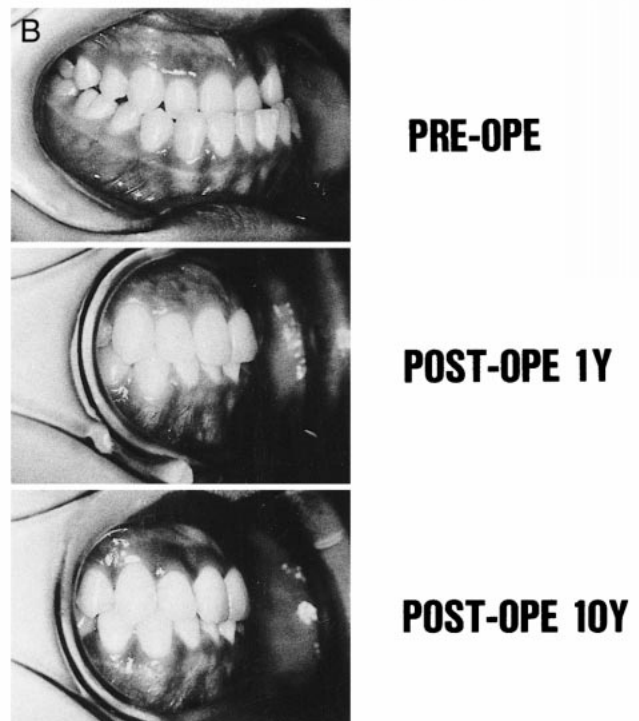
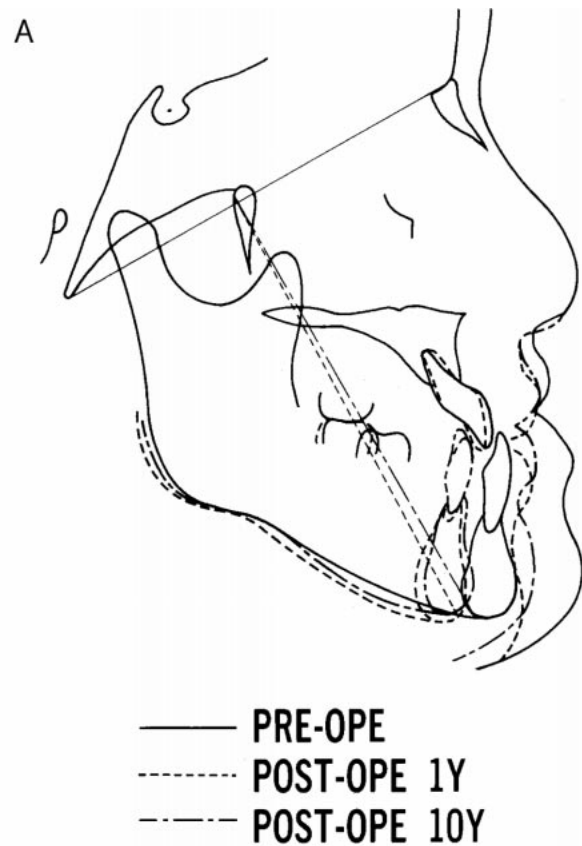
Group	Change in the SN-Occlusal Plane (degree)			
	n	Mean	SE	SD
Mesiofacial	8	0.50	0.21	0.60
Brachiofacial	7	-1.14	0.32	0.85

<sup>a</sup> n indicates number of patients; SE, standard error of mean; and SD, standard deviation.

siodolico-, and mesiobrachiofacial patterns and brachiofacial patterns was confirmed by a Student's *t*-test (Figure 6), indicating a distinct pattern of mandibular position for each facial type (SN-Pogonion angle  $P = .0003$ , Pogonion depth  $P = .0007$ , Pogonion height  $P = .0011$ , and SN-occlusal plane angle  $P = .0008$ ). Therefore, facial pattern types may serve as a basis for predicting the pattern of relapse following BSSO during the period of long-term follow-up.

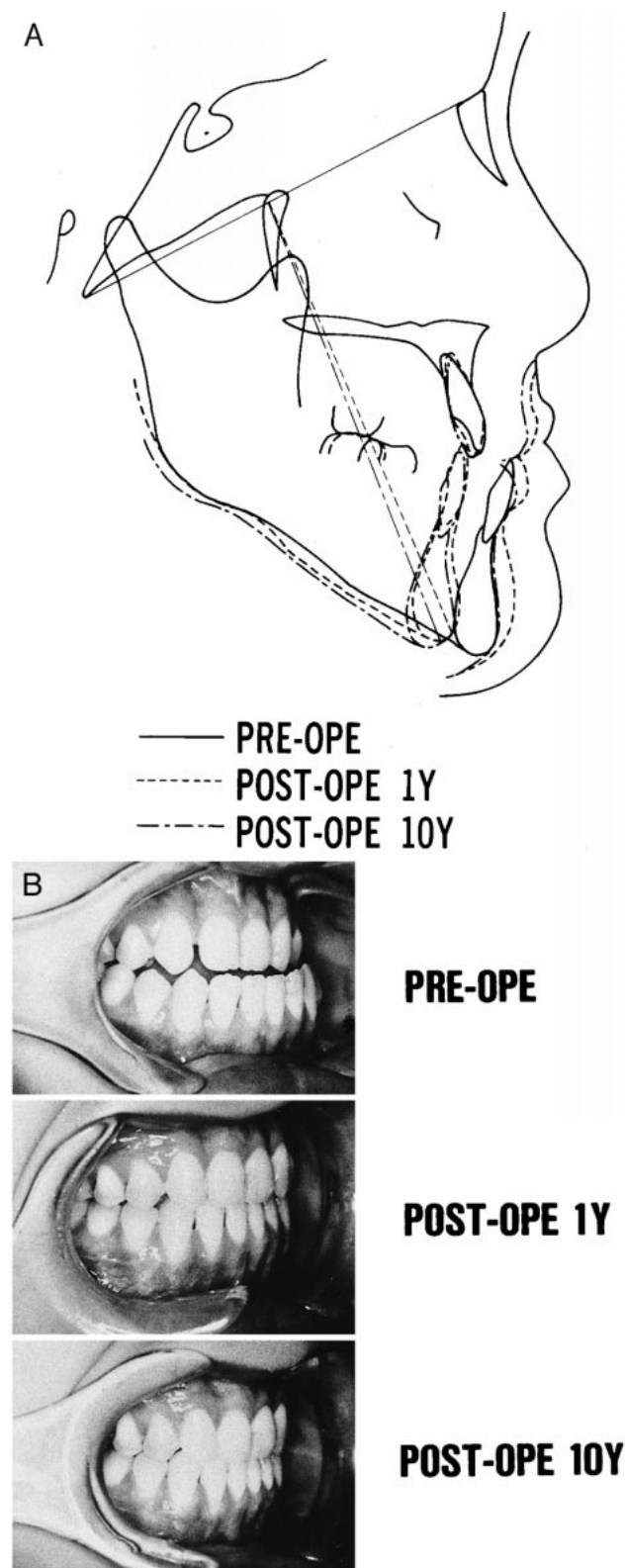
**DISCUSSION**

Postoperative dental and skeletal stability in patients for whom mandibular prognathism was corrected in combination with surgery remains controversial. The nature of relapse is multifactorial and thus certain considerations need to accompany interpretation of the present data. To establish reliable investigative procedures for this type of study, measurement error should be taken in account. In the present study, every effort was taken in to have all clinical procedures and cephalometric measurements performed by the same operator or one of a few experienced operators. These standardized methods and analyses were done to minimize measurement error.



**FIGURE 4.** (A) Changes on profilogram of a patient with brachyfacial type. Position of chin shifted anteriorly during long-term follow-up. (B) Clinically acceptable occlusion during long-term follow-up.





**FIGURE 5.** (A) Changes on profilogram of a patient with mesiofacial type. Measurements of cephalometric analysis showed relapse in a clockwise manner; however, the profile was still acceptable after long-term follow-up. (B) Clinically acceptable occlusion during long-term follow-up.

The cephalometric analysis in the present study consisted of 2 major methods. The first was Ricketts' method of classifying different facial patterns. The second was an assessment of 3 parameters to determine mandibular position, namely SN-Pogonion angle, Pogonion depth and Pogonion height. Thus, the present study attempted to study typical facial patterns and treatment relapses during long-term follow-up and to determine whether a relationship exists between facial pattern and mandibular relapse. The results indicated that SN-Pogonion angle, and linear measurements of Pogonion height and Pogonion depth were parameters of mandibular position.

While every effort was made to avoid sampling bias, the small number of subjects in the present study ( $n = 15$ ) does not allow us to consider it a true random sample in a statistical sense. Therefore, a larger sample group is needed to discuss predictable patterns in relation to mandibular movement among facial types and relapse. However, during long-term follow-up, it is often difficult to maintain a large sample group, because patients often relocate and drop out of the study.

If a sample population includes cases undergoing combined surgical procedures in the study protocol, this may be camouflaging any actual change in soft and hard tissues in relation to mandibular setback. The present sample group of patients all underwent mandibular setback surgery alone, not in combination with maxillary jaw or genioplasty. This enables a clear estimation of the correlation between surgical modality and changes in cephalometric measurements.

The present results demonstrated that changes in mandibular position occur even after postoperative orthodontic treatment following mandibular setback surgery. Many factors may affect the results of surgical correction.<sup>15-16</sup> First, surgical intervention should be delayed until mandibular growth has ceased. Several studies have reported being able to assess the growth peak of the facial skeleton with mandibular prognathism. The results suggest an effective means of determining the appropriate timing for initiating treatment and application of orthognathic surgery. The mean age of the present study population at the time of surgery was 22 years and 1 month for males and 20 years and 9 months for females. At this point, growth and development of facial structures should have ceased. Furthermore, explaining relapse in terms of age as the sole causal factor is problematic.

On the other hand, Morrill et al<sup>17</sup> reported that there may be subtypes of Class III malocclusion which have specific and different responses to surgical treatment. Our results confirmed that a significant correlation existed between facial type and relapse pattern.

The brachiofacial pattern has the greatest horizontal component in which the setback is performed. The aim is to decrease this horizontal component with the use of the BSSO to obtain an acceptable profile. When mandibular setback is applied to patients with a brachiofacial pattern,

**TABLE 6.** Cephalometric Measurements of a Typical Brachiofacial Patient as Demonstrated by Case No. 9

	Case No 9			
	Pre-Operative	Post-Op One Year	Post-Op Ten Years	Change
Facial axis	93.5	88.0	89.0	+1.0
Facial depth	97.5	92.0	93.0	+1.0
Mand. plane angle	23.0	25.5	25.0	-0.5
Lower facial height	47.0	51.5	51.0	-0.5
Mand. arc	57.5	32.0	30.0	-2.0
Total facial height	57.5	62.0	61.5	-0.5
SN Pog angle	90.0	84.5	85.5	+1.0
Pog depth (mm)	64.5	54.0	56.0	+2.0
Pog height (mm)	121.5	126.0	124.5	-1.5
SN-occlusal plane angle	12.0	14.0	12.5	-1.5

**TABLE 7.** Cephalometric Measurements of a Typical Mesiofacial or Doliofacial Patient as Demonstrated by Case No. 1

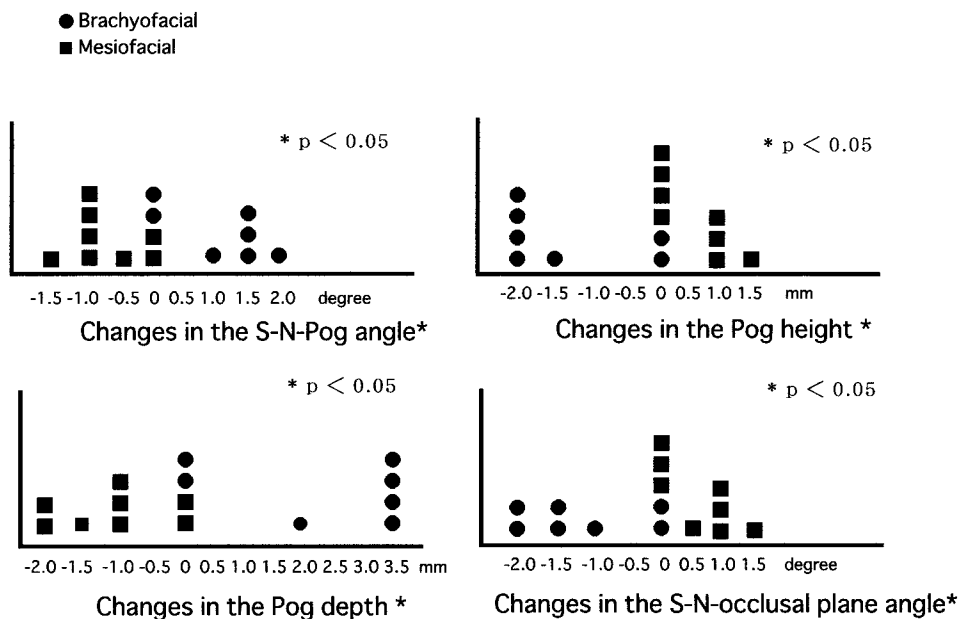
	Case No 1			
	Pre-Operative	Post-Op One Year	Post-Op Ten Years	Change
Facial axis	89.5	85.0	83.5	-1.5
Facial depth	90.5	87.0	85.5	-1.5
Mand. plane angle	32.5	34.0	40.0	+6.0
Lower facial height	51.5	51.5	55.0	+3.5
Mand. arc	23.5	27.0	24.0	-3.0
Total facial height	66.0	64.0	66.0	+2.0
SN Pog angle	82.0	78.0	76.5	-1.5
Pog depth (mm)	49.0	40.0	38.0	-2.0
Pog height (mm)	135.0	129.0	130.5	+1.5
SN-occlusal plane angle	17.0	15.0	16.0	+1.0

movement of the distal segment is in a backward and clockwise direction. This movement causes a shortening of posterior facial height. In such cases, a pattern of anterior relapse was noted postoperatively (Table 6, Figure 4 A–B). Case 9 showed typical changes in brachiofacial pattern. This case demonstrated the characteristic features of mandibular movement for the brachiofacial pattern type. Because of a decrease in SN-occlusal plane angle, while all other parameters showed an anterior and upward change of the mandible, forward relapse occurred with a closing of the bite.

On the other hand, the osteotomy is performed to decrease facial height for mesiofacial or doliofacial tendency patterns. This produces a counterclockwise rotation of the distal segment and necessitates elongation of the posterior

facial height with rotation around a fulcrum at the molars. Consequently, a clockwise pattern of relapse occurred (Table 7, Figure 5 A–B). Case 1 presented the typical changes in facial type. This case demonstrated characteristic features of mandibular movement for the doliofacial and mesiofacial pattern types. Because of an increase in the SN-occlusal plane angle, while all other parameters showed a posterior and downward change in the mandible, backward relapse occurred with a change in opening the bite. Thus, when the mandible was adjusted in a posterior direction, an anterior pattern of relapse was observed and when facial height was adjusted, a vertical pattern of relapse occurred. These results indicate that a relationship exists between the direction of mandibular adjustment and the direction of relapse.

Each facial type responds differently to the BSSO sur-



**FIGURE 6.** Distribution of 15 cases according to the degree of change in each parameter.

gical procedure. This response pattern should be taken into account when setting treatment objectives. According to Rickett's Bioprogressive Therapy,<sup>12</sup> the dolico type has a high angle and a larger vertical component around the mandible, particularly at the chin. The face appears long and in many cases the mouth protrudes forward. Downward posterior regression of the chin may occur after BSSO due to weaker natural anchorage of the muscles. In contrast, the brachio type has a deep bite and a larger horizontal component in the chin, so the facial shape appears short with a protruding chin. Natural anchorage of the muscles is fairly strong and thus it can be difficult to raise the bite.

The results suggest that treatment outcomes can be predicted based on the characteristics of each facial type (ie, anchorage type, direction of growth, and horizontal and vertical measurements). In the present study, the greatest change in measurements was seen in brachiofacial cases. These indicate a deeper bite and stronger musculature, which provides a strong natural anchorage. This causes greater resistance to mandibular rotation during treatment. In contrast, the dolico facial type tends to open during treatment. Therefore, it is of paramount importance to assess each facial type and determine its likely reaction to the surgical procedure. In addition, to prevent such changes and maintain good stability of the mandibular position and occlusion, care should be taken in the planning of surgical procedures and orthodontic treatment for each facial type. For brachiofacial cases, such planning should attempt to obtain a sufficient amount of mandibular setback and centric stop for occlusion, and furthermore eliminate dental decompensation sufficiently by preoperative orthodontic treatment. For mesio and dolico tendency facial cases, planning should attempt to establish sufficient occlusal bite by preoperative orthodontic treatment.

Cranial base measurements of the mandibular plane or facial axis of the chin provide only general clues for classifying these facial types. It is necessary to develop more meaningful definitions based on function or muscular support so critical for anchorage and treatment planning from measurements that directly involves the internal mandibular form and lower vertical facial height.<sup>12</sup>

Good prognosis cannot be guaranteed simply by achieving a union of the mandibular fragments as per the preoperative plan. As indicated in the present study, any definition of success must also take into account the formation of an acceptable profile as well as stable adaptation of tissues to the newly established position.

The desire for an acceptable facial profile was the strongest reason for our patients to seek corrective surgery. Furthermore, a stable mandible, which is necessary for effec-

tive mastication, was almost as important to them as a good profile. Careful postoperative management is required in order to ensure suitable postoperative results. Treatment decisions leading to successful outcome should be guided, in part, by appropriate preoperative classification of the patient's facial type. However, careful long-term follow-up is needed even after cessation of the postoperative orthodontic treatment. Further research on the biological potential of relapse for each facial type is needed.

## REFERENCES

1. Trauner R, Obwegeser H. Surgical correction of mandibular prognathism with consideration of genioplasty. *Oral Surg Oral Med Oral Pathol.* 1957;10:677-689.
2. Dal Pont G. Retromolar osteotomy for the correction of prognathism. *J Oral Surg.* 1961;19:42-47.
3. Epker BN. Modifications in the sagittal osteotomy of the mandible. *J Oral Surg.* 1977;35:157-159.
4. Bell WH, Schendel SA. Biologic basis for modification of the sagittal ramus split operation. *J Oral Surg.* 1977;35:362-369.
5. Rodriguez RR, Gonzalez M. Skeletal stability after mandibular setback surgery. *Oral Surg Oral Med Oral Pathol.* 1996;81:31-33.
6. Kobayashi T, Watanabe I, Ueda K, Nakajima T. Stability of the mandible after sagittal ramus osteotomy for correction of prognathism. *J Oral Maxillofac Surg.* 1986;44:693-697.
7. Martis CS. Complications after mandibular sagittal split osteotomy. *J Oral Maxillofac Surg.* 1984;42:101-107.
8. Paulus GW, Steinhäuser EW. A comparative study of wire osteosynthesis versus bone screws in the treatment of mandibular prognathism. *Oral Surg.* 1982;54:2-6.
9. Leonard M. Preventing rotation of the proximal fragment in the sagittal ramus split operation. *J Oral Surg.* 1976;34:942.
10. Isaacson RJ, Kopytov OS, Bevis RR, Waite DE. Movement of the proximal and distal segments after mandibular ramus osteotomies. *J Oral Surg.* 1978;36:263-268.
11. Hovell J. Muscle patterning factors in the surgical correction of mandibular prognathism. *J Oral Surg.* 1964;22:122-126.
12. Ricketts RM, Bench RW, Gugino CF, Hilgers JJ, Schulhof RJ. Part 4, the use of superimposition areas to establish treatment design. In: *Bioprogressive Therapy*. USA Rocky Mountain/Orthodontics JPO Inc; 1979:55-69.
13. Ricketts RM, Bench RW, Gugino CF, Hilgers JJ, Schulhof RJ. Part 6, forces used in bioprogressive therapy. In: *Bioprogressive Therapy*. USA Rocky Mountain/Orthodontics JPO Inc; 1979:93-109.
14. Nezu H, Nagata K, Yoshida Y, Kosaka H, Kikuchi M. Cephalometric comparison of clinical norms between the Japanese and Caucasians. *Nippon Kyosei Shika Gakkai Zasshi.* 1982;41:450-465.
15. Mitani H, Sato K, Sugawara J. Growth of mandibular prognathism after pubertal growth peak. *Am J Orthodont Dentofacial Orthop.* 1993;104:330-336.
16. Sato K, Abe S, Mitani H. Estimation of mandibular growth using biological markers of bone metabolism in urine. *Orthod Waves.* 1999;58:199-207.
17. Morrill LR, Baumrind S, Miller D. Surgical correction of mandibular prognathism. I. A cephalometric report. *Am J Orthod.* 1974;65:503-518.