

Inflammatory Conditions of the Male Excurrent Ductal System. Part I.

Review

PETER T. K. CHAN AND PETER N. SCHLEGEL

*From the James Buchanan Brady Foundation,
Department of Urology, New York Presbyterian
Hospital–Weill Medical College of Cornell University;
and The Population Council, Center for Biomedical
Research, New York, New York.*

Physiologically, the endocrinologic interplay between testes and pituitary gland results in the production of spermatozoa. Before serving their role in fertilizing oocytes, spermatozoa must exit the testis and pass through a complex excurrent ductal system that includes the efferent ductules, epididymis, and vas deferens, which leads to the ejaculatory duct. Pathological conditions in any part of the excurrent ductal system obviously may have a significant effect on spermatozoa transport, resulting in subfertility or infertility. In addition to spermatozoa, semen is composed of secretions from a series of glandular organs, including the prostate, seminal vesicles, the bulbourethral (Cowper) gland and periurethral (Littré) gland. Collectively, these organs are known as the male accessory glands.

Various inflammatory conditions, including microbial infection, are by far the most common pathology encountered in the male reproductive system. The term *male accessory gland inflammation*¹ describes a broad spectrum of inflammatory conditions involving the male accessory glands. The prostate gland and the seminal vesicles together produce about 90% of the ejaculate volume. Although inflammatory conditions of these organs (prostatitis and seminal vesiculitis) are important clinical topics in andrology (Weidner et al, 1998a,b), in this review our discussion will focus mainly on the various inflammatory conditions of the excurrent ductal system. In Part I of this review, our discussion will focus mainly on the various inflammatory conditions of the epididymis and efferent ductile. In Part II, we will discuss the rarely described subject of vasitis and address the management issues and fertility effects of excurrent ductal inflammation.

Inflammatory Conditions of the Epididymis

Inflammatory lesions, particularly infection, are by far the most common pathological entity encountered in the epididymis. Epididymitis results in many days lost from work both in civilian life and in the military, where more than 20% of urologic admissions may be due to epididymitis (Bormel, 1963; Sharpiro and Breschi, 1973; Berger et al, 1979; Vordermark, 1985). Although epididymitis may be clinically asymptomatic, more commonly, a wide spectrum of signs and symptoms are associated with epididymal inflammation, including scrotal and pelvic pain, nodule, edema, irritative urinary symptoms, fever, purulent ejaculate or urethral discharge, and infertility. Rare clinical presentations of epididymitis include scrotal cutaneous fistula, hemospermia (Weidner et al, 1991) and septicemia (Sarma and Raghava, 1995).

Bacterial infections are the most common etiology for epididymitis. The risk factors, pathogens involved, and subsequent management are different between the adult and pediatric populations; hence, epididymitis in these 2 populations will be discussed separately. Infectious epididymitis and other forms of inflammatory epididymitis will be the focus of this section.

Common Infectious Epididymitis in Men

Studies in the 1980s reported 500 000 to 600 000 cases of acute epididymitis yearly (National Institutes of Health, 1981; Krieger, 1984). Sexually transmitted infections (STIs) are the most common causes of acute epididymitis. Despite increasing awareness among the general population of STIs, particularly of herpes and acquired immunodeficiency syndrome (AIDS), and the resulting popularity of barrier contraception, statistics in the 1990s from the National Institutes of Health (1998) revealed a rising incidence of STIs. Part of the reason for this increase in incidence is that young adults become sexually active at an earlier age but marry at a later age. This, along with a high divorce rate, results in a higher likelihood of multiple sexual partners, and a subsequent higher risk for developing STIs among sexually active people.

Among men younger than age 35 years, epididymitis is most commonly transmitted through sexual contact. In the United States, the most common pathogen in adult infectious epididymitis is *Chlamydia trachomatis* (Berger, 1991). In some developing communities, epididymitis from *Neisseria gonorrhoeae* may be more prevalent than

Correspondence to: Peter T.K. Chan MD, 4908 Ponsard Avenue, Montreal, Quebec Canada H3W 2A4 (e-mail: sperminator.II@hotmail.com).

Received for publication April 23, 2001; accepted for publication November 7, 2001.

¹ While also known as male accessory gland infection in the literature, the authors prefer the term male accessory gland *inflammation* to properly include the various noninfectious inflammatory conditions of these organs.

Chlamydia (Hoosen et al, 1993). Less-common pathogens in acute epididymitis include *Ureaplasma urealyticum*, *Escherichia coli*, *Enterococcus faecalis*, and *Pseudomonas aeruginosa* (Kashiwagi et al, 2000). Epididymitis usually results from retrograde ascent of urethral pathogens via the ejaculatory ducts and the vas deferens. Sexually transmitted epididymitis usually is accompanied by urethritis, with complaints of dysuria, urethral irritation, and mucoid or mucopurulent discharge. However, up to 40% of men infected with *Chlamydia* report no symptoms (Institute of Medicine, 1997).

Infection with human immunodeficiency virus (HIV) type 1 through semen contact represents a major route of transmission. In men with HIV infection, marked abnormalities of the male accessory reproductive organs and seminiferous epithelium, including inflammation and destruction of germinal cells with fibrosis and hyalinization, have been reported (Da Silva et al, 1990; Dalton and Harcourt-Webster, 1991; Pudney and Anderson, 1991; Martin et al, 1992). These insults to the reproductive system are reflected by a decrease in semen parameters, in terms of sperm motility percentage, normal morphology by strict criteria, leukocytospermia, teratozoospermia, and oligoasthenoteratozoospermia (Muller et al, 1998). The quality of semen parameters correlates with the severity of the infectious status, as determined by patients' peripheral CD4⁺ cell count and clinical stages. The extent to which this decline in semen quality is attributable to the direct result of HIV infection to the reproductive organs, hormonal effects or deterioration of general health, or the effects of therapeutic drugs received by patients, remain unresolved questions.

Infectious epididymitis from *E. coli*, a gram-negative enteric organism commonly involved in urinary tract infection, is rare among young heterosexual men, although unprotected anogenital intercourse significantly increases the risk of coliform epididymitis (Berger et al, 1987). On the other hand, infectious epididymitis among men older than age 35 are more commonly due to enteric organisms. Obstructive urinary symptoms, which may be due to urethral stricture, bladder neck obstruction, or benign prostatic hyperplasia, which are commonly seen in men older than age 50, appear to be major risk factors for the development of epididymitis or other lower urinary tract infection (Thind et al, 1992). Incomplete emptying of urine along with a higher voiding pressure in order to overcome the obstruction facilitates reflux of infected urine into the excurrent ductal system, leading to infection (Figure 1).

Proper use of antimicrobials against specific pathogens is the key in the management of infectious epididymitis to avoid complications such as septicemia, especially in elderly patients. In rare cases of more severe forms of epididymitis, abscesses may form. They may rupture and

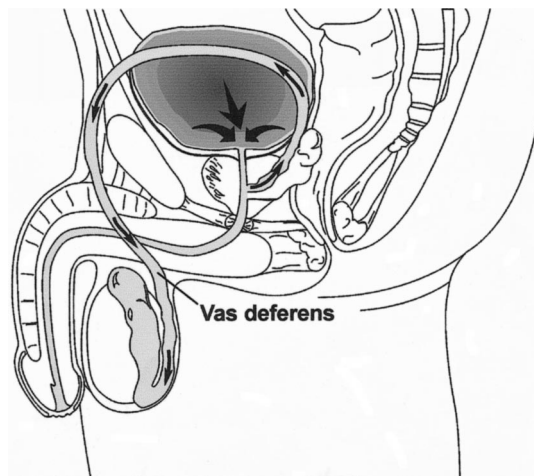


Figure 1. High voiding pressure secondary to urinary obstruction may lead to reflux of urine (arrows) into the excurrent ductal system, causing inflammation.

form sinus tracts through the scrotal wall, associated with sperm extravasation and formation of sperm granulomas (Goodson and Fruchtman, 1975). In addition, the mass effect of the abscess or its direct invasion into testicular parenchyma may compromise vascular supply to the testis, leading to ischemia, infarction, or atrophy of the testis (Slavis et al, 1989).

Epididymitis in the Pediatric Population

Pathogens for infectious epididymitis in the pediatric population are somewhat different, although venereal pathogens causing STIs may also be seen in sexually active adolescents. When venereal pathogens are isolated from younger children with urogenital infections, however, sexual abuse should be suspected. Common bacteria causing epididymitis in boys include *E. coli* and *Haemophilis influenzae*. Rare pathogens, such as *Salmonella*, *Pseudomonas*, and other viral infections (Coran and Perlmutter, 1965) have been reported.

The age distribution of childhood epididymitis has been reported to be bimodal (Likitnukul et al, 1987) at ages younger than 5 years and at early puberty. Anatomical defects are strongly associated with epididymitis in the first group of young boys (Merlini et al, 1997). Some of the malformations, such as posterior urethral valves, urethral stricture, or hypoplasia, may result in bladder outlet obstruction and high bladder pressure voiding with resultant reflux into the ejaculatory duct and epididymis, causing inflammation or infection. This is analogous to epididymitis in older men with obstructive urinary symptoms. In other cases, pathological connections may exist between the urinary, genital, and sometimes the lower gastrointestinal tract. Because these genitourinary abnormalities place boys at high risk for urinary tract infection, affected patients tend to present with infections at a much

younger age. With improvements in prenatal diagnostic sonography and earlier initiation of treatment, this group of patients with urogenital malformation can occasionally be identified before infectious complications develop. In managing this group of patients, in addition to proper treatment of the ongoing infection, the underlying malformation should be identified and corrected surgically, if possible, to avoid recurrent infection.

The pathogenesis of epididymitis in early pubertal boys may also involve systemic hematogenous dissemination of pathogens (Dairiki Shortliffe, 1998). Urogenital malformation in this group is uncommon, although urodynamic studies indicate that older boys with epididymitis commonly have a dysfunctional voiding pattern, including bladder hyperactivity and detrusor-sphincter dyssynergia (Bukowski et al, 1995). These patients tend to have incomplete emptying of urine as well as high voiding pressure, placing them at risk for reflux epididymitis. The reason for the voiding dysfunction presenting at an older age is uncertain. Although manifestation of underlying neurological problems is a possibility, psychological factors among adolescence, from personal and social stresses, is a more common etiology.

Epididymitis commonly presents in the pediatric population as an acute scrotum. A long list of differential diagnoses of acute scrotum exists, including epididymo-orchitis, testicular or spermatic cord torsion, torsion of testicular or epididymal appendages, incarcerated hernia, acute hydrocele, testicular tumor, idiopathic scrotal edema, nonthrombocytopenic vasculitis from Henoch-Schönlein purpura, trauma, and hydrohematocele. Some conditions, such as torsion of appendages, may be managed conservatively with analgesics, whereas others, such as testicular torsion, will require immediate surgical exploration. Epididymitis occurs almost as frequently as testicular torsion (Caldamone et al, 1984; Yazbeck and Patriquin, 1994). Although a detailed clinical history and careful physical examination are the key initial steps in managing an acute scrotum, the presenting symptoms and physical signs, particularly in infants and younger boys, are often not specific enough to differentiate the etiologies. The presence of a cremasteric reflex correlates with the absence of testicular torsion, although exceptions have been reported. A positive Prehn sign for epididymitis, in which elevation of the scrotum relieves the discomfort, is generally considered not reliable.

Laboratory investigations that may indicate epididymitis include pyuria, leukocytosis, and a positive urinary culture in more severe infection. However, in noninfectious epididymitis these results may be negative. Imaging modalities may be helpful in distinguishing epididymitis versus testicular torsion or other inflammatory processes in an acute scrotum. Sonography with color Doppler provides images of the epididymides and testes (Wilbert et

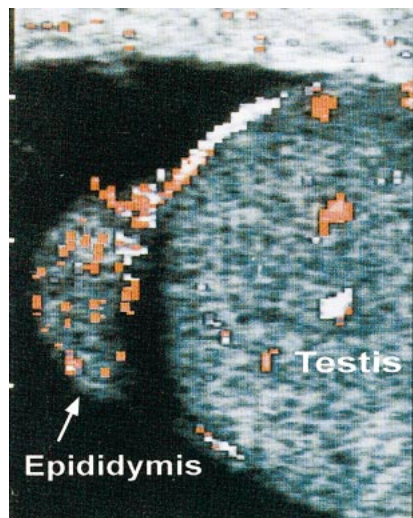


Figure 2. Epididymitis in longitudinal color Doppler sonographic scan. Note the presence of increased blood flow (demonstrated as red pixels) in the caput epididymis.

al, 1993; Suzer et al, 1997; Munden and Trautwein, 2000; Weber et al, 2000; Blaivas et al, 2001). The presence of hypervascularity of the epididymis is suggestive of epididymitis (Figure 2), whereas in testicular torsion, a decrease in arterial flow should be noted. Radionuclide scintigraphy using technetium-99m can also help distinguish an inflammatory condition from testicular torsion (Meloul et al, 1995). In epididymitis, an intensely labeled, or “hot” image on the hemiscrotum is involved (Figure 3). False-positive and false-negative results of these imaging studies are not uncommon. Furthermore, the time required to perform these studies may unnecessarily delay appropriate surgical management. Testicular torsion requires urgent surgery to detorse the vascular pedicle within hours in order to preserve testicular viability. Thus, if the index of suspicion for testicular torsion is high, such as with sudden onset of scrotal pain and no evidence of inflammation or infection, immediate surgical scrotal exploration should be performed without waiting for imaging studies.

Iatrogenic Epididymitis

Epididymitis can be a complication of medical treatments. Drug-induced epididymitis has been reported with the use of amiodarone (Gasparich et al, 1984; Hutcheson et al, 1998), a potent class III antidysrhythmic benzofurane derivative for treating refractory ventricular and supraventricular cardiac arrhythmia (Hamoud et al, 1996; Gabal-Shehad and Monga, 1999). Postmortem examination of patients affected by amiodarone-induced epididymitis showed focal areas of epididymal fibrosis with lymphatic infiltration. Although the exact mechanism of this disease is unknown, studies have shown that the drug concentra-

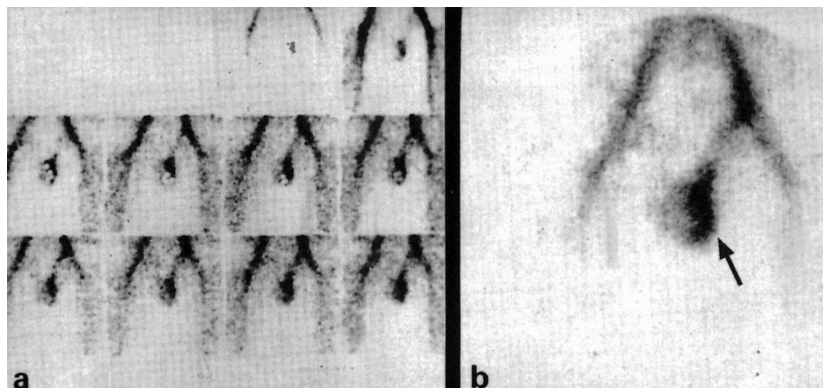


Figure 3. Left epididymitis in radionuclide scan. (a) Sequential increase in tracer uptake over the left hemiscrotum ("hot" sign). (b) Static scrotal scan demonstrating accumulation of radioactive tracer consistent with increased left hemiscrotal blood flow and epididymitis (arrow).

tion in many body tissues, such as epididymis, may be up to 300-fold greater than the serum level (Sadek et al, 1993) and that the side effects are dose-dependent and duration-dependent (Greene et al, 1983). In addition, anti-amiodarone antibodies have been identified in patients with side effects (Pichler et al, 1988), suggesting that amiodarone-induced epididymitis may be a direct chemical effect on the tissues or an autoimmune phenomenon. Because amiodarone-induced epididymitis is a sterile inflammation, patients generally do not require or respond to antibiotic therapy. Reduction or discontinuation of amiodarone provides rapid relief of symptoms, although symptoms have been reported to recur if the drug is reinstated at the same dosage (Gabal-Shehab and Monga, 1999).

Infectious epididymitis can also be induced iatrogenically from various medical and surgical procedures of the urinary tract, including intermittent urethral catheterization (Perrouin-Verbe et al, 1995), indwelling urinary catheter, cystoscopic examination, vasectomy (Moss, 1992), and some prostate surgery (Fournier et al, 1995). The mechanism is likely due to introduction of pathogens into the lower urinary tract that eventually spread to the epididymis or other parts of the excurrent ductal system, causing infections. It should be kept in mind that most patients requiring these procedures may be at risk for developing lower urinary tract infection due to their initial medical conditions, which may include neurogenic bladder from diabetes or other neurologic pathologies, or urinary obstruction from benign prostatic hyperplasia. It is therefore important for clinicians to consider any early symptoms or signs of infections so that appropriate treatment can be initiated promptly in this group of high-risk patients.

Trauma and Stress-Induced Epididymitis

Traumatic epididymitis may occur secondary to iatrogenic injury to the epididymis during various scrotal surgeries.

More frequently, however, traumatic epididymitis is seen in scrotal trauma. Although commonly associated with other complications, such as testicular rupture, infarction, and intratesticular hematoma, which require surgical exploration, traumatic epididymitis may occur as an isolated finding, particularly in less-severe scrotal injury. It should be pointed out that epididymitis after trauma can be associated with underlying infection, with the trauma being an aggravating event to the infection (Berger et al, 1978, 1979). On physical examination, traumatic epididymitis can mimic infectious epididymitis with a swollen and tender epididymis. High-resolution color Doppler sonography often reveals focal or diffuse hyperemia (Gordon et al, 1996). This finding, along with a history of scrotal trauma, helps make the diagnosis of traumatic epididymitis. Unlike infectious epididymitis, management of traumatic epididymitis does not require antibiotics. Conservative management with ice-pack application, scrotal support and elevation, and rest often significantly relieve the symptoms. Long-term complications of traumatic epididymitis include chronic epididymitis and infertility due to obstructive damage to the epididymal tubules.

There has been recent documentation in the literature that epididymitis can be induced by physical stress, especially by heavy lifting or other strenuous activity. Because it is considered a work-related injury by some occupational medicine physicians, this stress epididymitis may contribute to considerable time lost from work and subsequent compensation. In one retrospective series of an occupational health center, 70% of men with a diagnosis of acute epididymitis reported an immediate and preceding event of heavy lifting or severe strain at work (Sawyer and Anderson, 1996). The mechanism of stress epididymitis is believed to be due to reflux of sterile urine through the posterior urethra and vas deferens reaching the epididymis, and causing chemical inflammation. Although management of this form of sterile chemical epididymitis should not require antibiotics, due to the prev-

absence of infectious epididymitis, a course of antibiotics is often used initially, along with antiinflammatory drugs. For the same reason, bacterial culture, which although may be falsely negative even in infectious epididymitis, is indicated when managing these patients.

Uncommon Infectious Epididymitis

Opportunistic infections are caused by pathogens that would not otherwise result in a clinical infection in a host with a normal immune system. There has been a general increase in the incidence of opportunistic infections in the past decade as we witness an increase in the patient population with suppressed immune systems, such as those with HIV infection, receiving immuno-suppression treatment for transplantation, or undergoing chemotherapy. When managing immuno-compromised patients, a high index of suspicion in recognition of the infection, aggressive diagnostic maneuvers, and prompt and appropriate treatment are the keys to successful management.

Various fungal and opportunistic bacterial forms of epididymitis have been reported, including candidiasis, coccidiomycosis, blastomycosis, actinomycosis, histoplasmosis, aspergillosis, *Nocardia*, *Listeria*, and cytomegalovirus (Docimo et al, 1993; Lyne and Flood, 1995; Hood et al, 1998; Erden et al, 2000; von Schnakenburg et al, 2000). Although these pathogens may spread in a retrograde fashion from the lower urinary tract to the epididymis, a hematogenous route is considered another common pathway for development of opportunistic epididymitis. Common antibiotic treatments for epididymitis targeted at chlamydial or gonococcal infection are not effective for most opportunistic infections. Initial urine cultures should be obtained. Diagnostic procedures such as scrotal sonography with needle aspiration may be considered to obtain appropriate cultures to guide treatment. However, aspiration of the epididymis may cause epididymal trauma and subsequent infertility. Another reason for being aggressive in diagnosing and treating opportunistic infection is that the local infection presented may be the early sign of systemic infection, which is highly lethal in this subgroup of patients (Secil et al, 1998).

Tubercular epididymitis (Gueye et al, 1998; McVie et al, 2000), which is relatively rare nowadays in developed countries, is often associated with infection of other parts of the genitourinary system. Tuberculosis mycobacteria may spread to the epididymis lymphatically and hematogenously (Gow, 1998). Alternatively, the bacteria may descend from the infected kidney to the prostate, where they spread retrocanicularly to the epididymis (Lattimer, 1983). Venereal transmission of genital tuberculosis has also been reported (Wolf and McAninch, 1991). The disease usually starts in the caudal portion of epididymis. This may be due to its richer blood supply compared with other parts of the epididymis, or because it is the first

portion involved by urinary reflux along the vas deferens (Kim et al, 1993). The incidence of tuberculosis in the United States has increased since the late 1980s (Chaisson and Slutkin, 1989). Much of this increase can be attributed to a larger population of immunocompromised patients.

Tubercular epididymitis can also be caused iatrogenically from intravesical instillation of Calmette-Guérin bacillus (BCG; O'Connell et al, 1993; Hansen and Mortensen, 1997; Menke and Heins, 2000), a common treatment for in situ or superficial transitional cell carcinoma of the urinary bladder. Traumatic catheterization of the urethra during instillation may increase the risk of hematogenous spread of BCG organisms. Clinically, tuberculosis epididymitis may present as an acute infection with pain and swelling of the organ, or it may present as a solid scrotal mass indistinguishable from a testicular tumor or other inflammatory condition (Truelson et al, 1992). Serious complications of tuberculosis epididymitis have been reported (Skoutelis et al, 2000). Fine-needle aspiration of the epididymis may sometimes be used to obtain a positive mycobacterium culture to confirm the diagnosis. Histological findings of caseation and granulomatous inflammatory lesions with multinucleated giant cells, along with identification of acid-fast bacilli in tissue may help in making the diagnosis.

Parasitic epididymitis due to schistosomiasis (Gelfand et al, 1970), enterobiasis (Kollias et al, 1992), and filarial disease (Williams et al, 1996) have been reported. The routes of parasitic infection to the genito-urinary system are peculiar to the specific parasite. Although it is extremely rare in United States, a parasitic etiology should be considered in certain groups of immigrants or travelers to developing countries.

Other Inflammatory Lesions of the Epididymis

Malignant neoplastic lesions are extremely rare in the epididymis. Most nodular lesions found in the epididymis are of benign inflammatory origin. The term *inflammatory pseudotumor* has been used to describe such rare lesions (Brauers et al, 1997). These lesions may occur idiopathically or as a reactive process after initial infection or injury. Inflammatory pseudotumors are often solitary and well-encapsulated. Because of the need to rule out an intratesticular tumor, such scrotal lesions should be carefully evaluated with scrotal sonography. If indeterminate findings are present, surgical excision is indicated to form a histological diagnosis. Other causes of granulomatous lesions include tuberculosis (Wolf and McAninch, 1991), brucellosis (Afcar et al, 1993), malakoplakia (McClure, 1980), sarcoidosis (Ryan et al, 1993), and xanthogranulomatous epididymitis (Matsuoka et al, 2001).

Behçet syndrome, first described by a Turkish dermatologist, Hulusi Behçet, is a systemic vasculitis of un-

known etiology. It is most prevalent in Turkey, Iran, and Japan (Yazici, 1994). A multisystem disorder, Behçet syndrome often presents with mucocutaneous (skin lesions and oral or genital aphtous ulcerations), ocular (chronic relapsing uveitis), musculoskeletal, neurological, and vascular involvement. Epididymitis has been reported to be as common as 5% to 19% of cases (Callejas-Rubio et al, 1998; Cetinel et al, 1998). Acute epididymitis in Behçet syndrome is noninfectious and often resolves with conservative treatment.

Sperm granuloma, although more frequently seen associated with the vas deferens after vasectomy (see Part II), is also found in epididymal tubules, and is commonly seen in men who have had a previous vasectomy. The pathogenesis of epididymal sperm granuloma is likely due to tubular injury from increased epididymal luminal pressure after vasectomy. This “blow-out” injury of epididymal tubules results in leakage of sperm, causing granuloma formation. Obstruction at the level of ejaculatory duct has also been reported to cause refractory epididymitis (Rotolo, 1995).

Epididymitis nodosa, a counterpart of vasitis nodosa, has been described. Epididymitis nodosa was rarely reported and it was once believed that this form of inflammation did not exist outside the vas deferens (Schmidt and Morris, 1973). Some authors, however, believed that it is probably not an uncommon finding (Schned and Selikowitz, 1986), but is often overlooked due to its small and inconspicuous nature. Epididymitis nodosa is similar to vasitis nodosa in that both are benign inflammatory conditions with similar histological features and pathogenesis. Tubular proliferation, with typical stromal inflammation characterized by infiltration of histiocytes, polymorphonuclear leukocytes, and Langerhans giant cells, is the main histological feature. Tubular obstruction, leading to increased luminal pressure and “blow-out” injury, is believed to be the underlying cause, resulting in leakage of spermatozoa, causing a characteristic inflammatory reaction and excessive regeneration of the epithelial lining.

Inflammatory Conditions of the Efferent Ductules

Efferent ductules are histologically and physiologically distinct from the rest of the epididymis. Pathological conditions found in the efferent ductules are commonly those associated with testes or the epididymis, due to their close proximity to one another. Isolated lesions in the efferent ductules are extremely rare. A few case reports on lesions of the efferent ductules of the epididymis have been documented. There is a general consensus that epididymal

papillary cystadenoma, a glandular, papillary cystic lesion with typically tall columnar ciliated cells, originates from efferent ductal epithelium (Sherrick, 1956; Grant and Hoffman, 1963; Shan et al, 1968). This rare lesion is well-known to be related to von Hippel-Lindau (VHL) disease, although sporadic cases unrelated to VHL have been reported (Kallie et al, 1983). This benign lesion has been postulated to be inflammatory in origin because of the presence of granulation, giant cells, cholesterol crystal deposition, and calcification in the wall of the cyst (Hill, 1962). Finally, a series of granulomatous lesions, probably of ischemic origin, has been reported in the efferent ducts (Nistal et al, 1997).

Conclusion

Inflammatory conditions of the excurrent ductal system can have a significant effect on the reproductive health of men. Epididymitis is a commonly encountered clinical entity affecting both the adult and pediatric populations. Andrologists should be aware of the presentation and potential etiologies of this condition.

References

- Afcar M, Baydar I, Sirmatel F. Epididymo-orchitis due to brucellosis. *Br J Urol.* 1993;72:104–105.
- Berger RE, Alexander ER, Monda GD, Ansell J, McCormick G, Holmes KK. *Chlamydia trachomatis* as a cause of acute “idiopathic” epididymitis. *N Engl J Med.* 1978;298:301–304.
- Berger R, Alexander E, Harnisch J, Paulsen CA, Monda GD, Ansell J, Holmes KK. Etiology, manifestations and therapy of acute epididymitis: prospective study of 50 cases. *J Urol.* 1979;121:750–754.
- Berger R, Kessler D, Holmes KK. Etiology and manifestations of epididymitis in young men: correlations with sexual orientation. *J Infect Dis.* 1987;155:1341–1343.
- Berger RE. Acute epididymitis: etiology and therapy. *Semin Urol.* 1991; 9:28–31.
- Blaivas M, Sierzenski P, Lambert M. Emergency evaluation of patients presenting with acute scrotum using bedside ultrasonography. *Acad Emerg Med.* 2001;8:90–93.
- Bormel P. Current concepts of the etiology and treatment of epididymitis. *Med Bull US Army, Europe.* 1963;20:332–334.
- Brauers A, Striepecke E, Mersdorf A, Sohn M, Fuzesi L. Inflammatory pseudotumor of the epididymis. *Eur Urol.* 1997;32:253–255.
- Bukowski TP, Lewis AG, Reeves D, Wacksman J, Sheldon CA. Epididymitis in older boys: dysfunctional voiding as an etiology. *J Urol.* 1995;154:762–765.
- Caldamone A, Valvo J, Altebarmakian V, Rabinowitz R. Acute scrotal swelling in children. *J Pediatr Surg.* 1984;19:581–584.
- Callejas-Rubio JL, Ortego N, Diez A, Castro M, Higuera JDL. Recurrent epididymo-orchitis secondary to Behçet’s disease. *J Urol.* 1998;160: 496.
- Cetinel B, Obek C, Solok V, Yaycioglu O, Yazici H. Urologic screening for men with Behçet’s syndrome. *Urology.* 1998;52:863–865.
- Chaisson RE, Slutkin G. Tuberculosis and human immunodeficiency virus infection. *J Infect Dis.* 1989;159:96–100.

- Coran AG, Perlmutter AD. Mumps epididymitis without orchitis. *N Eng J Med*. 1965;272:735.
- Da Silva M, Shevchuk MM, Cronin WJ, Armenakas NA, Tannenbaum M, Fracchia JA, Ioachim HL. Detection of HIV-related protein in testes and prostate of patients with AIDS. *Am J Clin Pathol*. 1990; 93:196–201.
- Dalton AD, Harcourt-Webster JN. The histopathology of the testis and epididymis in AIDS—a post-mortem study. *J Pathol*. 1991;163:47–52.
- Dairiki Shortliffe LM. Urinary tract infections in infants and children. In: Walsh PC, Retik AB, Vaughan AJ, Wein AJ, eds. *Campbell's Urology*. 7th ed. Philadelphia: WB Saunders; 1998:1681–1707.
- Docimo SG, Kang J, Rukstalis DB, Cotton D, Rukstalis MR, DeWolf WC. Candida epididymitis: newly recognized opportunistic epididymal infection. *Urology*. 1993;41:280–282.
- Erden A, Fitoz S, Karagulle T, Tukul S, Akyar S. Radiological findings in the diagnosis of genitourinary candidiasis. *Pediatr Radiol*. 2000; 30:875–877.
- Fournier G, Indudhara R, Gajendran V, Huang E, Narayan P. Epididymo-orchitis after cryoablation of prostate for prostate cancer. *J Endourol*. 1995;9:349–351.
- Gabal-Shehab LL, Monga M. Recurrent bilateral amiodarone induced epididymitis. *J Urol*. 1999;161:921.
- Gasparich JP, Mason JT, Greene HL, Berger RE, Krieger JN. Non-infectious epididymitis associated with amiodarone therapy. *Lancet*. 1984; 2:1211–1212.
- Gelfand M, Ross CMD, Blair DM, Castle WM, Weber MC. Schistosomiasis of the male pelvic organs. *Am J Trop Med Hygiene*. 1970;19: 779–784.
- Goodson JM, Fruchtman B. Spermatic granulomas of epididymis. *Urology*. 1975;5:278–280.
- Gordon LM, Stein SM, Ralls PW. Traumatic epididymitis: evaluation with color Doppler sonography. *AJR Am J Roentgenol*. 1996;166:1323–1325.
- Gow JG. Genitourinary tuberculosis. In: Walsh PC, Retik AB, Vaughan AJ, Wein AJ, eds. *Campbell's Urology*. Philadelphia: WB Saunders; 1998:812.
- Grant SM, Hoffman EF. Bilateral papillary adenomas of the epididymides. *Arch Pathol*. 1963;76:620–625.
- Greene HL, Graham EL, Werner JA, Sears GK, Gross BW, Graham GB, Kudenchuk PG, Probaugh GB. Toxic and therapeutic effects of amiodarone in the treatment of cardiac arrhythmias. *J Am Coll Cardiol*. 1983;2:1114–1128.
- Gueye SM, Ba M, Sylla C, Ndoye AK, Fall PA, Diaw JJ, Mensah A. Les manifestations epididymaires de la tuberculose uro-génitale. *Prog Urol*. 1998;8:240–243.
- Hamoud K, Kaneti J, Smailowitz Z, Lissmer L. Amiodarone-induced epididymitis. *Eur Urol*. 1996;29:497–498.
- Hansen CP, Mortensen S. Epididymo-orchitis and Reiter's disease. Two infrequent complications after intravesical Bacillus Calmette-Guérin therapy. *Scand J Urol Nephrol*. 1997;31:317–318.
- Hill RB Jr. Bilateral papillary, hyperplastic nodules of epididymis. *J Urol*. 1962;87:155–158.
- Hood SV, Bell D, McVey R, Wilson G, Wilkins EGL. Prostatitis and epididymo-orchitis due to *Aspergillus fumigatus* in a patient with AIDS. *Clin Infect Dis*. 1998; 26:229–231.
- Hoosen AA, O'Farrell N, van der Ende J. Microbiology of acute epididymitis in a developing community. *Genitourin Med*. 1993;69:361–363.
- Hutcheson J, Peters CA, Diamond DA. Amiodarone induced epididymitis in children. *J Urol*. 1998;160:515–517.
- Institute of Medicine. In: Eng TR, Bulter WT, eds. *Committee on prevention and control of sexually transmitted diseases. The hidden epidemic: Confronting sexually transmitted diseases*. Washington: National Academy Press; 1997.
- Kallie NR, Fisher GF, Harker JR. Papillary cystadenoma of the epididymis. *Can J Surg*. 1983;26:174–175.
- Kashiwagi B, Okugi H, Morita T, Kato Y, Shibata Y, Yamanaka H. Acute epididymo-orchitis with abscess formation due to *Pseudomonas aeruginosa*: report of 3 cases. *Hinyokika Kyo*. 2000;46:915–918.
- Kim SH, Pollack HM, Cho KS, Pollack M, Han MC. Tuberculous epididymitis and epididymo-orchitis: sonographic findings. *J Urol*. 1993; 150:81–84.
- Kollias G, Kyriakopoulos M, Tiniakos G. Epididymitis from *Enterobius vermicularis*: case report. *J Urol*. 1992;147:1114–1116.
- Krieger JN. Epididymitis, orchitis, and related conditions. *Sex Transm Dis*. 1984;11:173–181.
- Lattimer JK. Editorial comment. *J Urol*. 1983;129:613.
- Likitnukul S, McCracken GJ Jr, Nelson JD, Votteler TP. Epididymitis in children and adolescents. A 20-year retrospective study. *Am J Dis Child*. 1987;141:41–44.
- Lyne JC, Flood HD. Bilateral fungal epididymo-orchitis with abscess. *Urology*. 1995;46:412–414.
- Martin PM, Gresenguet G, Herve VM, Renom G, Steenman G, Georges AJ. Decreased number of spermatozoa in HIV-1-infected individuals. *AIDS*. 1992;6:130.
- Matsuoka K, Yano H, Inoue M, Iida S, Hirabayashi Y, Noda S. Xantho-granulomatous epididymitis. *BJU Int*. 2001;87:275–276.
- McClure J. A cause of malacoplakia of the epididymis associated with trauma. *J Urol*. 1980;124:934–935.
- McVie JL, Bani-Hani K, Bury RW, Duthie R, Walker SJ. Tuberculosis as a cause of chronic epididymo-orchitis in a male caucasian. *Hosp Med*. 2000;61:670–671.
- Melloul M, Paz A, Lask D, Manes A, Mukamel E. The value of radio-nuclide scrotal imaging in the diagnosis of acute testicular torsion. *Br J Urol*. 1995;76:628–631.
- Menke JJ, Heins JR. Epididymo-orchitis following intravesical bacillus Calmette-Guérin therapy. *Ann Pharmacother*. 2000;34:479–482.
- Merlini E, Rotundi F, Seymandi PL, Canning DA. Acute epididymitis and urinary tract anomalies in children. *Scand J Urol Nephrol*. 1997;32: 273–275.
- Moss WM. A comparison of open-end versus closed-end vasectomies: a report on 6220 cases. *Contraception*. 1992;46:521–525.
- Muller CH, Coombs RW, Kreiger JN. Effects of clinical stage and immunological status on semen analysis results in human immunodeficiency virus type 1-seropositive men. *Andrologia*. 1998;30(suppl 1): 15–22.
- Munden MM, Trautwein LM. Scrotal pathology in pediatrics with sonographic imaging. *Curr Probl Diagn Radiol*. 2000;29:185–205.
- National Institutes of Health. In: NIAID Study Group. *National Institutes of Health publication 81–2213: Sexually Transmitted Diseases 1980 Status Report*. Washington: US Government Printing Office; 1981.
- National Institutes of Health. *National Institute of Allergy and Infectious Diseases Fact Sheet*. Bethesda, MD: Public Health Service; 1998.
- Nistal M, Mate A, Paniagua R. Granulomatous epididymal lesion of possible ischemic origin. *Am J Surg Pathol*. 1997;21:951–956.
- O'Connell HE, Russell JM, Schultz TC. Delayed epididymitis following intravesical bacillus Calmette-Guérin administration. *Aus N Zeal J Surg*. 1993;63:70–72.
- Perrouin-Verbe B, Labat JJ, Richard I, Mauduyt del la Greve I, Buzelin JM, Mathe JF. Clean intermittent catheterisation from the acute period in spinal cord injury patients. Long term evaluation of urethral and genital tolerance. *Paraplegia*. 1995;33:619–624.
- Pichler WJ, Schindler L, Staubli M, Stadler BM, de Weck AL. Anti-amiodarone antibodies: detection and relationship to the development of side effects. *Am J Med*. 1988;85:197–202.
- Pudney J, Anderson D. Orchitis and human immunodeficiency virus type

- 1 infected cells in reproductive tissues from men with the acquired immune deficiency syndrome. *Am J Pathol.* 1991;139:149–160.
- Rotolo JE. Refractory epididymitis and ejaculatory duct obstruction. *J Urol.* 1995;154:1863–1864.
- Ryan DM, Lesser BA, Crumley LA, Cartwright HA, Person S, Hass GP, Bower G. Epididymal sarcoidosis. *J Urol.* 1993;149:134–136.
- Sadek I, Biron P, Kus T. Amiodarone-induced epididymitis: report of a new case and literature review of 12 cases. *Can J Cardiol.* 1993;9:833–836.
- Sarma PS, Raghava R. Acute epididymo-orchitis preceding *Escherichia coli* septicaemia. *J Assoc Physicians India.* 1995;43:643–644.
- Sawyer EK, Anderson JR. Acute epididymitis: a work-related injury? *J Natl Med Assoc.* 1996;88:385–387.
- Schmidt S, Morris R. Spermatic granuloma: the complication of vasectomy. *Fertil Steril.* 1973;24:941–947.
- Schned AR, Selikowitz SM. Epididymitis nodosa. *Arch Pathol Lab Med.* 1986;110:61–64.
- Secil M, Goktay AY, Dicle O, Yorukoglu K. Bilateral epididymal candida abscess: sonographic findings and sonographically guided fine-needle aspiration. *J Clin Ultrasound.* 1998;26:413–415.
- Shan YH, Schinella RA, Draper JW. Papillary clear cell cystadenoma of the epididymis. *J Urol.* 1968;100:661–665.
- Sharpiro ST, Breschi LC. Acute epididymitis in Vietnam: review of 52 cases. *Mil Med.* 1973;138:643–645.
- Sherrick JC. Papillary cystadenoma of the epididymis. *Cancer.* 1956;9:403–407.
- Skoutelis A, Marangos M, Petsas T, Chionis I, Barbaliias G, Bassaris H. Serious complications of tuberculous epididymitis. *Infection.* 2000;28:193–195.
- Slavis SA, Kollin J, Miller JB. Pyocele of scrotum: consequence of spontaneous rupture of testicular abscess. *Urology.* 1989;33:313–316.
- Suzer O, Ozcan H, Kupeli S, Gheiler EL. Color Doppler imaging in the diagnosis of the acute scrotum. *Eur Urol.* 1997;32:457–461.
- Thind P, Brandt B, Kristensen JK. Assessment of voiding dysfunction in men with acute epididymitis. *Urol Int.* 1992;48:320–322.
- Truelson T, Wishnow KI, Johnson DE. Epididymo-orchitis developing as a late manifestation of intravesical Bacillus Calmette-Guérin therapy and masquerading as a primary testicular malignancy: a report of 2 cases. *J Urol.* 1992;148:1534–1535.
- Von Schnakenburg C, Hinrichs B, Fuchs J, Kardorff R. Post-transplant epididymitis and orchitis following *Listeria monocytogenes* septicaemia. *Pediatr Transplant.* 2000;4:156–158.
- Vordermark JS. Acute epididymitis: experience with 123 cases. *Mil Med.* 1985;150:27–30.
- Weber DM, Rosslein R, Fliegel C. Color Doppler sonography in the diagnosis of acute scrotum in boys. *Eur J Pediatr Surg.* 2000;10:235–241.
- Weidner W, Jantos C, Schumacher F, Schiefer HG, Meyhofer W. Recurrent haemospermia—underlying urogenital anomalies and efficacy of imaging procedures. *Br J Urol.* 1991;67:317–323.
- Weidner W, Ludwig M, Miller J. Therapy in male accessory gland infection—what is fact, what is fiction? *Andrologia.* 1998a;30(suppl 1):87–90.
- Weidner W, Schill W-B, Schroeder-Printzen I, Kohn F-M. Editorial. *Andrologia.* 1998b;30(suppl 1):1.
- Wilbert DM, Schaerfe CW, Stern WD, Strohmaier WL, Bichler KH. Evaluation of the acute scrotum by color-coded Doppler ultrasonography. *J Urol.* 1993;149:1475–1477.
- Williams PB, Henderson RJ, Sanusi ID, Venable DD. Ultrasound diagnosis of filarial funiculoepididymitis. *Urology.* 1996;48:644–646.
- Wolf JS Jr, McAninch JW. Tuberculous epididymo-orchitis: diagnosis by fine needle aspiration. *J Urol.* 1991;145:836–838.
- Yazbeck S, Patriquin H. Accuracy of Doppler sonography in the evaluation of acute conditions of the scrotum in children. *J Pediatr Surg.* 1994;29:1270–1272.
- Yazici H. Behçet's syndrome. In: Klippel J, Dieppe P, eds. *Rheumatology.* St Louis, Mo: Mosby-Year Book; 1994:1–6.