

# Inflammatory Conditions of the Male Excurrent Ductal System. Part II.

## Review

PETER T. K. CHAN AND PETER N. SCHLEGEL

*From the James Buchanan Brady Foundation,  
Department of Urology, New York Presbyterian  
Hospital–Weill Medical College of Cornell University;  
and The Population Council, Center for Biomedical  
Research, New York, New York.*

In Part I of the review, we discussed epididymitis, a commonly encountered clinical entity, and the rarely described efferent ductule inflammation. In Part II of the review, we focus on another rarely described inflammatory condition of the excurrent ductal system; namely, vasitis. In addition, the management issues and effects of the various excurrent ductal inflammatory conditions on fertility will be discussed.

### ***Inflammatory Conditions of the Vas Deferens***

Anatomically, the vas deferens is a peculiar structure in that its muscular wall is thick and its lumen is extremely small. In fact, it is the only tubular organ of the human body in which the diameter of the lumen is less than the thickness of the wall. Any mucosal changes or muscle discontinuity can result in serious impedance of the free transmission of spermatozoa along its lumen.

In the epididymis, inflammatory lesions are the most frequently encountered pathological conditions in the vas deferens. Other pathological entities, such as a primary neoplasm of the vas deferens, are extremely rare. Vasitis nodosa is by far the most commonly described inflammatory condition of the vas deferens in the literature. Other inflammatory conditions, including infectious vasitis, will be discussed in this section.

#### *Vasitis Nodosa*

Originally described in 1943 (Benjamin et al, 1943), vasitis nodosa is a benign disorder characterized macroscopically by nodularity of the vas. Microscopically, there is perivascular proliferation of tubules lined with epithelium and stromal inflammation with infiltration of histiocytes,

polymorphonuclear leukocytes, and Langerhans giant cells (Figure 1). This condition is pathologically similar to salpingitis isthmica nodosa in females. Idiopathic vasitis nodosa is rare. Only 90 well-documented cases were reported up to the early 1980s since its first description. The pathogenesis of this condition is now known to be associated with obstruction or injury to the vas deferens, resulting in leakage of spermatozoa, causing a characteristic inflammatory reaction with excessive regeneration of the vasal epithelial lining. With the increasing popularity of vasectomy for contraception, vasitis nodosa is found in as many as 50%–66% of vasectomized men in large series (Kiser et al, 1986; Hirschowitz et al, 1988). Other clinical settings in which pathological diagnosis of vasitis nodosa is reported include severe chronic cystitis, bladder diverticulum, prostate cancer (Civantos et al, 1972), and primary infertility (Taxy et al, 1981).

Patients with vasitis nodosa are generally asymptomatic (Kiser et al, 1986). The physical finding of a nodule in the vas deferens is often described, although it is not a reliable or specific finding. An accurate diagnosis can be made only histologically. In postvasectomy patients in whom vasitis nodosa is most commonly found, associated histological abnormalities include sperm granulomas, mucinous metaplasia of the proliferating ductules, and hyperplasia of nerves in the perivascular tissues. The incidence of vasitis nodosa does not seem to increase after the first few months following vasectomy, suggesting that vasitis develops, if at all, within this period (Hirschowitz et al, 1988). The pathogenesis of vasitis nodosa is believed to be secondary to increased vasal luminal pressure causing disruption of the epithelial lining and extravasation of the highly immunogenic spermatozoa into the surrounding tissue (Olson, 1971; Civantos et al, 1972). This inflammatory reaction and the growth of epithelial cells from the vasal mucosa into the inflamed tissues result in formation of the proliferating ductules. Chronic inflammation of the ductal epithelium may initiate the mucinous metaplasia often seen in this condition.

Earlier reports noted that vasitis nodosa may mimic carcinoma (Graham and O'Connor, 1954; Civantos et al, 1972; Davies, 1973; Costa, 1977; Taxy, 1978). The epithelial atypia, mitotic activity, and neural or vascular invasion by the proliferating tubules in some cases make the identification of this benign process difficult. Vasitis nodosa, however, can be differentiated from carcinoma by the presence of a characteristic branching ductal pattern

Correspondence to: Peter T.K. Chan MD, 4908 Ponsard Avenue, Montreal, Quebec Canada H3W 2A4 (e-mail: sperminator\_II@hotmail.com).

Received for publication April 23, 2001; accepted for publication November 7, 2001.

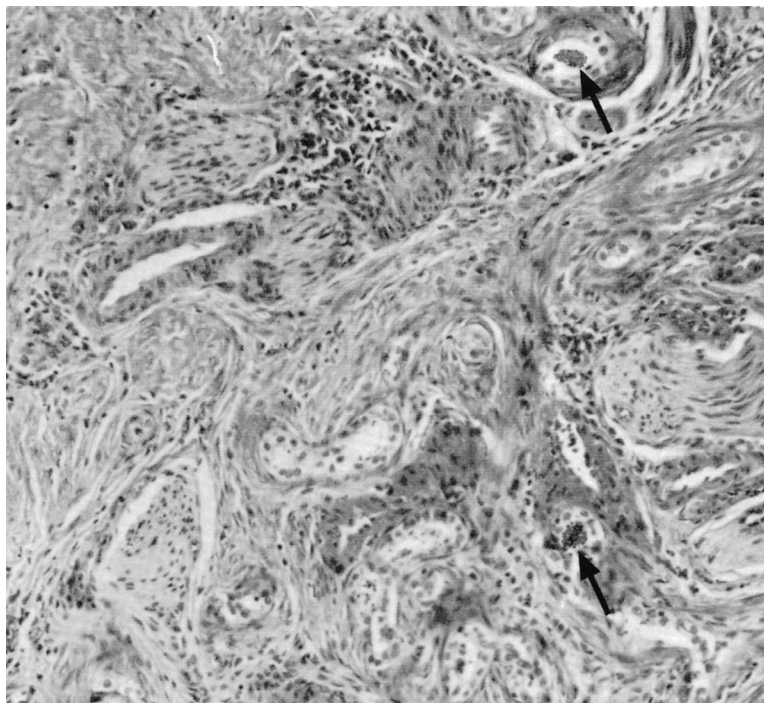


Figure 1. Vasitis nodosa. Note the presence of intraluminal spermatozoa (arrows). Original magnification 200 $\times$ .

(Warner et al, 1983; Balogh and Travis, 1984) and the presence of intraluminal or intramural spermatozoa or fragments of spermatozoa identifiable with hematoxylin and eosin staining or electron microscopy. Immunohistochemistry can also be used to confirm the diagnosis of vasitis nodosa (Sakaki et al, 2000). The mechanism by which the apparently benign tissue acquires the ability to proliferate and invade neuronal tissue remains speculative (Balogh and Travis, 1985), although neural invasion by benign tissue of prostatic, pancreatic, breast, and skin origin has been described (Davies, 1973; Costa, 1977; Carstens, 1980; Lapins and Helwig, 1980).

Vasitis nodosa per se is a benign condition that requires no specific treatment. With the increasing popularity of microsurgical vasovasostomy to restore fertility, vasitis nodosa now is often an "incidental" surgical finding in men with previous vasectomy. The presence of vasitis nodosa does not seem to affect the surgical outcome of vasovasostomy (Hirschowitz et al, 1988). It is interesting that the finding of a sperm granuloma during vasovasostomy, which is often associated with vasitis nodosa in men with previous vasectomy, is generally considered a sign of favorable outcome of the surgery. Silber (1977) suggested that sperm granuloma, formed by leakage of spermatozoa causing a local inflammation, acted as a "safety valve" to relieve the high pressure in the testis and epididymis, thereby preventing disruption of epididymal tubules due to high intraluminal pressure.

Among men with a distant history of previous vasectomy, up to 10% have motile sperm found in a centrifuged pellet of semen (Lemack and Goldstein, 1996). Vasitis nodosa has been implicated as a cause of late failure of vasectomy (Olson, 1971; Civantos et al, 1972; Philp et al, 1984). The proliferating ductules in vasitis nodosa are believed to act as channels for spermatozoa to pass through the vasal gap (Schmidt, 1966; Pugh and Hanley, 1969), although this view has been challenged by other investigators (Freund et al, 1989).

#### *Infectious Vasitis*

Although most infections of the vas deferens are seen in association with epididymo-orchitis or acute prostatitis, rare cases of primary infectious vasitis have been reported (Wolbarst, 1933; Veenema and Lattimer, 1957; Bissada and Redman, 1976; Ryan and Harte, 1988). Pathogens causing infectious vasitis include common urinary tract pathogens such as *Escherichia coli*, mycobacteria causing tuberculosis, and other rare urogenital pathogens such as *Haemophilus influenzae*. Patients with infectious vasitis usually present with a mass in the groin or scrotal spermatic cord. Thus, vasitis should be included in the differential diagnosis in patients with such presentations. The principle in the treatment of vasitis is identical to treating other urogenital infections. Bacterial culture of blood, urine, and semen may be required to identify the pathogen. Appropriate antibiotic treatment should be ini-

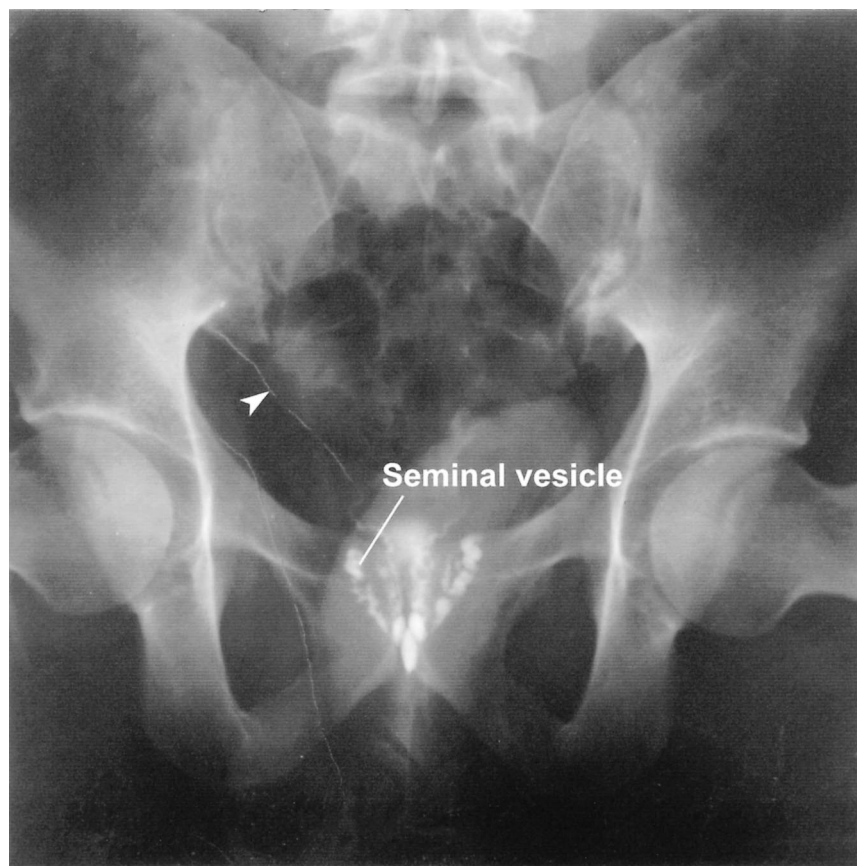


Figure 2. Vasography demonstrating patency of the right vas (arrow head). Reflux of contrast medium into the seminal vesicles is a normal finding. Left seminal vesicle retained contrast medium from a left vasography performed previously. In this vasogram, no contrast has passed into the urethra, suggesting obstruction of the ejaculatory ducts.

tiated. Surgical exploration with drainage may be required in severe cases or when other scrotal pathology, such as testicular torsion, is present.

#### *Other Inflammatory Conditions of the Vas Deferens*

Inflammation and resulting fibrosis are basic features of the healing process. In general, the severity of the insult dictates the amount of inflammation, final scarring, and subsequent functional impairment. Injury to the vas may occur with excessive surgical manipulation. The vulnerability of the vas deferens to injury has been demonstrated in animal studies (Shandling and Janik, 1981; Bengt and Jordan, 1993). Signs of inflammatory reaction were noted in all layers of the vas even after simple digital compression of the vas deferens for 30 seconds (Shandling and Janik, 1981). The clinical implication of the vulnerability of the vas to injury is significant, considering the volume of surgery, including inguinal hernia repairs, that occur in close proximity to the vas deferens. This is of particular concern in the pediatric population, in whom difficulty in identifying anatomical structures due to their small size increases the risk of vasal injury.

Iatrogenic inflammation of the vas deferens has also been associated with vasography, in which radio-opaque contrast material is injected into the vasal lumen and a radiograph obtained (Figure 2). Since its first description by Belfield in 1913, vasography has been used for the evaluation of obstructive azoospermia, staging of prostate cancer, and in evaluation and treatment of persistent perineal pain. With the introduction of various new diagnostic modalities, vasography, although still performed nowadays, has more specific indications. The most common clinical setting in which vasography is indicated is during microsurgical vasovasostomy or vasoepididymostomy to confirm the patency of the distal segments of the vas. The technique of performing the procedure, with the introduction of microsurgery, is more refined (Goldstein, 1995), and the use of radio-opaque contrast material can often be omitted.

The extent of inflammation in the vas after vasography often involves areas far beyond the site of injection, depending on the pressure of injection and the type of contrast materials used (Mumford and Davis, 1979; Bertram et al, 1985). Injection of saline or Ringers lactate is as-



sociated with the least inflammatory response. Water soluble, nonionic contrast media entail a low risk of inflammation in animal studies. Oil-based contrast agents are associated with the highest risk of vasitis (Bertram et al, 1985). Clinically, the inflammatory reaction may lead to vasal stenosis or even complete obstruction. The choice of contrast medium for radiographic vasography should thus be a hydrophilic nonionic contrast at low concentration.

Percutaneous intravasal injection of various materials, such as polyurethane or silicone rubber, has been tested in men as a potential method of contraception (Zhao, 1991; Chen et al, 1996). This method of contraception, which is potentially reversible (Zhao, 1991), has been evaluated in a prospective study (Chen et al, 1992). These authors concluded that vasal injection of polyurethane is less effective than vasectomy with higher short-term and long-term complications. In a follow-up morphological study (Chen et al, 1996), it was noted that the disappearance of spermatozoa in ejaculate was not due to occlusion of the vasal lumen by polyurethane. Instead, the procedure causes rupture of the vas deferens, resulting in leakage of the injected material, and causing an inflammatory reaction that eventually occluded the vas lumen. At the present time, the method of male contraception by intravasal injection remains experimental.

### **Management of Excurrent Ductal Inflammation**

Most cases of inflammation and infection of the excurrent ductal system are amenable to pharmacological treatment. Appropriate agents include antimicrobials, and anti-inflammatory and analgesic agents. Adjunctive measures such as bed rest, ice packs, and scrotal elevation to improve lymphatic drainage and to decrease the extent of edema may provide relief of symptoms. As previously emphasized, prompt and proper diagnosis of the underlying etiology of the infection or inflammation is the key step to guide the appropriate treatment and to rule out other significant underlying pathologies, such as testicular torsion or neoplasm. The importance of patient education cannot be overemphasized. Young adults with history of sexually transmitted infections (STIs) are at risk of recurrent infection. Educating patients on the use of barrier protection, identifying and treating sexual partners, and life style modifications are important preventive measures that all clinicians should take. Patients with underlying medical conditions predisposing them to infections should be educated to identify early signs of infection.

In severe cases, particularly infection in immunocompromised hosts, more aggressive management is often

necessary. Various imaging modalities, including sonography (Wilbert et al, 1993), computed tomography, radionuclide scintigraphy (Chen et al, 1983), and magnetic resonance imaging (Kim et al, 1997) may facilitate diagnosis. Surgical aspiration with imaging guidance and drainage of abscesses may be required for diagnostic or therapeutic purposes.

Chronic inflammation of the epididymis may produce intractable pain. Not infrequently, these patients may fail conservative management, including pharmacological, local anesthesia, and even psychological/behavioral therapy. Microsurgical or retroperitoneal denervation of the spermatic cord has had a reported success rate of 80% of cases in a recent small series (Levine et al, 1996; Cadeddu et al, 1999). Epididymectomy may be considered in severe cases. Obviously, epididymectomy has a serious effect on the fertility of the patient, and the procedure may also jeopardize the blood supply of the testicle, causing ischemic atrophy. The results of this invasive procedure for chronic epididymitis, however, are not satisfactory, because 30% to 90% of these patients have persistent scrotal pain (Padmore et al, 1996), with some patients eventually proceeding to removal of the ipsilateral testicle. In addition, a significant proportion of these patients have histologically normal epididymides. The etiology of chronic intrascrotal pain in these patients is uncertain. This further highlights the importance of careful selection of patients and adequate preoperative counseling.

Another indication for epididymectomy is persistent intrascrotal pain postvasectomy, which may occur in up to one-third of patients (McMahon et al, 1992). The etiology of this postvasectomy epididymalgia remains speculative. It may be due to increased intraluminal pressure due to vasal obstruction. Perineural fibrosis has also been postulated as a factor (Sweeney et al, 1998). Although some andrologists will first attempt to reverse the vasectomy by performing a vasovasostomy, epididymectomy, with removal of the vas deferens up to the vasal gap from vasectomy, may be offered in selected patients who are refractory to other treatments. Epididymectomy for this group of patient has been reported to be effective in 50%–95% of cases (Selikowitz and Schned, 1985; Chen and Ball, 1991; West et al, 2000).

As previously discussed, infectious epididymitis may be due to reflux of pathogens from the lower urinary tract via the vas deferens to the epididymis. Men who have indwelling urethral catheters are at particular risk for recurrent epididymitis. If more conservative measurement, such as intermittent catheterization, is not able to control recurrent epididymitis, suprapubic cystostomy or prophylactic vasectomy may be performed to prevent reflux of pathogens to the epididymis (Hoppner et al, 1989, 1992; Thirumavalavan and Ransley, 1992).

## Inflammation of the Reproductive Tract and Fertility

### Detection of Genital Tract Infections

The association between genital tract infections and abnormal semen parameters, such as azoospermia, oligoasthenoteratozoospermia, increased antisperm antibody levels, and ejaculation disturbances is accepted by the World Health Organization (1992). Diagnosis and treatment of documented genitourinary infections are essential in the initial management of couples who present with infertility. However, a large proportion of genital tract infection in men is asymptomatic, making it a challenge to define a clinically significant infection. The prevalence of genital infection among infertile men varies from 10% to 20% (World Health Organization, 1992). Besides regional factors, this variability may result from differences in diagnostic accuracy and criteria.

The significance of leukocytospermia in semen samples is controversial (Aitken and Baker, 1995), but its presence is regarded as an indicator of genital tract infection (World Health Organization, 1992). However, a poor correlation exists between the various methods of detecting semen leukocytes, including cytological identification, immunocytochemistry, monoclonal antibody labeling, reactive oxygen species measurement, and leukocyte peroxidase tests. Many of these methods are labor-intensive and costly, and may not be routinely available in many clinical andrological laboratories. Furthermore, the cutoff level of leukocytes, which is diagnostic of leukocytospermia ( $<1.0 \times 10^6/\text{mL}$ ) is an empiric one (Aitken and Baker, 1995).

The use of leukocytospermia as an indicator of genital tract infection in asymptomatic men has significant limitations. In many men with leukocytospermia, the condition will resolve without treatment (Yanushpolsky et al, 1995). In one study (Wolff, 1995), 54% of 100 men with leukocytospermia had a completely negative semen microbiology and serology. Whereas approximately 25% of men with leukocytospermia had antibodies against *Chlamydia trachomatis*, almost as many nonleukocytospermic samples have the same finding. Likewise, other pathogens, including *Ureaplasma urealyticum*, *Proteus mirabilis*, *Mycoplasma hominis*, *Escherichia coli*, and *Enterococcus*, are detected at similar frequencies in leukocytospermic or nonleukocytospermic samples. Several studies have reported the use of other biochemical or physical markers in men to help diagnose inflammation of the reproductive tract or differentiating bacterial infection versus bacterial contamination of the specimen. These semen markers include magnesium, inorganic phosphate (Adamopoulos and Deliyannis, 1983), citric acid (Comhaire

### Indigenous flora of the male urogenital tract\*

---

*Staphylococcus* (coagulase-positive and coagulase-negative)  
*Streptococcus*  
*Enterobacter*  
*Acinetobacter*  
*Corynebacterium*  
*Neisseria*  
*Mycobacterium*  
*Peptococcus*  
*Peptostreptococcus*  
*Bacteroides*  
*Fusobacterium*  
*Mycoplasma*  
*Candida*

---

\* Adapted from Schiefer, 1998.

et al, 1989), interleukin-6 (Zalata et al, 1995; Depuydt et al, 1996) and interleukin-8 (Koumantakis et al, 1998).

It is recommended that microbiological study of semen be performed in asymptomatic infertile men with leukocytospermia. Aerobic and anaerobic culture of semen can detect a wide range of urogenital pathogens. *Chlamydia trachomatis* can be detected on McCoy cell cultures from urethral swabs. More recent and sophisticated tests have included the use of polymerase chain reaction or ligase chain reaction and enzyme-linked immunosorbent assay for the detection of antibodies against the chlamydial lipopolysaccharide (Palayekar et al, 2000).

Even the interpretation of a positive semen culture should be approached with caution. As many as 83% of healthy men may have a semen culture positive for aerobes and anaerobes. When evaluating microbiologic findings, the indigenous flora of the male urogenital tract and possible contamination of primarily sterile samples must be taken into consideration. The types and quantity of microbial colonization in the male urogenital tract depend on the patient's age, general health and hygienic status, anamnesis (history of STI or urinary tract infection and previous history of urogenital instrumentation), sexual activity (abstinent, monogamous, promiscuous), and sexual predilections (genital-genital, genital-oral, or genital-anal intercourse). One study demonstrated that genital cleansing with antibacterial soap can change the results of semen culture for a significant proportion of men (Kim and Goldstein, 1999). The spectrum of the resident flora ranges from avirulent to facultatively pathogenic organisms (Table) (Schiefer, 1998). These organisms comprise the normal male genital flora from the prostate, bulbourethral glands, or distal urethra. Thus, findings of a positive semen culture may not necessarily indicate a clinical infection (Willen et al, 1996). These controversies complicate management, especially the use of antibiotics or anti-inflammatory drugs, in men who present with infertility and signs of genital infection.

Some pathogens, however, are considered obligately

pathogenic. These include *Chlamydia trachomatis*, *Neisseria gonorrhoeae*, *Treponema pallidum*, *Mycobacterium tuberculosis*, *Haemophilus ducreyi*, Herpes simplex virus II and I, papilloma viruses, and *Trichomonas vaginalis*. Qualitative evidence of these obligately pathogenic microbes, or a distinct quantity increase of facultative pathogens, should indicate appropriate treatment.

An earlier study from the World Health Organization (Comhaire et al, 1986) reported that in infertile couples in whom male accessory gland inflammation (MAGI) in the male partner was the only abnormality detected, treatment with doxycycline did not influence the semen parameters nor enhance the probability of conception. More recent studies evaluating the effects of antibiotic treatment on semen quality and fertility of patients confirm this lack of improvement after antibiotic treatment (Comhaire and Zalata, 1996). Although this lack of effect may be due to difficulty in properly selecting asymptomatic men with true infection who require treatment, other factors such as inadequate penetration of antibiotics into the affected organs or irreversible functional damage caused by the infection should also be considered.

#### *Reproductive Significance of Various Inflammatory Conditions*

There is still a lack of concrete data with consistent evidence demonstrating a negative influence of subclinical infection and inflammatory diseases on male fertility status (Krause, 1994; Weidner et al, 1998; Diemer et al, 2000). Various mechanisms have been proposed on how various inflammatory conditions of the genital tract may lead to male infertility. Many of these notions, however, are still under debate (Eggert-Kruse et al, 1998; Michelmann, 1998; Wolff, 1998; Hales et al, 1999). Genital infections may affect the secretory function in seminal vesicles and prostate. MAGI may also lead to decreased epididymal secretion of alpha-glucosidase (Depuydt et al, 1998), which has been shown to have a positive effect on spermatozoa binding capacity and intrauterine insemination (Ben Ali et al, 1994; Milingos et al, 1996). Production of antisperm antibodies from cross-reactivity between certain epitopes on the bacterial surface and spermatozoa, particularly the carbohydrate determinants (Kurpisz and Alexander, 1995), has been reported to impair sperm fertilizing capacity (Clarke et al, 1985; Hinting et al, 1996).

Leukocyte products such as lymphokines, monokines, and reactive oxygen species have been shown to reduce sperm fertilizing ability (Hill et al, 1989; Henkel and Schill, 1998). Leukospermia has been associated with abnormal spermatozoal morphology, including elongated and small heads, tail and neck abnormalities, retention of cytoplasmic droplets, and abnormal acrosomal morphology (Menkveld and Kruger, 1998). Leukocytospermia

may also affect hyperactivation of spermatozoa during capacitation (Chan et al, 1994).

Bacterial inhibitory effect on sperm motility may be another mechanism. *E. coli* has been shown to have a significant negative effect on sperm motility (Diemer et al, 1996; Huwe et al, 1998). However, in some of these studies the titer of bacteria is much higher than that encountered in vivo. In fact, such inhibitory effects on sperm motility was not found with other pathogens such as *Staphylococcus saprophyticus*, *Pseudomonas aeruginosa*, and *Enterococcus* (Huwe et al, 1998; Kohn et al, 1998).

Acrosomal reaction is a prerequisite for spermatozoa to penetrate the zona pellucida and to fertilize the oocyte. Although the rate of spontaneous acrosomal reaction of spermatozoa does not correlate with the success rate of in vitro fertilization (IVF), the index of inducibility, measured by the difference between induced (after incubation with calcium ionophore or exposure to low temperature) and spontaneous acrosomal reaction, is of prognostic value for sperm fertilization capacity (Cummins et al, 1991; Henkel et al, 1993). Bacteria including *Ureaplasma urealyticum*, *E. coli*, and *Mycoplasma hominis* have been demonstrated to have a negative effect on ionophore-induced acrosomal reaction of human spermatozoa in vitro (Rose and Scott, 1994; El-Mulla et al, 1996; Kohn et al, 1998). Similar effects in vivo, however, were not documented. Kohn et al (1998) suggested that this may be due to the following factors: 1) intraindividual variations of inducibility of acrosomal reaction, 2) induction of acrosomal reaction by different stimulation protocols in the various studies, 3) lower concentration of bacteria in vivo, 4) protective effects of seminal plasma in vivo, 5) induction of acrosomal reaction by artificial systems in vitro, and 6) different serotypes of bacteria used for experiments.

Symptomatic genital urinary tract infections should be treated to avoid infection of the female partner, and secondary obstruction and dysfunction of the testes, epididymides, and accessory glands. However, with a lack of adequate evidence demonstrating an association between MAGI and fertility, the role of treating asymptomatic leukospermia or bacteriospermia in subfertile men and their partners, at a significant cost to the health care system without documented benefit, remains controversial.

Many studies have evaluated the effects of bacteriospermia on the success rate of IVF and concluded that there is no adverse effect of bacteria, and that prophylactic antibiotic therapy is unnecessary (Stovall et al, 1993; Claman et al, 1996; Liversedge et al, 1996; Bussen et al, 1997). Routine sperm washing during preparation for IVF may remove bacteria. The presence of antibiotics (penicillin and streptomycin) in the culture media in some IVF protocols may further eradicate bacteria not removed by



washing (Cottell et al, 1997). There has been a single case reported of a man with *E. coli* in semen and multiple previous IVF failures who achieved successful fertilization leading to pregnancy with testicular sperm aspiration and intracytoplasmic sperm injection (Seidman et al, 1999). However, a direct causal relationship between the presence of bacteria and fertilization failure has not been established.

Besides potentially affecting the physiological function of spermatozoa, MAGI may also lead to various obstructive causes of infertility. Inflammation leads to fibrosis, which in turn, may cause stenosis of the lumen along the male reproductive tract. Idiopathic obstructive azoospermia, in which a man has normal spermatogenesis with no apparent cause for the obstruction, may be either congenital or acquired, possibly due to MAGI. This condition can often be managed by microsurgical vasovasostomy or vasoepididymostomy to bypass the site of obstruction with a success rate of 70% or better (Goldstein et al, 1998; McCallum et al, 1999). Not uncommonly, however, signs of chronic inflammation at the sites of stenosis in the epididymal tubules or, less commonly, vas deferens, are noted intraoperatively. These observations suggest that patients may be unaware of a previous episode of inflammation of the excurrent ductal system or sex accessory glands.

## Conclusion

We have presented a comprehensive review of inflammatory conditions that are found in the vas deferens, epididymis, and efferent ductules. The sequelae of these inflammatory conditions may often have a severe effect on these organs, particularly in relation to fertility. Although effective treatments, both medical and surgical, are available for infections and their sequelae, recognition of the disease with prompt diagnosis is critical for successful management of these conditions and prevention of complications. Andrologists should thus be familiar with the wide clinical spectrum of pathologies that may be encountered in this unique organ system.

## References

Adamopoulos DA, Deliyannis V. Seminal plasma magnesium, calcium and inorganic phosphate concentration in normozoospermic and subfertile men. *Andrologia*. 1983;15:648-654.

Aitken RJ, Baker HWG. Seminal leukocytes: passengers, terrorists or good Samaritans? *Hum Reprod*. 1995;10:1736-1739.

Balogh K, Travis WD. The frequency of perineurial ductules in vasitis nodosa. *Am J Clin Pathol*. 1984;82:710-713.

Balogh K, Travis WD. Benign vascular invasion in vasitis nodosa. *Am J Clin Pathol*. 1985;83:426-430.

Belfield WT. Skiagraphy of the seminal ducts. *JAMA*. 1913;60:800.

Ben Ali H, Guerin JF, Pinatel MC, Mathieu C, Bouliou D, Tritar B. Relationship between semen characteristics, alpha-glucosidase and the capacity of spermatozoa to bind to the human zona pellucida. *Int J Androl*. 1994;17:121-126.

Benge BN, Jordan GH. Prepubertal vasal injury: its effect on postpubertal vas deferens. *J Urol*. 1993;149:906-909.

Benjamin JA, Robertson TD, Cheetham JG. Vasitis nodosa: a new clinical entity simulating tuberculosis of the vas deferens. *J Urol*. 1943;49:575-582.

Bertram RA, Carson CC, Szpak C. Vasography: effect of various agents on vas deferens patency. *J Urol*. 1985;133:1087-1089.

Bissada NK, Redman JF. Unusual masses in the spermatic cord: report of six cases and review of the literature. *South Med J*. 1976;69:1410-1412.

Bussen S, Zimmermann M, Schleyer M, Steck T. Relationship of bacteriological characteristics of semen indices and its influence on fertilization and pregnancy rates after IVF. *Acta Obstet Gynecol Scand*. 1997;76:964-968.

Cadeddu JA, Bishoff JT, Chan DY, Moore RG, Kavoussi LR, Jarrett TW. Laparoscopic testicular denervation for chronic orchialgia. *J Urol*. 1999;162:733-735.

Carstens PHB. Perineural glands in normal and hyperplastic prostates. *J Urol*. 1980;123:686-688.

Chan P, Su BC, Tredway DR, Whitney EA, Pang SC, Corselli J, Jacobson JD. White blood cells in semen affect hyperactivation but not sperm membrane integrity in the head and tail regions. *Fertil Steril*. 1994;61:986-989.

Chen DC, Holder LE, Melloul M. Radionuclide scrotal imaging: further experience with 210 new patients. Part 2: results and discussion. *J Nucl Med*. 1983;24:841-853.

Chen ZW, Gu YQ, Liang XW. Safety and efficacy of percutaneous injection of polyurethane elastomer (MPU) plugs for vas occlusion in human. *Int J Androl*. 1992;5:468-472.

Chen Z, Gu Y, Liang X, Shen L, Zou W. Morphological observations of vas deferens occlusion by the percutaneous injection of medical polyurethane. *Contraception*. 1996;53:275-279.

Chen TF, Ball RY. Epididymectomy for post-vasectomy pain: histological review. *Br J Urol*. 1991;68:407-413.

Civantos F, Lubin J, Rywlin AM. Vasitis nodosa. *Arch Pathol*. 1972;94:355-361.

Claman P, Toye B, Amimi MN, Jessamine P, Peeling RW. Does serologic evidence of remote *Chlamydia trachomatis* infection and its heat shock protein (CHSP 60) affect in vitro fertilization-embryo transfer outcome? *Fertil Steril*. 1996;65:146-149.

Clarke GN, Elliot PJ, Smaila C. Detection of sperm antibodies in semen using the immunobead test: a survey of 813 consecutive patients. *Am J Reprod Immunol*. 1985;7:118-123.

Comhaire FH, Rowe PJ, Farley TMM. The effect of doxycycline in infertile couples with male accessory gland infection: a double blind prospective study. *Int J Androl*. 1986;9:91-98.

Comhaire FH, Vermeulen L, Pieters O. Study of the accuracy of physical and biochemical markers in semen to detect infectious dysfunction of the accessory sex glands. *J Androl*. 1989;10:50-53.

Comhaire FH, Zalata A. Some aspects of male accessory gland infection, and its possible role in male infertility. In: Comhaire F, ed. *Male Infertility*. London: Chapman and Hall; 1996:261-266.

Costa J. Benign epithelial inclusions in pancreatic nerves. Letter to the Editor. *Am J Clin Pathol*. 1977;67:306-307.

Cottell E, Barry-Kinsella C, Lennon B, Harrison RF, McMorow J. Processing of semen in an antibiotic-rich culture medium to minimize microbial presence during in vitro fertilization. *Fertil Steril*. 1997;67:98-103.

Cummins JM, Pember SM, Jequier AM, Yovich JL, Hartmann PE. A test of the human sperm acrosome reaction following ionophore chal-

- lenge. Relationship to fertility and other seminal parameters. *J Androl.* 1991;12:98–103.
- Davies JD. Neural invasion in benign mammary dysplasia. *J Pathol.* 1973;109:225–231.
- Depuydt CE, Bosmans E, Zalata A, Schoonjans F, Comhaire FH. The relation between reactive oxygen species and cytokines in andrological patients with or without male accessory gland infection. *J Androl.* 1996;17:699–707.
- Depuydt C, Zalata A, Christophe A, Mahmoud A, Comhaire F. Mechanisms of sperm deficiency in male accessory gland infection. *Andrologia.* 1998;30(suppl 1):29–33.
- Diemer T, Weidner W, Michelmann HW, Schiefer HG, Rován E, Mayer F. Influence of *Escherichia coli* on motility parameters of human spermatozoa in vitro. *Int J Androl.* 1996;19:271–277.
- Diemer T, Ludwig M, Huwe P, Hales DB, Weidner W. Influence of urogenital infection on sperm function. *Curr Opin Urol.* 2000;10:39–44.
- Eggert-Kruse W, Rohr G, Probst S, et al. Antisperm antibodies and microorganisms in genital secretions—a clinically significant relationship? *Andrologia.* 1998;30(suppl 1):61–71.
- El-Mulla KF, Kohn FM, Dandal M, El Beheiry AH, Schiefer HG, Weidner W, Schill WB. In vitro effect of *Escherichia coli* on human sperm acrosome reaction. *Arch Androl.* 1996;37:73–78.
- Freund MJ, Weidmann JE, Goldstein M, Marmar J, Santulli R, Oliveira N. Microrecanalization after vasectomy in man. *J Androl.* 1989;10:120–132.
- Goldstein M. Vasography. In: Goldstein M. ed. *Surgery of Male Infertility.* Philadelphia: WB Saunders; 1995:26–32.
- Goldstein M, Li P-S, Matthews GJ. Microsurgical vasovasostomy: the microdot technique of precision suture placement. *J Urol.* 1998;159:188–190.
- Graham JB, O'Connor VJ. Spermatic cord tumors: review of literature and a case of an unusual vas deferens tumor in an infertility problem. *J Urol.* 1954;72:946–949.
- Hales DB, Diemer T, Hales KH. Role of cytokines in testicular function. *Endocrine.* 1999;10:201–217.
- Henkel R, Muller C, Miska W, Gips H, Schill WB. Determination of the acrosome reaction in human spermatozoa is predictive of fertilization in vitro. *Hum Reprod.* 1993;8:2128–2132.
- Henkel R, Schill W-B. Sperm separation in patients with urogenital infections. *Andrologia.* 1998;30(suppl 1):91–97.
- Hill JA, Cohen J, Anderson DJ. The effects of lymphokines and monokines on sperm fertilizing ability in the zona-free hamster egg penetration test. *Am J Obstet Gynecol.* 1989;160:1154–1159.
- Hinting A, Soebadi DM, Santoso RI. Evaluation of the immunological cause of male infertility. *Andrologia.* 1996;28:123–126.
- Hirschowitz L, Rode J, Guillebaud J, Bounds W, Moss E. Vaginitis nodosa and associated clinical findings. *J Clin Pathol.* 1988;41:419–423.
- Hoppner W, Kressel K, Lopez-Gamarrá D, Buchsel HP, Hartmann M. Operative therapy of epididymitis. *Urologe A.* 1989;28:31–35.
- Hoppner W, Strohmeyer T, Hartmann M, Lopez-Gamarrá D, Dreikorn K. Surgical treatment of acute epididymitis and its underlying diseases. *Eur Urol.* 1992;22:218–221.
- Huwe P, Diemer T, Ludwig M, Lui J, Schiefer HG, Weidner W. Influence of different uropathogenic microorganisms on human sperm motility parameters in an in vitro experiment. *Andrologia.* 1998;30(suppl 1):55–59.
- Kim FY, Goldstein M. Antibacterial skin preparation decreases the incidence of false-positive semen culture results. *J Urol.* 1999;161:819–821.
- Kim M-J, Lee JT, Lee MS, Suh JS, Yoo HS. MR imaging of male infertility with an endorectal surface coil. *Abdom Imaging.* 1997;22:348–353.
- Kiser GC, Fuchs EF, Kessler S. The significance of vaginitis nodosa. *J Urol.* 1986;136:42–44.
- Kohn F-M, Erdmann I, Oeda T, El-Mulla KF, Schiefer HG, Schill W-B. Influence of urogenital infections on sperm functions. *Andrologia.* 1998;30(suppl 1):73–80.
- Koumantakis I, Matalliotakis I, Kyriakou D, Fragouli Y, Relakis K. Increased levels of interleukin-8 in human seminal plasma. *Andrologia.* 1998;30(suppl 1):339–343.
- Krause W. Prostatitis and male infertility. In: Weidner W, Madsen PO, Schiefer HG, eds. *Prostatitis.* New York: Springer; 1994:91.
- Kurpysz M, Alexander NJ. Carbohydrate moieties on sperm surface: physiological relevance. *Fertil Steril.* 1995;63:158–165.
- Lapins NA, Helwig EB. Perineural invasion by Karatoacanthoma. *Arch Dermatol.* 1980;116:791–793.
- Lemack GE, Goldstein M. Presence of sperm in the pre-vasectomy reversal semen analysis: incidence and implications. *J Urol.* 1996;155:167–169.
- Levine LA, Matkov TG, Lubenow TR. Microsurgical denervation of the spermatic cord: a surgical alternative in the treatment of chronic orchialgia. *J Urol.* 1996;155:1005–1007.
- Liversedge NH, Jenkins JM, Keay SD, McLaughlin EA, Al-Sufyan H, Maile LA, Joels LA, Hull MGR. Antibiotic treatment based on seminal cultures from asymptomatic male partners in in-vitro fertilization is unnecessary and may be detrimental. *Hum Reprod.* 1996;11:1227–1231.
- McCallum SW, Berger RE, Goldstein M. Vasoepididymostomy. In: Vaughan ED, Perlmutter AP eds. *Atlas of Clinical Urology.* Philadelphia: Current Medicine; 1999:Chapter 13.
- McMahon AJ, Buckley J, Taylor A, Lloyd SN, Deane RF, Kirk D. Chronic testicular pain following vasectomy. *Br J Urol.* 1992;69:188–191.
- Menkveld R, Kruger TF. Sperm morphology and male urogenital infection. *Andrologia.* 1998;30(suppl 1):49–53.
- Michelmann HW. Influence of bacteria and leukocytes on the outcome of in vitro fertilization (IVF) or intracytoplasmic sperm injection (ICSI). *Andrologia.* 1998;30(suppl 1):99–101.
- Milingos S, Comhaire FH, Liapi A, Aravantinos D. The value of semen characteristics and tests of sperm function in selecting couples for intra-uterine insemination. *Eur J Obstet Gynecol Reprod Biol.* 1996;64:115–118.
- Mumford SD, Davis JE. Flushing of distal vas during vasectomy. *Urology.* 1979;14:433–441.
- Olson AL. Vaginitis nodosa. *Am J Clin Pathol.* 1971;55:364–368.
- Padmore DE, Norman RW, Millard OH. Analyses of indications for and outcomes of epididymectomy. *J Urol.* 1996;156:95–96.
- Palayekar VV, Joshi JV, Hazari KT, Shah RS, Chitlange SM. Comparison of four nonculture diagnostic tests for Chlamydia trachomatis infection. *J Assoc Physicians India.* 2000;48:481–3.
- Philp T, Guillebaud J, Budd D. Late failure of vasectomy after two documented analyses showing azoospermic semen. *Br Med J.* 1984;289:77–79.
- Pugh RBB, Hanley HG. Spontaneous recanalisation of the divided vas deferens. *Br J Urol.* 1969;41:340–347.
- Rose BI, Scott B. Sperm motility, morphology, hyperactivation, and ionophore-induced acrosome reactions after overnight incubation with mycoplasmas. *Fertil Steril.* 1994;61:341–348.
- Ryan SP, Harte PJ. Suppurative inflammation of vas deferens: an unusual groin mass. *Urology.* 1988;31:245–246.
- Sakaki M, Hirokawa M, Horiguchi H, Wakatsuki S, Sano T. Vaginitis nodosa: immunohistochemical findings—case report. *APMIS.* 2000;108:283–286.
- Sawyer EK, Anderson JR. Acute epididymitis: a work-related injury? *J Natl Med Assoc.* 1996;88:385–387.
- Schmidt SS. Techniques and complications of elective vasectomy. The role of spermatic granuloma in spontaneous recanalization. *Fertil Steril.* 1966;17:467–482.



- Selikowitz SM, Schned AR. A late post-vasectomy syndrome. *J Urol.* 1985;134:494–497.
- Shandling B, Janik JS. The vulnerability of the vas deferens. *J Pediatr Surg.* 1981;16:461–466.
- Schiefer HG. Microbiology of male urethroadnexitis: diagnostic procedures and criteria for aetiologic classification. *Andrologia.* 1998;30(suppl 1):7–13.
- Seidman DS, Madjar I, Levron J, Levran D, Mashiach S, Dor J. Testicular sperm aspiration and intracytoplasmic sperm injection for persistent infection of the ejaculate. *Fertil Steril.* 1999;71:564–566.
- Silber SJ. Microscopic vasectomy reversal. *Fertil Steril.* 1977;28:1191–1202.
- Stovall DW, Bailey LE, Talbert LM. The role of aerobic and anaerobic semen cultures in asymptomatic couples undergoing in vitro fertilization: effects on fertilization and pregnancy rates. *Fertil Steril.* 1993;59:197–201.
- Sweeney P, Tan J, Butler MR, McDermott TED, Grainger R, Thornhill JA. Epididymectomy in the management of intrascrotal disease: a critical reappraisal. *Br J Urol.* 1998;81:753–755.
- Taxy JB. Vaginitis nodosa. *Arch Pathol Lab Med.* 1978;102:643–647.
- Taxy JB, Marshall FF, Erlichman RJ. Vasectomy. Subclinical pathologic changes. *Am Surg Pathol.* 1981;5:767–762.
- Thirumavalavan VS, Ransley PG. Epididymitis in children and adolescents on clean intermittent catheterisation. *Eur Urol.* 1992;22:53–56.
- Veenema RJ, Lattimer JK. Genital tuberculosis in the male: clinical pathology and effect on fertility. *J Urol.* 1957;78:65–77.
- Warner JJ, Kirchner FK Jr, Wong SW, Dao AH. Vaginitis nodosa presenting as a mass of the spermatic cord. *J Urol.* 1983;129:380–381.
- Weidner W, Ludwig M, Miller J. Therapy in male accessory gland infection—what is fact, what is fiction? *Andrologia.* 1998;30(suppl 1):87–90.
- West AF, Leung HY, Powell PH. Epididymectomy is an effective treatment for scrotal pain after vasectomy. *BJU Int.* 2000;85:1097–1099.
- Wilbert DM, Schaerfe CW, Stern WD, Strohmaier WL, Bichler KH. Evaluation of the acute scrotum by color-coded Doppler ultrasonography. *J Urol.* 1993;149:1475–1477.
- Willen M, Holst E, Myhre EB, Olsson AM. The bacterial flora of the genitourinary tract in healthy fertile men. *Scand J Urol Nephrol.* 1996;30:387–393.
- Wolbarst AL. The vas deferens, generally unrecognized clinical entity in urogenital disease. *J Urol.* 1933;29:405–412.
- World Health Organization. *WHO Laboratory Manual for the Examination of Human Semen and Semen-Cervical Mucus Interaction.* 3rd ed. Cambridge, United Kingdom: Cambridge University Press; 1992.
- Wolff H. The biologic significance of white blood cells in semen. *Fertil Steril.* 1995;63:1143–1157.
- Wolff H. Methods for the detection of male genital tract inflammation. *Andrologia.* 1998;30(suppl 1):35–9.
- Yanushpolsky EH, Politch JA, Hill JA, Anderson DJ. Antibiotic therapy and leukocytospermia: a prospective, randomized, controlled study. *Fertil Steril.* 1995;63:142–147.
- Zalata A, Hafez T, van Hoecke MJ, Comhaire F. Evaluation of beta-endorphin and interleukin-6 in seminal plasma of patients with certain andrological diseases. *Hum Reprod.* 1995;10:3161–3165.
- Zhao SC. Methods of reversible vas occlusion by percutaneous injection of polyurethane and silicone rubber. In: Yuan T, ed. *Monograph of Vas Occlusion.* 1st ed. Shan Xi, China: Provincial Publishing House of Science and Technology; 1991:29–32.