

# Case Report: Orthodontic treatment of dental problems in incontinentia pigmenti

Takashi Yamashiro, DDS, PhD; Koichi Nakagawa, DDS, PhD; Kenji Takada, DDS, PhD

**I**ncontinentia pigmenti is an uncommon genodermatosis that occurs in female infants. The disease usually appears at birth or shortly thereafter. The initial symptom consists of erythematous eruption with linear vesiculation, followed a few weeks or months later by verrucous growths and spots of pigmentation, mostly on the torso. These spots gradually fade and usually disappear by adulthood.<sup>1,2</sup> Other characteristics include ocular anomalies, scalp abnormalities, nail dystrophy, dental anomalies, and disorders of the central nervous system.<sup>2,3</sup>

The characteristic dental defects in incontinentia pigmenti are partial anodontia and the presence of some peg-shaped teeth.<sup>2,4-8</sup> The deciduous and/or the permanent teeth may be involved. Late eruption of teeth is also observed in some cases.<sup>2</sup>

In this report, we present a patient with incontinentia pigmenti who exhibited multiple missing teeth in both the mandible and maxilla.

The patient also had malpositioned teeth and decreased occlusal vertical dimension associated with the missing teeth. Orthodontic treatment was required for prosthetic purposes. The characteristic dental anomalies of incontinentia pigmenti and the treatment procedures are discussed.

## Case report

The patient, a 21-year-old female, presented at the orthodontic clinic of the university dental hospital for evaluation of partial anodontia. A diagnosis of incontinentia pigmenti had been made at birth, when she was noted to have cutaneous vesicular lesions. These changed to brown lesions after a few weeks and then faded during the succeeding years. She showed no pigmented macules, and no other abnormalities were noted during childhood except partial anodontia and delayed eruption of deciduous and permanent teeth.

## Abstract

Incontinentia pigmenti is an uncommon genodermatosis that occurs in female infants. The characteristic dental defects are partial anodontia and the presence of some peg-shaped teeth. This report describes a patient with incontinentia pigmenti who exhibited multiple missing teeth in both arches. The patient had malpositioned teeth and decreased occlusal vertical dimension associated with the missing teeth. Orthodontic treatment was required for prosthetic purposes. The dental anomalies of incontinentia pigmenti and the treatment procedure are presented.

## Key words

Incontinentia pigmenti • Missing teeth

Submitted and accepted for publication: August 1996

Angle Orthod 1998;68(3):281-284.

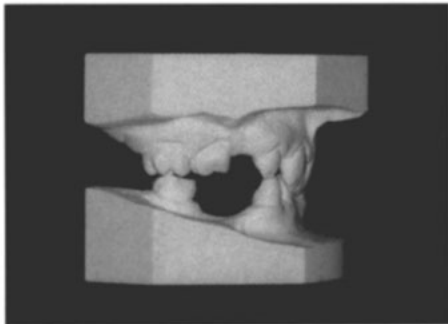

Figure 1A

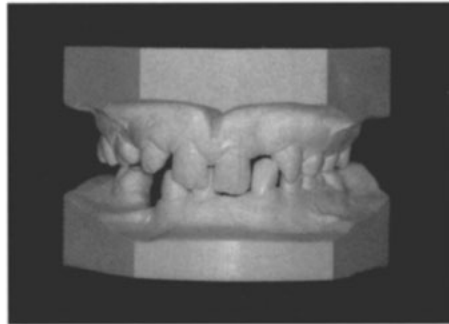


Figure 1B

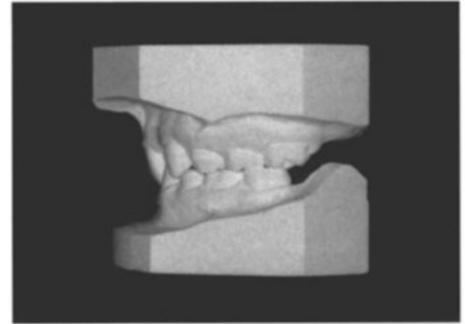


Figure 1C

Figure 1A-E

Pretreatment study casts. Note the multiple missing teeth in both arches. The lower right canine and lower left premolar were peg-shaped. The residual teeth migrated to neighboring and opposing edentulous spaces.

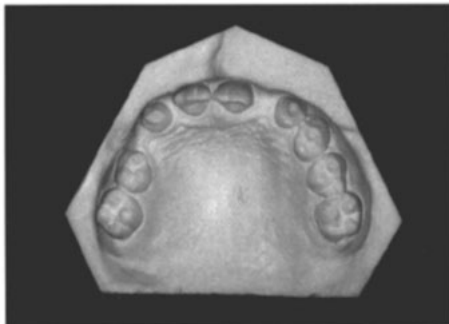


Figure 1D

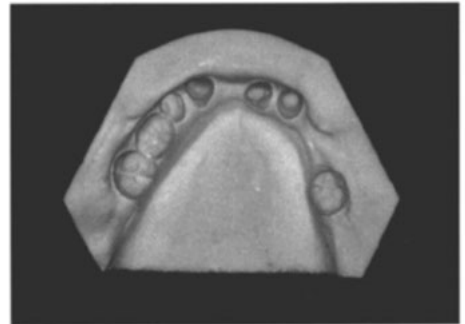


Figure 1E

Figure 2

Pretreatment facial photographs. The chin appeared prominent and the lower lip retrusive.



Figure 2A

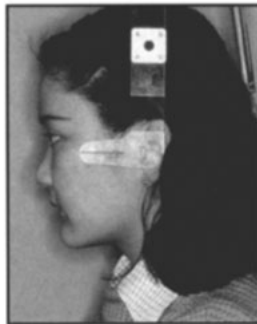

Figure 2B

Figure 3

Pretreatment panoramic radiograph. Note multiple missing teeth in the upper and lower arches.

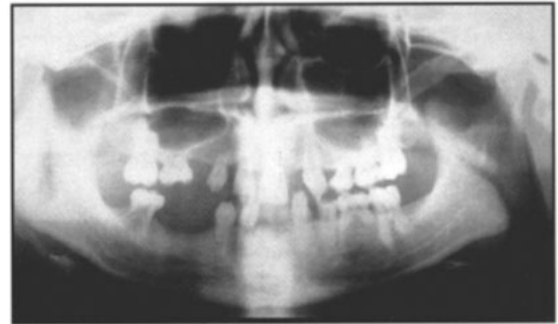

Figure 3

Upon examination of the dentition, multiple missing teeth were observed in both arches. The lower right canine and lower left premolar were peg-shaped, the upper central incisors were extruded, and the left central incisor was in contact with the opposing crest of the mandible (Figure 1). No other problems were observed in the oral hard or soft tissues.

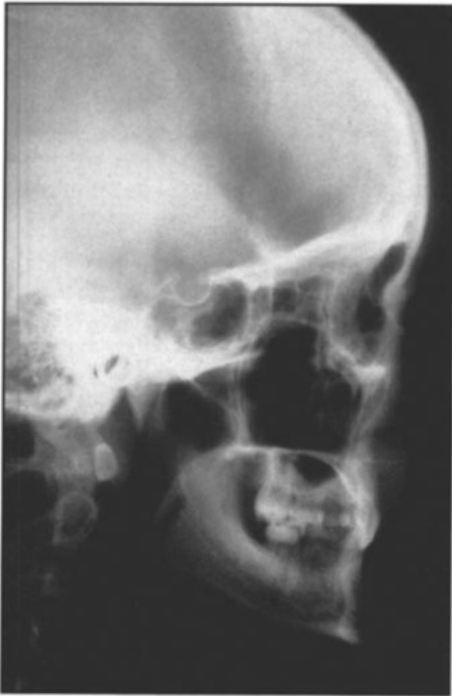The clinical examination revealed chin prominence and a retrusive lower lip (Figure 2A-B). There was no active periodontal disease or dental caries, and no clinical signs of jaw dysfunction. The panoramic radiograph revealed no dentofacial abnormalities other than multiple missing teeth (Figure 3). Cephalometrically, the patient had a skeletal Class III jaw relationship (ANB=-1°) and a low mandibular plane angle

(FMA=17°, Figure 4). The maxilla and mandible were normal in size. Upper and lower incisors were lingually inclined (U1/FH=95°, L1-MP=77°).

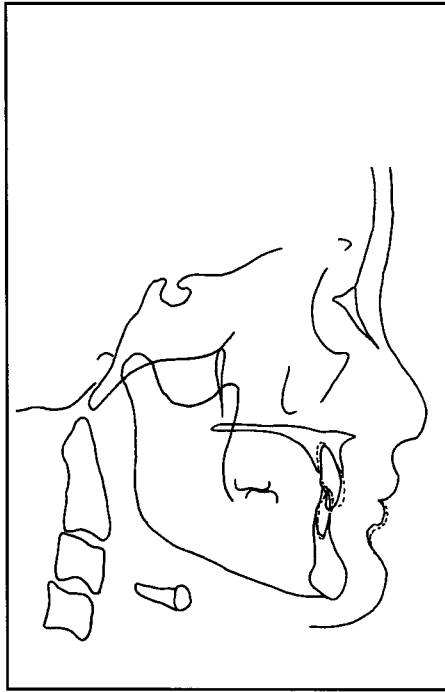
Because some teeth had migrated into the edentulous spaces, prosthetic reconstruction would be difficult without excessive tooth preparation. Therefore, orthodontic treatment was planned to reposition the teeth.

#### Discussion

This patient had multiple missing teeth in both jaws. In addition, the upper right canine and lower right premolar were peg-shaped. According to Carney,<sup>4</sup> partial anodontia and peg-shaped or otherwise malformed teeth are the most common anomalies associated with incontinentia



**Figure 4**



**Figure 5**

**Figure 4**  
Pretreatment cephalometric radiograph. The patient showed a skeletal Class III jaw-base relationship and low mandibular plane angle.

**Figure 5**  
Superimposed pretreatment and post-treatment tracings.

*pigmenti*, occurring in 30% and 43% of patients, respectively. Carney also reported that 18% of patients experience late eruption. Some patients also have enamel disorders with multiple caries and crumbly teeth. However, none of these other features were observed in the current patient.

The patient did show a skeletal Class III relationship with a low mandibular plane angle. Because the maxilla was normal in size and position and the mandible was normal in size, upward rotation of mandible resulted in the Class III pattern. This skeletal pattern is at least partly due to the decreased vertical occlusal dimension associated with a posterior anodontia. When edentulous spaces are present in the premolar region, posterior teeth are likely to migrate mesially. The shifting of these teeth results in loss of vertical dimension.<sup>9</sup> In addition, vertical eruption and subsequent appositional alveolar bone growth might be disturbed because occlusal forces have to be withstood by fewer teeth than usual.

The patient had multiple missing teeth in the upper and lower arches, and the residual teeth had migrated to neighboring and opposing edentulous spaces. This made prosthetic procedures difficult because proper spaces for placement of the pontics of restoration were not available.

Orthodontic repositioning of malpositioned teeth often provides a better basis for subsequent prosthetic procedures. In this case, orthodontic treatment was limited and compromised because of fewer anchorage teeth, but it made the untreated case manageable. Indeed, orthodontic treatment could avoid excessive tooth preparation and devitalization.

#### Author address

Takashi Yamashiro  
Department of Orthodontics  
Okayama University Dental School  
Shikata-Cho 2-5-1  
Okayama City, Okayama 700-8525  
Japan

Tel.: +81-86-235-6692

Fax: +81-86-235-6694

E-mail: yamat@dent.okayama-u.ac.jp

*Takashi Yamashiro, assistant professor, Department of Orthodontics, Okayama University Dental School, Okayama, Japan.*

*Koichi Nakagawa, associate professor, Department of Orthodontics, Faculty of Dentistry, Osaka University, Osaka, Japan.*

*Kenji Takada, professor and chair, Department of Orthodontics, Faculty of Dentistry, Osaka University, Osaka, Japan.*

**References**

1. Garney RG. Incontinentia pigmenti: A report of five cases and review of the literature. *Arch Dermatol* 1976; 112: 535-42.
2. Garney RG. Incontinentia pigmenti. A world statistical analysis. *Arch Dermatol* 1976; 112: 535-42.
3. Wiklund DA, Weston WL. Incontinentia pigmenti: A four-generation study. *Arch Dermatol* 1980; 116: 701-3.
4. Baddour HM, Steed DL, Tilson HB. Incontinentia pigmenti: Report of case. *J Oral Surg* 1981; 39: 57-9.
5. Bjellerup M. Incontinentia pigmenti with dental anomalies: A three-generation study. *Acta Derm Venereol* 1982; 62: 262-4.
6. Milam PE, Griffin TJ, Shapiro RD. A dentofacial deformity associated with incontinentia pigmenti: Report of a case. *Oral Surg Oral Med Oral Pathol* 1990; 70: 420-4.
7. Russell DL, Finn SB. Incontinentia pigmenti (Bloch-Sulzberger syndrome): A case report with emphasis on dental manifestations. *J Dent Child* 1967; 34: 494-500.
8. Vogt J, Matheson J. Incontinentia pigmenti (Bloch-Sulzberger syndrome): A case report. *Oral Surg Oral Med Oral Pathol* 1991; 71: 454-6.
9. Marks MH, Corn H. *Atlas of adult orthodontics: Functional and esthetic enhancement*. pp. 466-490. Philadelphia, London: Lea&Febiger, 1989.