

The effect of dexamethasone in the pathogenesis of ligature-induced periodontal disease in Wistar rats

Efeito da dexametasona na patogênese da doença periodontal induzida por ligadura em ratos Wistar

Juliano Cavagni*
Ana Cristina Soletti**
Eduardo José Gaio***
Cassiano Kuchenbecker Rösing****

ABSTRACT: The aim of this study was to evaluate, in rats, the role of the systemic use of dexamethasone in the pathogenesis of induced alveolar bone loss. In 26 female Wistar rats, ligatures were placed around the second upper molars, and the contralateral ones served as intra-group controls. Two groups were formed. The test group received 0.5 mg/kg of dexamethasone subcutaneously every third day during thirty days. The control group received the same amount of saline solution. After thirty days, the animals were sacrificed and their maxillae were removed. Sodium hypochlorite was used to prepare the specimens, and the cementum-enamel junction was stained with 1% methylene blue. Morphometric analysis of the alveolar bone loss was performed with standardized digital photographs, and the distance between the cementum-enamel junction and the alveolar bone crest was measured with the software ImageTool 3.0. Intra-examiner calibration revealed a Pearson correlation coefficient of 0.99. Statistical analysis was performed by paired or independent sample *t* tests, as appropriate ($\alpha = 0.05$). Dexamethasone increased the mean alveolar bone loss in ligature-induced periodontitis in relation to the control group (0.77 and 0.61 buccally, and 0.65 and 0.56 palatally, respectively). No significant differences were observed intergroups in the teeth without ligatures. In the animal model used here, the use of dexamethasone increased the progression of ligature-induced alveolar bone loss.

DESCRIPTORS: Alveolar bone loss; Dexamethasone; Periodontal diseases; Rats.

RESUMO: O objetivo deste estudo foi avaliar o papel do uso sistêmico da dexametasona na patogênese da perda óssea alveolar induzida em ratos. Em 26 ratos Wistar fêmeas, foram colocadas ligaduras em torno do seu segundo molar superior, servindo o lado contralateral como controle intragrupo. Foram formados dois grupos. O grupo teste recebeu 0,5 mg/kg de dexametasona subcutaneamente a cada três dias durante um período de 30 dias. O grupo controle recebeu a mesma quantidade de solução salina. Após 30 dias, os animais foram sacrificados e suas maxilas removidas. Para o preparo das peças foi usado hipoclorito de sódio e, para corar a junção cimento-esmalte, foi usado azul de metileno. A análise morfométrica da perda óssea alveolar foi realizada por fotografias digitais padronizadas, e a distância entre a junção cimento-esmalte e a crista óssea alveolar foi medida pelo programa ImageTool 3.0. A calibração intra-examinador revelou um coeficiente de Pearson de 0,99. A análise estatística foi realizada pelo teste *t* pareado ou teste *t* para amostras independentes, conforme apropriado ($\alpha = 0,05$). A dexametasona aumentou a média de perda óssea alveolar na periodontite induzida por ligadura em relação ao grupo controle (0,77 e 0,61 por vestibular e 0,65 e 0,56 por palatino, respectivamente). Não foram observadas diferenças significativas intergrupos nos dentes sem ligadura. No modelo animal usado neste estudo, a dexametasona aumentou a progressão de perda óssea alveolar induzida por ligadura.

DESCRIPTORES: Perda óssea alveolar; Dexametasona; Doenças periodontais; Ratos.

INTRODUCTION

The pathogenesis of destructive periodontal disease is currently understood as the response given by an individual to the bacterial challenge of subgingival dental biofilm. This response is modulated by different mechanisms including genetic,

environmental and acquired factors. Thus, the way the host responds to the bacterial challenge is going to be reflected or not in periodontal breakdown¹⁴.

The role of anti-inflammatory drugs in the pathogenesis of destructive periodontal disease

* DDS; **MS – School of Dentistry, Lutheran University of Brazil.

*** DDS; ****PhD – School of Dentistry, Federal University of Rio Grande do Sul.

has been studied, especially the use of non-steroidal anti-inflammatories. These drugs are linked to the inhibition of the metalloproteinase matrix and the reduction in prostaglandin expression, by acting in the cyclooxygenase pathway. The results of these studies have demonstrated either less periodontal breakdown^{4,10,15} or absence of significant differences^{2,16}.

Additionally, studies with patients that used non-steroidal anti-inflammatories^{5,20,23} revealed, at least in some study periods, differences in periodontal tissue destruction. However, studies that have analysed the role of steroidal anti-inflammatory drugs are scarce and were performed under research paradigms different from those of today. Additionally, studies involving dexamethasone and periodontitis are lacking^{1,8,12}. Dexamethasone inhibits the production of some inflammatory cytokines activated by LPS, diminishing macrophage activation. This is a clear demonstration that it is capable of modulating inflammation¹³.

The aim of the present study was to evaluate the role of the systemic use of dexamethasone in the pathogenesis of induced alveolar bone loss in Wistar rats.

MATERIALS AND METHODS

Animals

Twenty-six female Wistar rats, 2 months old, were used in the present study. A 12 hour light and dark cycle was applied. Four to five rats were housed in each cage at a temperature of around 20°C. Standard rat chew pellets (Nuvilab®, Curitiba, Brazil) and water *ad libitum* were available. Sample size calculation was performed with the standard deviations of the data of this study, considering a mean difference of 0.3 mm as significant, admitting an alpha error of .05 and a beta of .1, and a sample of 11 animals was considered necessary per group.

Experimental groups

The animals were randomly assigned by the flip of a coin into two groups as follows:

- Test Group - was submitted to ligature-induced periodontal disease and received dexamethasone (Merck Sharp & Dohme®, São Paulo, Brazil), 0.5 mg/kg of body weight subcutaneously every third day during 30 days (n = 13).
- Control Group - was submitted to ligature-induced periodontal disease and received the same

amount of saline solution (Texon®, Viamão, Brazil) subcutaneously every third day for the same time period as the Test Group (n = 13).

Experimental procedures

Cotton ligatures (Ethicon, Johnson & Johnson®, São Paulo, Brazil) were placed around the second maxillary molars on the right side at the first day. Sacrifice took place 30 days after the placement of the ligatures.

Body weight was measured weekly in order to verify systemic conditions of the animals. The Ethical Committee of the Lutheran University of Brazil approved the present study.

Laboratory procedures

Following sacrifice, the left and right segments of the maxillae were dissected out and fixed in 10% neutral buffered formalin (Sigma-Aldrich®, Saint Louis, USA) for 24 hours. The specimens were then immersed in sodium hypochlorite (Q'Boa®, Osasco, Brazil) with 9% of active chlorine during 5 hours. Then the specimens were defleshed. 1% Methylene blue (Sigma-Aldrich®, Saint Louis, USA) was used during 1 minute to stain the cementum-enamel junction, followed by rinsing with water.

Measurements

Standardized pictures were taken of each specimen with a Nikon D100 Camera (Nikon®, Ayuthaya, Thailand) and Medical Lenses (Nikon®, Ayuthaya, Thailand). A minimal focal distance was used and the specimen was placed with the occlusal surfaces parallel to the floor. A tripod was used to minimize errors. Pictures were taken from the buccal and palatal aspects of the specimens. Pictures were measured with the aid of the ImageTool 3.0 computer software (UTHSCSA ImageTool 3.0®, San Antonio, USA). The bone level at the mesial aspect of the mesial root of the second maxillary molar, buccally and palatally, on both sides (with or without ligatures), was measured. Bone level was measured between the enamel-cementum junction and the alveolar bone crest in the picture. This measure was considered in the present study as the alveolar bone loss. This method was performed according to Gaio *et al.*⁶ (2004).

Reproducibility

Before the analysis was performed, the examiner was trained by double measurements of

20 specimens, with a one-week interval. Paired *t* test statistics was run and no differences were observed in the mean values for comparison (*p* value = 0.51). Additionally, Pearson's correlation coefficient was obtained between the 2 measurements and revealed a very high correlation (0.99, *p* = 0.000).

Statistical analysis

A normal distribution of the data was verified. Mean values of animal weight were obtained at baseline, 7, 14, 21 and 30 days of the experiment. Independent sample *t* test was used to compare weight between tests and controls. Mean values of bone level were obtained for buccal and palatal aspects and compared by independent sample *t* test between both groups and by paired sample *t* test between the sides with and without ligatures within the same animals. The level of significance was set at 5%.

RESULTS

The results of the present study concern 2 approaches: first, the systemic effect of dexamethasone, demonstrated by the analysis of body weight of the animals; and second, the main outcome – alveolar bone loss – in teeth with or without ligature for groups test and control.

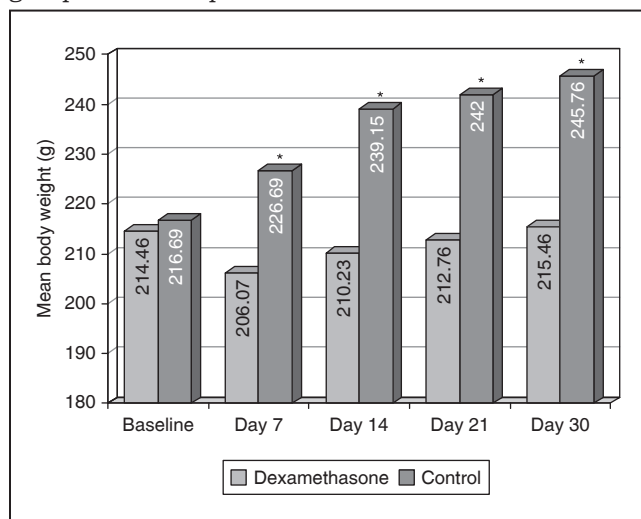
Graph 1 shows the mean body weight values for the experimental groups. The absence of statistically significant differences between tests and controls observed at baseline was not maintained throughout the study. At day 7, animals from the control group gained weight, whereas the ones from the test group (dexamethasone) lost weight, revealing statistically significant differences. At days 14, 21 and 30, test animals showed a tendency to gaining weight, although the body mass of the controls revealed statistically significant higher values (*p* < .05).

Table 1 demonstrates the main outcome of the present study (alveolar bone level 30 days after baseline) for both test and control groups during the study period. It can be observed that for the analysis performed buccally in teeth with ligature, groups test and control showed a mean value of 0.77 (± 0.12) and 0.61 (± 0.12) millimeters. This difference was statistically significant (*p* = 0.029). The same result was seen palatally with 0.65 (± 0.11) and 0.56 (± 0.06) for tests and controls, respectively, with a *p* value of 0.024.

Statistically significant differences were not detected between test and control groups neither buccally nor palatally in teeth without ligatures.

An intra-group comparison was performed between teeth with and without ligature and it is demonstrated in Graph 2. Independently from the experimental group, teeth with ligatures always showed statistically significant higher amounts of bone loss both buccally and palatally.

GRAPH 1 - Mean body weight (g) for the experimental groups and time periods.

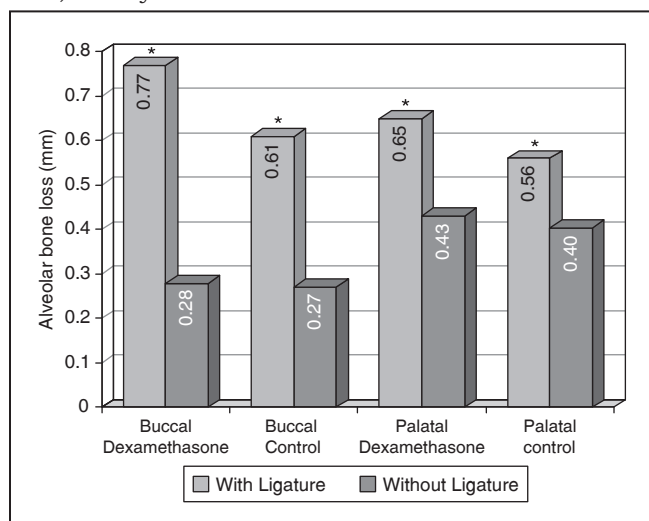


*Statistically significant differences between groups (independent sample *t* test).

TABLE 1 - Mean (± standard deviation) of alveolar bone loss, in millimeters, for test and control groups, in teeth with or without ligature, 30 days after ligature placement.

	Dexamethasone (test)	Control	<i>p</i> value (independent sample <i>t</i> test)
Buccal (with ligature)	0.77 ± 0.12	0.61 ± 0.12	0.029
Palatal (with ligature)	0.65 ± 0.11	0.56 ± 0.06	0.024
Buccal (without ligature)	0.28 ± 0.05	0.27 ± 0.04	0.55
Palatal (without ligature)	0.43 ± 0.05	0.40 ± 0.08	0.37

GRAPH 2 - Alveolar bone loss for test and control groups, according to location and the presence of ligature, 30 days after baseline.



*Statistically significant differences between sides with and without ligature (paired sample *t* test).

DISCUSSION

The present study evaluated the effect of a steroidal anti-inflammatory (dexamethasone) on the pathogenesis of ligature-induced periodontal breakdown in Wistar rats. The results demonstrated a higher bone loss in sides with ligature and under the intake of dexamethasone.

In the study of the pathogenesis of periodontal diseases, animal models are useful because human studies are difficult to be performed for ethical reasons. Ligature-induced periodontal disease is considered to be one of the possible ways of studying this subject^{7,18,19}.

Most of the studies have used histometric measurements for this purpose. However, the limitation of the number of slides evaluated as well as the possibility of not representing the complete pattern of alveolar bone loss should be kept in mind^{3,11,21}. For this reason, in the present study, dry bone was used to demonstrate bone level. Gaio *et al.*⁶ (2004) have validated this dry bone quantification of alveolar bone loss in relation to histometric measurements.

Additionally, blinding of the examiner, randomization, utilization of a sufficient number of animals and use of comparative groups were principles followed by this study in order to better generate evidence¹⁷. Our sample size calculation, with a power of .90 indicated a minimum number of 11

rats in each group. Thus, we consider the sample of our study adequate in terms of quantity.

The first observed outcome in this study was body weight of the animals, which is a known way of evaluating systemic health⁷. At baseline, no statistically significant differences were observed between test and control groups, which means they were comparable in this aspect at the beginning of the study. However, the use of dexamethasone caused an initial loss in body weight, which was recovered subsequently, but led test animals to always display statistically lower weight. A possible explanation for this fact is that some loss of weight (of approximately 5% of body mass, which is considered low) has been reported in the first week of dexamethasone intake. The elevated dose of dexamethasone used in this study was chosen in order to better verify the potential of interfering in pathogenesis. However, the concentration used was equivalent to that used in human steroid treatments of short duration¹³. It has to be reminded that the use of dexamethasone is widespread. Adaptation of the animals to the medicine was associated with the ceasing of the diarrhea noted in the first days, including gain in weight from day 7 on.

Dexamethasone is suggested to impair wound healing and to diminish bone mineralization²². The first effect could be reflected in more attachment loss, and the second effect could be connected to the observed fact that the maxillae from the test group could be easily fractured, as compared to those of controls.

The main outcome of this study, alveolar bone loss, was different between the studied groups both in the analyses performed buccally and palatally. Hence, no differences were observed in teeth without ligatures (Table 1). Moreover, Graph 2 demonstrates that teeth with ligature, regardless of the group, displayed more alveolar bone loss, which guarantees that the ligature-induced model promoted periodontal breakdown.

Thus, the potential role of steroidal antiinflammatories in enhancing tissue loss can be discussed. The results of our study indicate a different outcome as compared to that observed with the use of non-steroidal antiinflammatories^{5,9,10}.

The greater alveolar bone loss observed in the present study is an important finding, which deserves some interest. The anti-inflammatory effect can minimize clinical signs of inflammation at first by reducing host response. This impaired host response could be responsible for more tis-

sue breakdown. One of the suggested side effects of dexamethasone is enhancing potential of infections²².

Studies with other anti-inflammatory drugs presented diverse results from these, however, the host response modulation is always observed^{2,4,5,15,16}.

Taking this into consideration, the results of the present study may add to the knowledge of the biological plausibility of pathogenesis of periodontal disease, suggesting association between the used medication and increase in alveolar bone loss. This information does not have the inten-

tion of being of direct clinical impact, but to show the potential of dexamethasone, as well as other steroidal antiinflammatory drugs to be a modifier of periodontal breakdown. However, patients and practitioners should be aware of this fact in clinical approaches.

CONCLUSION

It may be concluded that the use of systemic dexamethasone is associated with higher bone loss in ligature-induced periodontal disease in rats.

REFERENCES

1. Applebaum E, Seelig A. Histologic changes in jaws and teeth of rats following nephritis, adrenalectomy, and cortisone treatment. *Oral Surg Oral Med Oral Pathol* 1955;8(8):881-91.
2. Bissada NF, Ng VW. Clinical evaluation of systemic doxycycline and ibuprofen administration as an adjunctive treatment for adult periodontitis. *J Periodontol* 1998;69(7):772-6.
3. Björnsson MJ, Velschow S, Stoltze K, Havemose-Poulsen A, Schou S, Holmstrup P. The influence of diet consistency, drinking water and bedding on periodontal disease in Sprague-Dawley rats. *J Periodontol Res* 2003;38(6):543-50.
4. Ciancio SG. Systemic medications: clinical significance in periodontics. *J Clin Periodontol* 2002;29 Suppl 2:17-21.
5. Feldman RS, Szeto B, Chauncey HH, Goldhaber P. Non-steroidal anti-inflammatory drugs in the reduction of human alveolar bone loss. *J Clin Periodontol* 1983;10(2):131-6.
6. Gaio EJ, Fernandes MI, Oppermann RV, Rados PV, Rösing CK. Analysis morphometric and hystometric bone high in induced periodontitis. *J Dent Res [periódico on line]* 2004. Available from: URL: http://iadr.confex.com/iadr/brazil04/preliminaryprogram/abstract_55977.htm.
7. Galvão MPA, Chapper A, Rösing CK, Ferreira MBC, Souza MAL. Methodological considerations on descriptive studies of induced periodontal disease in rats. *Pesqui Odontol Bras* 2003;7:56-62.
8. Glickman I, Shklar G. The effect of systemic disturbances on the pulp of experimental animals. *Oral Surg Oral Med Oral Pathol* 1954;7(5):550-8.
9. Heasman PA, Benn DK, Kelly PJ, Seymour RA, Aitken D. The use of topical flurbiprofen as an adjunct to non-surgical management of periodontal disease. *J Clin Periodontol* 1993;20(6):457-64.
10. Holzhausen M, Rossa Junior C, Marcantonio Junior E, Nassar PO, Spolidorio DM, Spolidorio LC. Effect of selective cyclooxygenase-2 inhibition on the development of ligature-induced periodontitis in rats. *J Periodontol* 2002;73(9):1030-6.
11. Klausen B, Evans RT, Sfantescu C. Two complementary methods of assessing periodontal bone level in rats. *Scand J Dent Res* 1989;97(6):494-9.
12. Labelle RE, Schaffer EM. The effects of cortisone and induced local factors on the periodontium of the albino rat. *J Periodontol* 1966;37(6):483-90.
13. Metzger Z, Klein H, Klein A, Tagger M. Periapical lesion development in rats inhibited by dexamethasone. *J Endod* 2002;28(9):643-5.
14. Page RC, Kornman KS. The pathogenesis of human periodontitis: an introduction. *Periodontol* 2000 1997;14:9-11.
15. Paquette DW, Willians RC. Modulation of host inflammatory mediators as a treatment strategy for periodontal disease. *Periodontol* 2000 2000;24:239-52.
16. Pauletto N, Silver JG, Larjava H. Nonsteroidal anti-inflammatory agents: potential modifiers of periodontal disease progression. *J Can Dent Assoc* 1997;63(11):824-9,832.
17. Sackett D. Evidence-based medicine: how to practice and teach EBM. New York: Churchill Livingstone; 2000.
18. Sallay K, Sanavi F, Ring I, Pham P, Behling UH, Nowotny A. Alveolar bone destruction in the immunosuppressed rat. *J Periodontal Res* 1982;17(3):263-74.
19. Susin C, Rösing CK. O rato como modelo para o estudo das repercussões do estresse nas doenças periodontais. *Revista Periodontia* 2002;13(6):7-17.
20. Taiyeb Ali TB, Waite IM. The effect of systemic ibuprofen on gingival inflammation in humans. *J Clin Periodontol* 1993;20(10):723-8.
21. Tatakis DN, Guglielmoni P. HLA-B27 transgenic rats are susceptible to accelerated alveolar bone loss. *J Periodontol* 2000;71(9):1395-400.
22. Wannmacher L, Ferreira MBC. *Farmacologia clinica para dentistas*. 2ª ed. Rio de Janeiro: Guanabara Koogan; 1999.
23. Williams RC, Jeffcoat MK, Howell TH, Rolla A, Stubbs D, Teoh KW, *et al*. Altering the progression of human alveolar bone loss with the non-steroidal anti-inflammatory drug flurbiprofen. *J Periodontol* 1989;60(9):485-90.

Received for publication on Feb 25, 2005
Sent for alterations on Jun 13, 2005
Accepted for publication on Sep 13, 2005