

## Multiple Intussusceptions as Primary Manifestation of Peutz-Jeghers Syndrome: Report of a Case

Mohammad-Reza Motie\*<sup>1</sup>, MD; Ahmad Amouzesi<sup>1</sup>; Ali Najib Jalali<sup>1</sup>, MD

1. Department of Surgery, Mashhad University of Medical Sciences, Mashhad, IR Iran

Received: Aug 27, 2008; Final Revision: Feb 08, 2009; Accepted: Feb 24, 2009

### Abstract

**Background:** Peutz-Jeghers syndrome is a rare hereditary disorder characterized by hamartomatous polyps in the gastrointestinal tract and typical pigment lesions. It is a rare cause of multiple intussusceptions. Previous studies on Peutz-Jeghers syndrome reported only one case of multiple intussusceptions. We describe a case of appendiceal and multiple small intestine intussusceptions presenting as peritonitis in a patient with Peutz-Jeghers syndrome.

**Case Presentation:** A 17-year-old girl presented with an 8 day history of a sharp, non-radiating periumbilical pain. She underwent surgery with the diagnosis of peritonitis. Intraoperative findings included appendiceal and multiple small intestine intussusceptions. The final pathological evaluation of the specimen confirmed the diagnosis of Peutz-Jeghers syndrome

**Conclusion:** Multiple intussusceptions may occur as the primary manifestation of Peutz-Jeghers syndrome. Because of its complications, in view of the presence of multiple polyps, early intervention is strongly recommended.

*Iranian Journal of Pediatrics, Volume 19 (Number 3), September 2009, Pages: 313-316*

**Key Words:** Peutz-Jeghers syndrome; Multiple intussusceptions; Appendiceal intussusceptions; hamartomatous polyps

### Introduction

Peutz-Jeghers syndrome (PJS) is an unusual hamartomatous polyposis of the gastrointestinal (GI) tract<sup>[1]</sup>. Oral pigmentation around lips may occur as diffuse lesions and macules may be found on the buccal mucosa.

It is a rare syndrome inherited in an autosomal dominant pattern and it is together. It is a rare syndrome inherited in an autosomal dominant pattern. Recurrent episodes of polyp induced bowel intussusception are a common presentation in

\* Corresponding Author;

Address: Department of General Surgery, Imam-Reza University Hospital, Mashhad, IR Iran

E-mail: motiem@mums.ac.ir

this syndrome which requires frequent laparotomies [1].

Simultaneous occurrence of appendiceal and multiple small intestine intussusceptions have been rarely reported in patients with Peutz-Jeghers syndrome. This is a case of Peutz-Jeghers syndrome presenting as peritonitis with appendiceal and multiple bowel intussusceptions.

### **Case Presentation**

A 17-year-old girl presented to the Emergency Department (ED) complaining of a 4 year intermittent abdominal pain. She presented with 8 day history of a sharp, radiating periumbilical pain. This had become progressively worse over the past 8 hours. It was described as sharp, non-radiating pain in periumbilical area not affected by position or activity. Episodes of pain typically lasted about 2 hours, and were associated with nausea, and coffee ground vomiting. The patient had normal bowel movements produced a soft and maroon colored stool of normal caliber. She suffered from fever, no bloody diarrhea, and weight loss. Also, the patient had primary amenorrhea.

Past medical history was negative for peptic ulcer disease, gall bladder disease, pancreatitis, or genitourinary problems. Family history indicated that her mother has had the same symptoms having undergone surgery for intussusception, uterine cyst and hemorrhoids. She was a known case of Peutz-Jeghers syndrome.

On physical examination, she was awake and alert laying in the supine position with knees drawing up toward the chest in discomfort. The patient showed pigmented lesions on lips and buccal mucosa. Her oral temperature was 37.2°C, heart rate 100 beats/min, respiratory rate 18 breaths/min, and blood pressure 120/90 torr. She was dehydrated, pale and anicteric. Pulmonary and cardiac examinations were normal. Abdominal examination revealed moderately distended

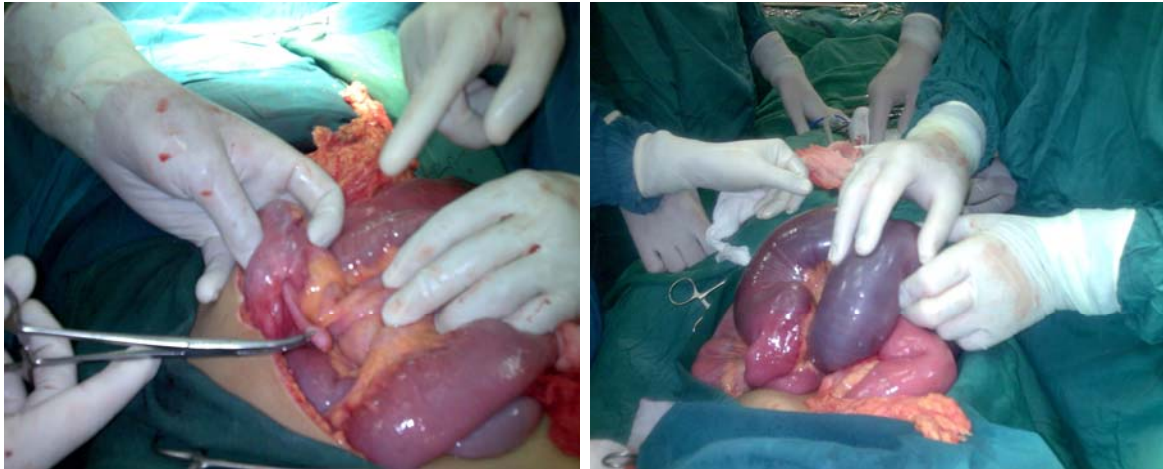
abdomen, decreased bowel sounds, and diffuse tenderness with rebound tenderness, most prominent in the upper abdomen. Anorectal examination revealed red, bloody mucus in the rectal vault. The remainder of the physical examination was unremarkable.

Laboratory studies revealed: serum sodium concentration, 138 mEq/L; potassium, 4.5 mEq/L; chloride 105 mEq/L, bicarbonate 17.9 mEq/L, blood urea nitrogen 9 mg/dL, serum creatinine, 0.8 mg/dL; and glucose of 90 mg/dL. The complete blood cell count showed white blood cells 29.3 K/\_L with neutrophilia (90%), hemoglobin 6.3 gm/dL, hematocrit 21.3% and platelet count 150 K/\_L. The urine analysis showed normal results. The patient was taken to the operating room with the diagnosis of peritonitis. Intraoperative findings showed multiple intussusceptions of the small intestine, appendiceal intussusception, as well as large multiple polyps throughout the small and large intestine (Fig 1). Multiple intussusceptions were reduced manually, and a right hemicolectomy was performed for the appendiceal intussusception. Then large multiple polyps as the leading point of the intussusception went through segmental resection. The pathological evaluation of the specimen confirmed the diagnosis of Peutz-Jeghers syndrome.

### **Discussion**

Peutz-Jeghers syndrome is a rare, autosomal dominant multi-organ cancer syndrome<sup>[2,3]</sup>. It is also one of the most common hamartomatous syndromes<sup>[4]</sup>. Clinical manifestations may include abdominal pain, anemia secondary to bleeding, and intestinal obstruction due to intussusceptions<sup>[5]</sup>. Rarely, appendiceal and multiple bowel intussusceptions were seen in the patients.

Over a thirty year period, Ladd and Gross reported 484 cases of intussusceptions. Among them, only 1% showed multiple



**Fig 1:** Appendiceal intussusceptions (left), Intestinal intussusceptions (right)

intussusceptions [6]. This condition has been reported in patients following aneurysm repair<sup>[7,8]</sup>, secondary melanomata<sup>[9]</sup>, submucous lipoma<sup>[10]</sup>, metastatic lung cancer,<sup>[11]</sup> and rarely is associated with Peutz Jeghers syndrome. Multiple intussusceptions in the latter occurred in small intestine [12-14], or simultaneously in small and large intestines [15,16]. To our knowledge, simultaneous occurrence of appendiceal and small intestinal intussusceptions in patients with Peutz-Jeghers syndrome has not been reported.

Having an incidence rate of 0.01% which has been reported in the literature, appendiceal intussusception is uncommon and typically found at the time of the operation. Usually associated with males in the first decade, patients tend to present with symptoms of vague colicky lower abdominal pain with or without symptoms of small bowel obstruction<sup>[17]</sup>.

According to Langsam et al classification, there are four anatomic types of appendiceal intussusception as the followings: type 1 begins at the tip of the appendix. The tip of the appendix is the intussusceptum, and its more proximal portion is the intussusciens. Type 2 begins at the base of the appendix. The base is the intussusceptum, and the cecum is the intussusciens. For type 3, the proximal portion of the appendix forms the

intussusceptum and is received into the distal portion. Type 4 is a complete inversion of the appendix, with accompanying ileocecal intussusception. Either type 1 or type 2 can result in complete inversion of the appendix into the cecum, that is, the inside-out appendix. The current case represents type 2 intussusception<sup>[18]</sup>.

### **Conclusion**

Simultaneous occurrence of multiple small intestine and appendiceal intussusceptions has not been reported up to now. Multiple intussusceptions may occur as the primary manifestation of Peutz-Jeghers syndrome. Because of its complications, in view of the presence of multiple polyps, early intervention is strongly recommended.

### **Acknowledgment**

The authors wish to appreciate Ms. Massoumeh Hassanpour for editing the manuscript.

## References

1. Homan M, Dolenc Strazar Z, Orel R. Peutz-Jeghers syndrome: A case report. *Acta Dermatovenerol Alp Panonica Adriat* 2005;14(1):26-9.
2. Peutz JL. On a very remarkable case of familial polyposis of the mucous membrane of the intestinal tract and nasopharynx accompanied by peculiar pigmentation of the skin and mucous membrane. *Ned Tijdschr Geneeskd*. 1921; 10: 134-46.
3. Jeghers H, McKusick VA, Katz KH. Generalized intestinal polyposis and melanin spots of the oral mucosa, lips and digits. *N Engl J Med*. 1949;241(26):1031-6.
4. Kaiser AM, Nunoo-Mensah JW, Beart RW Jr. Tumors of the colon. In: Zinner MJ, Ashley SW (eds). *Maingot's Abdominal Operations*. 11<sup>th</sup> ed. New York: McGraw-Hill. 2007; P:633.
5. McGarrity TJ, Amos C. Peutz-Jeghers Syndrome: Clinicopathology and molecular alterations. *Cell Mol Life Sci*. 2006; 63(18):2135-44.
6. Ladd WE, Gross RE. *Abdominal Surgery of Infancy and Childhood*. Philadelphia: Saunders. 1941; P:188.
7. Jaretzki A. Multiple intussusceptions after aneurysm repair. *Am Coll Surg*. 2006; 203(3):407-8.
8. Sowemimo OA. Multiple intussusceptions after Aneurysm Repair. *Am Coll Surg*. 2006;202(5):844-5.
9. Kander HS. Multiple intussusceptions caused by secondary melanomata. *Lancet* 1938;232(5994):139.
10. Costanzo A, Patrizi G, Cancrini G, et al. Double ileo-ileal and ileo-cecocolic intussusception due to submucous lipoma: case report. *J Chir*. 2007; 28(4):135-8.
11. Huang YJ, Wu MH, Lin MT. Multiple small-bowel intussusceptions caused by metastatic lung cancers. *Surgery*. 2008; 143(1):148-9.
12. Marschall J, Hayes P: Intussusception in man with Peutz-Jeghers syndrome. *CMAJ*. 2003;163(3):315-16.
13. Guerriero O, Tufano G, Pennetti L, et al. Small intestinal polyposis in Peutz-Jeghers syndrome: combined treatment with surgery and intra-operative endoscopy. *Chir Ital*. 2003;55(2):271-4.
14. Slamā KD, Teitelbaum DH. Multiple sequential intussusceptions causing bowel obstruction in a preterm neonate. *J Pediatr Surg*. 2007;42(7):1279-81.
15. Choi SJ, Chung SY, Kim SK, et al. A case of Peutz-Jeghers syndrome associated with jejunojejunal and colocolic intussusception. *Chonnam Med J*. 1999;35(3): 407-12.
16. Sohn YH, Joo YE, Yoon KW, et al. A case of Peutz-Jeghers syndrome with multiple intussusception and rectal adenocarcinoma. *Korean J Gastrointest Endosc*. 2001;22(4):220-4.
17. Ijaz S, Lidder S, Mohamid W, et al. Intussusception of the appendix secondary to endometriosis: a case report. *J Med Case Reports*. 2008;2:12.
18. Yoshikawa A, Kuramoto S, Mimura T, et al. Peutz-Jeghers syndrome manifesting complete intussusception of the appendix and associated with a focal cancer of the duodenum and a cystadenocarcinoma of the pancreas: report of a case. *Dis Colon Rectum*. 1998;41(4):517-2.