

Giant Cavernous Hemangioma on Tc-99m RBC Scan

Armaghan Fard-Esfahani (MD), Maryam Chavoshi (MD),
Mohammad Eftekhari (MD), Babak Fallahi (MD),
Davood Beiki (PhD), Mohsen Saghari (MD)

Research Institute for Nuclear Medicine, Tehran University of Medical Sciences, Tehran, Iran

(Received 22 November 2008, Revised 15 December 2008, Accepted 23 December 2008)

ABSTRACT

A 36-year-old woman with right upper quadrant abdominal pain since three months previously and no other significant medical history was referred for evaluation of an abdominal mass. Upon clinical examination, a large palpable mass in the mid-upper abdominal area was noted. Abdominal ultrasound and spiral CT-scan showed a large hepatic mass in the left liver lobe. The patient was referred for Tc-99m labeled RBC scintigraphy to assess the possibility of presence of liver hemangioma. The radionuclide imaging confirmed the diagnosis of hemangioma which in this case, the huge size of the lesion was of interest.

Key Words: Cavernous hemangioma, Radionuclide imaging, ^{99m}Tc -RBC

[Iran J Nucl Med 2009; 17\(1\): 57-60](#)

Corresponding author: Dr Maryam Chavoshi, Research Institute for Nuclear Medicine, Shariati Hospital, Tehran University of Medical Sciences, Tehran, Iran. E-mail: mchavoshi@razi.tums.ac.ir

INTRODUCTION

Among hepatic malignant tumors, metastatic lesions are the most common. Hepatocellular carcinoma is the most common primary neoplasm of the liver. As surgical intervention is not usually considered for benign liver tumors, radiological distinction between malignant and benign lesions is of utmost importance. Several imaging modalities have been used to detect benign tumors, which in many cases, resemble malignant lesions.

Ultrasound, CT-scan and MRI are in wide use to evaluate liver masses (1). Hemangioma is the most common benign tumor of the liver (2-5), being the second prevalent liver tumor, only following metastatic lesions. The reported incidence rate is 0.4-7.3% (4). Female/male ratio is 2:1 to 5:1. Most often, hemangiomas are asymptomatic, with a low risk of complication (5).

Classical pattern of hemangioma on US is a homogenous densely echogenic mass with well-defined margins. Although this pattern is frequently seen, it is not a diagnostic feature (2).

On CT-scan, hemangioma is a hypo attenuated lesion in non-contrast images, which shows gradual enhancement from periphery in the arterial phase, after contrast injection (5).

Tc-99m labeled Red Blood Cell (^{99m}Tc -RBC) scintigraphy is an accurate method for the diagnosis of hemangioma with a high specificity, sometimes referred to as the most specific technique (4). The sensitivity significantly improves by using SPECT (2-5). SPECT is more accurate than planar mode, particularly in the small, posterior or multiple hemangiomas (6). The classic scintigraphic pattern of hemangioma on

^{99m}Tc -RBC study is called perfusion- blood pool mismatch. The lesion shows decreased uptake in the early phase, but becomes hot on delayed images (1, 5).

CASE REPORT

A 36-year-old woman was referred for ^{99m}Tc -RBC scintigraphy for evaluation of her large hepatic mass. She has been suffering from right upper quadrant abdominal pain since three months before. No significant past medical history was noted and the patient had no other symptoms. On clinical examination, a palpable mass in the mid and upper abdominal area was noted.

Abdominal CT-scan images revealed a large hypo dense mass sized 19*15*11cm in the left liver lobe, extending to the right and lower abdominal regions (Figure 1).

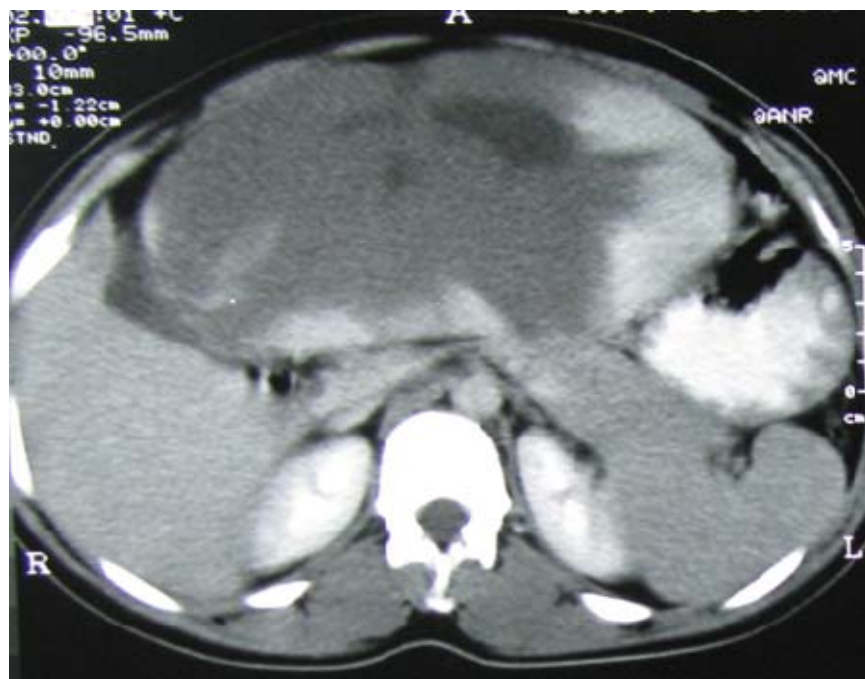

Figure 1. Large hepatic mass in the transverse images of abdominal CT-scan. Note photopenic areas inside the lesion possibly related to scarring.

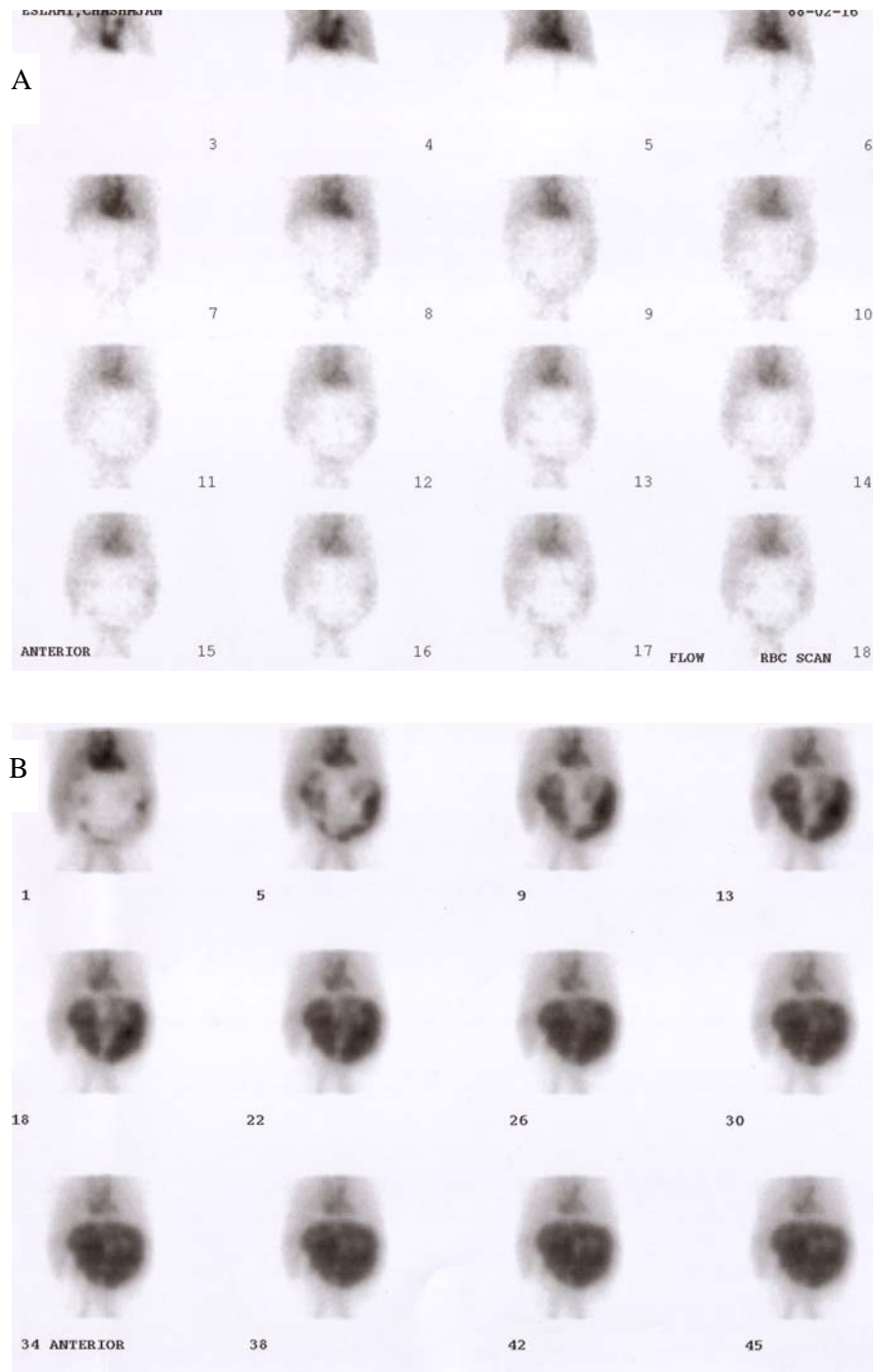


Figure 2. Immediate angiographic (A) and dynamic (B) images of the anterior abdomen. The large photopenic area shows gradual filling subsequently.

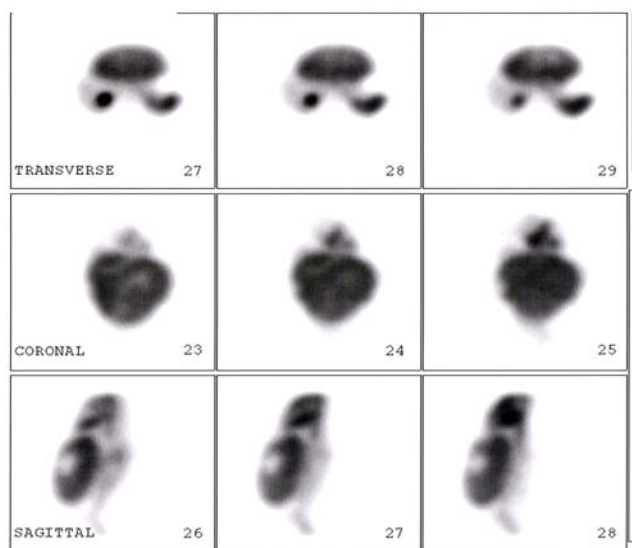


Figure 3. SPECT images of the large hepatic mass in transverse, coronal and sagittal views.

^{99m}Tc -RBC scintigraphy was performed after injection of in vitro labeled RBCs with 20 mCi Tc-99m pertechnetate in planar and SPECT mode (Figures 2 and 3). The immediate angiographic planar images during first one minute after injection revealed a large area of decreased perfusion in the mid abdomen, with a rim of activity around it. Subsequent dynamic images in 45 minutes showed gradual filling of the lesion from periphery toward center, which at last became a hot large lesion occupying nearly all mid-abdominal region. For better localization of the mass, SPECT images were also acquired.

In correlation to the CT images, the scintigraphy showed an interesting large hot lesion. Compatible with the CT mass, this lesion showed the typical scintigraphic appearance of the liver hemangioma which confirmed the diagnosis.

REFERENCES

1. Savci G. The changing role of radiology in imaging liver tumors: an overview. *Eur J Radiol* 1999; 32(1): 36-51.
2. Birnbaum BA, Weinreb JC, Megibow AJ, Sanger JJ, Lubat E, Kanamuller H et al.

Definitive diagnosis of hepatic hemangiomas: MR imaging versus Tc-99m-labeled red blood cell SPECT. *Radiology* 1990; 176(1): 95-101.

3. Kudo M, Ikekubo K, Yamamoto K, Ibuki Y, Hino M, Tomita S et al. Distinction between hemangioma of the liver and hepatocellular carcinoma: value of labeled RBC-SPECT scanning. *AJR Am J Roentgenol* 1989; 152(5): 977-983.
4. Krause T, Hauenstein K, Studier-Fischer B, Schuemichen C, Moser E. Improved evaluation of technetium-99m-red blood cell SPECT in hemangioma of the liver. *J Nucl Med* 1993; 34(3): 375-380.
5. Vilgrain V, Boulos L, Vullierme MP, Denys A, Terris B, Menu Y. Imaging of atypical hemangiomas of the liver with pathologic correlation. *Radiographics* 2000; 20(2): 379-397.
6. Fard-Esfahani A, Fallahi B, Khatami K, Eftekhari M, Saghari M, Beiki D et al. Agreement of two methods of planar and SPECT scintigraphy with ^{99m}Tc -RBC in detection of liver hemangioma. *Iran J Nucl Med* 2006; 14(26): 8-12.