

long duration and slow evolution, two were post-encephalitic. The average age 44.6 years and length of history 17.6 years were significantly different from the group as a whole.

We developed the idea that at least two factors were operative here, the surgical lesion and other lesions produced by the disease. It is suggested that to produce hemichorea in these patients at least two lesions are necessary, the one accomplished by the disease, the other by the surgeon. Apparent confirmation of this hypothesis was strikingly provided at a later date by the sixth patient. An intelligent woman of 38 years of age and 11 years' history, her Parkinsonism was largely confined to one side and thalamic lesions resulted in an excellent result with return to near-normality. About nine months later, following a fall, chorea appeared in the hand and fingers and over the subsequent eighteen months has got gradually worse and now affects the leg. Further lesions in the lateral thalamic and capsular area have failed to improve or arrest the progress of her condition.

One might put this hypothesis in terms of logic and suggest that there is an inherent driving force which produces such involuntary movement. This is normally inhibited by other inputs, the whole forming an INHIBIT/AND switch. There are least two and probably many more, inputs to the inhibit line and these may form a simple OR switch. No output is possible from the 'ballismus' switch if any of the OR inputs are working.

It is interesting to speculate on the possibilities of treatment inherent in such a system. If the OR system only is present in the subthalamic nucleus then damage to this nucleus will result in hemichorea and the more severe the damage the more severe the chorea. If the INHIBIT/AND system only is in the nucleus then partial destruction might produce hemichorea whilst total destruction would stop it. The same is true if both OR and INHIBIT/AND switches are within the nucleus.

I would suggest that the evidence I have presented to you suggests that part, at least, of the OR system is outside the subthalamic nucleus and probably in the lateral thalamic area. It would seem possible, as has been suggested elsewhere, therefore, that total destruction of the subthalamic nucleus is the rational treatment for such cases. I am not suggesting that this hypothesis represents an exhaustive analysis of the logic of such a system, the variations are numerous and it is undoubtedly a great deal more complex than I have suggested. I would hope, however, that the clinical evidence I have presented adds a little more weight to the suggestion that total destruction of the subthalamic nucleus would be worthwhile in such cases.

TREATMENT OF INTENTIONAL TREMOR

BY

STEREOTAXIC SURGERY

Alimohammadi, A. M.D. ★

Attempts to produce tremor as a consequence of surgical lesions of the basal ganglia, the subthalamic nucleus, or the substantia nigra, have been unsuccessful. Reports concerning the production of pure parkinsonian tremor in animals are not reliable. Lesions involving the cerebellum or its efferent pathways produce an intentional tremor which persist as long as 230 days (Carpenter- Mettler). It is associated with ataxia and other asynergic disturbances. It is actually an established fact, that any lesion along the dentato-rubro-thalamic tract is followed by a contralateral or homolateral ataxia, which can be abolished or at least diminished by lesion within the pallidum.

(Fig. 1). Schematic drawing demonstrating the dentato-rubro-thalamic pathways. A lesion within this tract produce a contralateral intentional tremor.

(Fig. II). Stereotaxic lesion in the brachia conjunctiva of monkey produced an intentional ataxic tremor.

(Fig. III). In the same monkey a subsequent lesion within the pallidum relieved the animal from his tremor.

Considering these physiological facts it should be possible to abolish the intentional tremor by putting a lesion into the pallidum. A number of patients suffering from disseminated sclerosis have such a severe intentional tremor, that they are fully handicapped even in their usual living activities, such as dressing, eating and toileting. There are only five cases described in the literature, four cases are operated by Krayenbuhl and one by Cooper, unfortunately there is no time to give further detail about these cases. But in whole the result are encouraging.

★ Department of Neurosurgery, Pahlavi Hospital, Tehran, Iran.

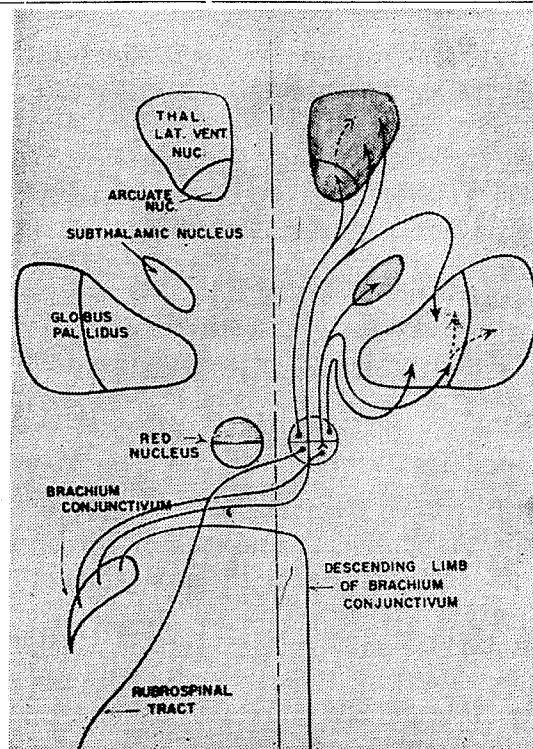
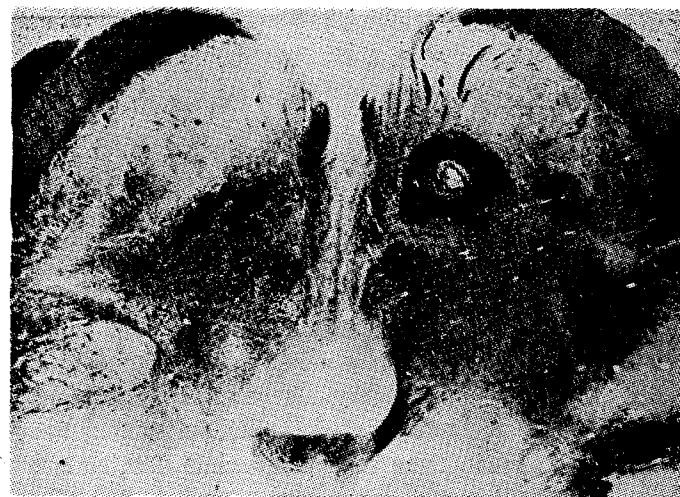

Fig I



From Carpenter (1) Fig II

We have operated upon three cases of severe bilateral intentional tremor. The first patient was a young man of 22 teacher, whose illness began 5 years previous to his admission. The course of the disease with its period of remissions was characteristic of disseminated sclerosis. The examination revealed dysarthric speech with temporal pallor of both papilla disturbance of coordination in all four extremities, pronounced pyramidal sings in both legs and severe ataxia. The most outstanding clinical picture was a bilateral ataxic tremor of both hands. We tried to releave him from his tremor by putting a stereotaxic lesion within the left pallidum. The operation was not successfull.

Three months later, the ventrolateral nucleus of the thalamus was coagulated, we tried delibrately to put the lesion rather laterally in order to touch the internal capsule.

After the operation the patient presented a right-sided hemiparesis but the tremor was improved to about 90%. The hemiparesis subsided gradually and the tremor returned to some degree.

The final result after 7 months was a 50 % improvement regarding the tremor of the right hand and a slight paresis of the right leg.

The second case was a man of 26, with a history of 5 years tremor. When admitted he presented the full picture of a multiplex sclerosis.

He had paraplegia with a severe intentional tremor in both upper extremities. After the stereotaxic thalamotomy on the left side he was drowsy for several weeks, but the tremor of the right arm was greatly diminished. He recovered from his drowsiness and he could use his right hand and was quite satisfied with the result of the operation.

The third case was a woman aged 52. She present a drastic intentional tremor in all the extremitis and in the head. Besides disartritic speech no other abnormal sings were detected. A stereotaxic thalamotomy brought no relief. Howevare when we examined her three months later, we found a decrease of tremor to at least 60 %, no motor weakness could be detected.

(Fig. IV). In order to find monro and aqueduct Myodil is injected in lateral ventricle.

(Fig. V). Coagulation point into ventrolateral nuclous of thalamus in the third patient who have been operated on.

(Fig. VI). A.P. View of the same patient which shows the coaguation point.

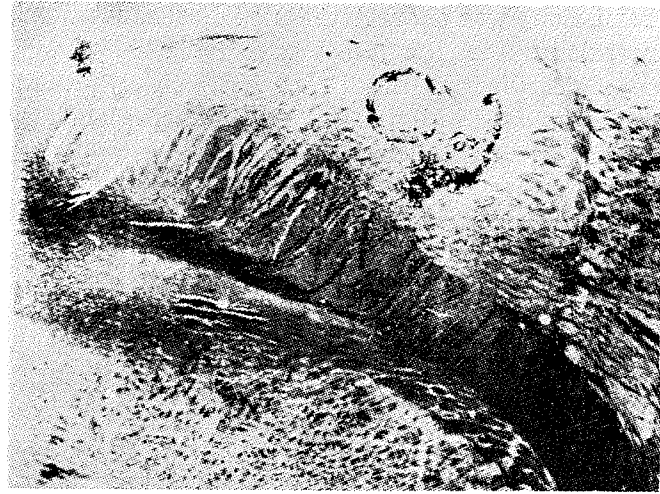


Fig III

From Carpenter (1)




Fig IV

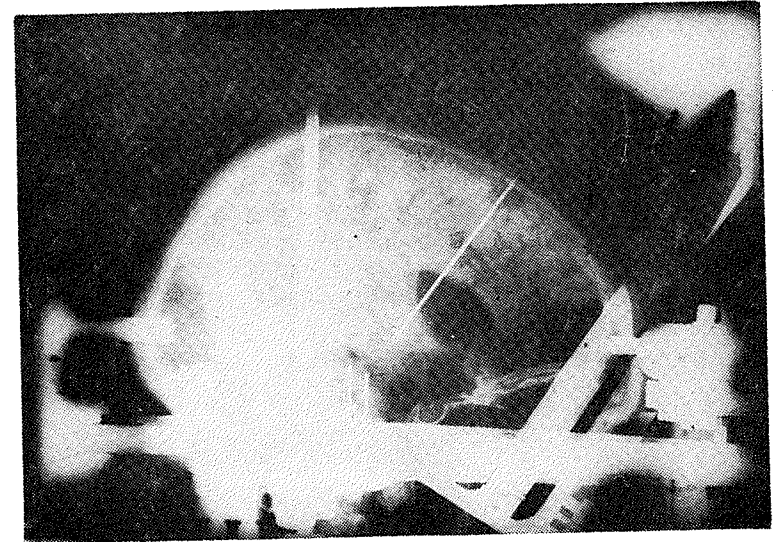


Fig V




Fig VI

References

- 1- Carpenter, M.E. Glindsman, W. and Fabrega, H. (1958); Effects of Secondary Pallidal and Striatal Lesions upon Cerebellar Dyskinesia. *Neurology*, 352-358.
- 2- Cooper, I.S. (1960); Neurosurgical Alleviation of Intention Tremor of Multiple Sclerosis and Cerebellar Disease. *New. Engl. Med.* 263; 441-444.
- 3- Walker, A. E. and Botterell, E.H. (1937); The Syndrome of the Superior Cerebellar Peduncle in the monkey; *Brain* 60: 329-353.
- 4- Krayebuhl, H. and Yasargil, M.G. (1961); Relief of Intention tremor due to Multiple Sclerosis by Stereotaxic Thalamotomy, 1st. International Symposium on Stereocencephalotomy, 368-374.