

Diphenylhydantoin Sodium: Gingival Hyperplasia and Orthodontic Treatment

JOHN J. CUNAT, D.D.S., M.S.

SEBASTIAN G. CIANCIO, D.D.S.

Diphenylhydantoin sodium (DPH), more commonly known as sodium dilantin, has been used since 1938 to control the frequency and severity of epileptic seizures.¹ The relationship of this treatment to the appearance of gingival hyperplasia is well documented and, consequently, will not be reviewed here.² Interested readers may find detailed information and an extensive bibliography on the subject in a comprehensive work by Aas.³

The purpose of this paper is to describe coordinated periodontic and orthodontic therapy in coping with a clinical problem and, additionally, to report the response of the tissues to orthodontic manipulation. In order to underscore the multiple implications of this situation, the material will be presented in the form of a case report.

CASE REPORT

The patient, a 13 year-old negro male, presented to the orthodontic clinic at the State University of New York at Buffalo for treatment. At that time he displayed a crowded, Class I malocclusion which was complicated by a rather typical hyperplastic gingival reaction to DPH (Figure 1). He had begun to experience seizures when he was eleven years old, two years prior to the time he appeared in our clinic. The first symptoms appeared as periods of "dis-orientation" and "shaking." Electroencephalographic evidence confirmed the original diagnosis of *petit mal epilepsy*.

Varying dosages of phenobarbital were used initially in an effort to control the problem. After approximately

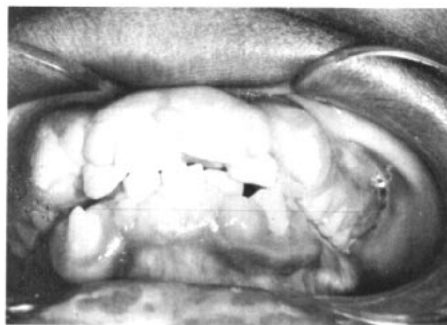


Fig. 1 Appearance of gingival hyperplasia when case presented.

six months the patient continued to have periodic seizures and, therefore, he was started on a regimen of 200 mgm per day of DPH. This was about a year and a half before he sought orthodontic treatment. The dosage of DPH was altered by his physician, as needed, to keep the seizures controlled. This continues to be the plan of treatment. At about the same time mechanical orthodontic therapy began, 250 mgm per day of Mysoline was added to the patient's intake of DPH.

Our orthodontic diagnosis indicated that we would be best able to treat the case by extracting the four first premolars, retracting the canines, and realigning the incisors in a less protrusive labiolingual position. Facial photographs, as well as the lateral cephalometric tracing with selected lines and planes, are shown in Figures 2 and 3.

For several reasons the initiation of this involved orthodontic procedure was thought to be inadvisable with the gingiva in its hyperplastic state. First of all, we felt that mechanical irritation and/or impaired oral hygiene which

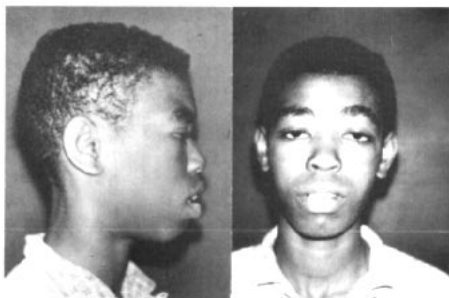


Fig. 2 Facial photographs at start of treatment.

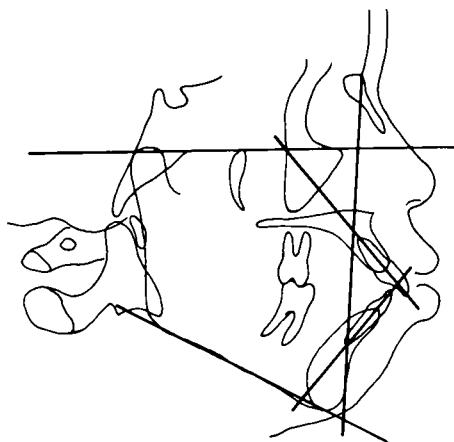


Fig. 3 Cephalometric tracing at start of treatment.

could be a sequela to treatment might foster the progression of the gingival reaction and result in increased periodontal involvement and damage. Secondly, the increased mass and fibrous nature of the gingiva could impede the progress of mechanical retraction and alignment of the canines and incisors. The patient, therefore, was referred to the Department of Periodontology for evaluation and treatment. An external bevel gingivectomy was performed which did not require osseous recontouring. This resulted in the vastly improved clinical picture seen in Figure 4. The patient was given instructions in oral hygiene and provided with an electric tooth brush and a self-powered water spray appliance.

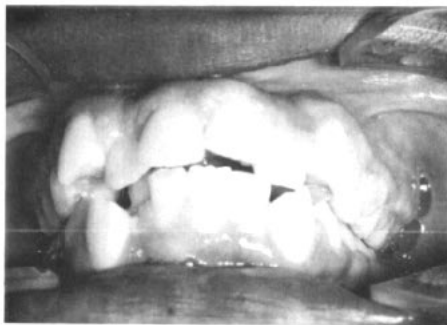

Fig. 4 Intraoral photographs following periodontal treatment.

Following the periodontal treatment, the next step was to evaluate the tendency that the gingiva would display toward the recurrence of hyperplasia. Therefore, the patient was kept under close observation for two months. During this time little gingival change was noted and oral hygiene was excellent. Further, since our diagnosis suggested the removal of tooth material in order to best resolve the orthodontic problem, we wanted to adequately test gingival reactivity to physical forces before we proceeded. Consequently, stainless steel, preformed bands were placed on both upper second premolars to ascertain whether the added stimulation that they would inevitably provide would cause the gingiva to react unfavorably. Two weeks later there had been no overt effect, so .025 brass wire was looped around the brackets on the bands and brought into contact with the gingival tissue immediately superior to the second premolars on either side. We felt that this would be a severe test of the reactive potential that existed in that tissue. One month later very little change was evident, so bands were placed on the maxillary first permanent molars. The brass loops at the premolars were allowed to remain in contact with the gingiva for three more weeks. The hyperplasia did not increase clinically so bands were placed on the mandibular first permanent molars.

During this period of time oral hygiene continued to be excellent.

The case was evaluated once again one and a half months later, which was approximately six months after the completion of gingival surgery. No significant change was seen in the gingiva either around the appliances that had been in position, or more generally throughout the arch. The patient was then referred for the extraction of the four first premolars.

This cautious approach was taken because, up until the time of extraction, all of the appliances could have been removed and a wholly different treatment plan evolved. Now, however, conventional orthodontic therapy was instituted.

Cervical traction against the maxillary molars was utilized to augment upper anchorage, and a lip bumper was used for the same purpose in the mandible. The maxillary canines were retracted with sectional arches until the mandibular canines could also be moved distally without interference. As retraction proceeded, spaces opened in the maxillary and mandibular incisal areas indicating the successful distal movement of the canines. The incisors were the last teeth to be banded and bilateral closing looped arches were used for final space closure.

Finishing arches were then placed for only a short time since the gingiva had once again begun to proliferate. Oral hygiene became very poor during the latter half of treatment, so it was not possible to determine whether the hyperplasia was caused by the irritation of the appliances, the tooth movement itself, as a reaction to the debris that was almost always present, or as a response to the continued intake of DPH and/or Mysoline.

No effort was made to hasten treatment, nor was the patient especially cooperative. However, the total active

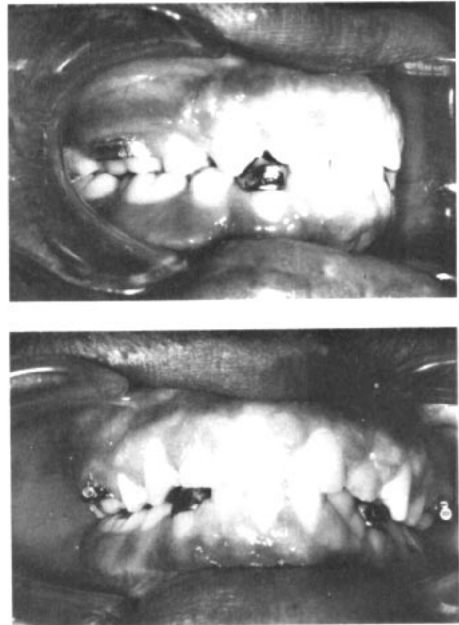


Fig. 5 Appearance of case twelve months after initiation of mechanical treatment.

appliance time was only twelve months (Figure 5). One could not help but be impressed by the response of the teeth to orthodontic forces and the rapidity of movement that ensued.

Facial photographs and the cephalometric tracing at the conclusion of active treatment are shown in Figures 6 and 7. Occlusal photographs of the models before and after appliance therapy are seen in Figure 8.

The patient will again be referred to the Department of Periodontology for reassessment and additional gingival surgery.

Further evidence on the reaction of the tissues at a microscopic level would seem to be warranted in order to adequately explain these clinical observations.

*State Univ. of New York at Buffalo
School of Dentistry
Buffalo, New York 14214*

REFERENCES

1. Goodman, L.S. and Gilman, A. *The Pharmacological Basis of Therapeutics*, Macmillan, New York, 219-224, Third Edition, 1965.
2. Dummett, C. O. Oral Tissue Reactions from Dilantin Medication in the Control of Epileptic Seizures, *J. Periodont.*, 25:112-122, 1954.
3. Aas, E. Hyperplasia Gingivae Diphenylhydantoinea, *Acta Odont. Scan.*, 21: Supp 34, 1-142, 1963.

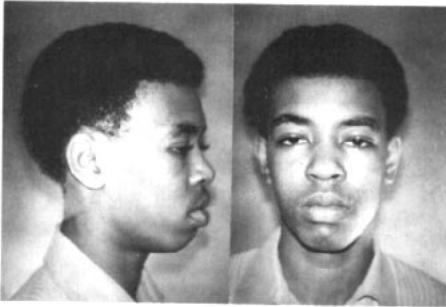


Fig. 6 Facial photographs following active treatment.

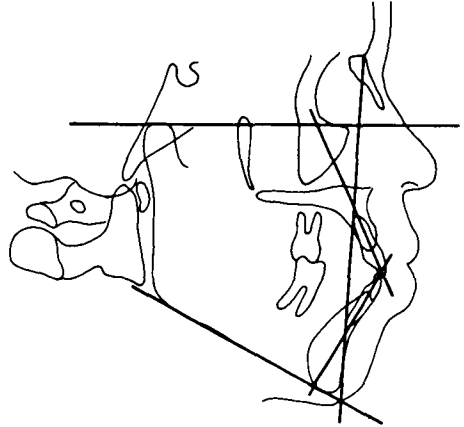


Fig. 7 Cephalometric tracing following active treatment.

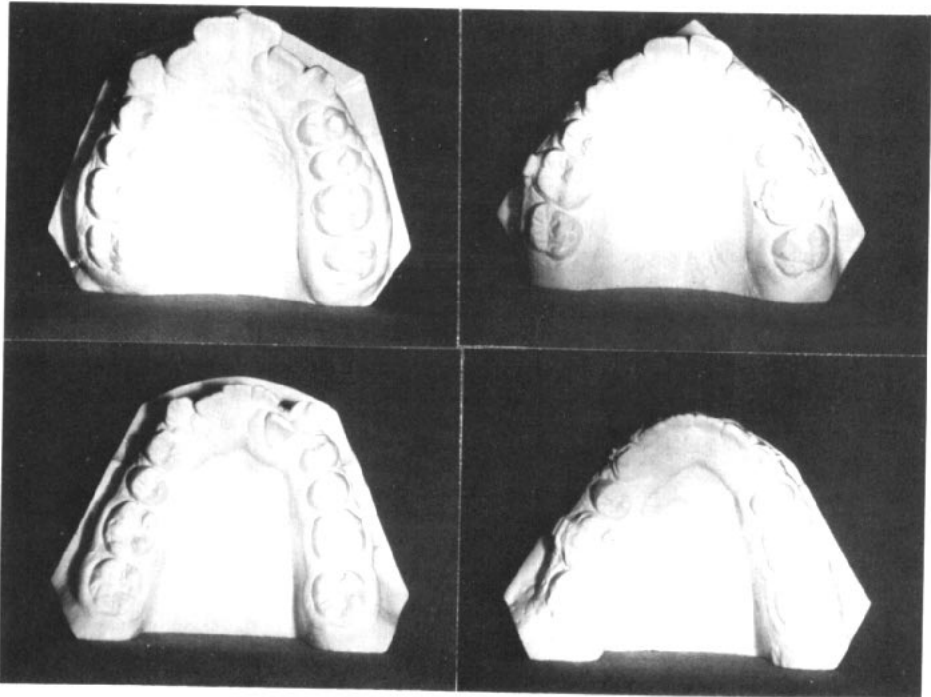


Fig. 8 Left, models before treatment, right, after.