

# The Role of the Functional Matrix in Mandibular Growth\*

MELVIN L. MOSS, D.D.S., Ph.D.

ROBIN M. RANKOW, D.D.S., M.D.

## INTRODUCTION

The orthodontic profession is deeply involved in all aspects of the growth and development of the orofacial region and of the craniofacial complex as well. Several new concepts are currently being put forth which, if they are correct, may well alter some of the now-accepted bases for diagnosis, therapy and prognosis. One of these is the extension of the method of Functional Cranial Analysis to the problem of mandibular growth.

It is evident that the method of Functional Cranial Analysis, in general, and the significance of the role of functional matrices, implicit within this method, are becoming matters of potential meaning to orthodontics. It seems appropriate therefore to provide a more explicit statement of these concepts, together with a forceful example of the application of these concepts to clinical practice. Admittedly, the orthodontist is not called upon to treat the temporomandibular joint surgically. Yet it is undeniably true that much of the therapy of dental malocclusion, as well as the orthodontic contribution to the overall treatment of orofacial malformations, is based importantly upon an appreciation of the growth processes of this region. The present paper attempts to utilize a clinical case report of a new therapeutic technique as a dramatic

means of indicating the applicability of functional cranial analysis to the question of mandibular growth. Specific attention is paid to the demonstration of the primary morphogenetic role of the functional matrices in mandibular growth.

Recent theoretical and experimental studies have fundamentally altered our understanding both of the functional anatomy as well as the growth processes of the mandible. The older unitary view of the mandible has been replaced by the concept of a composite structure formed of a number of relatively independent units. More importantly, we now deemphasize the role of the condylar cartilages in total mandibular growth, limiting their influence to the condylar processes alone. It is explicitly stated<sup>1,2,3</sup> that the normal dimensional and spatial growth changes of the mandible do not depend primarily upon the growth processes occurring within the condylar cartilages. This hypothesis is supported by substantial experimental data.<sup>4,5,6,7,8</sup>

It is obvious that the diagnosis, treatment and prognosis of mandibular growth disturbances primarily depend upon the clinician's conceptions of the biology of the mandible. Ankylosis of the temporomandibular joint, when associated with interference of mandibular growth, is a specific case in point. If it is believed that the affected cartilaginous condylar areas are the primary growth sites of a unitary mandible, then little thought may be given to the possible therapeutic effect of their removal. However, the removal of ankylosed condylar processes in a composite mandible

---

From the Department of Anatomy, College of Physicians and Surgeons, Columbia University; and the Surgical Service, Presbyterian Hospital, New York. Aided, in part, by research grant NB-00965, National Institute of Neurological Diseases and Blindness.

would be expected theoretically to permit the other, nondiseased, mandibular units to move in space as their undisturbed, normal growth continued.

During the past several years one of us (R.R.) has performed bilateral removal of the mandibular condyles in a series of young children suffering from ankylosis of the temporomandibular joints. A sufficient postoperative period permits us to demonstrate the beneficial effects of this surgical procedure on mandibular growth.

#### CASE REPORT

D.P., a seven year-old white female, was first seen in March, 1961 for difficulty in opening the jaws associated with excessive salivation and difficulty in chewing. There was a history of a "hard" delivery but otherwise the birth had been a normal full term. For about three years prior to admission the patient had been unable to open her mouth completely. This was first noted in 1958 when the patient was undergoing tonsillectomy which could not be done because of the limited opening. General somatic growth and development were normal except for a gross hearing loss.

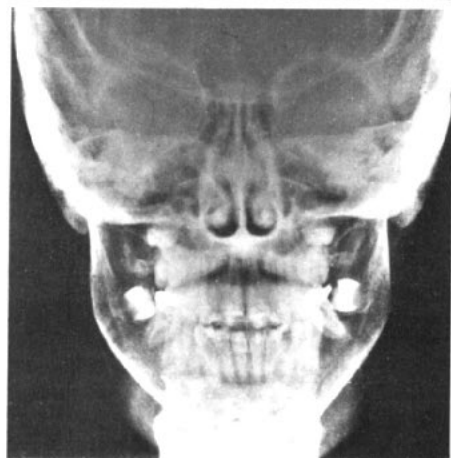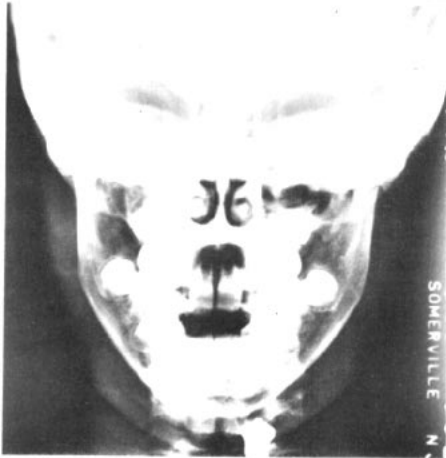
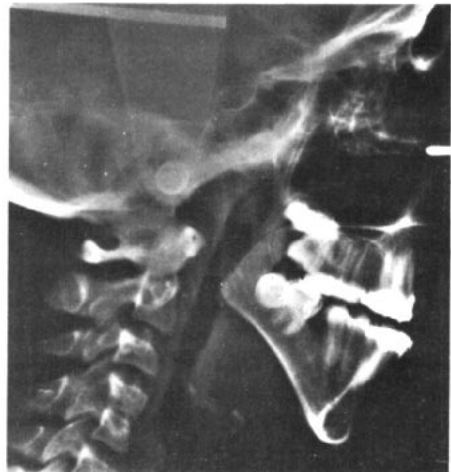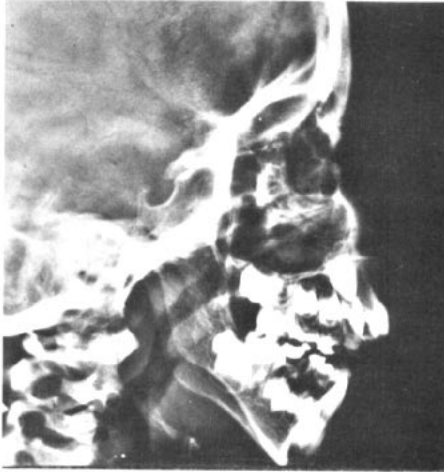The child was admitted to the Babies Hospital, Columbia-Presbyterian Medical Center. Laboratory studies of the blood and urine were within normal limits. The significant physical findings in this well-developed, well-nourished child were pertinent to the oral cavity and the temporomandibular joints. There were marked dental caries and an anterior open bite of the teeth, but only one cm of actual opening of the jaw on forced excursion. Laminagraphic x-rays of the temporomandibular joints confirmed the limited forward movement of the condylar heads in the glenoid fossae. The condyles appeared hypoplastic bilaterally and double forked on the left. A twenty-five per cent bilateral conductive hearing loss,

more marked on the left, was noted after audiograms and clinical testing. In view of these findings, the patient's left temporomandibular joint was explored through a preauricular intertragal transmeatal incision on the day following admission.<sup>9</sup> There was no precise meniscus, only fibrous adhesions to the glenoid fossa of two malformed cartilaginous nubbins representing the bifid condylar process of the mandible. This deformed condylar head was removed after transection at the neck of the condyle. There was distinct improvement of passive opening of the jaws during anesthesia. The patient did well postoperatively and was discharged one week after operation.

The child continued to improve but still had some persistent limitation of a full range of opening of the jaws. Further x-ray studies evidenced a similar deformity of the right mandibular condyle as previously illustrated for the left. The patient was admitted to the hospital and the right temporomandibular joint explored in October, 1961. A bifid cartilaginous condylar head without the presence of an articulating disc was present with adhesion of the smaller knob to the zygomatic arch and of the larger remnant to the glenoid fossa. Following the excision of this deformed bifid condyle, the mandible could be opened widely; it functioned freely thereafter without limitation following discharge eight days after the operation.

The hearing levels returned to normal on both the right and left sides. It was suggested that the restoration of the hearing may have been the result of reventilation of the Eustachian tubes.

The patient has been followed at regular intervals during the past five years and continues to open the jaws widely. The oral status has been corrected with appropriate dental fillings. There is objective esthetic improvement in the facial development. She was last seen in February 1966.



Figs. 1, 2 Logitronic prints of preoperative (1961) lateral and posteroanterior roentgenographs of the patient.

Figs. 3, 4 Longitronic prints of postoperative (1966) lateral and posteroanterior roentgenographs of the patient.

GROWTH ANALYSIS

Pre- and postoperative lateral and posteroanterior head films were taken. The preoperative lateral film was not taken in a standardized manner; however, the others were taken in a cephalometric apparatus (Figs. 1-4).

Acetate tracings were made with a common plane of registration on the anterior cranial base outlines. The rationale of this technique is discussed elsewhere.<sup>10</sup> Analysis of these tracings demonstrated the dimensional and spatial changes of the mandible in the

five year period following bilateral condylectomy.

The posteroanterior tracings (Fig. 5) demonstrate the vertical and lateral growth of the mandible, relative to a nongrowing, and therefore "fixed," anterior cranial base. The lateral tracings (Fig. 6) also demonstrate vertical and horizontal growth of the mandible. Attention is called to the increase in horizontal length of the mandibular corpus, as well as to the vertical lowering of this corpus with increasing age. Specifically, we wish to emphasize that antegonial

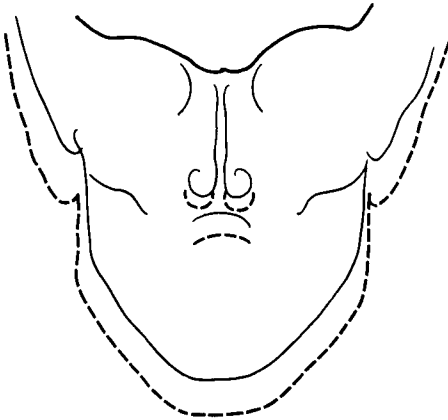


Fig. 5. Superimposed tracings of the posteroanterior films. Solid line is pre-operative, interrupted line is postoperative. Registration is on the outline of the floor of the anterior cerebral fossa and planum sphenoidale. Note the vertical and horizontal growth of the mandible.

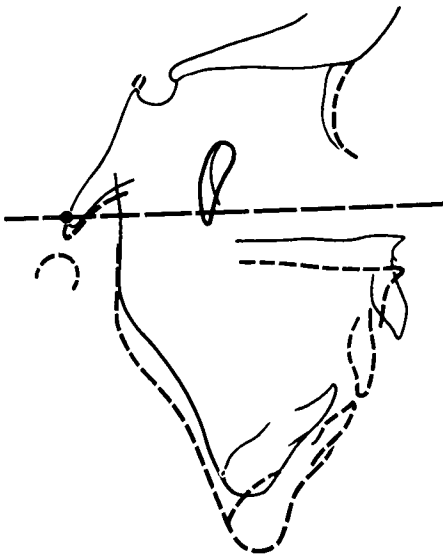


Fig. 6. Superimposed tracings of the lateral films. Registration is on the cerebral surface of the clivus and the anterior cranial fossa. Note especially the growth of the mandibular body in length as well as its lowering in space. Such growth is obviously possible without condyles, being a response to the primary growth of the several functional mandibular matrices. See text for details.

notching did *not* develop in this child. Dental eruption has continued normally. The anterior open bite is being treated orthodontically. The current photographs give no indication of severe mandibular malformation (Fig. 7), and are in marked contrast to the picture of progressive micrognathia (*vogelgesicht*) typically demonstrated by the unoperated patient with bilateral temporomandibular joint ankylosis (see: Figure 9 in reference 11, taken from 12).

In summary, during the five year postoperative period, this noncondylar mandible has: a) lowered in space, b) increased in body length, c) moved horizontally, d) increased in total projective width and e) continued normal dental maturation.

Interpretation of these data requires us to review both the older concepts of mandibular anatomy and growth, as well as the newer ideas derived from the technique of functional cranial analysis developed by us.<sup>2,3,17</sup>

#### PREVIOUS VIEWS OF MANDIBULAR ANATOMY AND GROWTH

In classical osteology it is implicit that the ability to disarticulate and describe a given bone is felt to confer upon this structure a sense of reality. It is quite consistent within such a system to adopt a *unitary* view of the mandible in which this bone is considered to be a biological whole. This unitary bone is divided for descriptive and functional purposes into a body, a chin and several processes: alveolar, angular and coronoid, and a plethora of names and sites of measurement bestowed by anatomists, physical anthropologists and orthodontists.

The process of mammalian mandibular growth has been a subject of study for almost 200 years (see: 2, for a review). The hallmark of the earlier viewpoint is as follows, "the main growth center (of mandibular growth) is the hyaline cartilage in its condyle,"

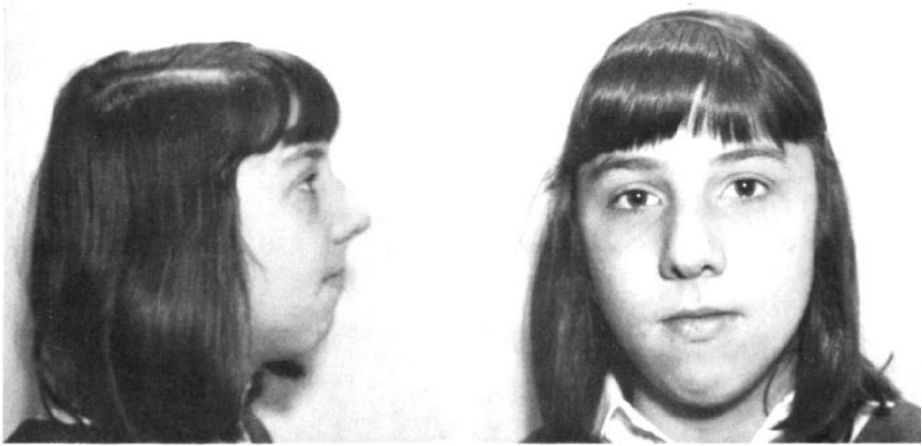

Fig. 7 Photographs of the patient made in 1966. The most important observation is the lack of the typical antegonial notching so characteristic of unoperated patients with temporomandibular joint ankylosis in childhood.

and "Growth at the condyle which rests against the articular fossa at the cranial base causes a downward and forward shift of the entire mandible."<sup>13</sup> The undoubted periosteal growth processes involved in ramal, corpal and alveolar growth were viewed as secondary to the condylar changes. With time, the periosteal contributions were further diminished conceptually.

For example, Peskin and Laskin<sup>14</sup> report that "the mandible condyle is the most important growth center of the mandible. Through interstitial and appositional growth of cartilage in the area *both the height of the ramus and the over-all length of the jaw are increased*" (italics ours). This enthusiasm is matched in a recent publication of Sarnat and Laskin<sup>11</sup> in which the condylar cartilage is said to serve "as the pacemaker and organizer for growth of the entire mandible." (italics ours). To complete this presentation of a once widely-accepted view we note the recent statement of Brodie<sup>15</sup> that "the chief site of growth of the mandible is at the condyle. . . ." In this same paper we find a statement that "the condylar cartilage not only contributes to increase

in ramal height and to total mandibular length, but in addition *to the antero-posterior increments of the mandible as a whole*" (italics ours) (See: Brodie,<sup>15</sup> figure 35 for a graphic presentation of his viewpoint).

We emphatically disagree with these views. The substance of our argument is given below, together with a statement of the newer concepts we have evolved.

#### FUNCTIONAL CRANIAL ANALYSIS OF MANDIBULAR FORM

Theoretical craniology was revitalized by the introduction of the functional cranial component concept of van der Klaauw.<sup>16</sup> Our theoretical and experimental studies led us to a resynthesis of the original hypothesis and to the introduction of the important complementary concept of the functional matrix (see references 17 and 3 for complete literature citations, and 18, 19, 20, 21 for subsequent contributions). For our present purposes the following summary statement will suffice.

The head and neck consists of a number of relatively independent, yet

integrated functions: digestion, respiration, speech, smell, taste, olfaction, audition, balance, vision and neural integration. Each such function is carried out by a *functional cranial component*. Each functional component consists of two parts: a) all of those "soft tissues" necessary to carry out this function, called *the functional matrix*; and b) those "skeletal tissues" which serve to protect and/or to support the functional matrix. This is called *the skeletal unit*.

In some analytical situations it may be shown that the skeletal unit consists of the related parts of more than one bone, i.e., the calvaria consists of the related endocranial surfaces of the frontal, sphenoid, parietal, temporal and occipital bones. In other situations a unitary bone must be broken down into its component skeletal units. As has been demonstrated repeatedly, the mandible is *not* a unitary biological object, but rather a composite of several relatively independent functional cranial components.<sup>2,22,23,24</sup> The skeletal units corresponding to these mandibular functional components include: a) the alveolar process, b) the coronoid process, c) the angular process, d) the body, e) the condylar process and f) the chin.<sup>25</sup> It is experimentally demonstrable that the functional matrix is *primary* and that the presence, size, shape, spatial position and growth of any skeletal unit is *secondary*, compensatory and mechanically obligatory to changes in the size, shape, spatial position of its related functional matrix.

In the mandible, teeth form the functional matrix for the alveolar skeletal unit. The temporalis muscle is the matrix related to the coronoid process. If we cut the nerve to the temporalis muscle, or perform a surgical myectomy<sup>26,27,28</sup> or observe their clinical homologues,<sup>29</sup> we find that the coronoid process alone is either greatly reduced in size or dis-

appears depending upon a number of factors: age, duration, species etc. Similar data exist for the other relatively independent mandibular functional cranial components.<sup>30</sup>

The condylar process is another independent mandibular skeletal unit. Developmentally it differs in that it originates as a mass of secondary cartilage, rather than by intramembranous bone formation. Endochondral replacement is the chief mode of bone formation, although some secondary cartilage undergoes direct metaplasia, *in situ* into osseous tissue, so that cells which at one moment are chondrocytes and chondroblasts are transformed into, not replaced by, osteocytes and osteoblasts. The condylar process fuses with adjacent skeletal units and eventually loses its histological distinctiveness. However, it is possible to have a mandible with one or both condyles congenitally missing. Such bilateral absence does not prevent the remaining mandibular cranial components from existing, growing, functioning or altering their spatial position.<sup>31</sup>

It now appears that the mandible consists of a number of individual functional cranial components, each having a functional matrix and a skeletal unit. It may be demonstrated that individual functional cranial components have no necessary (causal) relationship to each other. That is the size, shape or spatial position of the temporalis muscle and the coronoid process, for example, are not causally related to the size, shape or spatial position of any other mandibular functional cranial component, which may vary independently of the temporalis-coronoid unit. It is critical to grasp the significance of this statement concerning the real independence of cranial components from each other. Any alteration of one matrix causes a corresponding alteration of its specific skeletal unit alone, and does so without *necessarily* causing an alteration in

other adjacent functional cranial components. So, for example, the bilateral removal of the condylar processes in the child will result in the loss of a functional temporomandibular joint, converting the mandible to a muscularly suspended hyoid bone as it were, and in the loss of an effective means of increasing *condylar process length alone*. All other mandibular cranial components will remain relatively unaffected since these other mandibular skeletal units continue to respond normally to their intact and growing matrices.

#### FUNCTIONAL CRANIAL ANALYSIS OF MANDIBULAR GROWTH

Growth of the skull is not *primarily* a process of skeletal tissue growth. The growth of the several functional matrices occurs first, followed, in a secondary compensatory and mechanically obligatory fashion, by the growth of the related skeletal units. In the neurocranium the calvarial bones are embedded within a *neurocranial capsule*. It is the expansion of the enclosed and protected neural mass that provides the primary growth force causing the neurocranial capsule to expand. While the calvarial bones are passively carried outwards and upwards within the expanding capsule they may: a) grow thicker in both plates and diploe, b) alter their curvature and c) increase their area.

The calvarial sutures, like all other sutures, are *not* primary growth sites; they do not "act like epiphyses," and the expansion of the neural skull is *not* a secondary result of primary sutural expansion.<sup>3</sup> This same passive transport increasingly separates adjacent bones at sutural areas. New bone formation at sutural areas is a secondary, compensatory osteogenesis, successfully keeping the mechanically important sutures in being. Observation of such bone formation is not evidence of an interstitial

growth force pushing the bone apart. Briefly, primary growth of the neural mass causes the skull to expand secondarily.

Let us apply these concepts to the facial skull (splanchnocranium). The facial bones lie embedded within an orofacial capsule. This capsule surrounds such functional matrices as teeth, sinus spaces, glands, muscles, blood vessels and nerves and the biologically real volumes of the nasal, oral and pharyngeal cavities. The facial sutures are functionally identical with the calvarial sutures, i.e., their growth is not the primary cause of facial skull growth. As in the neural skull, it is the growth of the orofacial matrices that furnishes the primary morphogenetic forces for facial skull growth. The primary growth of these matrices causes the orofacial capsule to expand secondarily, outwards, downwards and laterally. Each of the individual skeletal units is passively translated as its functional matrix grows, and each skeletal unit grows in response to the altering spatial and functional demands of its related matrix. The direction of growth of the skeletal units, of course, bears no necessary relationship to the direction of passive translation, i.e., some surfaces of several maxillary and mandibular skeletal units may grow upward or backward, as the bone is being translated downward or forward respectively.<sup>42</sup>

Normally the mandible, as a whole, simultaneously lowers and moves anteriorly in space with the expansion of the orofacial matrix. Such movement would passively disarticulate the temporomandibular joint if there was not a secondary, compensatory and mechanically obligatory growth of the condylar cartilages. The growth observed at the condylar cartilage is not primary or, in *any* way, responsible for the growth of any other mandibular skeletal unit except the condylar process itself.

We need not concern ourselves here with a detailed exposition of either the absolute direction of growth of the several mandibular skeletal units or with a precise description of the morphologic processes at any specific site. It is sufficient to say that growth of all other mandibular skeletal units are the result of periosteal deposition and resorption.<sup>2</sup> The recent work of Enlow<sup>32,42</sup> demonstrates very well the complex nature of the spatial relocations and of the histological processes involved.

Condylectomy of experimental animals has been reported often.<sup>4,33,34,35,36,37,38,39,40,41</sup> Species differences must be carefully noted in comparing these data. Taken as a whole they show undoubted interruption of growth in length of the condylar processes post-operatively. However, in animals from which the mandibular condyles have been removed bilaterally, the remaining bone does function, grow and change its spatial position as the other intact mandibular matrices grow. "The present study of the effects of bilateral condylectomy in the rat confirmed previous investigations in showing that there was little impairment in masticatory function and that the condylectomized mandible continued to increase in size."<sup>37</sup> Such a result is surely desired in the treatment of children with bilateral temporomandibular joint ankylosis. Bilateral condylectomy is one method of attaining this.

#### SUMMARY

The application of the method of Functional Cranial Analysis to the study of human mandibular growth is reported. This has been done in the context of a five-year longitudinal study of the essentially normal dimensional and spatial growth changes in the mandible of a preadolescent patient, following bilateral removal of the condyles for the relief of temporomandibular joint ankylosis.

The biological bases for such continued growth changes are discussed with particular emphasis on the related concepts of functional cranial components and the functional matrix. It is emphasized that normally the condylar cartilages are not primary growth sites, in any way responsible for mandibular growth as a whole, but rather act as sites of secondary and compensatory growth of the condylar processes alone. Growth of the other portions of the mandible is governed by their own growth processes and is independent of condylar growth.

630 West 168th St.  
New York, N.Y. 10032

#### REFERENCES

1. Moss, M. L., Embryology, Growth and Malformation of the Temporomandibular Joint. in: *Disorders of the Temporomandibular Joint*. Ed. L. Schwartz, 89, W. B. Saunders, Phila. 1959.
2. ———, Functional analysis of human mandibular growth. *J. Prosth. Dent.*, 10:1149, 1960.
3. ———, The Functional Matrix, in: *Vistas in Orthodontics*. Eds. B. Kraus and R. Reidel, 85, Lea and Febiger, Phila. 1962.
4. Gianelly, A. S. and C. F. A. Moorrees, Condylectomy in the rat. *Arch. Oral Biol.*, 10:101, 1965.
5. Irving, J. T. and J. F. Durkin, A comparison of the changes in the mandibular condyle with those of the upper tibial epiphysis during the onset and healing of scurvy. *Arch. Oral Biol.*, 10:179, 1965.
6. Koski, K. and L. Makinen, Growth potential of transplanted components of the mandibular ramus of the rat. I. *Finska Tandlark. Forhandl.*, 59: 296, 1963.
7. Koski, K. and K. Mason, Growth potential of transplanted components of the mandibular ramus of the rat. II. *Finska Tandlark. Forhandl.*, 60:209, 1964.
8. Koski, K. and O. Ronning, Growth potential of transplanted components of the mandibular ramus of the rat. III. *Finska Tandlark. Forhandl.*, 61: 292, 1965.
9. Rankow, R. M. and A. J. Novack, Transmeatal condylectomy and meniscectomy. *Arch. Otolaryngol.*, 70: 703, 1959.



10. Salzman, J. A. (ed.), *Roentgenographic Cephalometrics*, J. B. Lippincott, Phila., 1961.
11. Sarnat, B. G. and D. M. Laskin, *Diagnosis and Surgical Management of Diseases of the Temporomandibular Joint*. C. C. Thomas, Springfield, 1962.
12. Engel, M. B., J. Richmond and A. G. Brodie, Mandibular growth disturbances in rheumatoid arthritis in childhood. *Amer. J. Dis. Child.*, 78: 728, 1949.
13. Weinmann, J. P. and H. Sicher, *Bone and Bones*, 2nd Ed., C. V. Mosby, St. Louis, 1955.
14. Peskin, S. and D. M. Laskin, Contributions of autogenous condylar grafts to mandibular growth. *Oral Surg., Oral Med. Oral Path.*, 20:517, 1965.
15. Brodie, A. G., Contributions of the mandibular condyle to the growth of the face. in: *The Temporomandibular Joint*, B. G. Sarnat, 2nd Ed., 77, C. C. Thomas, Springfield, 1964.
16. Klaauw, C. J. van der, Functional components of the skull. *Arch. Neerl., Zool.*, 8:1, 1948-1952.
17. Moss, M. L. and R. W. Young, A functional approach to craniology. *Am. J. Phys. Anthrop.*, 18:281, 1960.
18. Moss, M. L., D. Ju and G. Crikelair, Effect of radiation on the development of facial structures in retinoblastoma cases. *Am. J. Surg.*, 106: 807, 1963.
19. Moss, M. L., Morphological variations of the crista-galli and medial orbital margins. *Am. J. Phys. Anthrop.* 21:159, 1963.
20. ———, Vertical growth of the human face. *Am. J. Orthodont.*, 50: 359, 1964.
21. ———, Hypertelorism and cleft palate deformity. *Acta. Anat.*, 61: 547, 1965.
22. Symons, N. B. B., Studies on the growth and form of the mandible. *Dent. Rec.*, 71:41, 1951.
23. Washburn, S. L., The new physical anthropology. *Trans. N.Y. Acad. Sci.*, 13:298, 1951.
24. Moss, M. L., A biometric study of human mandibular segments. *Am. J. Phys. Anthrop.*, 10:257, 1952.
25. Horowitz, S. L. and R. H. Thompson, Variations of the craniofacial skeletons in postadolescent males and females. *Angle Orthodont.*, 34:97, 1964.
26. Washburn, S. L., The relation of the temporal muscle to the form of the skull. *Anat. Rec.*, 239, 1947.
27. Horowitz, S. L. and H. H. Shapiro, Modification of the skull and jaw architecture following removal of the masseter muscle in the rat. *Am. J. Phys. Anthrop.*, 13:301, 1955.
28. Avis, V., The relation of the temporal muscle to the form of the coronoid process. *Am. J. Phys. Anthrop.*, 17:99, 1959.
29. Rogers, W. M., and E. Applebaum, Changes in the mandible following closure of the bite with particular reference to edentulous patients. *J. Am. Dent. Assoc.*, 28:1573, 1941.
30. Avis, V., The significance of the angle of the mandible: an experimental and comparative study. *Am. J. Phys. Anthrop.*, 19:55, 1961.
31. Kazanjian, V. H., Bilateral absence of the ascending rami of the mandible. *Brit. J. Plast. Surg.*, 9:77, 1956.
32. Enlow, D. H., *Principles of Bone Remodeling*, C. C. Thomas, Springfield, 1963.
33. Jarabak, J. R. and T. M. Graber, Growth of the upper face following bilateral condylar resection. *J. Dent. Res.*, 30:491, 1951.
34. Jarabak, J. R., and K. Veke, Condylar regeneration in the rat. *J. Dent. Res.*, 31: 510, 1952.
35. Jarabak, J. R., and J. R. Thompson, Growth of the mandible of the rat following bilateral resection of the mandibular condyles. *J. Dent. Res.*, 30:492, 1951.
36. Jolly, M., Condylectomy in the rat. *Aust. Dent. J.*, 6:243, 1961.
37. Das, A., J. Meyer and H. Sicher, X-ray and alizarin studies of the effect of bilateral condylectomy in the rat. *Angle Orthod.*, 35:138, 1965.
38. Sarnat, B. G. and M. B. Engel, A serial study of mandibular growth after removal of the condyle in the *Macaca rhesus* monkey. *Plast. Reconstr. Surg.*, 7:364, 1951.
39. Sarnat, B. G., Facial and neurocranial growth after removal of the mandibular condyle in the *Macaca rhesus* monkey. *Am. J. Surg.*, 94:19, 1957.
40. ———, Postnatal growth of the upper face: some experimental considerations. *Angle Orthod.*, 33:139, 1963.
41. Sarnat, B. G. and D. M. Laskin, Surgery of the temporomandibular joint. in: *The Temporomandibular Joint*, 2nd Ed., 185, B. G. Sarnat, C. C. Thomas, Springfield, 1964.
42. Enlow, D. H., A morphogenetic analysis of facial growth. *Am. J. Orthodont.*, 52:283, 1966.