

# Developmental Migration Of Mandibular Buccal Dentition In Man\*

MELVIN L. MOSS, D.D.S., Ph.D.,  
SAUL N. GREENBERG, D.D.S. and  
CHARLES R. NOBACK, Ph.D.\*\*  
*New York, New York*

## INTRODUCTION

It is universally accepted that the facial skeleton is growing during the preadolescent and adolescent years in which orthodontic therapy is usually instituted. An extensive and generally excellent literature reports many of the morphological and mensural aspects of these growth processes. The orthodontist is aware that the growth of this region, in general, and of the maxilla and mandible in particular may greatly influence the clinical end result. It is not so well appreciated that the teeth themselves undergo certain positional changes relative to the bones which support them. This question is at once of basic interest to both the student of cranial morphogenesis and to the clinical orthodontist. The proper application of extrinsic forces to teeth which may then be moving in one or more planes of space *independently* of the movements of their supporting bones requires more than a philosophical acceptance that such movements exist. What is needed is a more precise and quantifiable description of such dental movements.

\*\* Department of Anatomy, College of Physicians and Surgeons, and Division of Orthodontics, School of Dental and Oral Surgery, Faculty of Medicine, Columbia University, New York.

\* Aided, in part, by a grant (A-812-C2) National Institute of Arthritis and Metabolic Diseases, National Institute of Health, Public Health Service.

The present paper reports data on one aspect of these movements; the normal anterior (mesial) migration of the mandibular buccal dentition. The correlation of such movements with the maturational status of the skeleton is noted. Finally, a possible role of these movements in the pathogenesis and treatment of Class II malocclusion is tentatively suggested.

## MATERIALS AND METHODS

The mental foramen was the reference point by which tooth movement was judged. It had been established previously that the site of this foramen in the mandibular body was proportionately identical at all ages in man<sup>1, 2</sup>. Tooth position was determined by the relationship of the root apex to the center of the foramen. In dried skulls root position was projected from the crown, while in x-rays of patients position was determined directly. Obviously tilted teeth, or those with curved apices were rejected. The left side was used consistently, both cross-sectional and longitudinal growth study techniques were used.

*Cross-sectional data:* These consisted of 233 American Indian skulls of all ages from the Department of Physical Anthropology, Harvard University, 118 assorted adult skulls from the Department of Physical Anthropology, American Museum of Natural History, and 37 *Macaca mulata* and *M. rhesus* skulls of various ages from the Department of Mammology of the latter in-

Table 1  
Position of mental foramen relative to  
mandibular dentition (in %) — left side of  
American Indians

	C	$m_1(P_1)$	$m_1-m_2(P_1-P_2)$	$m_2(P_2)$	$P_2-M_1$	$M_1$
No Decid. Dent. N=14	71.5	28.5				
Lower Decid. Incisors erupted N=14		100.0				
$m_2$ not erupted N=9		100.0				
Complete Decid. Dent. erupted N=65		90.8	9.2			
$M_1$ erupted N=29		38.0	44.8	17.2		
$M_1 - I_{1,2}$ erupted N=36		16.7	44.5	38.8		
$M_2$ erupted N=23			39.1	60.9		
$M_3$ erupted N=43			7.0	57.8	25.5	11.7

stitution.

X-rays of dental patients in this institution were obtained in an intra-oral film survey of 163 random white patients between the ages of 8 and 18 years (courtesy of Dr. J. A. Cuttita). No attention was paid to the orthodontic status of this group.

*Longitudinal data:* These were obtained during a three year study of 53 white Class II, Div. 1 patients. At the outset these patients were either untreated or had just had therapy instituted. There were no extractions in any patient and no deciduous teeth were present in either arch. All of these patients were included in a larger longitudinal study of digital epiphyseal fusion<sup>3</sup>. In 38 cases these epiphyses were either unfused or fusion was underway. This group was termed "open" and consisted of 19 males and 19 females with an initial mean age of 12.5 and 11.5 years respectively. In 15 cases digital epiphyseal fusion was

complete. This group was termed "fused" and were all female with an initial mean age of 13.5 years. Lateral jaw films were taken periodically in a standardized position, with a mean interval of 9 months. Serial, cephalometrically oriented, lateral skull films were also taken of each patient.

#### RESULTS

*Cross-sectional:* Tables 1 and 2 present data of the tooth position relative to the mental foramen in both man and Macaca monkey. In both forms, tooth migration was first noted when the first permanent molars were erupted. The extent of this migration is obviously conditioned by racial and ethnic factors. The random, white, cross-sectional sample of our clinic population (Table 3) shows a more retrusive position of the mandibular buccal dentition when compared with the other samples listed in Table 4 and with the corresponding data in Table 1.

Table 2  
Position of mental foramen relative to mandibular dentition in  
*Macaca Monkey*

	C-m <sub>1</sub>	m <sub>1</sub> (P <sub>1</sub> )	m <sub>1</sub> -m <sub>2</sub> (P <sub>1</sub> -P <sub>2</sub> )	m <sub>2</sub> (P <sub>2</sub> )	m <sub>2</sub> -M <sub>1</sub> (P <sub>2</sub> -M <sub>1</sub> )	M <sub>1</sub>	No.
Fetal	1						1
m <sub>2</sub> erupting		1					1
Complete decid. dent.	1	6					7
M <sub>1</sub> erupted	1	5	3				9
M <sub>1</sub> -I <sub>1</sub> erupted			1				1
M <sub>2</sub> present				6			6
M <sub>2</sub> -C present				1			1
M <sub>3</sub> present				4	3	4	11
No.	3	12	4	11	3	4	37

Table 3  
Position of mental foramen relative to  
mandibular dentition in whites (8-18 years).  
Data derived from intraoral x-rays

Age	P <sub>1</sub>	P <sub>1</sub> -P <sub>2</sub>	P <sub>2</sub>	P <sub>2</sub> -M <sub>1</sub>
8 N=7	2	3	2	—
9 N=15	2	12	1	—
10 N=14	3	10	1	—
11 N=15	3	11	1	—
12 N=10	2	7	1	—
13 N=18	1	15	2	—
14 N=19	0	14	4	1
15 N=24	3	14	7	—
16 N=18	0	14	4	—
17 N=13	0	9	4	—
18 N=10	1	7	2	—
Total N=163	17	116	29	1
Total Percent	10.4	71.2	17.8	0.6

Table 4  
The position of the mental foramen  
relative to mandibular teeth (in %)

Author	P <sub>1</sub>	P <sub>1</sub> -P <sub>2</sub>	P <sub>2</sub>	P <sub>2</sub> -M <sub>1</sub>	M <sub>1</sub>	No.
della Serra <sup>1</sup> .....	0.5	33.0	58.5	6.5	2.0	100
Tebo <sup>2</sup> .....	1.8	23.0	49.9	24.1	1.2	100
Moss <sup>3</sup> .....	.6	27.1	50.8	19.3	2.2	184
Moss <sup>4</sup> .....				100.0		31

<sup>1</sup>Brazilian adults (Topographia do canal mandibular. 1-114. S. Paulo 1945)

<sup>2</sup>Unselected adults (Dent. Items Inter., 73: 52-53, 1951)

<sup>3</sup>Random adult sample from the American Museum of Natural History.

<sup>4</sup>Australian Aboriginal adult mandibles from the same institution.

### Longitudinal

Dental migration relative to the mental foramen was observed in 17 of the 38 open cases (8 males and 9 females) and in none of the 15 fused cases (Table 5). In these 17 cases, 15 demonstrated movement equivalent of one half a premolar tooth width and 2 cases demonstrated movement equivalent to the width of a complete premolar tooth. The mean age at which the dental migration occurred was

14.0 years for the males and 12.0 years for the females.

Epiphyseal fusion was not completed in any of the 17 open cases which migrated during the course of the study and was observed in only two of the 21 open cases which showed no migration. It is apparent that the 36 open and fused cases in which no dental migration was observed had already completed those movements prior to the inception of the study

Table 5  
Position of mental foramen relative to mandibular  
dentition of orthodontic patients.\*

Source of material—lateral jaw x-rays

	Mean age years		P <sub>1</sub>	P <sub>1</sub> -P <sub>2</sub>	P <sub>2</sub>
Shift cases—open					
8 males	13.0 (M)		14	3	0
9 females	11.5 (F)	initial			
N=17					
	14.0 (M)		0	12	5
	12.0 (F)	final			
No Shift—open					
11 males	12.1 (M)		6	13	2
10 females	11.8 (F)	initial			
N=21					
No Shift—fused					
15 females	13.5 (F)	initial	3	8	4
N=15					

\* In this table "shift cases" are those showing dental migration, "open" refers to epiphyseal status. Initial age is age of first x-ray, while final age is that at which a film first demonstrated the shift.

(Table 5).

The reality of these movements had been preliminarily confirmed by animal experimentation. In two Green monkeys with metallic mandibular implants similar absolute dental migration has been observed. These data will be published elsewhere.

#### DISCUSSION

Human fetal studies substantiate the initial position of the mental foramen. At the third fetal month the usual location is between the developing follicles of the deciduous cuspid and the first deciduous molar<sup>4, 5</sup>. Our data make it clear that no essential anterior motion of the teeth occurs until the deciduous dentition is complete, in both man and monkey.

The alteration of the position of the mental foramen relative to the mandibular buccal dentition is unquestioned. The use of this foramen as a fixed point for measurement is justified in the following way. Let us divide the mandibular body into two horizontal chords, one extending from the mandibular foramen to the mental foramen and the other from the mental foramen to the mid-line of the mental symphysis, with the mandible held in a constant position<sup>6</sup>, in a series of mandibles of various ages. We measure the two chords as well as the transverse distance between the two mental foramina. We then determine the percentage of the whole that each chord forms. We may, alternately, plot these data on log paper and demonstrate their allometric relationships. Either way it will be found that throughout the growth of the mandible the mental foramen maintains a constant relationship. In Figure 1 the anterior segment is constantly 32% of total horizontal length. It is clear in this figure that the increase of anterior chord length is easily accounted for by the lateral increase in inter-

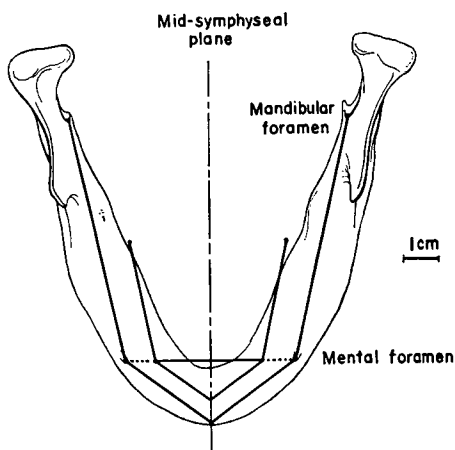


Fig. 1 An occlusal view of a human adult mandible with the dentition omitted. Two chords are shown, the anterior connecting the mid-symphyseal point with the mental foramen, the posterior connecting the mental and mandibular foramina. The inner chords illustrate identical relationships in a circumnatal mandible (anterior chord is 32% of total length). The transverse distance between the mental foramina is also shown. The dimensions of these chords and of the transverse diameter represent mean values of groups of North American Indian mandibles, adult and circumnatal, gathered at one pueblo (Canyon del Muerto, Arizona). The dimensional increases in chord and transverse lengths are proportional. The relative constancy of the site of the mental foramen is illustrated.

foraminal width alone, without recourse to any posterior movement of the foramen. Obviously the data presently reported indicate an absolute anterior migration of the buccal teeth through the alveolar bone.

Substantial support for our hypothesis is obtained from the literature. Studies by Friel<sup>7</sup> in both man and lower primates, of Clinch<sup>8</sup> and Bonnar<sup>9</sup> in man have established that the initiation of this movement occurs between the completion of the deciduous and the onset of the permanent dentition. They show further that these movements are not due to a mere "drifting" of teeth to close interproximal spaces. On the contrary, it is quite

clear that both maxillary and mandibular buccal segments move as a whole, often independently of each other and without necessary bilateral simultaneity. Whatever objections might have been raised in the part of the work of these authors, among others, on the ground of a lack of a fixed reference point would appear to be obviated by our present study. Similar movements of maxillary buccal teeth alone has been reported by Ly-sell<sup>10</sup> using the palatine rugae as a reference site.

The histological basis for the bodily movement of teeth through bone is quite firm. The data of Schwartz<sup>11</sup>, Stein and Weinmann<sup>12</sup>, and of Weinmann<sup>13</sup> have definitively established the simultaneous sequences of mesial osseous resorption and distal osseous apposition in buccal dental segments. Recently a homologous sequence was histologically established for the migration of the anterior teeth<sup>14</sup>.

While the reality of these movements is still a matter of discussion in some orthodontic circles, with pros and cons vigorously held<sup>15, 16</sup> biological thought on the matter is best summarized by Brash<sup>17</sup> who states "forward movement of the cheek-teeth in the alveolar bone is a fundamental phenomenon of the growth of the mammalian jaws".

#### CLASS II MALOCCLUSION

Our longitudinal data clearly demonstrated the final stages of dental migration in the 17 open cases. These same data, in addition, also showed that a Class II malocclusion is not necessarily related to dental migration or the lack of it. Certainly in the 21 open cases and in the 15 fused cases, in which the dental shift had already occurred, the malocclusion prior to treatment was no less real than in the 17 cases in which the buccal segments had not yet completed their move-

ment. The possibility remains that in these 17 cases a premature cessation of normal dental migration was etiologically significant. That tooth position alone differentiated these Class II cases was substantiated by tracings of the morphologic contours of the skull base<sup>18</sup> and of the facial skeleton obtained from the cephalometric films. These failed to reveal any difference between the several Class II subgroups. No sex differences were noted.

Dental migration occurred in our 17 cases during therapy. It is interesting to speculate as to the effect the lack of therapy might have had on the migration of teeth in these patients. The type of therapy had no apparent relationship to movement. In these 17 cases molar relationships became normal when dental migration was completed. In the remaining cases clinical correction occurred without further mandibular dental migration. The concept of correction through migration, in some cases, supports the views of Sleichter<sup>19</sup>. The possibility that the maxillary buccal dentition has migrated anteriorly more than normal in the remaining Class II cases raises interesting aspects worthy of further research.

The dichotomous classification of our longitudinal series into open and fused groups was clinically justified. Examination of the clinical progress notes invariably showed that treatment was at once more rapid and satisfactory in the open group, while in the fused group progress was slow and difficult at best.

In essence we were able to observe dental migration during therapy in a group of patients whose digital epiphyses were unfused. These patients were not younger than those similarly maloccluded in which dental migration had already occurred and whose digital epiphyses were also unfused. In the concurrent study of

digital epiphyseal fusion<sup>3</sup>, a quantitative measure of the rate of skeletal maturation was derived. On the average our present 17 cases demonstrating a delayed shift were characterized by a *slow* rate of digital epiphyseal fusion (i. e., they took about twice as long to fuse a given digital epiphysis as did a *fast* group). It has been established that the maturational status of the hand is a good indicator of general skeletal maturity<sup>20</sup>. Seemingly, dental migration is correlated in some manner with the rate of skeletal maturation as a whole.

#### SUMMARY

1. A longitudinal roentgenographic study of white Class II, Div. 1 adolescents was made.
2. The position of the mandibular buccal dentition was studied relative to the mental foramen. The position of this foramen was shown to be proportionately constant at all ages. The longitudinal data were compared with several cross-sectional studies.
3. In 17 cases an absolute mesial migration of these teeth was observed. This was shown to be the completion of a normal, physiological movement.
4. An additional 36 cases did not show such migration, as it had been completed prior to the inception of this study.
5. The status of digital epiphyseal fusion was used as an index of skeletal maturation. The dental migration occurred prior to the completion of this fusion.
6. It appeared that dental migration was completed more rapidly in cases whose rates of skeletal maturation were similarly more rapid.
7. The role of dental migration in

the etiology and treatment of this type of malocclusion was discussed.

630 West 168th St.

#### REFERENCES

1. Moss, M. L.: A Biometric Study of Human Mandibular Segments. *Am. J. Phys. Anthropol.*, 10: 257, 1952.
2. Moss M. L.: Differential Growth Analysis of Bone Morphology. *Am. J. Phys. Anthropol.*, 12: 71-75, 1954.
3. Moss, M. L.: and C. Noback: A Longitudinal Study of Digital Epiphyseal Fusion in Adolescence. *Anat. Rec.*, 131: 19-32, 1958.
4. Wasserfallen, P.: Les Changements de Positions des Follicules Dentaires dans la Mandibule du Foetus Humain. *Schw. Monatsch. Zahnh.*, 64: 551-581, 1954.
5. Mani G.: Les Positions des Follicules Dentaires dans le Maxillaire du Foetus Humain. *Arch. Stoma.*, 12: 117-146, 1957.
6. Morant, G. M.: A Biometric Study of the Human Mandible. *Biometrika*, 28: 84-122, 1936.
7. Friel, S.: The Development of Ideal Occlusion of the Gum Pads and the Teeth. *Am. J. Ortho.*, 40: 196-227, 1954.
8. Clinch L. M.: An Analysis of Serial Models between Three and Eight Years of Age. *Dent. Rec.*, 71: 61-72, 1951.
9. Bonnar, E. M. E.: Aspects of the Transition from Deciduous to Permanent Dentition. *Dental Practitioner*, 7: 42-54, 1956.
10. Lysell, L.: Plicae Palatinae Transverse and Papilla Incisiva in Man. *Acta Odont. Scand.*, 13: Suppl. 18, 1955.
11. Schwarz A. M.: über die Bewegung belasteter Zähne. *Zeit. Stomat.*, 26:40-83, 1928.
12. Stein, G. and J. Weinmann: Physiological Tooth Migration and its Significance for the Development of Occlusion. *J. Dent. Res.*, 29: 338, 1950.
13. Weinmann, J.: Das Knochenbild bei Störungen der Physiologischen Wanderung der Zähne. *Zeit. Stomat.*, 24: 397-423, 1926.
14. Schneider, B. and H. Sicher: Physio-

- logic Migration of Anterior Teeth. *Angle Ortho.*, 28: 166-175, 1958.
15. Sved, A.: The Mesial Drift of Teeth During Growth. *Am. J. Ortho.*, 41: 539-553, 1955.
  16. Baume, L. J.: Physiological Tooth Migration and its Significance for the Development of Occlusion. *J. Dent. Res.*, 29: 123-132; 331-338, 1950.
  17. Brash, J. C.: Comparative Anatomy of Tooth Movement During Growth of the Jaws. *Trans. Brit. Soc. for the Study Orthod.*, 97-118, 1952.
  18. Moss, M. L. and S. N. Greenberg.: Post-natal Growth of the Human Skull Base. *Angle Ortho.*, 25: 77-84, 1955.
  19. Sleichter, C. G.: Some Effects of the Occlusal Guide Plane in the Treatment of Class II, Div. I. Malocclusions. *Am. J. Ortho.*, 43: 83-89, 1957.
  20. Reynolds, E. L. and T. Asakawa: Skeletal Development in Infancy. *Am. J. Roentgen. Radium Ther.*, 65: 403-409, 1951.