

An Investigation of the Use of Occipital Anchorage in Orthodontic Treatment*

CHARLES S. KRESNOFF, B.S.D., D.D.S., M.S.D.
Chicago, Illinois

THE EFFECTIVENESS of any orthodontic mechanism for the application and control of force upon the dental units is dependent upon the nature of its anchorage. Intra-orally at least, as Strang so aptly put it, "stationary anchorage in orthodontia is a myth."²⁵ It is only when one anchorage unit is placed extra-orally that the reaction of the intra-oral forces upon it may be disregarded. Herein lies the principal advantage of occipital anchorage.

This study was prompted by the return of orthodontists' interest in the use of occipital anchorage. The Broadbent Bolton^{4,5} technique provided a more accurate appraisal of tooth movement than clinical observation and substantiation by other orthodontic records in common usage. It was our purpose to study the evolution of the technique and principles of occipital anchorage and their clinical application.

HISTORICAL REVIEW

The first use of the occiput as an aid to support structures in and about the mouth lies buried in antiquity. Perhaps it originated when man discovered that the pain of an injured jaw could be somewhat alleviated if it were held at rest by means of a sling tied to the top and back of the head. Soranus in the second century was the first to record the use of a head bandage to support an injured mandible.¹⁸ The popular use of the head bandage to immobilize jaw fractures led to its use by Cellier in 1802 for the treatment of luxation (Fig. 1) and by Fox in 1803 "to prevent accidents from happening in the extraction of teeth."³⁰

As is frequently the case in the evolution of an idea or a technique many men may arrive simultaneously at similar conclusions and the lag between the formal announcement and subsequent recording make it difficult to ascertain and give historical priority to the authors involved. The first use of occipital anchorage in the correction of irregularities of the teeth is difficult to determine.

Gunnel claimed to have used Fox's head bandage (at the suggestion of H. H. Hayden) in conjunction with ivory wedges to open the bite in the case of a protruding lower jaw in 1822 or 1823. Actually this claim was first recorded by him in 1841.¹⁵

In the first German book devoted to malocclusion, *Der Schiefstand der Zahne*, Christopher Kneisel in 1836 mentioned the use of occipital

* Presented before the Mid-Western Component of the Edward H. Angle Society of Orthodontia, October 18-20, 1942.

The material from which this paper is prepared was gathered in the Orthodontic Section, Northwestern University Dental School in partial fulfillment of the requirements for the degree of Master of Science in Dentistry.

anchorage. In order to effect the labial movement of an upper incisor he employed the force of a flat spring plate which was attached to the crown of a lower incisor, against the lingual surface of the upper tooth. To prevent displacement and enhance the spring action he applied “. . . a cap of linen with earlaps from the chin to the head in order to force the lower jaw against the upper.”¹⁹



Fig. 1



Fig. 2

The middle of the nineteenth century found the use of occipital anchorage for the correction of prognathism well established as recorded by Wescott²² (Fig. 2) and Sewill.²² The literature abounds with voluminous discussions of minor variations in the construction and application of the head-cap to cases of this kind. In the last quarter of the century we find occipital anchorage being used in other types of malocclusions. In 1873 Tomes was the first to record its use in a so-called successful correction of an “open bite”;²⁸ and Heinrich Potpeschnigg in the *Deutsches Viertel Jahr-*

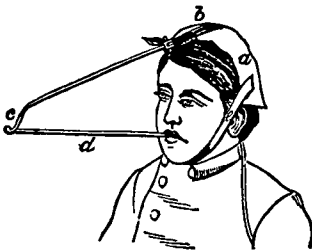


Fig. 3

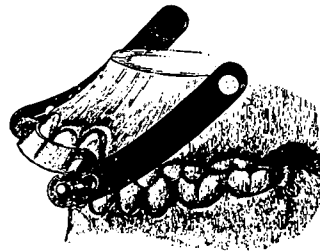


Fig. 4

schrift für Zahn Heilkunde in 1875 illustrates an incredible appliance for moving an anterior tooth²⁰ (Fig. 3).

It remained for Kingsley, a mechanical genius, artist, and sculptor, who has been called the father of modern orthodontia, to pioneer and popularize the use of occipital anchorage in a variety of malocclusions.

In 1875 Kingsley employed a vulcanite palate from rubber pulled

distally on a strip of gold covering the labial surfaces of the upper anterior teeth in order to effect their retrusion. Gold spurs one-half inch long were soldered to the labial strip and projected to the corners of the mouth.¹⁷ Brass strips were then attached to the spurs and they in turn were connected by means of elastics to a leather skull cap (Fig. 4). In this way he attempted to supplant the intra-oral action of the rubber tubing so that "the outside pressure was forcing the teeth up into the jaw, while the pressure inside was carrying them in a direct line backwards." The combined intra- and extra-oral pressures according to Kingsley not only tended to depress the elongated incisors but also inhibited their downward growth anteriorly.

Another method for the treatment of protruding incisors as described by Kingsley consisted of the use of a "skeleton headcap"¹⁶ in conjunction with an arch bar and attachment. Figure 5 illustrates his use of a chin strap in



Fig. 5

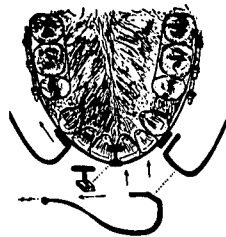


Fig. 6

conjunction with occipital anchorage for the correction of an open bite where the deformity was primarily confined to the lower jaw.

Farrar,¹³ publishing contemporaneously with Kingsley, modified the attachment of the head gear to fasten directly into a sleeve-like device on the intra-oral arch wire (Fig. 6). Evidencing a deep appreciation for the limitations of intra-oral anchorage, Farrar beautifully describes the use of occipital anchorage to retract upper anterior teeth after attempts to accomplish this intra-orally resulted in an undesirable mesial tipping of the molars.

At about this time, Dodge in 1891 described a method of holding an upper vulcanite bite plate in position by means of head bandages which merits mentioning only because he seems to have been the first to employ rubber tubing as a protective measure against the irritation of the metal parts of an extra-oral apparatus.¹²

In order to improve the means of applying occipital force, Angle² developed a net head cap attached to a non-collapsible wire rim which was connected by means of elastic bands with a traction bar. A metal socket attached to the center of the bar fitted over a projecting knob on the arch wire to form a ball and socket joint. By the use of this device, coupled with intramaxillary force the anterior segment of the dental arch was carried lingually in cases where the first bicuspid were extracted. This appliance can still be purchased.

With the advent of the use of intermaxillary elastics resort to the use of occipital anchorage became less frequent with Angle predicting its complete discard as efficiency and skill in the use of intermaxillary elastics developed.²

In 1908 Case⁹ in his *Dental Orthopedia* discusses "interdependent"

use of occipital and intermaxillary anchorage. Employing a traction bow similar to Angle on either the upper or the lower jaw alone or in combination with intermaxillary elastics, Case aptly illustrates the importance which he places on the auxiliary aid which can be obtained from occipital anchorage.

Figure 7 illustrates his method of exerting a distal pressure on the buccal teeth in a case of blocked out cuspids while at the same time carrying the anterior teeth labially by tightening the nuts in front of the buccal tubes. In Figures 8 and 9 is illustrated his method of applying occipital and intermaxillary force in the correction of Class II, Division 1, and open bite malocclusions. It is with reference to the latter that he felt "the possibility for applying the occipital force directly to the lower teeth in phalanx—as an aid in the correction of open bite malocclusions—would render the occipital force indispensable in the author's practice even if it could not accomplish another object."¹⁰

Notwithstanding the use of occipital anchorage at one time or another recommended by Angle, Kingsley, Case and others in the case of mandibular

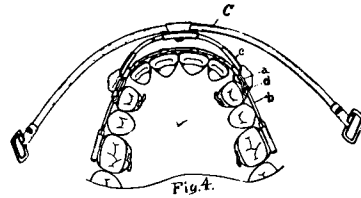


Fig. 7

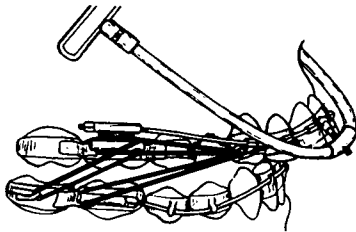


Fig. 8

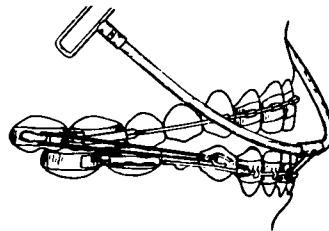


Fig. 9

protrusions, the general feeling concurred in by most authors was that its use was of little practical importance except in extremely young cases. It is occasionally mentioned in the literature as an aid in the retention of these cases.

The introduction of intermaxillary elastics caused a decline in the use of occipital anchorage and it was gradually removed from the armamentarium of the orthodontist by Angle's successive contributions of the ribbon arch, torque force, and the edgewise mechanism with the accompanying enhancement of anchorage possibilities. Irrespective of the improvement in mechanical methods of treatment it was again recognized that intra-oral stationary anchorage was still "a myth" and that in certain cases recourse to an extra-oral resistance unit was imperative.

Among contemporary orthodontists, Strang²⁴ in 1924 revived its use in conjunction with the ribbon arch. In a case of bimaxillary protrusion, he reported the use of occipital force at the suggestion of Dr. Minez. Here it was employed to tip back the buccal teeth after they had been previously employed as anchorage with Class II elastics in a similar distal tipping of the upper buccal segments. Light Class III elastics were worn during the day

to maintain the gain accomplished with occipital traction and at the same time exert as small a reactionary force upon the upper arch as possible.

Thompson,²⁷ reporting for the Eastern Component of the Angle Society, mentions using Class III elastics for distal movement of lower arch segments, relieving the strain on the maxillary denture by discarding the elastics at night and substituting occipital anchorage on the lower arch. He uses the reverse procedure when employing class II elastics for distal movement of maxillary arch segments.

In the philosophy of Class II treatment as outlined by Tweed²⁹ the head gear is again spectacularly revived. Crediting Drs. Milton Fisher and Paul Louis for the first design and use of the head gear for "anchorage preparation," Tweed in tipping back the lower teeth before employing Class II elastics, has recourse to occipital anchorage to support the upper arch at night while wearing heavy Class III elastics with a pull half as great as that of the head cap.

Recent reports include isolated cases and group studies of the construction and application of occipital anchorage in the treatment of malocclusion by Sayers,²¹ Sheldon,²³ Strayer²⁶ and others who use it as an active tooth moving device; an auxiliary support against undesirable effects of Class II and Class III elastics and as a retentive device in Class III treatment indicates that this form of extra-oral anchorage is once more on the ascendancy.

In applying extra-oral anchorage the application of force has been by means of head caps made of leather, metal strips, cloth and netting with attachment to the orthodontic appliance by means of elastics. The object has been to construct a comfortable and durable head gear, permitting accurate control of the amount and direction of force applied to the intra-oral mechanism. It is used to reinforce and overcome the anchorage resistance of dental units. The details of construction of the head cap are largely a matter of personal preference as long as the stability, comfort, control of force, mechanical efficiency and simplicity are maintained.

METHOD

In this investigation the ordinary commercial hair net, which is apparently so easily and universally tolerated and requires a minimum of change for its conversion to the application of occipital anchorage, was employed with slight modification according to the technic of Sheldon.²³ A triangular piece of padded cloth was sewn to the cap just in front of the ear with its apex on a direct line with the corner of the mouth. A large dress hook was sewn to the cloth for the reception of elastics. The application of force from the head cap to either the upper or the lower arch was made by means of a 19 g. round steel wire.

Irritation to the cheek was avoided by covering the wire with latex surgical tubing, $\frac{1}{8}$ inch wide with a $\frac{1}{32}$ inch wall. The covered wire was curved to conform to the outline of the cheek so as to stand three or four millimeters away from it when passive. When elastic force is applied to the cheek wire, there is a tendency for a pressure to be exerted against the cheek as well as the desired distal pull. The degree of medial pressure may be avoided by care in adjusting the wire away from the cheek.

ABSTRACTS OF CASE REPORTS

The following cases illustrate the clinical application of the principles and techniques discussed:

Case 1112

Female, age 8 years, 11 months, Class II—Division 1. Occipital anchorage used as an active tooth moving mechanism.

Mechanics of treatment:

Ribbon arch technique—.022 round arch used for two months to secure molar width in the upper arch allowing the arch to slide distally through the molar tubes and thus retract the anterior teeth.

Figure 10

1. Upper incisors tipped lingually.
2. Upper molar has moved anteriorly.
3. Mandible has moved slightly forward.
4. Superimposed mandibular tracings reveal no change in the incisor or molar position.
5. Occlusal plane tipped down anteriorly and up posteriorly.

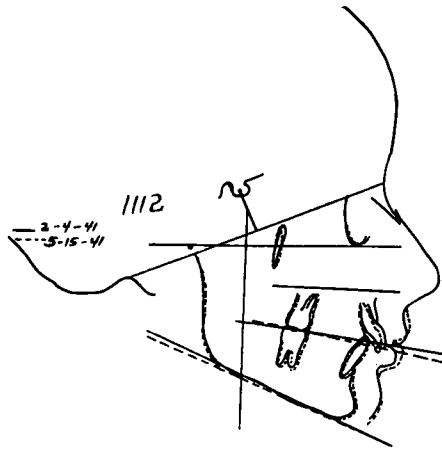


Fig. 10

Occipital anchorage was then employed for a similar length of time to retract the upper incisors.

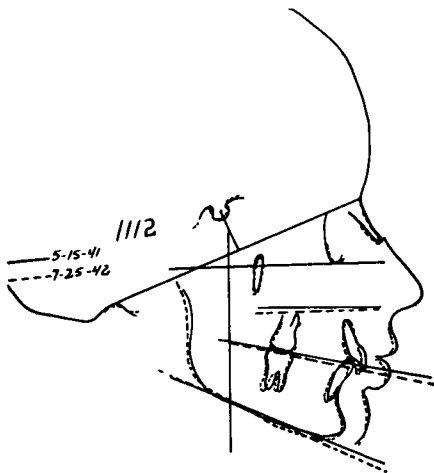


Fig. 11

Figure 11

1. Upper molar has moved occlusally without any change in inclination.
2. Upper incisors have tipped lingually.
3. The occlusal plane has tipped down in front.
4. The mandible has gone downward and backward.
5. Superimposed mandibular tracings reveal no change in the incisor or molar positions.

Up to this time no appliance was used on the lower arch. A lower ribbon arch with lingual torque on the anterior segment was now inserted. At the same time stops were placed in front of the molar sheaths and the headcap used to effect distal movement of the entire maxillary arch. (Patient on vacation, headcap worn for one month.)

Figure 12

1. Distal tipping of incisor.
2. Distal tipping of molar.
3. No apparent change in the occlusal plane.
4. The mandible has gone downward and forward slightly .
5. Superimposed mandibular tracings indicate:
 - (a) lower incisors had tipped distally in response to lingual torque,
 - (b) lower molar had tipped distally.

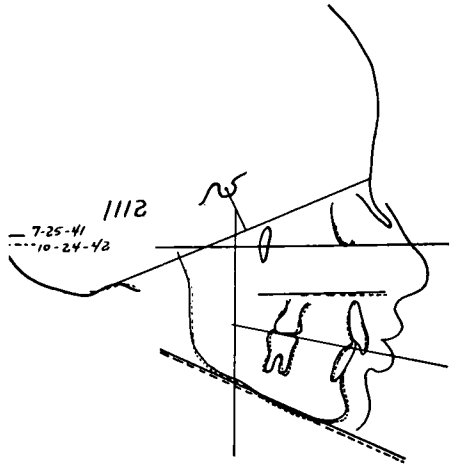


Fig. 12

The head cap was discontinued at this time and Class II elastics were introduced employing the regular ribbon arch technique.

Figure 13

The changes effected in a four month interval:

1. Upper molar has moved occlusally and distally.
2. Upper incisor has moved occlusally and lingually.
3. The occlusal plane has tipped downward anteriorly.
4. The mandible has gone downward and backward.

Superimposed mandibular tracings show:

1. Incisors have tipped labially on their base bone.
2. Lower molar has moved occlusally and mesially increasing its anterior inclination to its base.

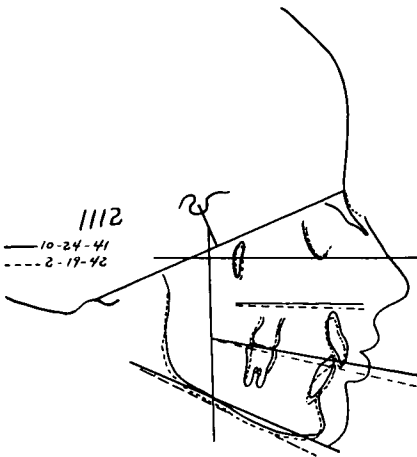


Fig. 13

The moment intermaxillary elastics were introduced changes in the axial inclination of the teeth in the resistance unit became evident not withstanding the incorporation of torque which in the previous composite

view was responsible for distal tipping of the lower incisors and molars. It was felt therefore that increased lingual torque was necessary in the lower anterior region.

Figure 14

Two months later:

1. Further distal tipping of the molar to a normal interdigitation with its opponent.
2. Incisor has moved occlusally without any change in its inclination.
3. The mandible has continued its downward and backward movement.
4. Superimposed mandibular tracings showed the molar has moved occlusally, without any change in axial inclination.

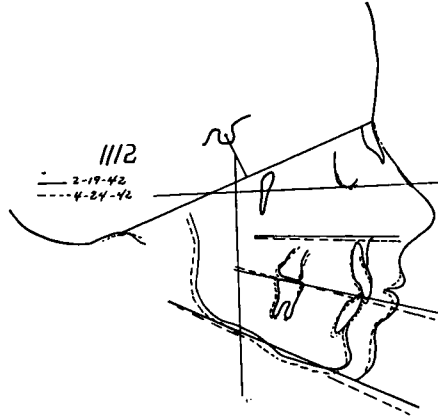


Fig. 14

Case 1107

Male—Age 11 years and 10 months, Class II, Division 1 subdivision. Occipital anchorage used: (a) to tip upper incisors and molars, (b) to support the lower arch.

Mechanics of treatment:

Edgewise bracket bands were placed on the upper anterior teeth and a .022 round gold wire with stops anterior to the molars was inserted. Occipital anchorage was then employed to activate the intra-oral appliance. No lower appliance was worn.

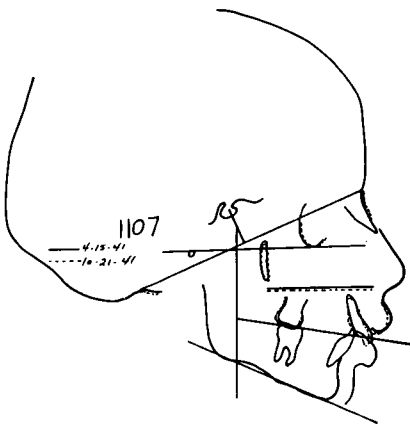


Fig. 15

Figure 15

1. The upper molar has tipped distally.
2. The upper incisors have moved occlusally and tipped lingually.
3. The lower molar and incisor show no evidence of any change.

A full lower edgewise appliance was then placed and Class II elastics worn without any head gear for two and one half months.

Figure 16

1. Upper molars were moved occlusally and tipped distally.
2. The upper incisors have tipped lingually.
3. The mandible has moved forward and downward.

Superimposed mandibular tracings show that:

1. The lower molar has moved mesially and tipped anteriorly on its base.
2. The lower incisor has tipped labially.

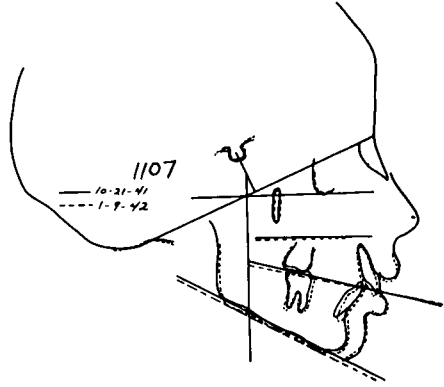


Fig. 16

In other words our lower anchorage was breaking down and so for the next three months we used occipital anchorage to support the lower arch against the reactionary effects of the Class II elastics. At the same time using a rectangular arch with second order bends in the upper for distal movement of the buccal segments.

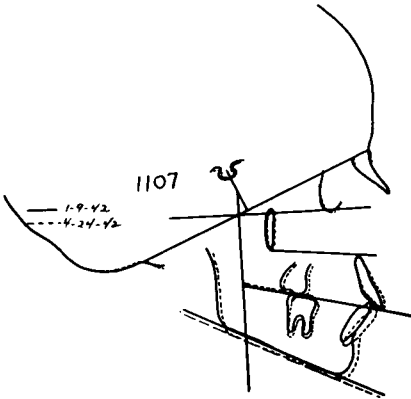


Fig. 17

Figure 17

1. The upper molar has moved mesially.
2. The upper incisor has tipped mesially.
3. The mandible has moved forward and downward.
4. Superimposed mandibular tracings showed that in spite of support afforded by the head cap the lower molar has moved with relation to its bony base and increased its mesial axial inclination.

The cephalometric tracings in the previous two cases of mixed dentition indicate that the use of occipital anchorage to tip the upper molars and incisors distally was effective although in a lesser degree than when intermaxillary elastics were used for a similar period of time. However the use of occipital anchorage to activate the intra-oral appliance of one arch produced negligible changes in the opposing arch. Similar treatment with intermaxillary elastics tended to effect greater changes in the axial inclination and spatial relation of the resistance units.

Case 928

Female, age 17 years and 6 months, Class I case with a tendency toward a bimaxillary protrusion. (Occipital anchorage used to support the upper arch against the reactionary effect of Class III elastics.)

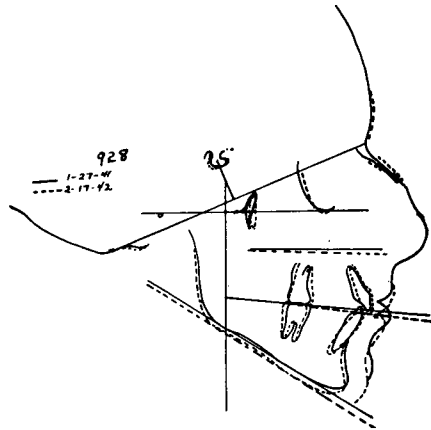
This case was previously treated with round labial arches obtaining arch form and length mainly through expansion. It was retained for two years. A partial collapse with loss of width and excessive mesial inclination of all four buccal segments prompted retreatment.

In the second period of treatment all teeth were banded with edgewise bracket bands and ideal .022 round arches used to obtain width. Tip-back bends were then employed in the lower buccal segments and Class III elastics were used to correct the mesial drift of the lower segments.

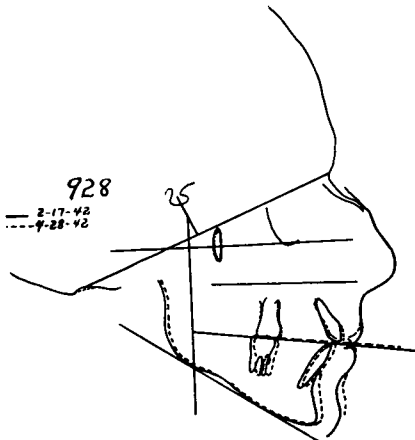
Figure 18

At the end of this period of treatment:

1. Upper molar has moved bodily forward.
2. Upper incisor has moved occlusally and bodily forward.
3. The entire mandible has moved downward and backward.
4. Superimposed mandibular tracings indicate that the lower incisors and molars had been tipped back, but at what expense?

**Fig. 18**

The alarming protrusion occasioned during treatment in a case which originally had a protrusive tendency, prompted us to employ occipital anchorage on the upper arch while wearing heavy Class III elastics and using light Class III intra-oral elastics during the day.

**Fig. 19***Figure 19*

A study and comparison of various tracings in this case together with clinical observation indicate that the mandible was held forward when this X-ray was taken. We must therefore disregard its position in the composite view.

1. The upper molar shows a slight mesial inclination.
2. As does also the upper incisor.
3. Superimposed mandibular tracings showed that the molar and incisor had been tipped distally an amount equal to that shown in the previous composite in a much shorter period of treatment.

This case graphically indicates the necessity for stabilizing the resistance arch against the deleterious effects of intermaxillary elastics. The use of Class III with auxiliary support caused an alarming forward displacement of the maxillary denture. Since the patient was at the end of the growth period it can be assumed that the anterior migration of the upper denture was definitely a function of the effect of the intermaxillary elastics.

The use of occipital anchorage to counteract this force was not entirely satisfactory. However the tracing indicates that the reinforcing action of the head gear made it possible to effect greater changes in the opposing arch utilizing intra-oral elastics than when these were employed with no auxiliary support to the resistance arch.

Case 1055

Female, age 17 years and 6 months, Class I with a mesial drift of the upper arch. This case was originally treated with round labial arches and attachment bands for 17 months. A complete relapse prompted retreatment.

Mechanics of treatment.

The first molars were banded and edgewise bracket bands were placed on the upper four bicuspid. An .022 wire with second order bends was inserted so as not to contact the anterior teeth. Attempt was made to move the buccal segments distally en masse utilizing occipital anchorage to activate the intra-oral mechanism. No appliance was placed on the lower arch.

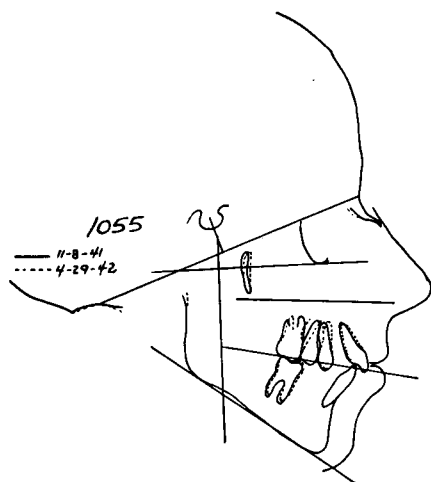


Fig. 20

Figure 20

1. Upper molar roots tipped mesially.
2. Upper incisor moved bodily forward.
3. Upper bicuspid roots moved mesially.

The crowns have remained practically stationary and the roots have migrated mesially. In other words we failed miserably.

This may be the result of a number of factors. The quickest and easiest alibi is that the patient failed to wear the head cap. Assuming that she had we could still obtain the identical unsatisfactory results if the second order bends were too great, or the force of occipital anchorage not great enough.

It is probable that the use of the head cap during a part of the day only did not provide the constant activating force which is so important in the use of second order bends.

COMMENT

In determining the efficacy of any mechanical therapy in the correction of malocclusion it is obvious that growth and developmental changes complicate the situation. When in addition, as in this investigation, a myriad of complex forces inherent in the intra-oral appliance are constantly either enhancing or inhibiting the action of the particular force studied, it becomes painfully apparent that a comprehensive evaluation of occipital anchorage in orthodontic therapy requires a greater number of cases and more accurate control.

The following observations must be considered in the light of the above reservations.

1. There is a place for occipital anchorage as an auxiliary in the treatment of malocclusion.

2. The head cap and its accessories for attachment to the intra-oral appliance can be made comfortable, and its psychological disadvantage overcome by careful patient management.

3. Occipital anchorage can be applied to either the upper or the lower jaw.

4. Occipital anchorage can stimulate tipping tooth movement although in a lesser degree than intermaxillary elastics.

5. Occipital anchorage was found to be less effective than intermaxillary elastics in activating the intra-oral appliance for mass movement of buccal segments.

6. The advantage of occipital anchorage over intermaxillary anchorage lies in the stability of the former as an anchorage unit.

7. A disadvantage of occipital anchorage lies in the difficulty of maintaining a continuous force; since for all practical purposes the head cap can only be worn at night.

8. Occipital anchorage can be used in the following manner: (a) when recourse to intermaxillary anchorage is impossible. (b) when the reaction of intermaxillary anchorage produces undesirable displacement of one anchorage unit. (c) as a reinforcing agent in resisting displacement in intermaxillary anchorage.

9. Any comprehensive evaluation of occipital anchorage must include an appraisalment of: (a) the duration of the force, (b) intensity of the force, (c) the mechanics of the intra-oral and extra-oral orthodontic appliances, (d) the potentialities of the tissues for reaction.

1442 East 55th Street

Bibliography

1. ADAMS, J. W. "Correction of Error in Cephalometric X-rays," *ANGLE ORTHODONT.*, Jan. 1940.
2. ANGLE, EDWARD H. *Treatment of Malocclusion of the Teeth*. Phila. S. S. White Co., 1907.
3. ANGLE, EDWARD H. "The Latest and Best in Orthodontic Mechanism," *Dental Cosmos*, 70:1143-1158, Dec. 1924.

4. BROADBENT, HOLLY. "A New X-ray Technique and its Application to Orthodontia," *ANGLE ORTHODONT.*, 1:45-66, Apr. 1931.
5. BROADBENT, HOLLY. "Bolton Standards and Technique in Orthodontic Practice," *ANGLE ORTHODONT.*, 7:209-233, Oct. 1937.
6. BRODIE, MEYER, *et al.* "Cephalometric Appraisal of Orthodontic Results," *ANGLE ORTHODONT.*, 8:261-330, Oct. 1938.
7. BRODIE, A. G. "Growth Pattern of the Human Head from the Third Month to Eighth Year of Life," *American Jnl. of Anatomy*, Vol. 68, Mar. 1941.
8. BRODIE, A. G. "Some Recent Observations on the Growth of the Mandible," *ANGLE ORTHODONT.*, pp. 63-75, Apr. 1940.
9. CASE, CALVIN. *Dental Orthopedia*. Chicago, C. S. Case Co. 1908.
10. CASE, CALVIN. *Dental Orthopedia*. Chicago, C. S. Case Co. 1921.
11. DOWNS, W. B. "A Study in Dental Arch Length," *ANGLE ORTHODONT.*, p. 78, Apr. 1940.
12. DODGE, HENRY. "Reciprocating Tooth Movement," *Dental Cosmos*, 33:1052, 1891.
13. FARRAR, J. N. "Bridle Apparatus for Correcting Protruding Teeth," *Dental Cosmos*, 28:405-408, 1886.
14. GOLDSTEIN, ABRAHAM. "Further Studies in Class II Treatment," *ANGLE ORTHODONT.*, 10:14-22, Jan. 1940.
15. GUNNEL, J. S. "A Remedy for the Protrusion of the Lower Jaw," *American Jnl. of Dental Science*, p. 65, 1841.
16. KINGSLEY, N. W. "Irregularities of the Teeth," *Dental Cosmos*, pp. 16-100, 1892.
17. KINGSLEY, N. W. *Treatment of Irregularities*. Johnston's Dental Misc., p. 41, 1875.
18. KINGSLEY, N. W. *Oral Deformities*. N. Y. Appleton & Co., 1880.
19. KNEISEL, CHRISTOPHER. *Der Schiefstand der Zahne*, Berlin-Mitter, 1836.
20. POTFESCHNIGG, HEINRICH. "Ein Zahnrichtmaschine," *Deutsche Viertel Jahrschrift Fur Zahn Heilkunde*, p. 34, 1875.
21. SAYERS, C. A. "Case Report," *ANGLE ORTHODONT.*, 10:216-218, Oct. 1940.
22. SEWILL, H. "Irregularities and Diseases of the Teeth," *British Dental Jnl.*, p. 66, 1870.
23. SHELDON, H. M. "A Head Cap for Extra-Oral Anchorage," *ANGLE ORTHODONT.*, 10:219, Oct. 1940.
24. STRANG, R. H. "Pitfalls in Class I Cases of Malocclusion," *Cosmos*, 66:731, July 1924.
25. STRANG, R. H. "Orthodontic Anchorage," *ANGLE ORTHODONT.*, 11:173-186, July 1941.
26. STRAYER, E. R. "Case Report," *ANGLE ORTHODONTIST*, 10:212-215, Oct. 1940.
27. THOMPSON, W. M. "Occipital Anchorage," *ANGLE ORTHODONT.*, 10:206-211, Oct. 1940.
28. TOMES, CHARLES S. "A Case of V-Shaped Contracted Maxilla," *British Jnl. of Dental Science*, p. 200, 1873.
29. TWEED, CHARLES. "Principles of the Edgewise Arch," *ANGLE ORTHODONT.*, 11:5-12, Jan. 1941.
30. WEINBERGER, B. W. *Orthodontics, A Historical Review of Its Origin and Evolution*. St. Louis, C. V. Mosby Co., 1926.
31. WRIGHT, CHESTER F. "The Edgewise Arch Mechanism," Dewey and Anderson, *Practical Orthodontia*. Fifth Rev. Ed. pp. 329-346, 1935.
32. WESTCOTT, AMES. "Operation for Correcting Protrusion of the Under Jaw," *American Jnl. Dental Science*, p. 147, 1844.