

## Stainless Steel Plain Bands versus Clamp Bands for Molar Teeth\*

SHELDON FRIEL, B.A., M. Dent. Sc., Sc. D.

*Dublin, Ireland*

Two contrary views have been held as to the best method of banding molar teeth as a means for the attachment of an orthodontic appliance. It has been taught that it is not possible to make a plain band for a molar that will fit along the cervical margin and that only an adjustable band that is properly shaped and subsequently screwed tight on the tooth, could fit.

A good deal of the misconception that has been held is due to a lack of appreciation of the actual form of the molars, and when the form is understood it becomes evident that it is possible to make a plain band that does actually fit, except in some exceptional shapes of teeth. It is likely that the clamp band fits equally badly in these latter cases.

If it is possible to make satisfactory plain bands they undoubtedly have decided advantages over clamp bands. The whole surface is free for the attachment of any tube or other fitting, whereas one is frequently handicapped by the nut and screw of the clamp band. Again the plain band not only protects the tooth more efficiently, but is more easily kept clean.

It is proposed to describe the forms of the maxillary and mandibular first permanent molars and to show the area which it is possible to band and yet have the cervical margin fit. The technique for the construction of stainless steel bands will be described, the joints being welded together by electric welding. Fig. 1.

There are other techniques for the construction of plain bands that, probably, are just as good. However, the technique described is simple, efficient and cheap.

In describing the surfaces to be banded, the buccal and lingual surfaces will be considered together and then the medial and distal surfaces together. Fig. 2a. The buccal surface slopes upward and outward from the coronal margin to within a short distance from the enamel-cementum junction, relative to the long axis of the tooth; then it slopes upward and inward, forming the neck of the tooth. The lingual surface, viewed from the same aspect of the tooth slopes upward and outward (again relative to long axis of tooth), also to within a slightly longer distance from the enamel-cementum junction, though at a more pronounced angle; it then slopes upward and inward to form the neck on the lingual surface. The lingual surface is

\*An original contribution.




Figure 1

Welder supplied by the British Insulated Cables, Ltd.; pedal closes electrodes and operates trip switch.

not as regular in its outline as the buccal surface owing to the difference in the size or even absence of the supplemental, mediolingual cusp. Where this cusp is very pronounced, the area over the cusp can be perpendicular up to within a short distance of the enamel-cementum junction. The gum margin, even up to the time of adult life, comes so low down as to cover

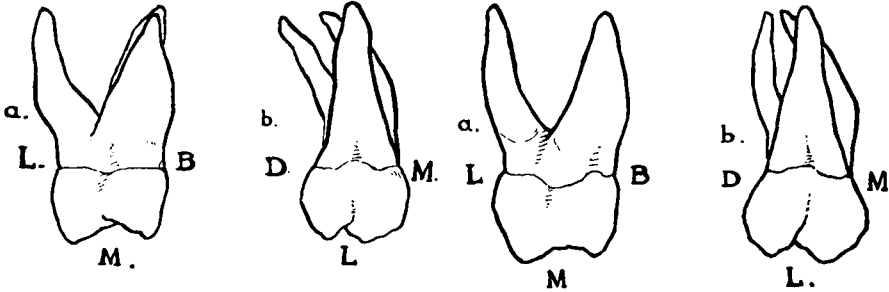


Figure 2

Drawing of two upper left first permanent molars; (a) viewed from medial sides, (b) viewed from lingual aspect.

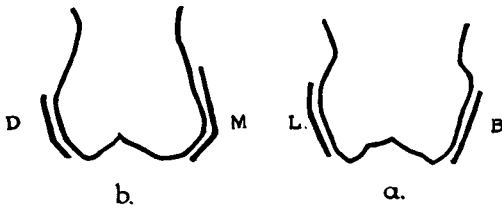


Figure 3

Diagrammatic drawing of maxillary left, first permanent molar with outline of plain band; (a) viewed from the medial aspect, (b) viewed from the buccal or lingual aspect.

the enamel where it slopes in towards the central axis of the tooth. From this description it will be seen that it is possible for a band to fit the buccal and lingual surfaces as far as the inward slope toward the central axis of the tooth.

The medial and distal surfaces, Fig. 2b, present quite a different appearance and from the description it will be seen that it is not possible for the band to fit on both of these surfaces as high up as on the buccal and lingual surfaces. The medial surface, as viewed from the buccal or lingual aspect slopes from the medial-marginal ridge, upward and outward to about a quarter of the length of the medial surface of the crown. Then there is a short perpendicular area. Gingivally to this, the medial surface

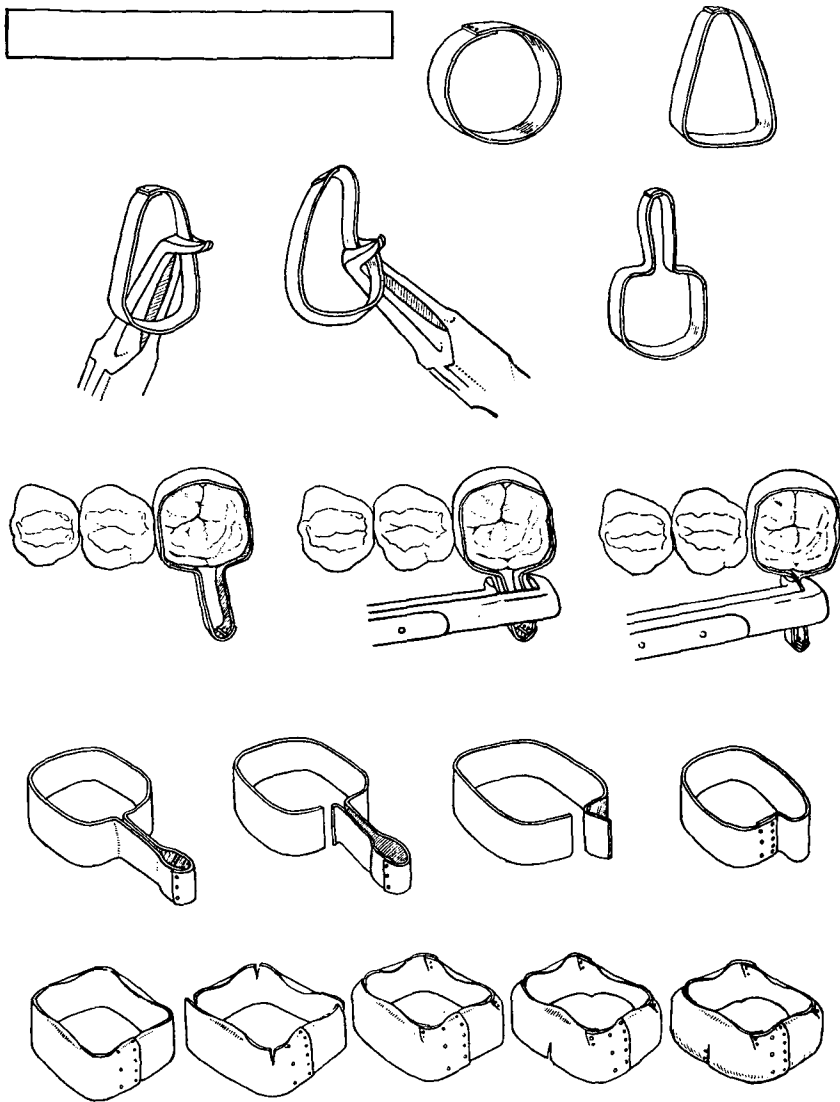


Figure 4  
 Stages of maxillary molar band construction.

slopes upward and inward. On the distal side, the coronal half slopes upward and outward to a little beyond the middle of the distal surface. This slope is parallel to the *cervical* upward and inward slope of the medial surface. The distal surface then slopes upward and inward, the latter slope being parallel to the *coronal* upward and outward slope of the medial surface. Thus, each of these two surfaces presents a coronal slope that

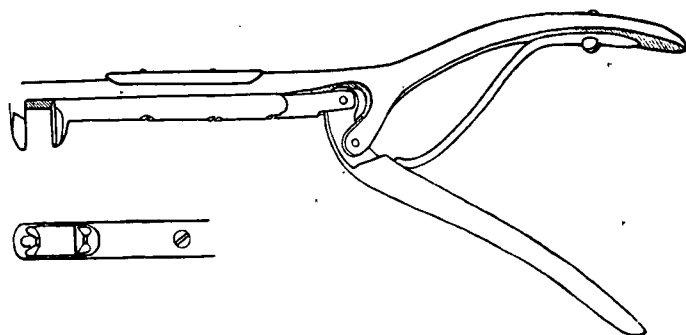


Figure 5  
Band-forming pliers, blades working at right angles to shaft.

is parallel to a cervical slope. It is obvious that a plain band can only fit three slopes at the one time and it is found, in practice, that the whole of the medial surface and somewhat less than two-thirds of the distal surface are the parts that are most conveniently banded. Fig. 3.

The forms of teeth that are difficult to band are those whose cervical half of the medial surface has a very marked inclination. It is not always possible to recognize these teeth in the mouth.

#### The Construction of a Maxillary Molar Band

The ends of a piece of stainless steel band material, 6 cm. long, 5 mm. wide and .15 mm. thick, (2.5 inches long, .196 inches wide and .0058 inches thick) brightly polished on one side only, are over-lapped and welded. Fig. 4. The loop is now shaped so that the part farthest from the joint is made to approximately fit the buccal surface of the tooth. The material is held in a pair of Pullen's band-forming pliers, about 8 or 9 mm. from the distobuccal angle of the band, and is given double-reverse, right-angled bends, thus forming the disto-lingual angle.

The material is now turned over and again held in Pullen's pliers, about 8 or 9 mm. from the medio-buccal angle, and similar double-reverse, right angled bends made. The material is now in the form of a ring with

two tails, like a pull-to joint. This ring is placed on the tooth and worked up to the required position. Should any discomfort be felt it is squeezed

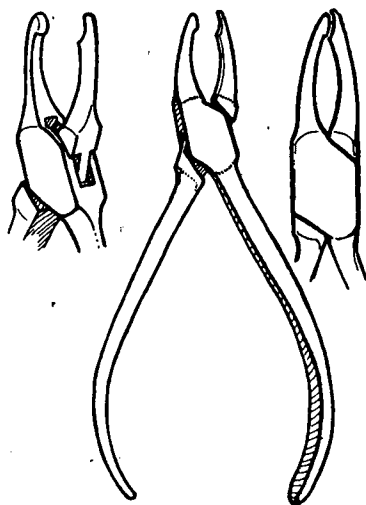


Figure 6

Pliers designed by Miss K. C. Smyth, London, for flattening projecting corners, where the band has been cut, overlapped and welded.

with a special band forming pliers, Fig. 5, the blades of which work at right angles to the shaft. This preliminary squeezing of the band makes it fit more accurately and there will be no discomfort in now working the ring onto the tooth to its full extent. The ring is again squeezed in its final position. The ring is removed. One tail is cut slightly ringwards of the crease made by the pliers, leaving the crease on the tail. The other tail is cut off about 3 mm. tailwards from the crease. The side cut close to the crease is lapped over the 3 mm. projection to the crease and welded. This cutting of the ring a little short of the crease makes the fit a little tighter. The squeezing of the ring onto the tooth shapes it, to a large extent, to the form of the tooth. The band is now placed on the tooth and, with the help of the patient by biting on a wooden tongue depressor, and also, by the use of Pullen's band adapter and a round orange wood stick, it is driven to the required position. If it has been made too tight, it can be enlarged with Mershon contouring pliers at the point where it is bearing, usually the distal, cervical surface, though at times it may be the medio-lingual surface. When pushed up to the proper position, the centre of each of the four coronal margins is burnished in with a burnisher. The ring is removed and the four coronal

corners are cut vertically with scissors to a depth of about 1 mm. With S. S. White's pliers, No. 118, the coronal edge is contoured inward, starting from the centre of each side and working towards the cut corners. The cut corners are overlapped and welded. A vertical cut, about 1.5 mm. long, is made with scissors at the centre of the medio-cervical margin. The disto-cervical

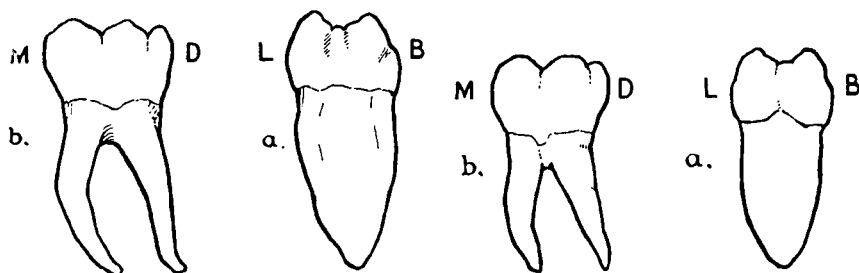


Figure 7

Drawings of two mandibular left, first permanent molars; (a) viewed from medial aspect, (b) viewed from buccal aspect.

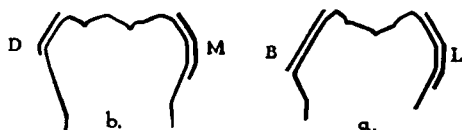


Figure 8

Diagrammatic drawing of mandibular right, first permanent molar, with outline of plain band; (a) viewed from medial aspect, (b) viewed from buccal aspect.

margin is then festooned. With S. S. White pliers, No. 118, the cervical edge is bent inward, starting at the centre of the buccal and lingual sides and working to the cut on the medial side and along the festooned distal side. The well over-lapped cut on the medial side is welded. The projecting corners, where the band has been cut, overlapped and welded, should be flattened with contouring pliers. Those designed by Miss K. C. Smyth, Fig. 6, are suitable. The band is again put on the tooth and gradually worked up to the required position. Some little difficulty may be found in starting the band on the tooth as it has been somewhat distorted by the contouring pliers, but it will be found that it will go on. The coronal edge should be burnished all round and any excess of overlap along the distal marginal ridge should be filed or stoned away.

### The Mandibular First Permanent Molar

The mandibular first permanent molar presents quite a different form from that of the corresponding maxillary tooth. Fig. 7a. As viewed from the medial aspect, the buccal surface is sharply inclined downward and outward, relative to the long axis, from the coronal margin to about 2 mm. above the enamel-cementum junction. Below this point it takes a reverse inclination. On the lingual surface the coronal part is similarly inclined to about 4 mm. above the enamel-cementum junction. Below this the surface is flat for about 1 to 2 mm. and then is inclined downward and inward. This latter inclination is nearly parallel to the main inclination of the buccal surface. Viewed from the buccal side, Fig. 7b, the medial surface is parallel or slightly inclined downward and outward to the long axis of the tooth to about midway between the coronal and cervical margins. Below this it is flat for a short area and then inclined downward and inward. The distal surface is more sharply inclined downward and outward for about one-third

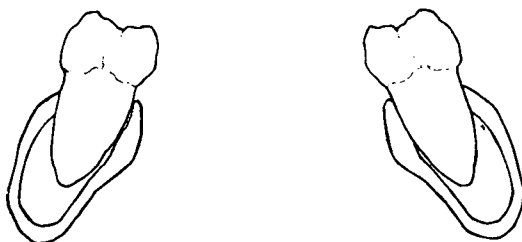


Figure 9

Drawing of section through the mandible and the first permanent molars. About 8 years of age. Showing lingual inclination of molars.

of the distance between the coronal marginal ridge and the cervical margin and this slope is nearly parallel to the rootward inclination of the medial surface. It is then inclined downward and inward. Diagrammatically, the tooth presents the following shape. Fig. 8. The main buccal slope is parallel to the gingival third of the lingual surface. The coronal third of the distal surface is parallel to the gingival third of the medial surface. Here, again, the buccal, lingual, medial and the coronal third of the distal surface can be banded, keeping the cervical edge of the band close to the tooth.

It must be pointed out that the long axis of the mandibular molar, in the mouth, is inclined lingually and consequently the exposed lingual surface



looks perpendicular and the buccal surface looks greatly inclined downward and outward. Fig. 9.

### The Construction of a Mandibular Molar Band

The procedure in making the mandibular bands is slightly different

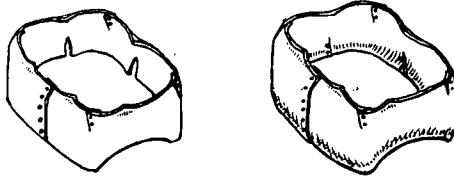


Figure 10  
Final stages of the mandibular band construction.

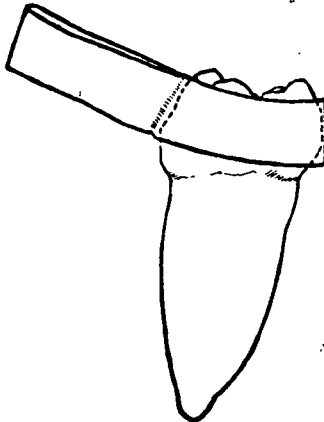


Figure 11

Diagrammatic drawing of mandibular right, first permanent molar from medial aspect, with outline of band material squeezed together on buccal surface. Showing gaps between the band material and the tooth below and above the flat area of the lingual surface.

from the maxillary band technique. The ring is squeezed on the buccal side instead of the lingual side, as in the case of the maxillary bands. After it has been fitted into place, after welding, it is removed and the coronal edge treated in the same way as that of the maxillary molar bands. The band is well festooned on the distal cervical margin. A vertical cut, about 2 mm. long, is made from the cervical margin, about the centre of the lingual surface. A similar cut, not so long, is made from the cervical margin, about the centre of the medial surface. The cervical margin is contoured inward with S. S. White Pliers, No. 118, and the cuts well overlapped, especially the lingual cut, and welded. Fig. 10.

It must be remembered that the original squeezing of the band material around the tooth does not make the band conform fully to the shape of the lingual and medial surfaces. It will be found that there is a gap between the tooth and the band, below and above the flat middle area. Fig. 11. The cut-

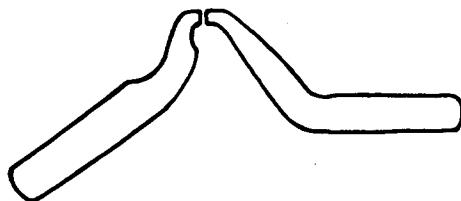


Figure 12  
Drawing of electrodes for welding band material.

ting and overlapping of the coronal corners and the cutting and overlapping on the cervical lingual and medial surfaces makes it possible for the band to fit, closely, the whole lingual and medial surfaces.

It is important that the shape of the electrodes of the electric welder be such as to fit into the different areas to be welded, without distorting the bands. Fig. 12. A small speed or volume of current should be used so as not to burn the metal and the switch must be made to operate as quickly as possible.

The stainless steel band material is comparatively soft, as supplied by the manufacturers, but the manipulation of the bands during their fitting considerably hardens the material, so that one finishes with quite a stiff, springy band.

The illustrations were used by me in a paper read before the British Society for the Study of Orthodontics in 1933.

3 Fitzwilliam Place.