

Change in Lip Contour with Maxillary Incisor Retraction

BENJAMIN H. WALDMAN

Dr. Waldman is in the private practice of dentistry in Avon, Connecticut. He is a dental graduate (D.D.S.) of the University of Maryland. This study was done as a resident in the department of Dentistry, Oral and Maxillo-facial Surgery at Mount Sinai Hospital in Hartford, CT.

Evaluation of upper lip retraction with retraction of the incisor edge in 41 Class II cases showed an average ratio of 1:3.8. Increase in the nasolabial angle was found to be associated with change in incisor angle and with palatal tilt, but there was no consistent relationship with horizontal movement of the incisor edge.

A major motivation for seeking orthodontic treatment is a desire to improve dental and facial esthetics. While the practitioner's concern for occlusal relationships may result in varying effects on facial contour, we cannot move teeth on an occlusal basis alone. One objective of the orthodontist should be to create or maintain the maximum esthetic harmony consistent with a functional occlusion.

In planning correction for a patient with a convex profile, the clinician must consider the soft tissue changes that may occur with correction of the antero-posterior position of the maxillary incisors. The problem is well summarized by Jacobs¹ who notes that mechanotherapy directed solely toward obtaining a functional occlusion may compromise facial esthetics in some patients.

The mechanics of treatment should be individually designed for each patient, rather than follow a simplified

Address:

Dr. Benjamin H. Waldman
47 Avonwood Road
Avon, CT 06001

"recipe" designed to correct a particular broad classification of dentoskeletal disharmony.

Angle noted that "though artists have always sought lines and rules for facial measurements which could be used to detect variations from the normal, there is no standard that would have universal application."³ Nevertheless, the measurement of soft tissue and dentoskeletal landmarks can be very useful in treatment planning.

O'Reilly³ noted in 1957 that profiles are often altered through mechanotherapy, but predictability is poor.

Subtelny⁴ studied thirty patients from Bolton's studies and described the interrelationship of effects of the nose, chin, lips, and teeth on the facial profile. He noted that soft tissue changes resulting from mechanotherapy are not always expected or desired.

In 1960, Robinson studied edentulous patients with different incisor positions. He stated that "as the maxillary central incisors move forward, the upper lip also moves forward, but though trends are evident in the group as a whole, individuals can show considerable variation."⁵

Rudee⁶ measured linear changes in incisor position and soft tissue (upper lip protrusion) as a perpendicular measurement from the facial plane. His study suggested a 1:2 (mode), or 1:3 (mean) ratio of upper lip retraction to maxillary incisor retraction.

Garner⁸ found a ratio of 1:2 in black females, noting that the ratio is closer to 1:3.6 in black males.

Harris⁷ found a ratio of upper lip to incisor retraction of 2:3 with maxillary osteotomy. This larger response is very possibly due to the retraction of skeletal and other structures not retracted with orthodontic tooth movement alone.

Hershey stated that "Investigators have been unable to isolate the effects of treatment on profile change because of the superimposed growth of the structure under investigation."⁹ He studied incisor retraction in 36 adult females and still found an unpredictable effect on the lip. His studies also suggested that lip morphology (incompetent vs. redundant) has little effect on the soft tissue response to dental movement.

Burstone¹⁰ feels that lip protrusion in Class II, division 1 malocclusion is the result of the combined effects of axial inclination of upper incisors, the adaptation of the upper lip to the incisor, and the thickness of soft tissue.

Respiratory pattern (nasal vs. mouth breathing) and other influences on lip posture are other factors.

One popular measurement of protrusion relative to the inferior border of the nose is the nasolabial angle. This is the angle formed by the intersection of a line tangent to the mean lower border of the nose and a line from subnasale to labiale superius. It averages 112° in patients with normal profiles.

Class II, Division 1 cases with obtuse nasolabial angles before treatment are likely to finish with a "dished in" look if particular care is not taken during treatment to avoid excessive retraction of the anterior teeth.

The purpose of this study is to document postural changes that have occurred in the upper lip with retraction of maxillary incisors in Class II, Division 1 malocclusions.

Factors to be considered are:

1. Treatment modality (mechanics)
 - a. Intra- or interarch traction
 - b. Extractions
 - c. Tipping or translation of teeth

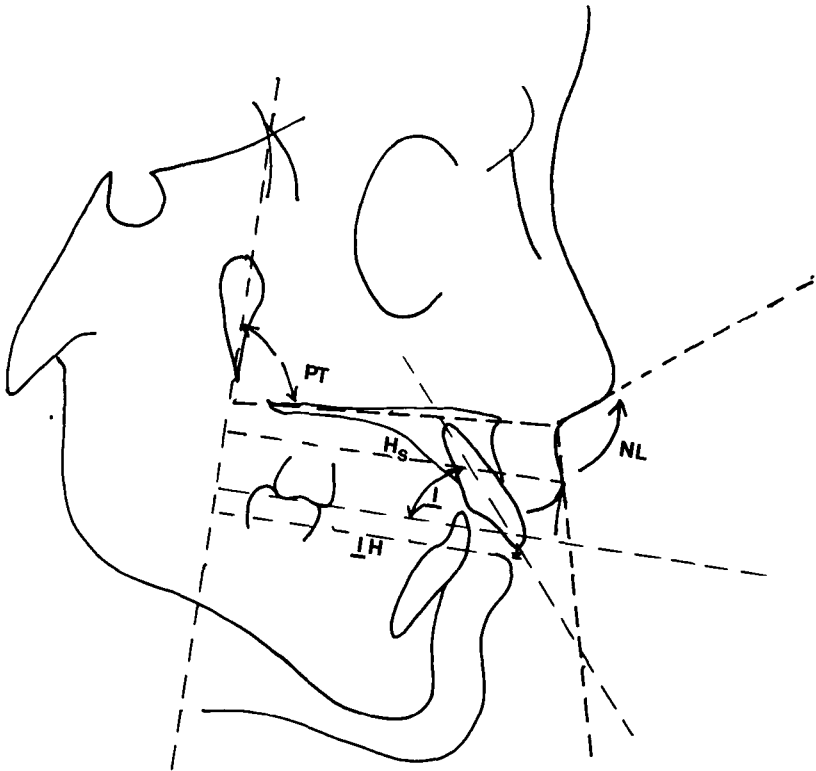


Fig. 1 Measurements used in this study. PT = Palatal tilt angle. NL = Nasolabial angle. *I* = Upper incisor angle. *I*H = Horizontal upper incisor position. Hs = Horizontal soft tissue position.

2. Soft tissue factors
 - a. Initial nasolabial angle
 - b. Facial profile
 - c. Tissue thickness
 - d. Lower facial height
3. Dentoskeletal factors
 - a. Palatal tilt
 - b. Axial inclination of teeth

METHODS AND MATERIALS

Anatomical structures were measured on lateral cephalometric radio-

graphs exposed before and after treatment. The analysis was planned to minimize the effects of growth, using some principles described by Enlow.¹¹ The reference line, PM, is a vertical line marking the posterior margin of the maxilla. It is defined above by a point at the intersection of the greater wings of the sphenoid with the floor of the anterior cranial fossa, and below by the inferior point of the pterygomaxillary fissure (Fig. 1).

Lip and tooth retraction were measured linearly parallel to the neutral occlusal line, which is constructed perpendicular to PM through the mean occlusal contacts of the first molars. Axial inclination of the incisors was also measured from this line.

Measurements considered are: (1) change in horizontal position of the maxillary incisor edge, (2) linear horizontal change of labiale superiorus, (3) change in nasolabial angle, (4) change in axial inclination of the maxillary incisor, and (5) palatal tilt.

It was especially interesting to note differences between the initial profiles of patients exhibiting increased nasolabial angles following treatment and those whose nasolabial angles were more acute after treatment.

RESULTS

Some of the changes with treatment are summarized in Table 1. The mean nasolabial angle in the sample was 113 degrees, indicating a typical population.

There was no significant correlation between horizontal movement of the edge of the maxillary incisor along the neutral occlusal axis and change in the nasolabial angle. Thus we can make no prediction of the change in the angulation of the upper lip to the nose on the basis of horizontal retraction of the incisor edge.

On the other hand, there was a significant correlation between the horizontal retraction of the incisor and the soft tissue at labiale superiorus. In the forty-one cases reported, the average retraction of the lip was 1.0 mm, with an average incisor retraction in the horizontal plane of 3.8 mm, for a ratio of 1:3.8. In this study, dental retraction had less effect

on soft tissue profile than previously reported by Rudee,⁶ Harris,⁷ and Garner.⁸

No correlation was found between horizontal change in the lip at labiale superiorus and nasolabial angle. There was a significant correlation ($R = .42$) between the change in angulation of the maxillary incisor and the nasolabial angle.

A positive relationship was also found between the angulation of the palate to PM (vertical maxilla), and the nasolabial angle. A more obtuse nasolabial angle can be expected with a steeper angulation of the palate, although the standard deviation was 5.9 degrees. This angle may also be related to anterior facial height.

Although the sample was not large enough for a statistical assessment of the relation between lip thickness and soft tissue profile changes, there appeared to be little relationship.

DISCUSSION

The results of this study indicate that it may be possible to anticipate changes in the soft tissue profile as a result of retraction of the anterior teeth.

If a large initial angle of palatal tilt is observed, or a large increase in the angulation of the upper incisors (lingual tipping) is expected, an increase in the nasolabial angle can be expected.

However, the presence of a large palatal tilt angle or expectation of incisor tipping should serve as a warning that an increased nasolabial angle or "orthodontic look" may result. Conversely, a patient for whom an increase in nasolabial angle would be desirable might benefit from lingual tipping of the upper incisors.

TABLE 1
Selected Measurements

<i>Patient</i>	<i>Sex</i>	<i>Age at Start</i>	<i>Overbite %</i>	<i>Overjet mm</i>	<i>Elastics</i>	<i>IH Change, mm</i>	<i>Hs Change</i>	<i>Nasolabial Angle Change</i>	<i>Incisor Angle Change</i>	<i>PT Angle</i>
1	F	12 ₁₁	100	10	II	6	4	-3°	6	83°
2	F	11 ₄	100	10	II	4	3	10°	14	76°
3	F	13 ₅	100	6	II	4	4	-11°	0	78°
4	F	11 ₁	50	9		2	0	-5°	10	73°
5	F	12 ₈	50	7		3	2	37°	11	104°
6	M	14 ₅	30	9	II	6	3	-3°	9	81°
7	F	12 ₇	Open	10	II	8	5	29°	15	85°
8	M	13 ₅	90	12		13	2	22°	29	78°
9	M	11 ₁	Open	8		7	1	-12°	4	79°
10	F	8 ₅	100	8	II	5	2	22°	9	80°
11	F	12 ₄	40	8		6	4	19°	20	77°
12	F	12 ₈	20	7		7	3	11°	7	77°
13	M	12 ₁₁	100	9	II	3	-5	-14°	10	84°
14	F	12 ₇	100	8	II	10	0	-4°	27	77°
15	F	11 ₁₀	80	5	II	3	4	-24°	2	75°
16	F	13 ₁₁	10	3		5	5	10°	14	85°
17	F	12 ₅	60	5		1	-4	-4°	-5	74°
18	M	10 ₅	100	9		10	8	15°	17	74°
19	M	12 ₁₁	80	5		-4	-5	-6°	-5	71°
20	M	16 ₇	50	4		-2	4	15°	5	73°
21	F	13 ₁₁	80	7		6	11	-18°	14	74°
22	F					1	-3	12°	-12	72°
23	F				II	8	2	6°	16	82°
24	M	14 ₅	100	8	II	7	2	5°	22	84°
25	F	13 ₅	50	3		-2	-1	9°	4	79°
26	M	10 ₅	50	7		-3	-7	-8°	5	75°
27	F				II	1	-4	2°	-2	82°
28	F	29 ₅			II	3	-1	-13°	10	67°
29	M	10 ₁				4	4	11°	1	77°
30	F	13 ₅	50	5		4	4	11°	5	77°
31	M	12 ₁₁	70	7	II	4	-1	35°	18	85°
32	F	11 ₄				1	-4	-22°	-8	79°
33	F	10 ₅	60	7		6	2	10°	3	71°
34	F	14 ₇	70	9	II	4	3	-6°	20	79°
35	F	12 ₅			II	3	-4	6°	-6	77°
36	F	12 ₇	100	4	II	2	4	7°	-2	84°
37	F		30	4		-4	-7	10°	-8	76°
38	F	10 ₇	7	80		9	0	-19°	16	80°
39	F	10 ₈	8	90	II	5	3	-5°	11	75°
40	F	9 ₅	8	50		5	7	45°	6	81°
41	F	13 ₁			II	2	3	12°	10	78°

The fact that no significant correlations were found between horizontal retraction of incisor or soft tissue and the nasolabial angle indicates that other forces must also be at play in the hard and soft tissue systems. These factors include orthopedic forces and growth, soft tissue consistency, musculature, and other variables that affect the physical form of the face.

With our present state of knowledge, we must regard the probable effects of this fusion of properties intuitively in treating orthodontic problems. We recognize their presence and maintain a close watch on the patient in order to circumvent their unfavorable influences and augment the desirable ones as needs arise.

SUMMARY AND CONCLUSIONS

Cephalometric analysis of the influence of hard tissue changes on lip contour in 41 cases showed the following effects.

Patients with large palatal tilt angles showed larger changes in the nasolabial angle with incisor retraction.

Nasolabial angle is increased with uprighting (lingual tipping) of the incisors.

Horizontal movement of the incisor edge has an unpredictable relationship with change in the nasolabial angle.

A ratio of 1:3.8 was found between lip retraction and incisor retraction.

REFERENCES

1. Jacob, J.: Vertical Lip Changes from Maxillary Incisor Retraction, *Am. J.* 201-212, 1980.
 2. O'Reilly, W. C. Proportional Changes of Hard and Soft Tissue Profiles as a Result of Orthodontic Treatment, M.S. Thesis, University of Washington, 1957.
 3. Subtelny, J. D.: A longitudinal study of soft tissue facial structures and their profile characteristics defined in relation to underlying skeletal structure, *Am. J. Orthod.* 45:481, 1959.
 4. Robinson, R.: Changes in lip position in coincidence with movement of artificial teeth, Thesis, Indiana University School of Dentistry, 1960.
 5. Rudee, D. A.: Proportional profile change concurrent with Orthodontic Therapy, *Am. J. Orthod.* 50:421-433, 1964.
 6. Harris, M. E.: Cephalometric prediction of soft tissue profile following anterior maxillary osteotomy. M.S. Thesis, University of Kentucky College of Dentistry, Department of Orthodontics, 1974.
 7. Garner, L. D.: Soft-Tissue Changes Concurrent with Orthodontic Tooth Movement, *Am. J. Orthod.* 66:367-371, 1974.
 8. Hershey, H. G.: Incisor tooth retraction and subsequent profile change in post-adolescent female patients, *Am. J. Orthod.* 61:45, 1972.
 9. Burstone, C. J.: Lip posture and its significance in treatment planning, *Am. J. Orthod.* 53:273, 1967.
 10. Enlow, D.: Basis for craniofacial form and function, *J. Am. Dent. Assn.* 41:165, 1971.
-