

The Development of Septal and Dental Deformity from Birth

LINDSAY P. GRAY, PETER I. DILLON, WILLIAM F. BROGAN
AND PATRICK J. HENRY

Lindsay P. Gray, M.B., B.S., D.L.O., F.R.A.C.S. is Consultant Emeritus Otolaryngologist to the King Edward Memorial Hospital for Women and Princess Margaret Hospital for Children.

Peter Dillon, M.D.Sc.(W.A.), D.D.-P.H., R.C.S.(Eng.) is Visiting Orthodontist, Princess Margaret Hospital for Children.

William Brogan, D.D.O., R.F.P.S., F.R.A.C.D.S. is Consultant Orthodontist, Princess Margaret Hospital for Children.

Patrick Henry, B.D.Sc.(W.A.), M.S.D. (Indiana), F.R.A.C.D.S. is Consultant Prosthodontist, Princess Margaret Hospital for Children.

The growth of the nasal septum, maxilla, mandible and dental alignment was followed in 145 subjects from birth to about the age of 6 years. A clear relationship was found between septal deformity at birth and later deformity of the maxilla and dental malocclusion.

The variations in incidence of septal and maxillary deformities and mandibular alignment with different fetal presentations and difficulties at birth have been well documented. At birth the maxilla is soft, malleable and easily deformed, as can be readily demonstrated by the change in shape of the palate with manipulation (L. Gray 1974, 1978, 1980).

Figure 1 shows the even shape of the palate at birth that is usually associated with a straight septum (type A). Figure 2 shows the uneven palatal outline usually associated with a unilateral septal deformity (type B).

It also shows the change accomplished by manipulation, which has not only improved the outline of the palate but also straightened the septal deformity. The manipulation was performed by passing special infant septal forceps into the nose, pressing down on the palate and then straightening the septum.

Address:

Dr. Lindsay P. Gray
57 Labouchere Rd.
South Perth, W.A. 6151
AUSTRALIA

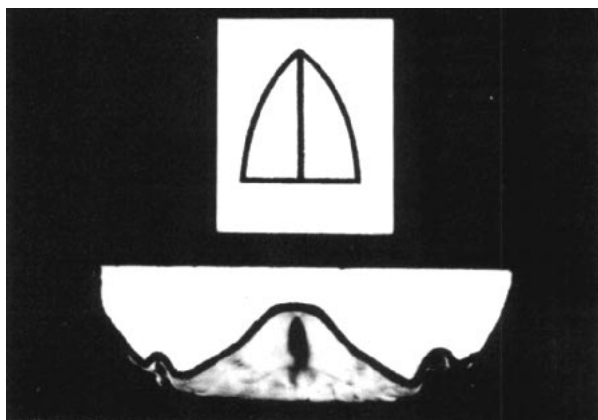


Fig. 1 Plaster cast of the maxilla of a 3-day-old baby, demonstrating the even shape of the palate usually associated with a straight septum (type A).

Previous work (L. Gray and Brogan 1970, 1972) reported the close association between dental malocclusion and septal deformity. The septal deviation can be predicted by examining the occlusion, and the dental occlusion by examining the nose.

This paper reports the results on a series of subjects examined at birth and then reviewed between 3 and 6 years of age with the primary dentition present. The objectives were to investigate:

- 1) The growth of the nasal septum.
- 2) The association of septal configuration with the growth of the face and development of the dentition.
- 3) The association of the incidence of upper respiratory tract infection and allergy with the septal configuration, which will be reported in a later paper.

It is intended to examine these same subjects again at 8 or 9 years of age.

MATERIAL AND METHOD

Over 400 subjects had been assessed and documented at birth. Those studied were a random selection of those available from that total list. Many could not be found due to transfer to other parts of the large state of Western Australia.

All were visited personally (by L.P.G.), and the ears, nose and throat examined. A dental examination at the Dental Clinic of the Princess Margaret Hospital included plaster casts of the maxillary and mandibular arches and facial photographs.

Dental records were made on 145 individuals, but 4 were not included in the dental assessment. Nine subjects from a previous investigation did not have adequate medical histories. Photographs were available on 114. The dental casts, photos, medical examination and history were all assessed separately and then finally correlated with the findings on septal configuration.

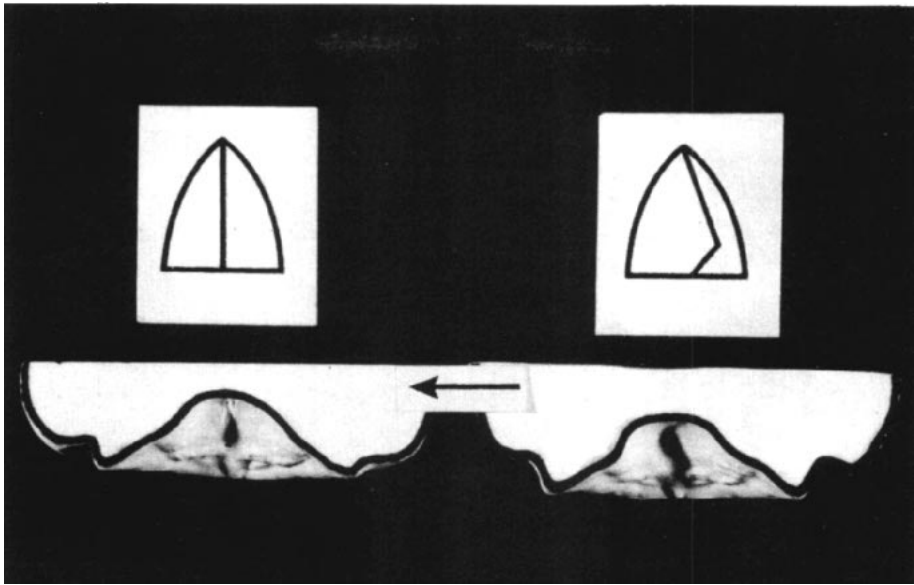


Fig. 2 The plaster cast of the maxilla of a 3-day-old baby on the left demonstrates the uneven outline which is usually associated with unilateral septal deformity (type B). The cast on the right is of the same palate immediately after manipulation, showing the improvement of the contour of the palate following straightening of the septum.

Based on previous work by L. Gray (1974, 1978 and 1980), the noses were classified into three types as found by inspection of the nose or by the passage of nasal testing struts.

- type A: Straight septum—42% at birth
- type B: Septum deformed to one side only (kinked)—31% at birth
- type C: Septum deformed to both sides (deviated)—27% at birth

THE GROWTH OF THE SEPTUM

At birth the septa of these children were assessed by the passage of nasal testing struts 6 mm wide by 2 mm thick (L. Gray 1974, 1978). This coarse method of testing is most useful for identifying the more severe abnormalities.

These patients were reassessed at 3 to 6 years of age by anterior rhinoscopy using a strong fine-angled light passed

into the anterior nares with the tip of the nose held up. More than half of those categorized as type A at birth showed no change later (Fig. 3); the remainder had minor septal deformities of types B or C. Those initially classified as type B or C showed minimal changes toward the other category, but *none* had changed to type A.

Thirty-three severe deformities causing symptoms at birth such as snuffing or poor feeding (L. Gray 1974, 1980) were treated with corrective manipulation. Of those, three (9%) became type A and the remainder had only minor deformities. Manipulation usually improves the shape of the palate as well as improving the septal deformity (Fig. 2).

This investigation clearly shows that septal deformity found at birth *will NOT disappear with growth.*

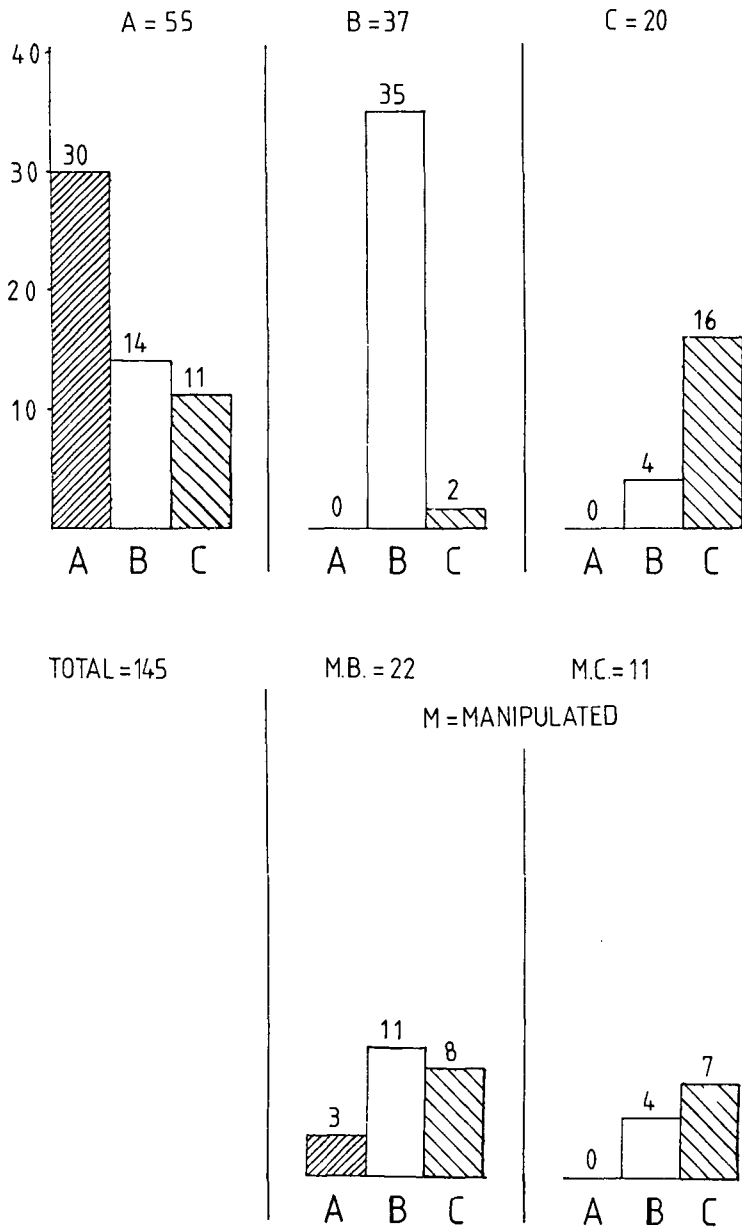


Fig. 3 Change of septal configuration with growth. Graphs show category at 3-6 years of age for children in each of the three categories at birth. The two lower graphs show category B and C septa that were manipulated at the time of birth to improve the septal configuration. This distribution clearly shows that deformed septa do not improve significantly with growth.

The Association of Septal Configuration with the Growth of the Face and Development of the Dentition

The development of the maxilla, palate, mandible and septum can be influenced by the following factors:

1) Developmental abnormality

Change in shape and position of developing palatal folds (Poswillo 1966, Aronov 1972, Griffin 1978 and L. Gray 1980). Aronov found abnormality in 25% of developing palatal folds.

2) Postural pressure during pregnancy

Head flexion can impair development of the mandible, as in Pierre-Robin Syndrome (Poswillo, 1966). Abnormal arm pressure can influence the maxilla (L. Gray, 1978; Dunn, 1973). Oligoamnios may also be a contributing factor.

3) Parturition pressure

Incidence of septal deformity and mandibular alignment varies with different fetal presentations and difficulties at birth (L. Gray 1978, 1980).

4) Familial genetic factors

(Sicher 1952, Sim 1977).

5) Functional matrices

(Moss 1962).

6) Environmental factors

Trauma, loss of teeth, dental caries, action of muscles, sucking of objects, etc. (Moyers 1973).

Factors 1, 2 and 3 are the major factors in the newborn.

Every baby is subjected to a certain amount of pressure during parturition, with head adaptations such as parietal bone and facial molding. Any molding of the face occurs across the

maxilla, because the bimalar span is the widest part of the face.

This molding compresses and deforms the soft maxilla. The arch of the palate is elevated and the nasal height from palate to base of skull is decreased. Under such loads the septum must inevitably be deformed. The deformation may be predominantly unilateral or bilateral.

The mandible is so very closely applied to the maxilla that it may also be deformed. It is especially susceptible to pressure from the oncoming shoulder (Fig. 4). This occurs in about 10% of all births, and has been found to usually return to normal alignment within 6 months.

The relationships of the septal configuration were considered in three parts:

1) Its relationship to the shape or configuration of the maxilla, palate and mandible.

2) Its relationship to the height and shape of the palate.

3) Its relationship to the shape of the external nares.

A dental cast was classified as normal on the basis of the following criteria:

a) For the maxillary and mandibular dental arches, the arch form was continuous without buckling, with no rotation or crowding or overriding of the teeth.

b) For the palate, the arch of the palate was symmetrical.

c) For intermaxillary relationship, the midlines of the maxillary and mandibular dental arches were in alignment with the mandible in centric relationship.

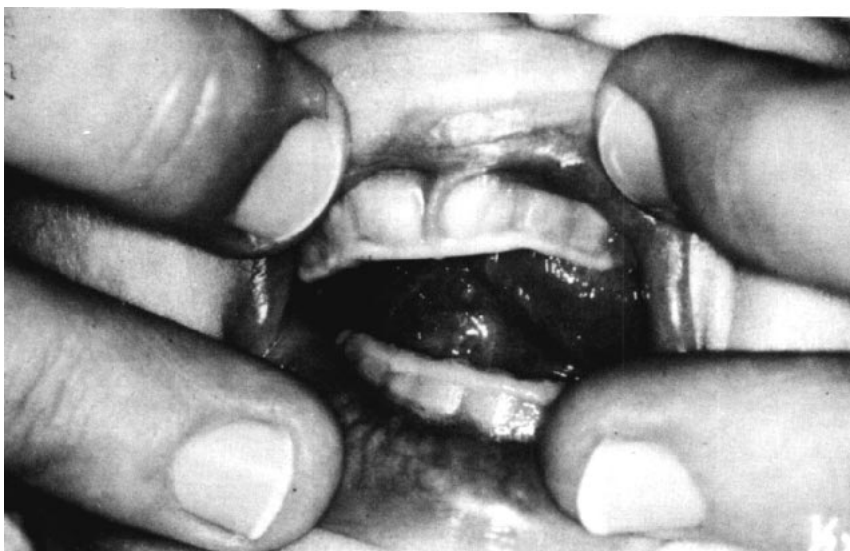

Fig. 4 Photograph of a baby at birth, demonstrating the angulation of the mandible in relation to the maxilla.

A. Mandible, Maxilla and Palate

Three components of each subject were evaluated—the mandible, the maxilla and the palate. The dental casts were assessed independently by two people (L.P.G. & P.I.D.), and the final findings mutually agreed upon. Each cast was allotted a maximum of 3 points. One point was allotted initially for a normal cast, and then 1 or 2 points were added according to the severity of the abnormalities.

Mandible

In the mandible, 1 point was added for deviation in midline alignment, rotation and compression, or crowding of the teeth. A change in position of the lower dental midline was considered to be an important early sign of abnormality.

Maxilla

In the maxillary dentition, rotation

and crowding were scored as 1 point each. Distortion of the line of the teeth, causing a tooth to be completely out of line or overlapping the next tooth, was considered to be strongly suggestive of maxillary compression.

Palate

To evaluate the palate, a silicone-based impression was taken from the dental cast of the maxilla and divided coronally in 3 places—along the mesial margins of the second deciduous molars, the first deciduous molars and the cuspids—using a long skin graft blade and a special holding device. These three segments were traced on graph paper, and the height and width from the midline were measured at the middle cut (Fig. 5). Points were added for a difference in height on the two sides, and for difference in width.

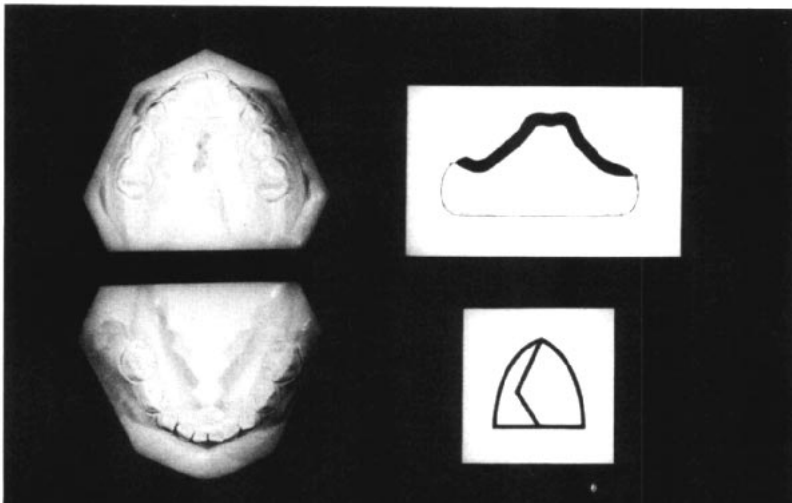
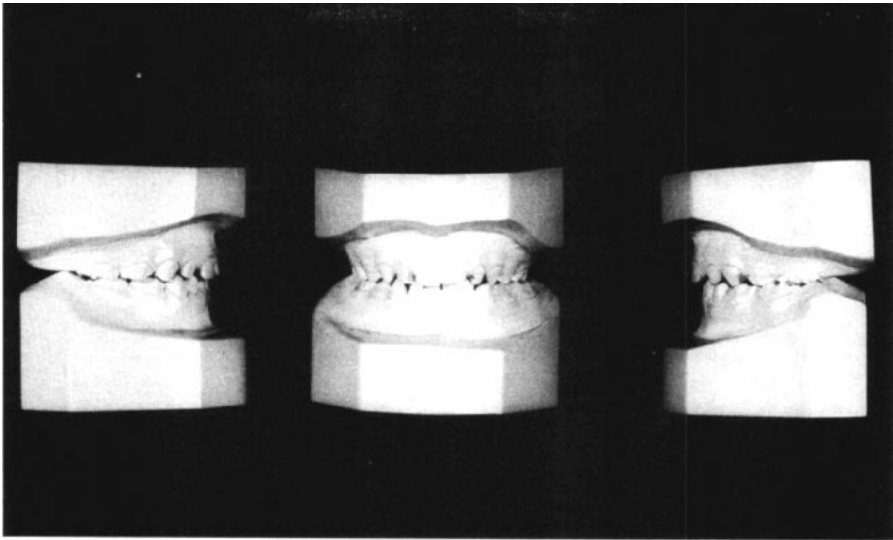


Fig. 5 Casts showing typical dental abnormality associated with septal deformity (patient S.M.).

A. The dental occlusion.

B. Occlusal view and section of the palatal cast with sign showing kinking septal deformity to the right (type B).

Note:

- 1) The mandible shows mild midline swing to the left, with sliding anteriorly on the right and posteriorly on the left. The mandibular arch also shows rotation and compression of the left anterior segment.
- 2) Lingual crossbite of the left buccal segments.
- 3) The maxilla shows deformity of the outline of the arch, with rotation of the incisors and lingual compression of the right anterior segment.
- 4) The palate is asymmetrical.

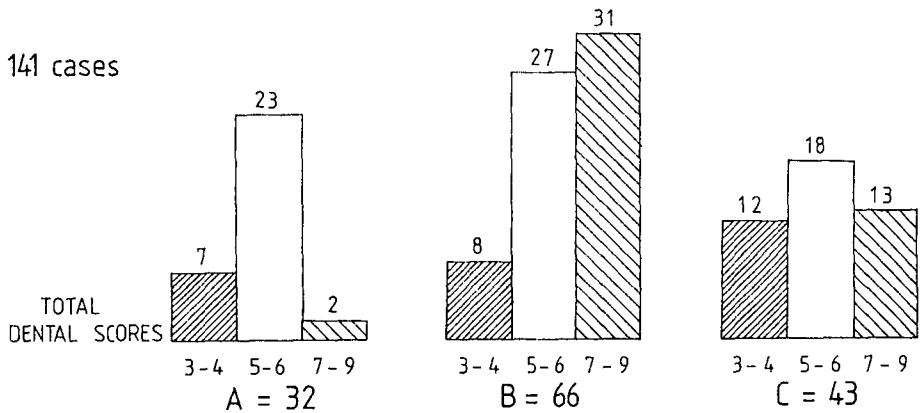


Fig. 6 Dental Correlation with Septal Configuration. Dental deformity scores for each type of septal configuration, showing minimal dental deformity in type A and highest incidence of severe deformity in type B subjects.

The points for each subject were totalled and called the Total Dental Score. A Total Dental Score of 3 for all three parts was classified as normal. The remaining subjects were divided into three groups—those scores totaling 3 or 4 (minor deformity), 5 or 6 (moderate deformity) and 7 to 9 (considerable deformity). Only three subjects had 9 points.

The groups were then plotted against the septal types (Fig. 6). This showed that type A is mainly associated with minor and moderate deformity, type B with considerable deformity, and type C with moderate deformity. These differences were statistically significant ($\chi_4^2 = 18.8$, $P < .001$).

Compression and rotation deformity of tooth position in the maxilla was found in 108 subjects, 65% of type A, 88% of type B and 65% of type C. The higher incidence of deformity in type B was statistically significant ($\chi_1^2 = 11.0$, $P < .001$).

Frank unilateral crossbite was not found in any type A subjects, in 6 of the type B and in 4 of the type C.

Anterior open bite was found in 18 subjects, of which 6 were type A, 8 type B and 4 type C, so this was not significant in the overall findings.

Mandibular Midline

The mandibular arch was found to be in the midline more often in type A (72%), less in type C (65%) and least in type B (50%). The Total Dental Scores demonstrated that there was increasing change in the midline position with increasing deformity ($\chi_2^2 = 31.5$, $P < .001$) (Fig. 7).

Textbooks (as Sim, 1977) state that a change in position of the lower dental midline is a warning of developing malocclusion. If maxillary compression occurs, it may compress one side, leading to later interference with the normal cuspal interdigitations of the mandibular teeth.

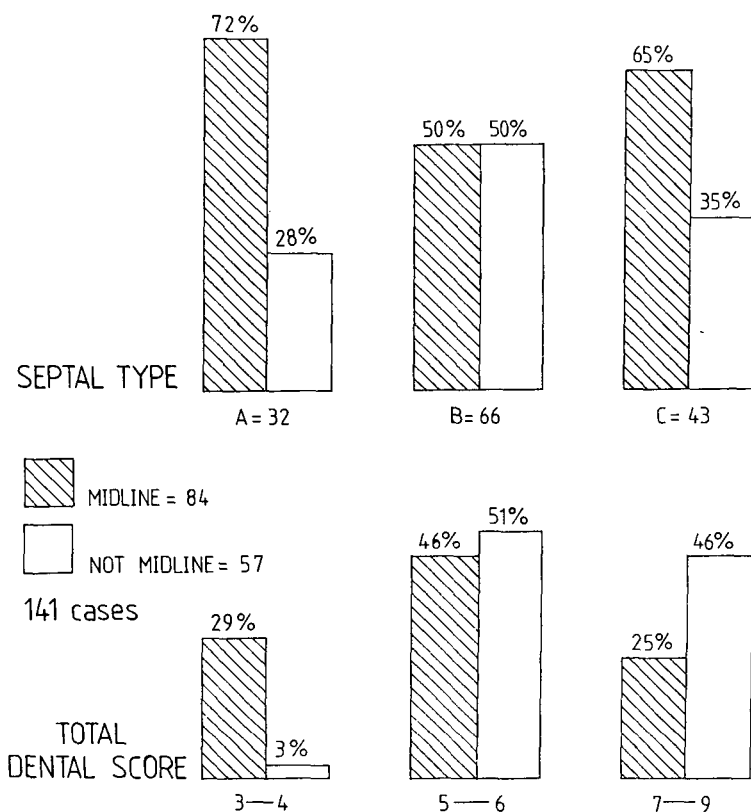


Fig. 7 Correlation of the midline position of the mandible with septal type and dental deformity score.

The midline position is commonest in type A and in the lowest dental scores, while midline shift is most common in type B and in the highest dental scores.

With minor compression the tips of the cusps may be in contact, and then because the mandible is mobile and functionally adaptable, one of three effects may result—

1) The mandible will gently swing or rotate to enable the cusps to interdigitate more comfortably (Figs. 5, 8 and 9). The teeth on the opposite side readily slide down the central groove to accommodate the bite as shown by the midline swing and difference in alignment of the deciduous molars on each side. (This was demonstrated in a dental model by L. Gray, 1974.)

2) Excessive tooth wear, with resultant flattening of the cusps.

3) With greater compression, frank lingual crossbite with the teeth in comfortable occlusion (Figs. 5, 8 and 9). Occasionally the crossbite may shift from one side to the other.

B. The Relationship of the Height and Shape of the Palate to the Septal Types.

Palatal height was not statistically related to the evenness or unevenness of the arch of the palate or to the septal type.

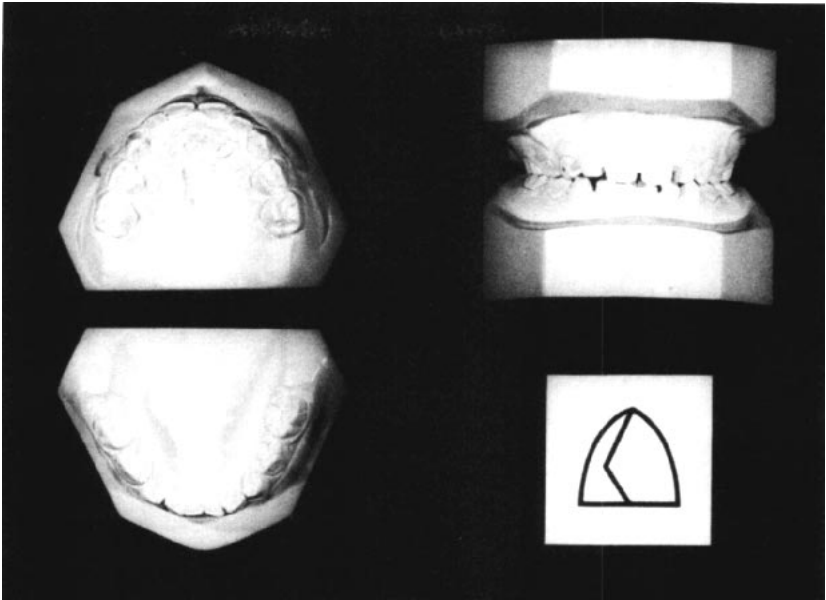


Fig. 8 Casts showing mild compression of maxilla (type B septum, patient N.B.). These casts show articulation with the tips of the cusps in occlusion. In this subject the bite would change in function to a crossbite on either side, where the occlusion was more stable and comfortable.

However, palatal asymmetry was present most frequently in type B, less in type C and least in type A (Fig. 10) ($\chi_2^2 = 7.2$, $P < .05$).

C. *The Relationship of the Shape of the External Nares to the Septal Types*

Photographs of 114 subjects were evaluated for unevenness of the external nares, as identified by narrowing or change in shape of one side. Unevenness was found in 60% of type B, 50% of type C and 42% of type A. While this was not statistically significant, it is consistent with the pressure molding theory.

Summary

To summarize, the incidence of deformity was greatest for type B, less for type C and least for type A, as seen in Table 1.

DISCUSSION

The close association of dental malocclusion with septal deformity suggests that the alignment and rotation of the dental follicles may be altered by molding or compression of the alveolar arch at the time of birth. Other factors may also influence the condition after birth.

The maxilla is easily deformed at birth, as is the mandible. The softness and malleability of the maxilla has been shown by the change in shape of the palate following manipulation. The septal configuration has been found to be related to the shape of the palate. Differences in size and level of the developing palatal arches may cause septal abnormalities.

It is suggested that minor generalized facial pressure during birth will produce minimal pressure changes on

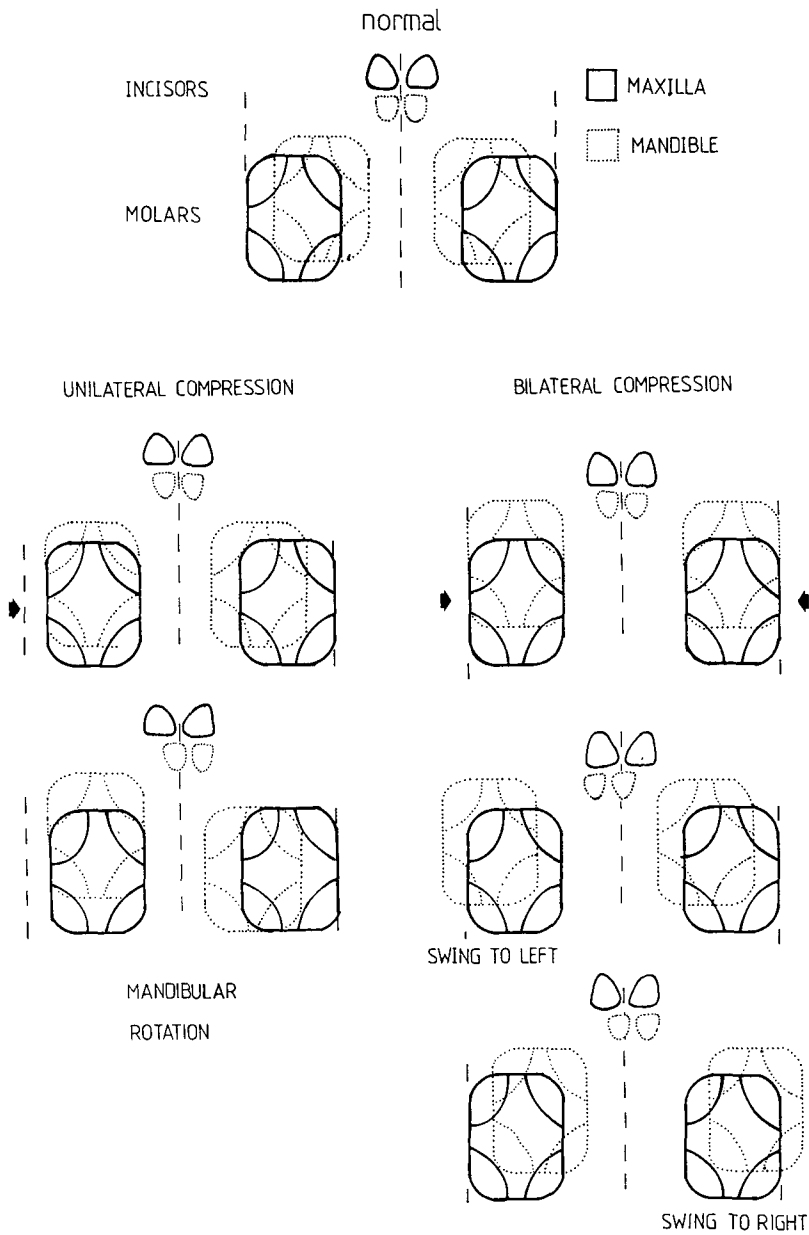


Fig. 9 Diagrammatic representation of the occlusal cause of movement of the mandible from the midline.

Unilateral compression causes unilateral articulation of the tips of the cusps, with ensuing horizontal rotation or swing of the mandible forward on one side and backward on the other, with a midline change. Further bilateral compression causes articulation of the tips of the cusps on both sides, which often causes a side movement with consequent lingual crossbite.

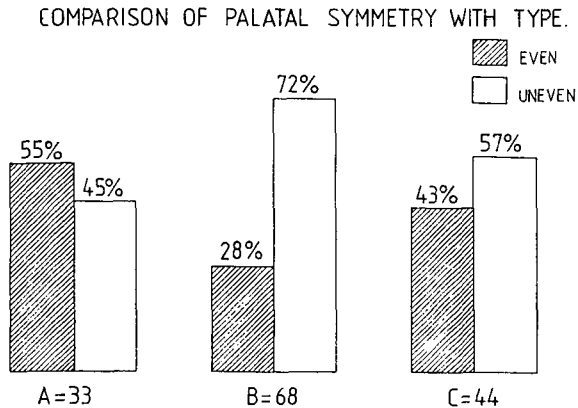


Fig. 10 Comparison of Palatal Symmetry with Septal type. The outline of the palate is most uneven in type B subjects.

TABLE 1
Incidence of Deformities with the Three Septal Types

| | <i>Type A</i> | <i>Type B</i> | <i>Type C</i> |
|--|---------------|---------------|---------------|
| | % | % | % |
| 1. High Total Dental Scores (7 to 9) | 6 | 47 | 30 |
| 2. Incidence of malaligned teeth | 65 | 88 | 65 |
| 3. Incidence of Mandibular arch swing | 28 | 50 | 35 |
| 4. Incidence of Palatal Asymmetry | 45 | 72 | 57 |
| 5. Incidence of Unevenness of External Nares | 42 | 60 | 50 |
| 6. Incidence of Lingual Crossbite | none | 6 cases | 4 cases |

the teeth and minimal palatal deformity, with little or no septal deformity (type A).

Bilateral pressure will cause more pressure on the anterior part of the maxilla, for the posterior part is attached to and protected by the base of the skull. Heavier forces can produce more crowding, overriding of the anterior teeth and the S-shaped compression of the septum (type C), as demonstrated by L. Gray and Brogan (1970, 1972).

Pressure from increased torsion will tend to push in on one side of the maxilla, elevating the side of the palate and kinking the septum to the op-

posite side at the vomer-cartilage-ethmoid junction (type B). This also causes localized compression of the alveolar arch, disturbing the developing tooth buds, and will eventually result in tooth malalignment and cuspal interference with occlusion.

This research has borne out very strongly that dental and palatal abnormalities are very likely to develop in subjects who have type B septal deformity at birth. It is much less likely in type C, and quite unlikely in type A. Clinical experience also supports these conclusions.

In many subjects these dental abnormalities are of sufficient severity to

expect that considerable malocclusion will develop. If this is so, then the same etiological factors producing septal abnormalities at birth must be considered to be factors in producing malocclusions.

The incidence of infection of the upper respiratory tract was also found to be greatest in type B and least in type A, which conforms with clinical experience.

The incidence of open bite was similar in all septal types, so it did not appear to be related to the other major dental changes in the maxilla.

Further confirmation of these findings must await the review of these subjects at age 8 or 9 years.

SUMMARY

The findings on the development of dental, facial and septal conditions from birth to about 6 years of age include the following:

1) Septal configuration can be readily tested at birth, and if deformity is present, then deformity will still be present at age 6 years.

2) The internal septal configuration can be categorized into three types:

type A: The septum is in the midline.

type B: There is unilateral bending or kinking of the septum at the vomerine junction.

type C: The septum is deformed to both sides in an S configuration.

3) Height of the palate does not predispose to septal deformity.

4) Dental abnormalities of rotation, compression or crowding of the teeth, asymmetry of width and height of the palate, and shift of the mandibular arch from the midline occur most frequently in cases of type B (88%), much less in type C and least in type A.

5) At birth one can predict that type B babies will have considerably more likelihood of developing occlusal abnormalities than type A babies.

6) The dental abnormalities in many of these subjects are of sufficient degree to expect that malocclusion will undoubtedly develop. Thus the same etiological factors producing septal abnormalities at birth must be considered to be factors producing many malocclusions.

We wish to thank the Princess Margaret Hospital; Sister Wheeler and Mrs. C. Walter for the photography and dental casts; Mr. Ralph Baker for producing the graphs—Mr. J. Shepherd, King Edward Memorial Hospital for Women, for his help in tracing the children—Mr. N. Stenhouse and Mr. K. Wearne of the Medical Statistics Department of the University of Western Australia for the statistical assessments—The Medical Photographic Department of the Public Health Department of Western Australia for the reproductions—The Princess Margaret Children's Medical Research Foundation (Inc.) for considerable financial assistance.

References on following page.

REFERENCES

1. Aronov, A. (1972): Development of the Hard and Soft Palate in Man. In G. H. Schumaker (Ed.). *Morphology of the Maxillo-Mandibular Apparatus*, Proc. IX International Congress of Anatomists, Leningrad. U.S.S.R. 1970. George Thieme, Leipzig, 1972. 70-73.
2. Dunn, P. M. (1973): Congenital Postural Deformities. Further Perinatal Associations. *Proc. Roy. Soc. Med.* 67, 32-36.
3. Gray, L. P., and Brogan, W. F. (1970): Septal Deformity Malocclusion and Rapid Palatal Expansion. *Aust. Dent. J.* 2 154-166.
4. Gray, L. P., and Brogan, W. F. (1972): Septal Deformity, Malocclusion and Rapid Maxillary Expansion. *Orthodontist* 4.2.
5. Gray, L. P. (1974): Septal and Associated Cranial Birth Deformities, Types, Incidence and Treatment. *Med. J. Aust.* 1, 557-563.
6. Gray, L. P. (1978): Deviated Nasal Septum, Incidence and Etiology. *Annals Otolaryngology & Laryngology*. 87. Supplement 50.
7. Gray, L. P. (1980): Relationship of Septal Deformity to Snuffy Nose, Poor Feeding, Sticky Eyes and Blocked Naso-Lacrimal Ducts. *International J. of Paediatric Otorhinolaryngology*, 2. 201-215.
8. Griffin, C. J. and McGrath, P.: Embryogenesis, Development and Some Anomalies of the Upper Respiratory Tract, Including the Septo-Maxillary Syndrome and its treatment. Sydney University Press. 1978.
9. Moss, M. (1962): The function matrix. *Vistas in Orthodontics*—Kraus, B. and Riedal, R. (eds.) (Philadelphia: Lea and Febiger) P. 85-98.
10. Moyers, R. E. (1973): *Handbook of Orthodontics*, Third ed. Year Book Medical Publishers Chicago. Pp. 242-271.
11. Poswillo, D. (1966): Observation of foetal posture and Causal Mechanisms of Congenital Deformity of Palate, Mandible and Limbs. *J. Dent. Res.* 584-596.
12. Sicher, H. (1952): *Oral Anatomy* (St. Louis the C. V. Mosby Co.).
13. Sim, J. M. (1977): *Minor Tooth Movement in Children*, 2nd Ed. St. Louis Mosby 1977.