

Varieties of *In Vivo* Tooth Movements

DONALD H. ENLOW, Ph.D.

JAMES A. McNAMARA, JR., D.D.S., Ph.D.

The "mesial drift" of maxillary and mandibular teeth is a process that is ordinarily regarded as a horizontal movement of teeth associated with continued deposition of new bone on the distal sides of alveolar sockets together with resorption from the mesial sides. This process is believed to provide rigid tooth-to-tooth buttressing that compensates for wear.² Drifting also functions in the anatomic placement of teeth during progressive growth and remodeling of the maxilla and mandible.¹ Transient rotary and tilting movements of the teeth occur during growth, and these are also associated with changing patterns of deposition and resorption on alveolar bone surfaces.

The process of mesial (and distal) drift has been associated with tooth movements primarily along a *horizontal* plane. The purpose of the present report is to point out that the mandibular and especially maxillary teeth also drift *vertically* to a marked extent. The *same* process of new bone deposit and old bone resorption on the various lining surfaces of the alveolar sockets also accomplishes inferior drift of the maxillary teeth and superior drift of the mandibular teeth. The over-all extent of inferior maxillary arch drift exceeds upward drift of the mandibular teeth because nasal expansion is involved in maxillary growth. The process of tooth drift is thus three-dimensional in nature. Deposition of bone on any "downward and forward" oriented surface of a distal alveolar wall together with simultaneous resorption from any mesial wall which faces in a generally oppo-

site, superior and posterior direction thereby associates with movement of the tooth in correspondingly forward and downward directions. Drift is thus not merely "mesial" in nature.

Precise distinctions between vertical "drift," "eruption," and "displacement" are essential. The differential effects of these three separate processes are illustrated in Figure 1. In studies of craniofacial growth involving forty-eight young, growing rhesus monkeys (*Macaca mulatta*), metallic implants were placed in the anterior maxillary arch of each animal and also in the anterior cranial floor.³ Following various periods of growth, the maxillary implants subsequently became "displaced" anteriorly (from position *A* to *B* in

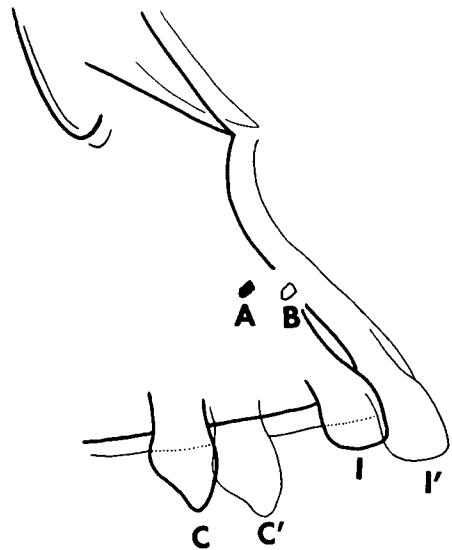


Fig. 1 Anterior nasomaxillary region, *Macaca mulatta*, showing displacement of an embedded metallic implant (*A* to *B*) and the anteroinferior drift of the deciduous teeth (*C* and *I*). Tracings are superimposed on anterior cranial base implants (not shown).

From the Department of Anatomy and Center for Human Growth and Development, The Univ. of Michigan.

Figure 1) relative to the anterior cranial fossa with the cranial floor implants superimposed. This is a result of a carry (displacement) of the entire ethmomaxillary complex in an infero-anterior direction. The displacement movement, according to conventional theory, is associated with the growth of the functional matrix together with compensatory bone growth in the various maxillary sutures.

Note that the total extent of anterior movement of the teeth (*I*, *I'* and *C*, *C'*) exceeds the extent of forward displacement of the implant itself. The difference between them represents the actual extent of *mesial* (*horizontal*) drift of the teeth. The total horizontal movement of each tooth is thus a composite of two growth processes, drift and displacement.

The total vertical (downward) movement of each tooth similarly exceeds the extent of downward displacement of the implant (which is minimal at this age level in this particular animal since the major period of vertical growth has already occurred). The difference between them represents the extent of *inferior* (*vertical*) drift and is associated with the same deposition and resorption of alveolar bone that is also related to the horizontal direction of drift described above. This vertical drift is in addition to any tooth eruption that occurs. Vertical drift, associated with the downward movement of the entire palatal and maxillary arch complex, is not to be confused with the separate process of tooth eruption which may occur simultaneously with the vertical drifting process. Note that the extent of crown protrusion beyond

the downward-growing inferior alveolar margin does not increase between stages *I*, *I'* and *C*, *C'*. It would thus be misleading and erroneous to designate this particular vertical tooth movement as "eruption", since the latter is concerned essentially with attaining occlusion. It is rather, a vertical drifting of the teeth associated with the direct downward growth by bone deposition and resorption (not displacement and sutural growth) of the entire maxillary arch, palate, and the vertical enlargement of the nasal chambers. The whole maxillary arch becomes composed of entirely new and different bone tissue during progressive growth due to the continued reformation and remodeling of the bone tissue as the teeth become relocated within the enlarging, changing maxilla and mandible.

*Department of Anatomy
West Virginia Univ.
Morgantown, W. Va. 26506*

ACKNOWLEDGMENTS

This study was supported, in part, by United States Public Health Service Grant DE-02272. Illustration by Mrs. Ruth Bigio.

REFERENCES

1. Enlow, D. H., Mesial drift as a function of growth. Symp. on Growth, University of West Indies, *West Indian Medical Journal* XIV:124, 1965.
2. Orban's, *Oral histology and embryology*. H. Sicher, ed., The C. V. Mosby Company, St. Louis, 1966.
3. McNamara, J. A., Jr., Neuromuscular and skeletal adaptations to altered orofacial function. Doctoral Dissertation, *The University of Michigan*, Ann Arbor, 1972.