

## A Rare Case of Pilomatricoma with Bullous Appearance

Ayşe Serap KARADAĞ<sup>1</sup>  
Meral EKŞİOĞLU<sup>2</sup>  
Ekin ÖZLÜK<sup>2</sup>  
Gülfer AKBAY<sup>2</sup>  
Alev EKEN<sup>2</sup>  
Savaş SEREL<sup>3</sup>  
Hesna Müzeyyen ASTARCI<sup>4</sup>

**Background:** Pilomatricoma is a rare, benign adnexal tumor differentiating toward elements of the hair matrix and shaft. It typically presents as a solitary, deep, dermal nodule. In addition, bullous changes can be rarely seen.

**Methods:** A 16-year-old girl with firm, mobile, multilobule and non-tender mass that has a soft, hemorrhagic blister-like formation on the left infraclavicular region is described.

**Results:** The histopathologic findings were consistent with pilomatricoma. In the dermis above the tumor, there were numerous dilated lymphatic and blood vessels. No pathologic elastic fibrils were identified with elastin stains. Collagen fibrils were normal with Mason trichrome stain.

**Conclusions:** The patient is diagnosed as pilomatricoma with bullous appearance.

**Key Words:** Adnexal tumor, pilomatricoma, with bullous appearance

### Nadir Görülen Bir Büllöz Pilomatrikoma Olgusu

<sup>1</sup> Department of Dermatology,  
Ankara Keçiören Research and  
Training Hospital,  
Ankara - TURKEY

<sup>2</sup> Department of Dermatology,  
Ankara Research and Training  
Hospital, Ankara - TURKEY

<sup>3</sup> Department of Plastic and  
Reconstructive Surgery,  
Ankara University Faculty of  
Medicine, Ankara - TURKEY

<sup>4</sup> Department of Pathology,  
Ankara Research and Training  
Hospital, Ankara - TURKEY

**Giriş:** Pilomatrikoma nadir görülen, kıl shaftı ve matriksinin primitif hücrelerinden köken alan benign bir neoplazidir. Tipik olarak tek, derin ve dermal bir nodül şeklinde görülür. Buna ilaveten nadiren büllöz değişiklikler görülebilmektedir.

**Metod:** Onaltı yaşında, sol infraclavikuler bölgede, yumuşak ve hemorajik bül benzeri görünümü olan, sert, mobil, multilobüle bir kitlesi olan bayan hasta bildirilmiştir.

**Sonuçlar:** Histopatolojik bulgular pilomatrikoma ile uyumluydu. Tümörün üzerinde dermiste çok sayıda dilate lenfatik ve kan damarları mevcuttu. Elastin boyasında elastik liflerde patolojiye rastlanmadı. Mason trichrome boyasında kolajen liflerin normal olduğu görüldü.

**Tartışma:** Hastaya büllöz görünüşlü pilomatrikoma tanısı kondu.

**Anahtar Sözcükler:** Adneksiyal tümör, pilomatrikoma, büllöz görünüm

Pilomatricoma is a common benign adnexal tumor differentiating toward elements of the hair matrix and shaft. It typically presents as a solitary, deep, dermal nodule (1). In addition, multiple lesions are rarely malignant and bullous, and anetodermic changes can be seen (1-4). We report a rare case of pilomatricoma with bullous appearance.

### Case report

A 16-year-old girl with three months history of hard swelling on her left shoulder was admitted to our clinic. The mass emerged 3 months ago and bullous formation associated swelling appeared during the last month. There was no trauma history. Family and past medical history was unremarkable. Systemic examination was normal. Physical examination revealed no regional lymphadenopathy. In dermatologic examination, there was a 2 × 1.6 cm, firm, mobile, multilobule, non-tender mass on the left infraclavicular region. A 1.8 × 1 cm soft, hemorrhagic blister-like formation was detected on the mass (Figure 1). Laboratory examination (complete blood count, serum biochemical and urine analysis, PA thorax radiography) was in normal limits.

The tumor was excised totally (Figure 2). In the histopathologic examination, the tumor was seen as multiple islands that had well defined borders and surrounded by a fibrous capsule in the dermis (Figure 3). These islands contained basophilic and shadow

Received: March 13, 2008  
Accepted: December 03, 2008

#### Correspondence

Ayşe Serap KARADAĞ  
Department of Dermatology,  
Ankara Keçiören Research and  
Training Hospital,  
Ankara - TURKEY

drayserem@yahoo.com

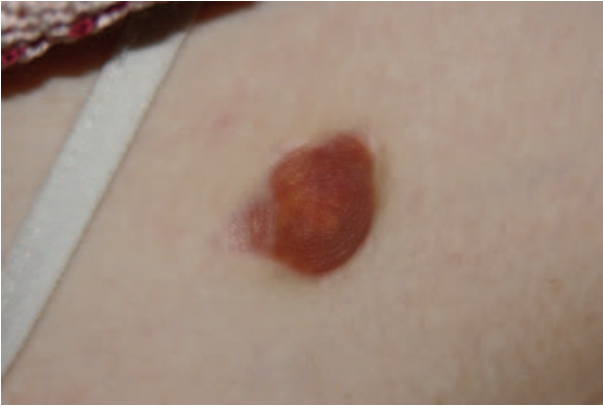

Figure 1. Appearance of the wrinkled bullous on the edge of the nodular lesion on the left shoulder of the patient.

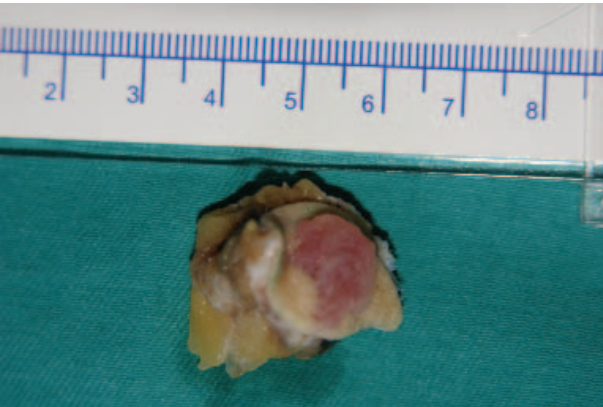


Figure 2. Macroscopic appearance of the totally excised lesion.

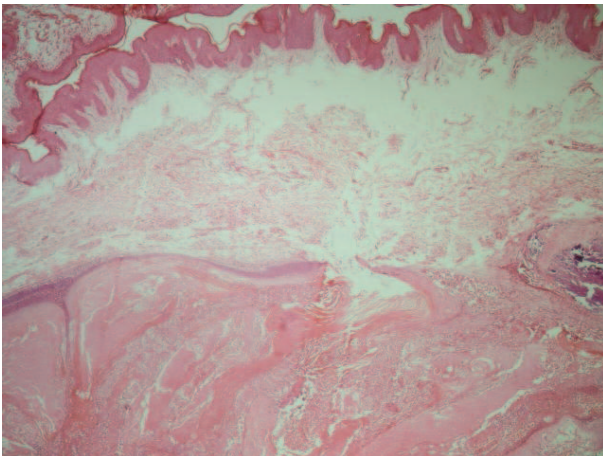


Figure 3. Appearance of the lesion that localizes under epidermis and in the edematous dermis.

cells, and also small, round, and eosinophilic staining keratinization regions (Figure 4). In the dermis above the tumor, there were numerous dilated lymphatic and blood vessels. No pathologic elastic fibrils were identified with elastin stains. Collagen fibrils were normal with Mason trichrome stain. Mucin accumulation was not detected with Alcian blue stains. The diagnosis was pilomatricoma with bullous appearance accordingly with above pathologic findings.

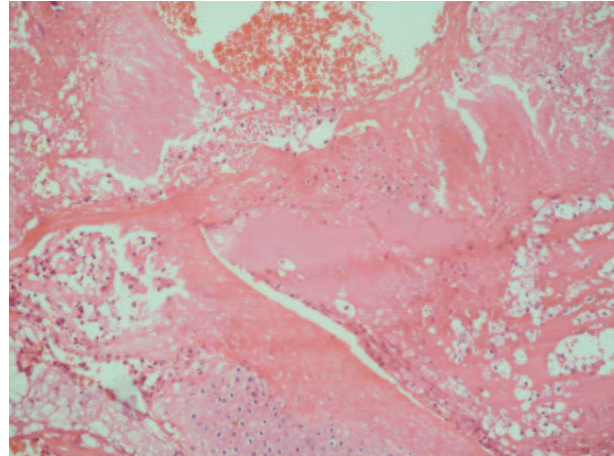


Figure 4. Appearance of ghost cells.

## Discussion

Pilomatricoma, also known as calcifying epithelioma of Malherbe, is a benign adnexal tumor differentiating toward elements of the hair matrix and shafts (1,2,5). These tumors tend to occur in women generally in the first 2 decades. Pilomatricomas have affinity to locate mainly on the head and neck, while bullous lesions are frequently found on shoulder and upper arm (2,5-7). It is seen as a single, hard and either deeply dermal or subcutaneous localization nodule, but also multiple lesions were reported (5). Overlying normal skin can be seen blue-red (7). Because of the low incidence and variable clinical presentation, pilomatricoma is a tumor commonly misdiagnosed. Associated changes of the overlying epidermis explain the vast list of conditions for which pilomatricoma can be mistaken. Epidermal, sebaceous, and dermoid cysts, vascular lesions, and foreign bodies are some of the entities mistaken for pilomatricomas (3).

Rarely bullous, keloid, perforan, vesicle-like lesions and pseudobullous changes have been reported (4,6,8).

Bullous pilomatricoma is an uncommon variant and only a few cases of this lesion exist in the literature (7,9). In Japan, the incidence of pilomatricoma with a bullous appearance was assumed to be 6.3% (7). Pilomatricoma with bullous appearance contains loose and thick wall on the hard tumor. Several hypotheses for etiopathogenesis have been reported including mechanical irritation, lymphatic obstruction, secondary anetoderma development and secretion of elastotic enzymes from tumor and inflammatory cells (9,10).

It was considered that mechanical irritation and minor trauma might be the initiative factor to accelerate tumor growing and bullous appearance formation (5,11). However, the current literature does not support this hypothesis due to the lack of trauma histories in some cases (6,10), and because of no trauma record in our case.

Inue et al. suggested that the tumor induced pressure on the area around the hard core of the pilomatricoma causes obstruction of the lymphatic vessels. The obstruction subsequently leads to dilatation and congestion of lymphatic vessels. As a result, tumor surrounded by prominent edema occurs in the dermis leading to bullous appearance formation (7).

In the review of 209 cases of pilomatricomas, Julian and Bowert (5) demonstrated that in pilomatricomas covered by vascular atrophic skin, the overlying dermis is filled with dilated lymphatic vessels. Numerous blood vessels lined with endothelial cells and chronic inflammatory cells infiltration was observed which was described as a lymphangiectatic variant. Dilated lymphatic vessels are known to be a common pathologic feature in the bullous appearance of pilomatricoma (5,6,11). Our case seems to contribute to the theory that lymphatic dilatation is a part of etiology, due to the fact that several lymphatic and blood vessels were identified in our histopathological examination.

Another hypothesis was proposed that pilomatricoma bullous appearance was affiliated to anetodermic alteration defined as pseudobullous appearance (1,10). In English and French literature, this variant is called secondary anetoderma involving a pilomatricoma (5). Focal destruction of elastic fibrils is the primary pathologic feature of the anetoderma. Some lesions of secondary anetoderma associated with a pilomatricoma include dermal atrophy, reduction, thinning, or degeneration of collagen bundles and dermal edema. Several retrospective studies have reviewed cases of pilomatricoma but their clinical and pathologic findings did not support anetodermic alteration (10). However, in some cases, diminished fragmented collagen and absence of elastic tissue were detected. It is supported that bullous appearance is related to anetoderma (12). In some cases, superficial elastic fibers were only observed on the upper part of the tumor complementing the proposal that these findings could show the early stage of anetoderma changes that would increase as tumor grows. The etiology of anetoderma is yet vague. Tumors might damage elastic fibers by mechanical trauma. Inflammation might trigger the release of elastosis by inflammatory cells while these enzymes may destruct elastic and collagen fibers (1,10).

In our cases, we believe that bullous appearance is not related with mechanical irritation due to the lack of trauma history. Besides, histopathologic examination revealed normal elastic bundles without pathologic findings in collagen fibers demonstrating a real blister. Accordingly, we exclude secondary anetoderma related to pseudobullous appearance. As several prominent dilated lymphatics and blood vessels exist in our examination, we believe that our case could be explained via lymphangiectatic variant hypothesis. Moreover, we deem that the bullous appearance might be related to obstruction and dilatation of lymphatic vessels. However, further research is warranted for the exact etiology of bullous appearance.

## References

1. Weichert GE, Bush KL, Crawford RI. Bullous pilomatricoma: a report of clinical and pathologic findings and review of dermal bullous disorders. *J Cutan Med Surg* 2001; 5: 394-6.
2. Pirouzmanesh A, Reinisch JF, Gonzalez-Gomez I, Smith EM, Meara JG. Pilomatricoma: a review of 346 cases. *Plast Reconstr Surg* 2003; 112: 1784-9.
3. Fernandes BF, Al-Hinai A, Belfort RN, Castiglione E, Arthurs B, Burnier MN Jr. Anetodermic variant of a periorbital pilomatricoma. *Ophthal Plast Reconstr Surg* 2008;24(5): 419-21.
4. Yiqun J, Jianfang S. Pilomatricoma with a bullous appearance. *J Cutan Pathol* 2004; 31(8): 558-60.

5. Julian CG, Bowers PW. A clinical review of 209 pilomatricomas. *J Am Acad Dermatol* 1998; 39: 191-5.
6. Prasad HR, Verma KK, Khaitan BK, Singh MK. Bullous pilomatricoma: a rare occurrence. *Acta Derm Venereol* 2001; 81: 217-8.
7. Inue S, Kanda R, Hata S. Pilomatricoma with a bullous appearance. *J Dermatol* 1997; 24: 57-9.
8. Alli N, GÜngör E, Artüz F. Perforating pilomatricoma. *J Am Acad Dermatol* 1996; 35: 116-8.
9. Lao LM, Kumakiri M, Kiyohara T, Sakata K, Takeuchi A. Papillary endothelial hyperplasia and dilated lymphatic vessels in bullous pilomatricoma. *Acta Derm Venereol* 2005; 85(2): 160-3.
10. Shames BS, Nassif A, Bailey CS, Saltzstein SL. Secondary anetoderma involving a pilomatricoma. *Am J Dermatopathol* 1994; 16(5): 557-60.
11. Fetil E, Soyal MC, Menderes A, Lebe B, Gunes AT, Ozkan S. Bullous appearance of pilomatricoma. *Dermatol Surg* 2003; 29(10): 1066-7.
12. Fujioka M, Gozo N, Osamu M, Tsuneyuki Y, Takehisa Y. Secondary anetoderma overlying pilomatricomas. *Dermatology* 2003; 207(3): 316-8.