

The Effects of Nitric Oxide on Rat Stomach Injury Induced by Acetylsalicylic Acid*

Murat YAĞMURCA¹

Muharrem UÇAR²

Ersin FADILLIOĞLU³

Hasan ERDOĞAN⁴

Feral ÖZTÜRK⁵

Aim: Acetylsalicylic acid (ASA, aspirin), which is one of the most frequently used drugs in the world, causes severe gastric mucosal injury. Nitric oxide (NO) is synthesized from L-arginine by nitric oxide synthase (NOS). NOS can be inhibited by N ω -nitro-L-arginine methyl ester (L-NAME) and stimulated by supplementing the diet with L-arginine (L-Arg). The aim of this study was to investigate the role of NO on gastric mucosal injury induced by ASA.

Materials and Methods: Male Sprague-Dawley rats were divided into seven groups: control, ASA, ASA+L-NAME, ASA+L-Arg, ASA+L-Arg+L-NAME, only L-NAME, and only L-Arg groups. After administration of the drugs, the rats were decapitated and their stomachs were removed and fixed in 10% neutral-buffered formalin solution.

Results: Mucosal erosion, intramucosal hemorrhage, inflammatory cell infiltration, gland cell detachment, and necrosis were observed in the ASA group. It was demonstrated that L-Arg administration decreased the gastric mucosal injury, whereas L-NAME administration increased the extent and severity of the gastric injury induced by ASA. L-Arg or L-NAME administration alone did not affect gastric mucosa.

Conclusions: We concluded that NO may have protective effects on gastric mucosal injury induced by ASA.

Key Words: Nitric oxide, stomach injury, acetylsalicylic acid, microscopy

¹ Department of Histology-Embryology,
Faculty of Medicine,
Afyon Kocatepe University,
Afyon - TURKEY

² Department of Anesthesiology,
Faculty of Medicine,
İnönü University,
Malatya - TURKEY

³ Department of Physiology,
Faculty of Medicine,
Hacettepe University,
Ankara - TURKEY

⁴ Department of Physiology,
Faculty of Medicine,
Gaziosmanpaşa University,
Tokat - TURKEY

⁵ Department of Histology-Embryology,
Faculty of Medicine,
İnönü University,
Malatya - TURKEY

Ratlarda Asetil Salisilik Asitin Neden Olduğu Mide Hasarında Nitrik Oksitin Etkileri

Amaç: Dünyada en çok kullanılan ilaçlardan biri olan asetilsalisilik asit (ASA) gastrik mukozada önemli hasarlara yol açmaktadır. Nitrik oksit (NO) nitrik oksit sentaz (NOS) ile L-arjininden sentezlenir. NOS; N ω -nitro-L-arjinin metil ester (L-NAME) ile inhibe edilebilir, diyetle L-arjinin (L-Arg) eklenmesi ile uyarılabilir. Bu çalışmanın amacı ASA'nın neden olduğu gastrik mukozal hasar üzerine nitrik oksitin rolünü araştırmaktır.

Yöntem ve Gereç: Erkek Sprague Dawley sıçanlar; kontrol, ASA, ASA+L-NAME, ASA+L-Arg, ASA +L-Arg+L-NAME, L-NAME ve L-Arg olmak üzere 7 gruba ayrıldı. İlaçların uygulanmasını takiben kesilen ratlardan alınan mide kesitleri %10'luk nötral tamponlanmış formalin ile tespit edildi.

Bulgular: ASA grubunda mukozal erozyon, intramukozal hemoraji, iltihabi hücre infiltrasyonu, bez hücrelerinde nekroz ve dökülme izlendi. L-Arg uygulanmasının ASA'nın yol açtığı gastrik hasarı azalttığı gösterildi. Diğer taraftan, L-NAME uygulamasının ise ASA'nın yol açtığı gastrik hasarı belirgin olarak artırdığı tespit edildi. Sadece L-Arg ya da L-NAME uygulanması gastrik mukozayı etkilemedi.

Sonuç: Bu çalışma ile, ASA ile meydana gelen gastrik mukozal hasarda, NO'nun koruyucu rolü olabileceği sonucuna varıldı.

Anahtar Sözcükler: nitrik oksit, mide hasarı, asetil salisilik asit, mikroskopi.

Received: December 28, 2007
Accepted: September 03, 2009

Correspondence

Murat YAĞMURCA

Posta Kutusu: 17

03000 Afyonkarahisar - TURKEY

yagmurcamd@yahoo.com

* This study was presented in part at the 6th National Congress of Histology-Embryology in Istanbul, Turkey, 12-15 September 2002.

Introduction

Nitric oxide (NO) is synthesized from L-arginine (L-Arg) amino acid by one of the three isoforms of nitric oxide synthetase (NOS). NOS-1 is found in the gastrointestinal tract and neurons (nNOS) (1). The inducible NOS (iNOS), which is called NOS-2, is an important isoform that is found in the endothelial cells, macrophages and neutrophils. iNOS is the isoform that is induced to increase its synthesis in some pathological conditions and is responsible for the injury (1). NOS-3, which is found in endothelial cells, has useful effects for the organism (1). The stomach has all three isoforms of NOS. It is suggested that NO causes gastric acid secretion and gastric mucosal protection through many separate mechanisms. NO was shown to directly increase gastric acid secretion. It also increases gastric blood flow via vasodilatation, which leads to increased mucus secretion. It was shown in experimental animal studies that NO production increases when L-Arg is added exogenously (1-3). NO production from L-Arg can be inhibited with L-Arg analogues, experimentally. These L-Arg analogues competitively inhibit NOS enzyme. *N*-nitro-L-arginine methyl ester (L-NAME) is the most commonly used NOS inhibitor.

In this study, we constituted gastric mucosal injury with acetylsalicylic acid (ASA) in rats and we evaluated the possible effects of NO on this injury. Its effects were also evaluated when NO production was suppressed with L-NAME and was induced with L-Arg.

Materials and Methods

Animals

Thirty-nine male Sprague–Dawley rats weighing 250–350 g were used (180 days old) in the experiments. The animals were housed in quiet rooms with 12-hour (h) light–dark cycles (7 am to 7 pm). The experiments were performed in accordance with the “Guide for the Care and Use of Laboratory Animals, DHEW Publication No. (NIH) 85-23, 1985” and approved by the local ethical committee of the Medical School of İnönü University. All experiments were done at the laboratories of İnönü University.

Animal Treatment Model of ASA-induced Gastric Mucosal Damage and Experimental Groups

For 18 h before the experiments, the animals were fasted, but allowed free access to water. Rats were

randomly assigned to one of seven groups: control untreated rats ($n = 7$); animals treated with single oral ASA (Sigma, St. Louis, MO, USA) alone (250 mg/kg) ($n = 7$); animals treated with single oral ASA (250 mg/kg) + intraperitoneal (i.p.) injection L-NAME (15 mg/kg) (Sigma, St. Louis, MO, USA) ($n = 7$); animals treated with oral ASA (250 mg/kg) + i.p. injection L-Arg (500 mg/kg) (Sigma, St. Louis, MO, USA) ($n = 7$); animals treated with oral ASA (250 mg/kg) + i.p. injection L-Arg (500 mg/kg) + i.p. injection L-NAME (15 mg/kg) ($n = 7$); animals treated with i.p. injection L-NAME (15 mg/kg) ($n = 2$); animals treated i.p. injection L-Arg (500 mg/kg) ($n = 2$). The animals were sacrificed 2 h after the administration of ASA. Their stomachs were removed, dissected along the greater curvature, and rinsed in cold saline solution. The stomach tissue was stored at -70°C until biochemical analyses.

Determination of Gastric Mucosa Tissue Nitric Oxide Levels with Biochemical Analysis

Nitric oxide has a half-life of only a few seconds because it is readily oxidized to nitrite (NO_2^-) and subsequently to nitrate (NO_3^-), which serve as index parameters of NO production. The method for measurement of plasma nitrite and nitrate levels was based on the Griess reaction (4). Samples were initially deproteinized with Somogyi reagent. Total nitrite (nitrite + nitrate) was measured by spectrophotometry at 545 nm after conversion of nitrate to nitrite by copperized cadmium granules. A standard curve was established with a set of serial dilutions of sodium nitrite. The resulting equation was used to calculate the unknown sample concentrations.

Histological Examination

Specimens were fixed in buffered 10% formalin and 4% paraformaldehyde solutions and stained. The mucosal specimens were evaluated qualitatively under light microscopy (Olympus BH2).

Statistical Analysis

Results were presented as means \pm SD. Distribution of the groups was analyzed with one sample Kolmogorov–Smirnov test. All groups showed normal distribution, so parametric statistical methods were used to analyze the data. One-way ANOVA test was performed and post hoc multiple comparisons were done with LSD. P values < 0.05 were regarded as statistically significant.

Results

Stomach Tissue Nitric Oxide Levels

Comparison of NO levels of gastric tissue according to the various study groups is shown in Figure 1. NO levels were found to be increased in ASA, L-Arg and ASA+L-Arg+L-NAME versus controls ($P < 0.05$). However, there was no significant difference between NO levels of the ASA+L-NAME group versus the control group ($P > 0.05$).

Histopathological Results

There was no recorded death in any of the experimental animal groups during the study period.

Control Group: The gastric tissues were investigated microscopically and it was observed that tissue samples of the control group rats showed normal histological findings (Figure 2-A).

ASA Group: Microscopic investigation revealed focal erosive area in gastric mucosa and a zone (clear zone) in the basal regions of the gastric glands stained pale. This zone was parallel to the surface of the stomach lumen. In this zone, the structures of the gland were destroyed. They had disintegrated from the basal lamina and fallen into the lumen. The nuclei of these cells became smaller and dense, and their cytoplasm were stained as dark eosinophilic bodies. Small hemorrhagic areas and patches of inflammatory cell infiltrations were present in the lumen of the glands and lamina propria (Figure 2-B).

ASA+L-NAME Group: The observations made in the ASA group were seen in broader areas and more sections in number in this group. In contrast to the ASA group, the depths of gastric pits were increased and there were some areas in which gastric surface epithelium lost its normal structure. In addition, marked vascular dilatation in the tunica mucosa, hemorrhage in gland lumens and inflammatory cell infiltrations surrounding particularly the vessels were observed. Furthermore, hemorrhagic areas were commonly seen in the tunica submucosa (Figure 2-C).

ASA+L-Arg Group: Focal epithelial losses were seen in the surface epithelium covering gastric pits. In this group, no hemorrhage was observed in the lamina propria or tunica submucosa (Figure 2-D).

ASA+L-Arg+L-NAME Group: In this group, focal cellular loss in the gastric mucosa was seen. In addition, eosinophilic areas including basal parts as well as adjacent regions stained pale were observed, as seen in the ASA and ASA+L-NAME groups. Dilatations in the basal regions of the gastric glands were also more apparent (Figure 2-E).

L-NAME Group: Stomach sections displayed normal histological findings (Figure 2-F).

L-Arg Group: Stomach sections displayed normal histological findings (Figure 2-G).

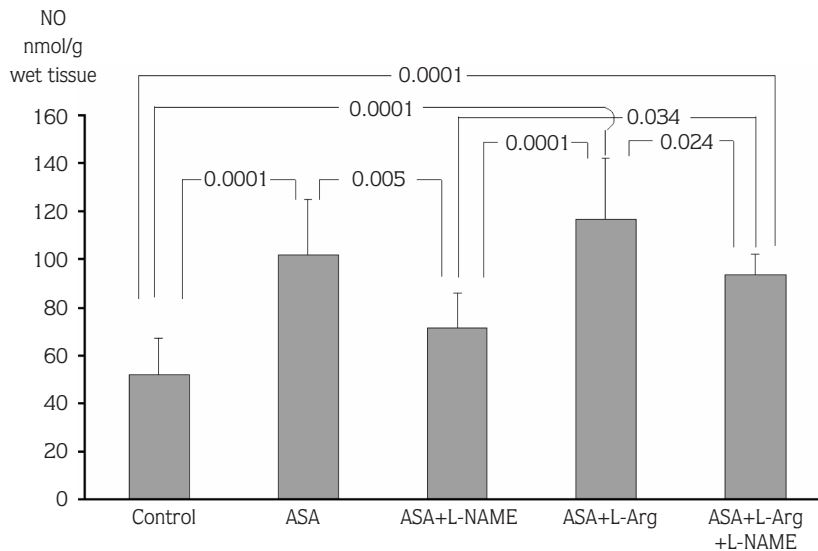


Figure 1. Comparison of the stomach tissue NO levels according to groups ($P < 0.05$ statistically significant).

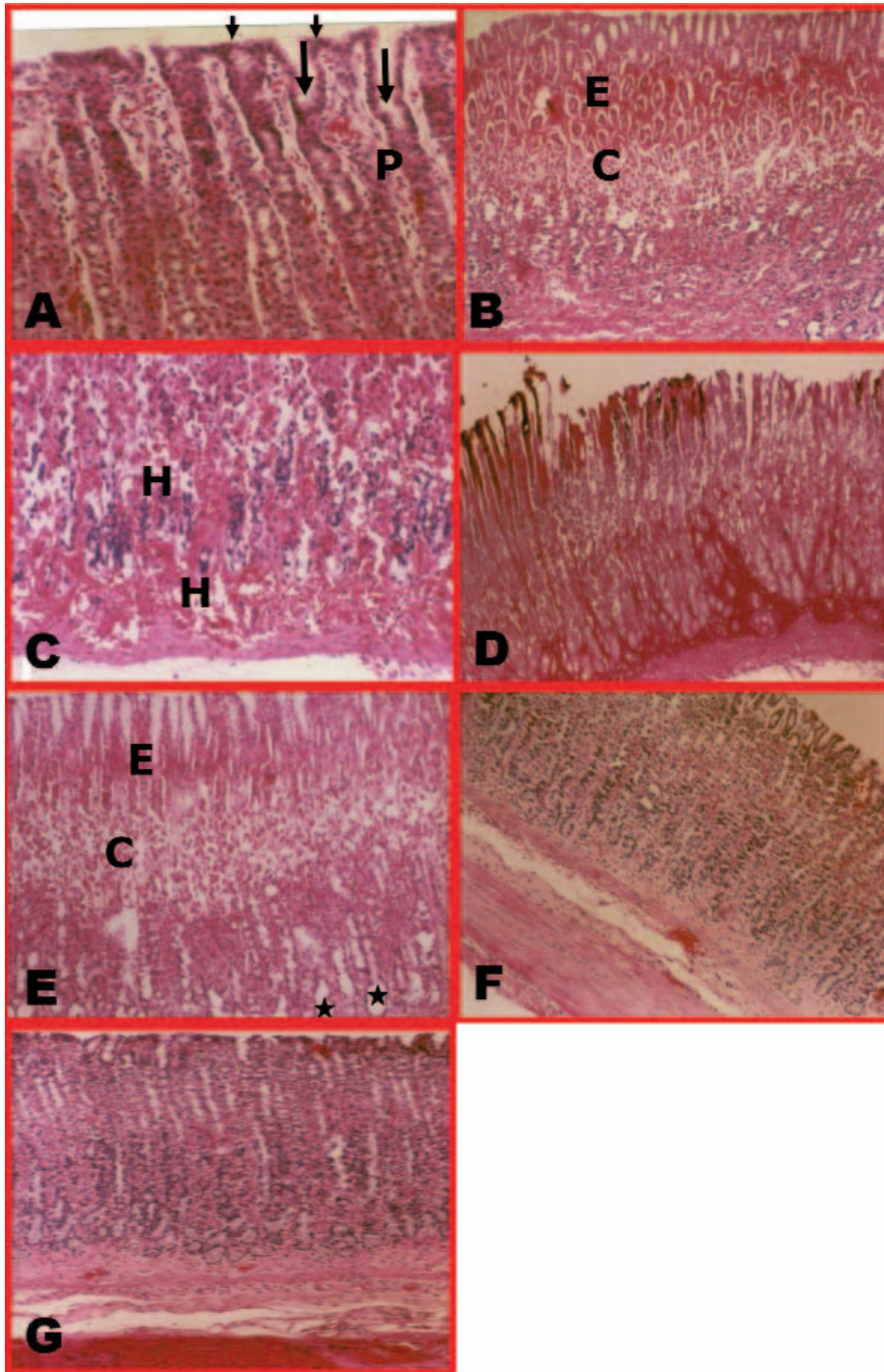


Figure 2. Hematoxylin & eosin (HE) staining of stomach in control (A), ASA (B), ASA+L-NAME (C), ASA+L-Arg (D) and ASA+L-Arg+L-NAME (E), L-NAME (F), and L-Arg (G) treatment rats. A- An appearance in control rat. Picture shows normal gastric mucosa, surface columnar epithelium (short arrows), gastric pits (long arrows) and lamina propria (P) (HE X20). B- An appearance in ASA-treated rats. Mucosal damage, eosinophilic area (E) and clear zone (C) are seen (HE X10). C- An appearance in ASA+L-NAME-treated rats. Mucosal hemorrhage (H) is seen (HE X20). D- An appearance in ASA+L-Arg-treated rats. Mild mucosal superficial damage is seen (periodic-acid Schiff [PAS]-Alcian blue X10). E- An appearance in ASA+L-Arg+L-NAME-treated rats. Eosinophilic area (E), clear zone (C) and dilation of the gastric glands (asterisks) are observed (HE X10). F- An appearance in L-NAME-treated rats, showing normal gastric mucosa (HE X10). G- An appearance in L-Arg-treated rats, showing normal gastric mucosa (HE X10).

Discussion

L-NAME inhibits NO synthesis. In contrast, L-Arg increases NO levels. In our study, it was found that mucosal damage was higher in the ASA+L-NAME than in the one ASA-only administered group. In contrast, mucosal damage was lower in the ASA+L-Arg group. It was also observed that administration of L-Arg or L-NAME alone did not cause any structural impairment. Therefore, it may be concluded that the damage-increasing effect of L-NAME, which is a NOS inhibitor, may have been neutralized by the administration of L-Arg (ASA+L-Arg+L-NAME). Another support for this hypothesis is the result that gastric mucosal damage in the ASA+L-Arg+L-NAME group was close to that observed in the control group.

Although the effect of ASA is supposed to be caused by the decrease in gastric mucosal blood flow and mucus secretion and increase in the back diffusion of the acid (5), the increase of NO level suggests that NO may play an important role in the mucosal pathology caused by ASA. Given that the effects of ASA on the gastrointestinal system are at least partly performed via prostaglandins, there likely exists a relationship between NO and prostaglandins (6). A study by Salvemini et al. (7) has shown that endogenous and exogenous NO increases PGE₂ secretion by direct activation of cyclo-oxygenase (COX) in fibroblasts. In the report in question, they showed that NO markedly increased COX activity. Those authors thought that they might play a key role in the mutual interaction of pro- and anti-inflammatory mediators of NOS and COX enzymes. However, in another study, Ko and Cho (8) found an increase in PGE₂ biosynthesis following the inhibition of NOS in the stomachs of rats. This finding suggests that NO may use some other ways outside of prostaglandins to exert its protective effect on gastric mucosa. It has been proposed that NO has many independent mechanisms to protect gastric mucosa. The increase in the NO level in the ASA group shows that some protective mechanisms have been activated following the ASA administration.

It has been shown that drugs such as indomethacin and ASA damage gastric mucosa by decreasing blood flow. It is known that hemorrhage, erosion and ulcers develop as a result of the decrease in mucosal blood flow. The best known vascular reaction in response to mucosal damage is hyperemia against irritant substances (9). When the mucosa is exposed to an irritant substance the

blood flow increases. This response is initiated by the afferent nerve endings under the epithelium (9). These afferent nerve endings have important functions. With acid infusion from the stomach lumen to the lamina propria, these nerve endings localized in this region are stimulated and these neurons synthesize calcitonin gene related peptide (CGRP) and send it to submucosal arterioles. CGRP causes vasodilatation by stimulating NO secretion and hyperemia following the damage (10). In a study by Holzer et al. (11), the importance of this reactive hyperemia was emphasized and shown with the removal of gastric sensory nerves and increase in the sensitivity of the stomach to damage-causing agents. Consequently, this proves the protective significance of these nerves, vasodilatation and the resulting hyperemia as a defense mechanism. Another study by Qiu et al. (12) showed that the decrease in NO levels decreases blood flow and increases the severity of mucosal damage. The deficiency of NO initially leads to vasoconstriction, followed by vasodilatation, and eventually ischemia-reperfusion-like condition, and in this process, free oxygen radicals play an important role. This study also emphasized that L-NAME increases the damage by decreasing blood flow.

It was shown that neutrophils play an important role in the damage of gastric mucosa as a result of non-steroidal anti-inflammatory drugs (NSAIDs) (13,14). McCafferty et al. (14) showed that gastric damage caused by indomethacin was mostly attenuated in neutropenic rats. Asako et al. (15) also stated that NSAID administration significantly decreased the leukocyte invasion in the endothelium of mesenteric venules.

It was stated that gastric damage may be prevented or at least decreased with the inhibition of neutrophil adhesion (16). Inflammatory cell infiltration in the ASA group was significantly increased in the ASA+L-NAME group in our study. Neutrophil predominance was obvious in cell infiltration. Inflammatory cell infiltration was scarce in the ASA+L-Arg group. Andrews et al. (17) observed that intercellular cell adhesion molecule-1 (ICAM-1) expression increased 30 minutes after ASA and indomethacin administration. On the other hand, gastric mucosa damage was mostly prevented with the administration of antibody against CD18 that is a CAM and NSAID (18). The importance of neutrophils in mucosal damage caused by the administration of NSAID was shown in many studies (18-22). Adhesion of

neutrophils to blood vessels was shown to be prevented by the effect of NO in the studies conducted by Wallace et al. (19) and Davies et al. (22). Kubes et al. (23) observed that adhesion of leukocytes to blood vessels was increased with the inhibition of NO synthesis. Another study stated that the chemotaxis of leukocytes to vessels was inhibited with the administration of NO donor (9). Low damage scores in the ASA+L-Arg group may have been caused by increased synthesis of NO that may finally have prevented the adhesion of neutrophils to vessels.

The fact that NO induces its protective effect by increasing gastric mucus was brought forward by Brown et al. (24), who stated that NO induced increased gastric mucus. Wallace et al. (9) observed that NO increased gastric mucus with the administration of carbachol. These suggest that NO was synthesized in epithelial cells and the cholinergic system was included in the synthesis of NO. NO was also important in the protection of the epithelial barrier. It was observed in our study that both superficial and neck mucus cells were damaged with administration of ASA with periodic acid-Schiff (PAS)-Alcian blue method. Dye properties were not changed in the non-eroded fields.

Increased damage in the ASA+L-NAME group was attributable to the inhibition of NO synthesis. We suggest that inhibition of NO synthesis may have increased damage because NO was an important agent

for protection of gastric mucosa in our study. Gastric NO levels were also in good concordance with our histopathologic results. Increased NO levels in the ASA group were decreased to control levels with the administration of L-NAME and increased with the administration of L-Arg. These results also supported the possible protective effect of NO in prevention of damage caused by ASA. L-Arg increases NO as a NO donor. Administration of L-NAME with L-Arg negated the inhibition of NOS. Administration of L-Arg without the administration of L-NAME increased tissue NO levels.

In conclusion, NO synthesis is inhibited by L-NAME, and stomach tissue NO levels were decreased. Histopathologically, mucosal damage caused by ASA was increased. L-Arg caused a significant increase in NO levels in stomach tissue. L-Arg administration decreased the damage caused by ASA. In addition, L-Arg prevented NOS inhibition by L-NAME. These data suggest that NO donors may increase the mucosal defense and that use of NO donors in combination with NSAID may also be useful in treatment.

Acknowledgements

This study was supported by a grant from İnönü University (2001/53).

References

1. Elliott SN, Wallace JL. Nitric oxide: a regulator of mucosal defense and injury. *J Gastroenterol* 1998; 33: 792-803.
2. Muscara MN, Wallace JL. Nitric Oxide V. Therapeutic potential of nitric oxide donors and inhibitors. *Am J Physiol* 1999; 276: 1313-6.
3. Moncada S, Higgs A, Furchgott R. XIV. International Union of Pharmacology Nomenclature in Nitric Oxide Research. *Pharmacol Rev* 1997; 49: 137-42.
4. Cortas NK, Wakid NW. Determination of inorganic nitrate in serum and urine by a kinetic cadmium-reduction method. *Clin Chem* 1990; 36: 1440-3.
5. Takeuchi K, Yasuhiro T, Asada Y, Sugawa Y. Role of nitric oxide in pathogenesis of aspirin-induced gastric mucosal damage in rats. *Digestion* 1998; 59: 298-307.
6. Wallace JL. Cooperative modulation of gastrointestinal mucosal defense by prostaglandins and nitric oxide. *Clin Invest Med* 1996; 19: 346-51.
7. Salvemini D, Misko TP, Masferrer JL, Seibert K, Currie MG, Needleman P. Nitric oxide activates cyclooxygenase enzymes. *Proc Natl Acad Sci* 1993; 90: 7240-4.
8. Ko JKS, Cho CH. Co-regulation of mucosal nitric oxide and prostaglandin in gastric adaptive cytoprotection. *Inflamm Res* 1999; 48: 471-8.
9. Wallace JL, Miller MJS. Nitric oxide in mucosal defense: a little goes a long way. *Gastroenterology* 2000; 119: 512-20.
10. Whittle BJR. Nitric oxide in gastrointestinal physiology and pathology. In: *Physiology of the Gastrointestinal Tract*. In: Johnson LR, editor. 3rd ed. New York: Raven Press; 1994: 267-94.
11. Holzer P, Pabst M.A. Visceral afferent neurons: role in gastric mucosal protection. *News Physiol Sci* 1999; 14: 201-6.
12. Qiu BS, Pfeiffer CJ, Cho CH. Effects of chronic nitric oxide synthase inhibition in cold-restraint and ethanol-induced gastric mucosal damage in rats. *Digestion* 1996; 57: 60-6.

13. Tarnawski AS, Schmassmann A, Peskar BM. Cyclooxygenase 2 - implications on maintenance of gastric mucosal integrity and ulcer healing: controversial issues and perspectives. *Gut* 2001; 49: 443-53.
14. McCafferty DM, Granger DN, Wallace JL. Indomethacin-induced gastric injury and leukocyte adherence in arthritic versus healthy rats. *Gastroenterology* 1995; 109: 1173-80.
15. Asako H, Kubes P, Wallace J, Wolf RE, Granger DN. Modulation of leukocyte adhesion in rat mesenteric venules by aspirin and salicylate. *Gastroenterology* 1992; 103: 146-52.
16. Elliott SN, Wallace JL. Neutrophil-mediated gastrointestinal injury. *Can J Gastroenterol* 1998; 12: 559-68.
17. Andrews FJ, Malcontenti-Wilson C, O'Brien PE. Effect of nonsteroidal anti-inflammatory drugs on LFA-1 and ICAM-1 expression in gastric mucosa. *Am J Physiol* 1994; 266: 657-64.
18. Wallace JL, McKnight W, Miyasaka M, Tamatani T, Paulson J, Anderson DC et al. Role of endothelial adhesion molecules in NSAID-induced gastric mucosal injury. *Am J Physiol* 1993; 265: 993-8.
19. Wallace JL, Reuter B, Cicila C, McKnight W, Grisham MB, Cirino G. Novel nonsteroidal anti-inflammatory drug derivatives with markedly reduced ulcerogenic properties in the rat. *Gastroenterology* 1994; 107: 173-9.
20. Beck LP, Xavier R, Lu N, Nanda NN, Dinauer M, Podolsky DK et al. Mechanism of NSAID-induced gastrointestinal injury defined using mutant mice. *Gastroenterology* 2000; 119: 699-705.
21. Morise Z, Granger DN, Fuseler JW, Anderson DC, Grisham MB. Indomethacin induced gastropathy in CD18, intercellular adhesion molecule 1, or P-selectin deficient mice. *Gut* 1999; 45: 523-8.
22. Davies NM, Roseth AG, Appleyard CB, McKnight W, Soldato PD, Calignano A et al. NO-naproxen vs. naproxen: ulcerogenic, analgesic and anti-inflammatory effects. *Aliment Pharmacol Ther* 1997; 11: 69-79.
23. Kubes P, Reinhardt PH, Payne D, Woodman RC. Excess nitric oxide does not cause cellular, vascular, or mucosal dysfunction in the cat small intestine. *Am J Physiol* 1995; 269: 34-41.
24. Brown JF, Hanson PJ, Whittle BJR. Nitric oxide donors increase mucus gel thickness in rat stomach. *Eur J Pharmacol* 1992; 223: 103-4.