

## Linear and Whorled Nevoid Hypermelanosis in Trisomy 13

Şengül YÜKSEL<sup>1</sup>  
Serap SAVACI<sup>1</sup>  
Uğur BIÇAK<sup>2</sup>  
Cengiz YAKINCI<sup>2</sup>  
Bülent MIZRAK<sup>3</sup>

**Abstract:** Linear and whorled nevoid hypermelanosis (LWNH) is a reticulate pigmentary disorder with a sporadic occurrence, generally representing a genetic mosaicism. In this case, we describe a two-month-old girl with trisomy 13, who presented with various systemic anomalies such as congenital ventricular septal defect, microcephaly, auricular deformities, flatness of nasal root, overlapping fingers, umbilical hernia, and LWNH. G-banding chromosomal analyses were performed on cultured peripheral blood lymphocytes of the patient and the parents. The karyotype of the patient was 47, XX,+13[100], with no mosaicism. The karyotypes of the parents were normal. To our knowledge, we present the first patient with LWNH in whom full trisomy 13 was confirmed postnatally in cultured peripheral blood lymphocytes.

**Key Words:** Linear and whorled nevoid hypermelanosis, trisomy 13

### Trizomi 13'lü Bir Hastada Linear ve Whorled Nevoid Hypermelanosis

**Özet:** "Linear and whorled nevoid hypermelanosis" (LWNH) genellikle genetik mozaizmi yansıtan, sporadik oluşan bir retiküler pigment hastalığıdır. Bu vakada, konjenital ventriküler septal defekti, çeşitli sistemik anomalileri ve LWNH'si olan trizomi 13'lü iki aylık bir kız hasta sunuldu. Hastanın ve ebeveynlerinin periferik kan lenfosit kültürlerinde G-bantlamalı kromozom analizleri yapıldı. Hastanın karyotipi, mozaizm olmaksızın 47, XX,+13[100] olarak saptandı. Ebeveynlerinin karyotipleri normal idi. Bildiğimiz kadarıyla postnatal olarak periferik kan lenfosit kültüründe tam trizomi 13 saptanan LWNH'li ilk hasta sunulmaktadır.

**Anahtar Sözcükler:** Linear and whorled nevoid hypermelanosis; Trizomi 13

- <sup>1</sup> Department of Medical Biology and Genetics, Faculty of Medicine, İnönü University, Malatya - TURKEY  
<sup>2</sup> Department of Pediatrics, Faculty of Medicine, İnönü University, Malatya - TURKEY  
<sup>3</sup> Department of Pathology, Faculty of Medicine, İnönü University, Malatya - TURKEY

### Introduction

Linear and whorled nevoid hypermelanosis (LWNH) is a sporadic pigmentary anomaly occurring within the first weeks of life, characterized clinically by swirls and streaks of macular hyperpigmentation following the lines of Blaschko without preceding inflammation and atrophy (1). Skin lesions following Blaschko's lines, thought to delineate clones formed from early ectodermal cells, reflect genetic mosaicism. An enormous range of cytogenetic abnormalities has been reported in pigmentary mosaicism, including polyploidy, aneuploidy, chromosomal deletions, insertions and translocations. Underlying chromosomal mosaicism has been demonstrated in only a few published cases with LWNH (2). Pigmentary mosaicism is occasionally associated with systemic abnormalities, particularly central nervous, cardiovascular, musculoskeletal, and ocular systems (3).

Changes in the number or structure of chromosomes are a major cause of congenital anomalies and intellectual impairment. Patau syndrome (trisomy 13) is very rare in live-born babies. Individuals with this chromosomal syndrome have a short lifespan and are rarely seen beyond infancy. Trisomy 13 is the third most common autosomal trisomy at birth, with trisomy 21, followed by trisomy 18, occurring more frequently. Trisomy 13 usually involves a maternal meiotic error of nondisjunction; however, paternal errors do occur. The features of trisomy 13 can be variable, but together can provide important clues that can lead to the diagnosis of this recognizable disorder. Intrauterine growth restriction, along with facial, heart, and limb anomalies, are the most striking features (4).

Received: February 06, 2008  
Accepted: August 27, 2008

#### Correspondence

Şengül YÜKSEL  
Department of Medical Biology  
and Genetics,  
Faculty of Medicine,  
İnönü University,  
Malatya - TURKEY

syuksel@inonu.edu.tr

To our knowledge, this is the first reported case with LWNH pattern and some extracutaneous manifestations accompanied by Patau's syndrome as well as full trisomy 13 confirmed postnatally in cultured peripheral blood lymphocytes.

### Case Report

A two-month-old girl diagnosed as trisomy 13 with typical hyperpigmented skin lesions along Blaschko's lines on her face, body, arms, and legs noted at the age of one week was admitted to our clinic for the evaluation of ventricular septal defect and various systemic anomalies. She was born at 42 weeks of gestation by uncomplicated cesarean delivery because of postmaturity to an 18-year-old mother. There was no parental consanguinity or family history of skin abnormalities. At the age of two months, her weight was 4,000 g (10<sup>th</sup> centile), head circumference 33 cm (<3<sup>rd</sup> centile) and length 53.3 cm (3<sup>rd</sup>-10<sup>th</sup> centile). Physical examination revealed microcephaly, low-set ears, auricular deformities, flatness of nasal root, bulbous nose, micrognathia, high palate, clenched hand, overlapping fingers, umbilical hernia, and limited abduction of hips. Auscultation revealed crepitant rales in lungs and 3/6° systolic murmur on the lower left sternal border. She was moderately dyspneic. The echocardiogram showed cardiomegaly, mesocardia, ventricular septal defect, pulmonary stenosis, and dextroposition of the aorta. Thoracic and abdominal ultrasonography, thorax computerized tomography, and

brain magnetic resonance imaging revealed cystic adenomatoid malformation in the left hemithorax, mild hepatomegaly, horseshoe kidney, and corpus callosum hypoplasia. There was no cortical response bilaterally on visual evoked potentials, and brain stem auditory evoked potentials were normal.

The patient had swirled and curved brownish hyperpigmented streaks on her face, body, arms, and legs, which followed Blaschko's lines (Figure 1). The hyperpigmented lesions did not show any surface changes such as hyperkeratosis, papillomatosis, scaling, atrophy or signs of inflammation. Skin punch biopsy demonstrated nevoid hypermelanosis (increased melanocyte count and hyperpigmentation in basal layer and prominent melanocytes) (Figure 2). Microscopic sections from the hyperpigmented area showed increased numbers of melanocytes in the basal layer, though melanin content was not strikingly increased. To compare the melanocyte population, another tissue sample from a normal area was taken and it showed moderate numbers of melanocytes.

G-banding chromosomal analyses of the patient and the parents were performed on cultured peripheral blood lymphocytes. The karyotype of the patient was 47, XX,+13[100], with no mosaicism. The karyotypes of the parents were normal. We could not perform skin fibroblast karyotype analysis due to technical reasons. While the routine studies of the patient were in process, she expired suddenly due to a cardiac arrhythmia.

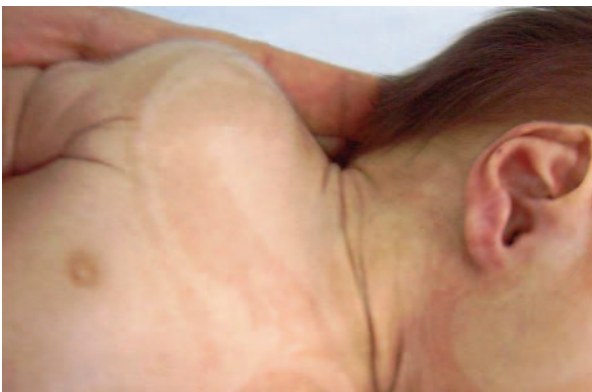

Figure 1. Asymmetrical streaks of linear hyperpigmentation that spread from the face to the neck, shoulders and chest.

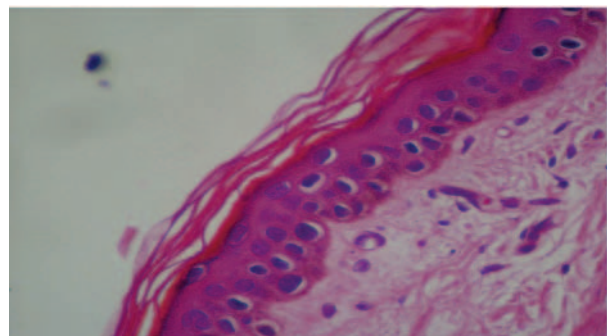


Figure 2. Skin biopsy from a pigmented macula on the leg showing increased melanin content in the basal layer and the prominent melanocytes (hematoxylin and eosin; 400x).

## Discussion

Our patient clinically showed typical trisomy 13 phenotype, and diagnosis was supported cytogenetically from peripheral blood lymphocytes. The diagnosis of LWNH was made according to Kalter's definition (1). However, recent studies in dermatology literature (2) conclude that hypomelanosis of Ito (HI) and LWNH should be grouped together as a heterogeneous collection of disorders indicative of underlying genetic mosaicism in some cases. The most confusing differential diagnosis to LWNH is HI, in which the lesions follow the same pattern and have the same age of onset. LWNH resembles HI in all but the color of the skin markings. The absence of preceding inflammatory disease, asymmetric streaks and whorls following Blaschko lines, delineation of the hyperpigmentation, histologic features, and association of congenital anomalies are very significant in our patient. In hypomelanosis, one helpful finding is that the face, palms, and soles are usually spared and exhibit the individual's normal skin tone. Thus, the lighter skin of the face of our patient was chosen as reference skin and the darker skin regions were therefore considered to be hyperpigmented.

Chromosomal and genetic alterations associated with pigmentary anomalies are quite heterogeneous. Several mechanisms may cause mosaicism with resultant skin areas of hypopigmentation or hyperpigmentation following the lines of Blaschko: Lyonization, chimerism, chromosomal mosaicism, somatic mutations, and half-chromatid mutations (2). Cytogenetic data related to LWNH are sparse. Most reported cases of LWNH are without associated chromosomal abnormalities, suggesting that LWNH is a distinct entity that is not associated with chromosomal mosaicism (3). A few cases of LWNH with mosaic trisomy have been reported, including trisomy 7, 14, 18, 20 and as well as X-chromosomal mosaicism (2), but the number of cases reported with chromosomal abnormalities is fewer than in HI. Hyperpigmentation along Blaschko lines has also been described in children with Down syndrome (3).

A few cases of HI and phylloid pigmentary pattern are associated with mosaic or translocation trisomic 13 (5-8).

Only Tunca et al. (9) reported hyperpigmented areas on the neck and axillary line with some scarring secondary to recurrent folliculitis in a case of full trisomy 13 in blood lymphocytes and skin fibroblasts, with long-term survival (>27 years). This patient also had revealed hyperpigmented areas similar to areas sometimes seen in patients with certain types of chromosomal mosaicism such as Pallister-Killian syndrome. In addition, their patient had many skin infections. In all instances, abnormal lymphocyte karyotypes with chromosomal mosaicism of lymphocyte and skin fibroblasts, either in combination or separately, were discovered. One of the limitations of this study is that karyotyping was done only on cultured peripheral blood lymphocytes. We thus can not be sure whether somatic or non-somatic chromosomal mosaicism existed in the skin of this patient. Although we could not take a biopsy from her skin, it is plausible that the chromosomal abnormalities were present among the cells on the body, and caused the congenital anomalies. Further, it is possible that our patient's pigmentary mosaicism may be associated with the trisomy 13 genetic trait. The etiopathogenesis of LWNH is still unclear, given that a variety of different karyotypes should result in a similar linear dyspigmentation, since the control of pigmentation is certainly complex and polygenic. Such genes map to different regions or multiple chromosomes. Alteration of genes involved in the production of pigmentation may be one mechanism involved in the pathogenesis of the pigmentary dysplasia seen in LWNH patients (10). This molecular heterogeneity correlates with the wide spectrum of clinical phenotypes observed. To better understand the relation between LWNH and trisomy 13, further studies with a large number of cases are required.

In conclusion, we report herein a case of LWNH, which was associated with systemic abnormalities. However, the abnormal pigmentation became the main clue as to the genetic etiology of her complex phenotype. To our knowledge, she is the only case reported with the characteristic findings of LWNH in whom full trisomy 13 was confirmed postnatally in cultured peripheral blood lymphocytes.

**References**

1. Kalter DC, Griffiths WA, Atherton DJ. Linear and whorled nevoid hypermelanosis. *J Am Acad Dermatol* 1988; 19: 1037-44.
2. Di Lernia V. Linear and whorled hypermelanosis. *Pediatr Dermatol* 2007; 24(3): 205-10.
3. Pinheiro A, Mathew MC, Thomas M, Jacob M, Srivastava VM, Cherian R et al. The clinical profile of children in India with pigmentary anomalies along the lines of Blaschko and central nervous system manifestations. *Pediatr Dermatol* 2007; 24(1): 11-7.
4. Collinsworth A, Lacassie Y. An unusual presentation of trisomy 13. *Am J Med Genet A* 2008; 146A(11): 1490-2.
5. Yakinci C, Kutlu NO, Alp MN, Senol M. Hypomelanosis of Ito with trisomy 13 mosaicism [46, XY, der (13;13) (q10;q10), +13/46,XY]. *Turk J Pediatr* 2002; 44: 152-5.
6. Happle R. Phylloid hypomelanosis is closely related to mosaic trisomy 13. *Eur J Dermatol* 2000; 10(7): 511-2.
7. Pillay T, Winship WS, Ramdial PK. Pigmentary abnormalities in trisomy of chromosome 13. *Clin Dysmorphol* 1998; 7(3): 191-4.
8. Fogu G, Maserati E, Cambosu F, Moro MA, Poddie F, Soro G et al. Patau syndrome with long survival in a case of unusual mosaic trisomy 13. *Eur J Med Genet* 2008;51(4): 303-314.
9. Tunca Y, Kadandale JS, Pivnick EK. Long-term survival in Patau syndrome. *Clin Dysmorphol* 2001; 10: 149-50.
10. Taibjee SM, Bennett DC, Moss C. Abnormal pigmentation in hypomelanosis of Ito and pigmentary mosaicism: the role of pigmentary genes. *Br J Dermatol* 2004; 151(2): 269-82.