

## PRIMARY LUNG BULLAE AND SCUBA DIVING

Graham Simpson

### Key Words

Case reports, fitness to dive, medical conditions and problems, pulmonary barotrauma, resort diving, treatment.

### Summary

Three cases are described where unsuspected congenital lung bullae led to diving accidents. In two cases the bullae ruptured causing spontaneous pneumothorax and in the third a tension bulla led to symptoms. All incidents occurred on introductory "resort" dives. The implications with regard to fitness to dive medicals are discussed.

### Introduction

Current Australian standards for diving medicals lay considerable emphasis on detection of conditions that may cause air trapping because of the potential risk of barotrauma. Attention is generally concentrated on the presence or absence of airflow limitation and particularly asthma, although the evidence that asthmatics are actually at greater risk of barotrauma is hard to find and the objections are largely based on theoretical considerations. Standards for recreational scuba diving do not mention bullous disease, although this is mentioned in the Australian Standard AS1299 (1992) for underwater workers for whom a chest radiograph is mandatory. I report three patients with asymptomatic primary bullous disease who all developed life threatening complications of their lung bullae on "resort" scuba dives.

### Case 1

A 19 year old Canadian tourist was admitted to hospital as an emergency. He gave no past history of asthma or any respiratory symptoms and was normally fit and well. He is a lifelong non-smoker. Earlier on the day of admission he had performed two resort scuba dives. The first dive was to 10 m for 20 minutes and he had no problems. His second dive was to 6 m for 30 minutes. On ascent he felt tightness in his throat and after surfacing was aware of some alteration of his voice quality. On examination he had surgical emphysema at the root of the neck and his chest radiograph confirmed a small right apical pneumothorax with some mediastinal emphysema. There were no signs of cerebral arterial gas embolism or any other decompression illness. The chest radiograph (Figure 1) also shows a large thin walled bulla in the right upper lobe containing a small amount of fluid. He was treated with 100% oxygen overnight and by the following morning his symptoms had improved and he was discharged.

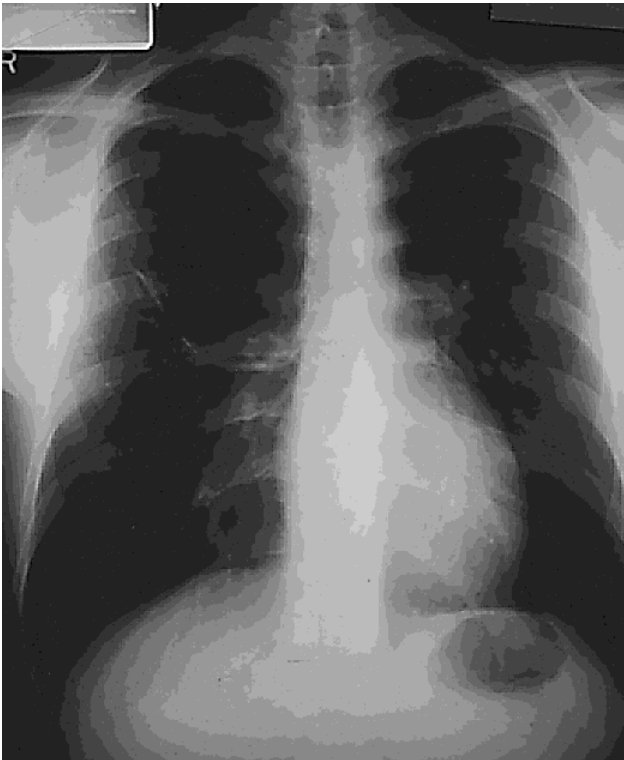Follow up x-ray one week later showed complete resolution of the pneumothorax, but persistence of the right upper lobe bulla. He flew home to Canada one week later without incident.

### Case 2

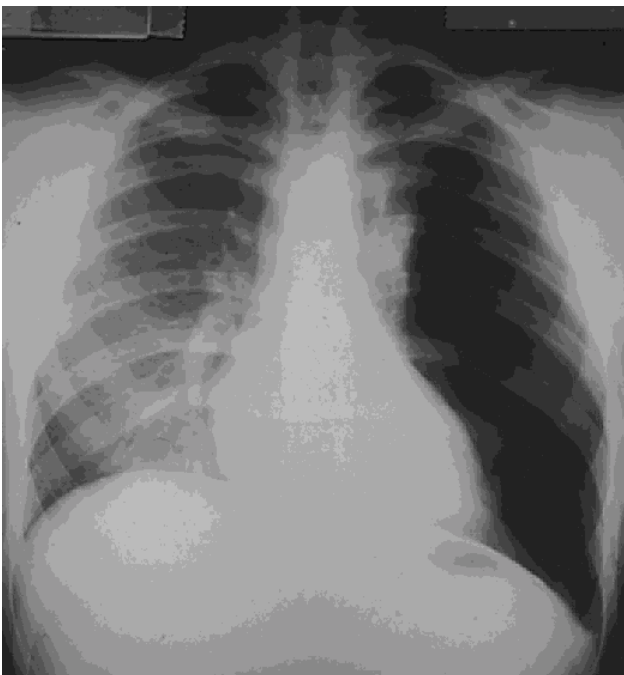
A 19 year old English tourist with no past history of cigarette smoking, asthma or other respiratory problems presented to a general practitioner one day after doing two resort scuba dives. He had never dived before. His first dive was to 10 m with a bottom time of 15 minutes and he experienced no problems. He enjoyed the experience so much he had a second dive again to 10 m, but for this time for around 20 minutes. He did a safety stop at 3 m for five minutes and then ascended to the surface. As he came up he developed pain in the left side of his chest which he described as more of a pressure than a sharp pain, but he did get some discomfort on taking a deep breath. He had no other symptoms. The general practitioner sent him for a chest radiograph which was reported by a consultant radiologist as showing a large left pneumothorax and he was referred for a specialist opinion regarding insertion of an intercostal drain. On examination he did have diminished, but not absent breath sounds over the left hemithorax and his chest x-ray (Figure 2) is more in keeping with a giant bulla than a pneumothorax. He was admitted to hospital and treated with 100% oxygen. A CT scan of the chest confirmed that he had a very large bulla occupying most of the left upper lobe, but which had not ruptured. His symptoms improved overnight. Follow up chest x-ray two weeks later showed no change and he flew back to England without further incident. It seemed likely that his symptoms were related to expansion of the bulla on ascent causing compression of neighbouring structures.

### Case 3

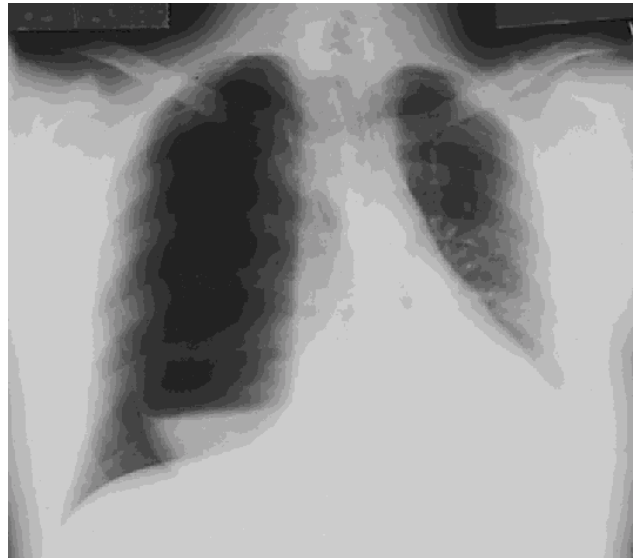A 30 year old English tourist was admitted as an emergency with severe right sided chest pain and breathlessness following his first resort scuba dive. He is a non-smoker with no past history of asthma or other respiratory problems. He had dived to 7 m for 30 minutes. He ascended in a controlled fashion, but as he approached the surface developed pleuritic right sided chest pain and breathlessness. Chest x-ray (Figure 3) showed a right sided pneumothorax and a very large thin walled bulla containing a significant amount of fluid, presumably blood. As he was significantly breathless it was decided to insert an intercostal drain. Because of the danger of puncturing the bulla this was done after a CT scan of the chest. This confirmed almost complete collapse of the lung and the presence of a large bulla in the right upper lobe. The bulla had however, deflated considerably compared with its appearance on the chest x-ray performed some hours earlier. The pneumothorax resolved and follow up x-rays



**Figure 1.** Chest radiograph (Case 1) showing small right apical pneumothorax with mediastinal emphysema and a large bulla in the right upper lobe.



**Figure 2.** Chest radiograph (Case 2) showing giant bulla in left upper lobe but no pneumothorax.



**Figure 3.** Chest radiograph (Case 3) showing large right pneumothorax with giant right upper lobe bulla containing fluid.

confirmed the persistent bulla in the right upper lobe. Unfortunately this became infected and was later resected at thoracotomy. He was allowed to fly home two weeks later.

### Discussion

Large bullae occurring in the lung in the absence of any other lung disease are not infrequent, though there seems to be no information as to the exact prevalence in the normal population.<sup>1</sup> They are more frequent in patients with Marfan's syndrome and Ehlers-Danlos syndrome with a prevalence around 10% in both conditions.<sup>2,3</sup> However, in the absence of other pathology most bullae do not cause any symptoms. The mechanism of formation of primary bullae is not understood. In order to remain air containing they obviously have to communicate with the tracheo-bronchial tree, but ventilation of these bullae is often poor and, on ascent from a scuba dive, there must be a considerable risk of expansion of the bulla with risk of rupture. This is not inevitable, as I have seen one Japanese diving instructor who was found to have a large apical bulla after successfully completing over 150 dives without any problem.

All three patients in this series presented to one practitioner over a three year period in a single centre and the problem may therefore be a significant one. All developed problems during resort dives which do not involve any pre-dive medical assessment. However, in none of these cases would the standard SPUMS medical for recreational scuba diving have detected the problem.

Although all of these instances took place on introductory resort dives where the diver had not undergone any training before diving there was no suggestion in any case that any of these divers had held their breath on ascent and increased the potential for barotrauma. It may be that there is a case to be made for a plain chest radiograph to be included in all diving medicals. It seems at least possible that a routine chest radiograph would prevent more diving accidents than the bronchial provocation testing which is so widely performed and for which the justification is entirely theoretical. Plain chest radiographs however, do not detect bullae reliably<sup>4</sup> though films taken at full expiration are more sensitive.<sup>1</sup>

One final point concerns Case 2 where symptoms were caused by acute enlargement of the giant bulla on ascent rather than rupture causing pneumothorax. Giant bullae can easily be confused with a pneumothorax, but insertion of a chest drain in these circumstances is exceedingly hazardous and is very likely to lead to broncho-pleural fistula and necessitate thoracic surgery. Unless the patient is *in extremis* intercostal drains should not be inserted into pneumothoraces before specialist advice is obtained.

## References

- 1 Fraser RG, Paré JAP, Paré PD, Fraser RS and Genereux GP. *Diagnosis of Diseases of the Chest. Vol. III. 3<sup>rd</sup> Edition.* Philadelphia: W.B. Sanders Company, 1990
- 2 Wood JR, Bellamy D, Child AH and Citron KM. Pulmonary disease in patients with Marfan's Syndrome. *Thorax* 1985; 40: 300-5
- 3 Ayres JG, Pope FM, Reidy JF and Clark TJH. Abnormalities of the lungs and thoracic cage in the Ehlers-Danlos Syndrome. *Thorax* 1985, 40, 300-5.
- 4 Laws JW and Heard BE. Emphysema and the chest film: a retrospective radiological and pathological study. *Brit J Radiol* 1962; 35: 750-6

*Dr F. G. Simpson, MD, FRACP, is Director of Thoracic Medicine, Cairns Base Hospital and Clinical Associate Professor, University of Queensland. His address is 130 Abbott Street, Cairns, Queensland 4870, Australia. Phone +61-7-4031-4095, fax +61-7-4051-8411. E-mail marjo@iig.com.au .*

## UHMS ANNUAL MEETINGS 1998 AND 1999

The UHMS annual meeting for 1998 will be in Seattle from 20th-24th May. This date was chosen so that UHMS could meet with the Aerospace Medical Association.

The 1999 meeting will either be in Boston or Philadelphia in June or July.

For further details contact

Undersea and Hyperbaric Medical Society  
10531 Metropolitan Avenue, Kensington  
Maryland 20895-2627, USA.  
Phone +1-301-942-2980  
Fax +1-301-942-7804  
URL = <http://www.uhms.org>

## IN-WATER RECOMPRESSION A SYMPOSIUM AND WORKSHOP

Sunday, May 24, 1998 Memorial Day Weekend  
at the

Seattle Sheraton Hotel  
Washington, USA.

Registration: \$125.00  
(Workshop Proceedings \$20.00)

For further information contact  
Jane Dunne

UHMS Headquarters  
10531 Metropolitan Avenue, Kensington  
Maryland 20895-2627, USA.  
Telephone +1-301-942-2980, Ext. 102

This interesting subject is now under scientific scrutiny. The Undersea and Hyperbaric Medical Society (UHMS) is hosting a symposium and workshop to be held in conjunction with the 1998 UHMS Annual Meeting in Seattle, Washington, USA. This event is co-chaired by Drs Merrill Spencer and Edmond Kay and is open to the public. Internationally known experts in Diving and Hyperbaric Medicine will address the issues of how and why a diver might accomplish In-Water Recompression (IWR). A crucial question to be addressed is when the benefits of early recompression outweigh the risks of this inherently difficult and sometimes dangerous procedure. The workshop objectives are to provide the Society and the diving community with guidelines for proper use including indications, triage, support, risks, benefits and contraindications to the use of IWR. The workshop is dedicated to Dr Ed Beckman and his pioneering work in IWR and early recompression.

To register for the IWR Workshop visit our web site and print out a "Fax Pre-Registration Form".

<http://weber.u.washington.edu/~ekay/IRW.html>