

Seckel Syndrome with Spontaneous Chromosomal Instability

Abdulgani TATAR¹
Zeynep OCAK¹
Hakan DONERAY²
Ergin IŞIK³
Ahmet YEŞİLYURT¹
Behzat ÖZKAN²
Sırtki ÖZTAŞ¹

Abstract: Seckel syndrome is an autosomal recessive disorder characterized by prenatal and postnatal growth retardation, bird-headed face and mild mental retardation. It is a disorder involving the DNA damage-response genes. Failure in the DNA damage response and repair process can cause chromosomal instability. In addition, it is possible that there are several loci responsible for this syndrome, and variety in the molecular pathogenesis is the cause of phenotypic heterogeneity. Three different loci have been reported thus far. The effect of the locus with mutation on phenotype may be used in the subgrouping of Seckel syndrome. We report a case with Seckel syndrome having spontaneous chromosomal instability. The patient had no hematologic or malignant disease although there was a severe chromosomal instability. To date, spontaneous chromosomal instability has been reported in two cases with Seckel syndrome.

Key Words: Seckel syndrome, chromosomal instability, chromosomal breakage syndrome

Spontan Chromosomal İnstabilitesi Olan Bir Seckel Sendromu

Özet: Seckel sendromu nabir bir otozomal resesif bozukluktur. Bu hastalarda prenatal ve postnatal büyüme geriliği, kuş kafası yüzü, mental retardasyon ve iskelet sistemi bozuklukları görülür. Bu vaka takdiminde spontan kromozomal instabilitesi olan bir Seckel sendromu hastasını rapor ettik. Hastada ileri derecede chromosomal instabilite olmasına rağmen hematolojik ve malignite açısından herhangi bir bulguya rastlanılmadı. Spontan kromozomal instabilite iki Seckel sendromu vakasında rapor edilmiştir.

Anahtar Sözcükler: Seckel sendromu, kromozomal instabilite, kromozomal kırık sendromu

Introduction

Seckel syndrome (MIM 210600) is a rare autosomal recessive disorder associated with short stature, prenatal and postnatal growth retardation, characteristic facial features (bird-headed face including prominent beaked nose, micrognathia and malformed ears), mental deficiency, microcephaly, and skeletal defects (1). Hematological abnormalities, including pancytopenia, myelodysplasia and acute myelogenous leukemia, have been reported in some patients with Seckel syndrome (2).

Because of the phenotypic heterogeneity, the diagnosis is difficult. In fact, a majority of the reported cases are suspected as not being real Seckel syndrome (3). Some diseases such as Nijmegen breakage syndrome, osteodysplastic primordial dwarfisms (types I, II and III) and Dubowitz syndrome can mimic Seckel syndrome.

Although Seckel syndrome is a chromosomal breakage syndrome, chromosomal breakage is generally shown by mitomycin-C (MMC) induction. Spontaneous chromosome breakage is very rare. Only two cases with pancytopenia have been reported to date (4,5).

Here, the case of a four-year-old female patient with Seckel syndrome involving spontaneous chromosomal breakage is reported.

Case Report

A four-year-old female patient was referred because of severe growth retardation and microcephaly. She was born to a consanguineous marriage (second-degree cousins)

¹ Department of Medical Genetics,
Faculty of Medicine,
Atatürk University,
Erzurum - TURKEY

² Department of Pediatric
Endocrinology, Faculty of Medicine,
Atatürk University,
Erzurum - TURKEY

³ Faculty of Medicine,
Atatürk University,
Erzurum - TURKEY

Received: September 04, 2007

Accepted: January 04, 2008

Correspondence

Abdulgani TATAR
Department of Medical Genetics,
Faculty of Medicine,
Atatürk University,
25240 Erzurum - TURKEY

abdulgani@atauni.edu.tr

in the 8th month of gestation after an uncomplicated pregnancy. Her birth weight, height and head circumference were 1200 g (-3.17 SD), 40 cm (-3.66) and 29 cm (-2.63), respectively.

The ages of her mother and father were 32 and 36 years, respectively. They also had two other healthy children. The mother had a history of eight miscarriages without a known cause and reported no exposure to any physical or chemical agents during all pregnancies.

In the physical examination of the patient, height, weight, and head circumference were 82 cm (-4.6 SD), 10 kg (-3.5) and 45 cm (-3.9), respectively. Microcephaly, a receding forehead, ptosis in the left eye, a beaked nose, large low-set ears, micrognathia, and hypoplastic mandible were noted (Figure 1a-b). The laboratory studies revealed no hematological or endocrinological abnormalities. Brain computed tomography (CT) and abdominal ultrasonography (USG) results were normal. The X-ray of the patient's spine showed mild thoracic kyphosis.

Cytogenetic analyses of peripheral blood were performed using standard procedures (6). In non-induced cultures, the examination of preparations stained by GTG-banding revealed normal karyotype in 12 (15%) of 80 metaphases analyzed. In the other 68 (85%) metaphases, numerical and/or structural chromosomal abnormalities

such as deletions, duplications, acentric chromosomes and dicentric chromosomes were detected (Figure 2a-b and Table 1). These abnormalities were not specific to any chromosome. Karyotype analyses were intermittently repeated three times, and severe spontaneous chromosomal instability was detected in all of them. The patient had not received any drug or been exposed to any toxic agent before cytogenetic analysis. The data of the final culture studies are provided in Table 1. In the MMC-induced cultures, 82 metaphases were analyzed and no numerical or structural chromosomal abnormalities were detected in 9 (11%) of them. The remaining 73 (89%) metaphases had various chromosomal aberrations. The rate of chromosome breaks increased in the MMC-induced cultures (Table 1). Additionally, in the induced cultures, the number of chromosomal aberrations in a metaphase was higher than in the non-induced cultures. During cytogenetic analyses of the patient, five healthy control individuals were used and an average of 80 metaphases per control case were analyzed. Karyotype analyses of parents were normal.

Discussion

Seckel syndrome is distinguished from Nijmegen breakage syndrome, Dubowitz syndrome and microcephalic osteodysplastic dwarfisms (types I, II, III)

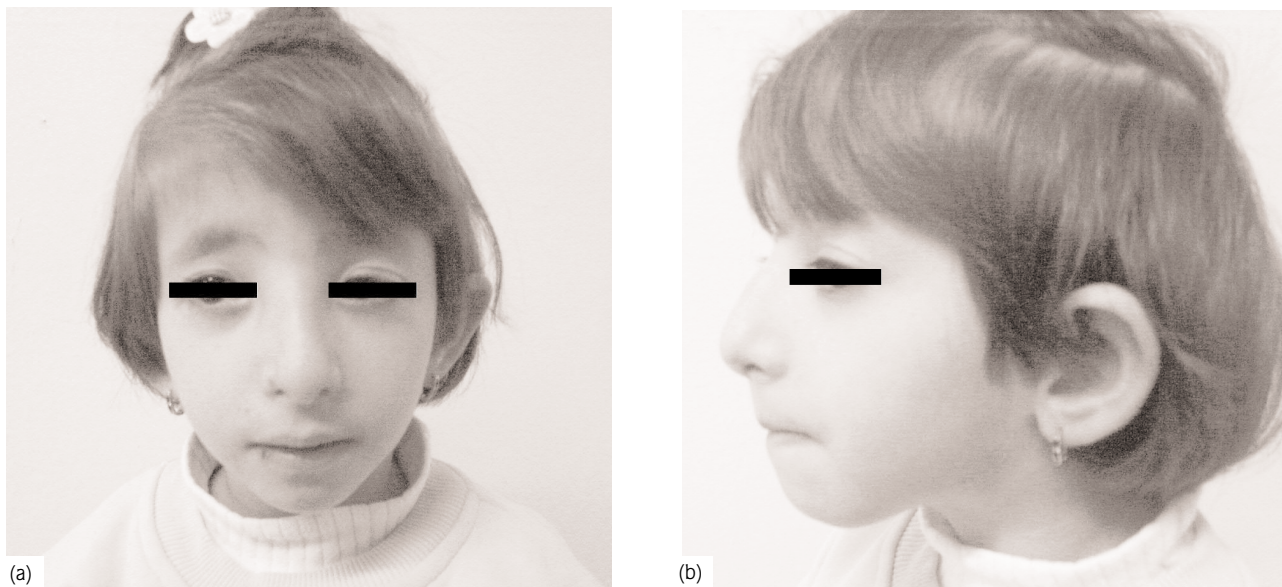


Figure 1. (a) Facial appearance of the patient with ptosis in left eye and bird-headed face.
(b) Facial appearance of patient with large low-set ears, micrognathia, and beaked nose.

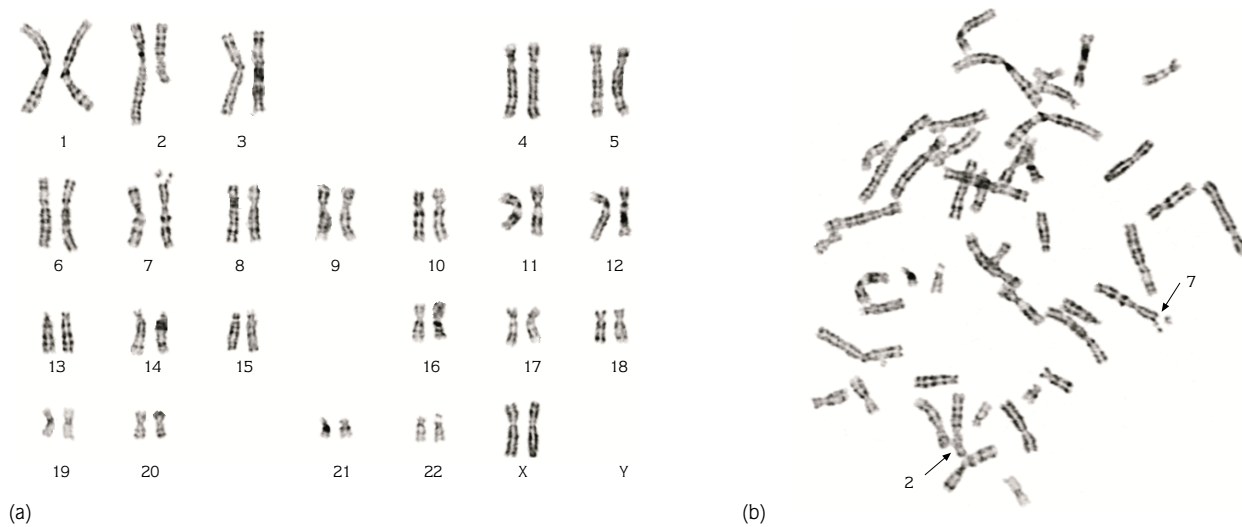


Figure 2. Samples of karyotype and metaphase of the patient:

(a) Chromosome 2 with del (q23-qter), chromosome 7 with breakage at p22 and chromosome 6 with a chromatid breakage are shown in karyotype.

(b) Chromosome 2 with deletion and chromosome 7 with chromosomal breakage are marked.

Table 1. Results of cytogenetic analyses of the patient and five control individuals. The results were given as the rate of metaphases with chromosomal aberration to the metaphases examined.

Chromosomal aberration	Spontaneous		Induced with MMC	
	Pt (%)	Controls (%)	Pt (%)	Controls (%)
Marker chromosome	64	0	69	0
Monosomy	42	0	67	1
Trisomy	4	0	1	0
Deletion	35	2	49	0
Duplication	10	0	11	0
Acentric chromosome	4	0	1	0
Pericentric inversion	1	0	0	0
Chromosome breakage	27	4	42	1
Chromatid breakage	8	2	8	1
Dicentric chromosome	2	0	6	0

by clinical, laboratory and radiological findings, although they share some similar features. Nijmegen breakage syndrome has additional clinical features such as radiosensitivity and immunodeficiency (7), neither or which was present in our patient. Types of microcephalic osteodysplastic dwarfism (types I, II, III) were ruled out by radiological findings and Dubowitz syndrome by bird-headed face. Dubowitz syndrome may also include infantile eczema, peculiar facies, short palpebral fissures,

ocular abnormalities, and immunodeficiency, but the patient had none of these.

In Seckel syndrome, chromosomal aberrations are reported as chromosome and chromatid breaks (8). The chromosomal abnormalities, which were detected at a high rate in our patient, were also based on the extreme chromosome breaks. The translocation type of rearrangements could not be detected.

New clinical findings have been added to Seckel syndrome since it was first reported by Seckel (1,9,10). Butler et al. (5) (1987) proposed a subgroup for Seckel syndrome. They took hematological and chromosomal abnormalities into consideration, which was supported by some authors in the following years (11). Syrrou et al. (12) (1995) reported three cases with Seckel syndrome having chromosomal instability, one of whom developed hematological disorder. Chanan-Khan et al. (2) (2003) reported a case having hematological disorder without chromosomal instability, but the hematological disorder was not persistent. Neither hematological disorder nor malignancy was detected in our patient despite severe spontaneous chromosomal instability. Thus, it was concluded that chromosomal instability may not always be accompanied by a hematological disorder, and chromosomal instability can not be related to hematological pathologies. In light of this, it can be said that chromosomal and hematological abnormalities may not be reliable for subgrouping.

Bobabilla-Morales et al. (11) (2003) proposed taking chromosome aberrations, in particular, into account for subgrouping. However, chromosomal aberrations have usually been shown as chromosome breaks by MMC induction, and they have not been related to phenotype (5). Although chromosomal rearrangements may badly affect patient prognosis, it has not been observed in patients with Seckel syndrome until now. In our patient, even though chromosomal instability had persisted for one year, prognosis of the patient was better than expected. On the contrary, Woods et al. (4) (1995) reported a case with spontaneous chromosomal instability, and the patient died at the age of 16 months probably because of pancytopenia.

Seckel syndrome is a disorder involving the DNA damage-response genes. Failure in the DNA damage response and repair process can cause chromosomal

instability. In addition, it is possible that there are several loci responsible for this syndrome and variety in the molecular pathogenesis is the cause of phenotypic heterogeneity (1). So far, three different loci have been reported: Goodship et al. (7) (2001) assigned the first locus (SCKL1) to chromosome 3q22.1-q24; Borglum et al. (13) (2001) assigned the second locus (SCKL2) to chromosome 18p11.31-q11.2, and Kilinc et al. (14) (2003) assigned the third locus (SCKL3) to chromosome 14q23. The effect of the locus with mutation on phenotype may be used in the subgrouping of Seckel syndrome. For proper subgrouping, the relationship between the defective locus and findings of the patient should be determined (15). The wide range of phenotypic features decreases the importance of phenotype for subgrouping; therefore, more effective criteria are necessary. When data of molecular analysis are increased and the relationship between molecular pathology and phenotype is demonstrated, the locus heterogeneity may be used in subgrouping. However, the use of this relationship will undoubtedly not be easy because the number of the genes responsible for the mechanism of DNA repair is high, and these genes play a role in Seckel syndrome.

At present, while there are problems in the differential diagnosis of Seckel syndrome and the number of patients is insufficient, undertaking subgrouping may not be approved, and this type of subgrouping may not be useful in estimating the prognosis of the patient.

To our knowledge, two cases with spontaneous chromosomal breakage have been reported until now, and these patients had pancytopenia (4,5). In contrast, no hematological pathology was detected in our patient. However, it is vital that the patients with Seckel syndrome be followed throughout their life considering the possibility of hematological and malignant diseases.

References

1. Faivre L, Merrer ML, Lyonnet S, Plauchu H, Dagoneau N, Campos-Xavier AB et al. Clinical and genetic heterogeneity of Seckel syndrome. *Am J Med Genet* 2002; 112: 379-83.
2. Chanan-Khan A, Holkova B, Perle MA, Reich E, Wu CD, Inghirami G et al. T-cell clonality and myelodysplasia without chromosomal fragility in a patient with features of Seckel syndrome. *Haematologica* 2003; 88: ECR14.
3. Shanske A, Caride DG, Menasse-Palmer L, Bogdanow A, Marion RV. Central nervous system anomalies in Seckel syndrome: report of a new family and review of the literature. *Am J Med Genet* 1997; 70: 155-8.
4. Woods CG, Leversha M, Rogers JG. Severe intrauterine growth retardation with increased mitomycin C sensitivity: a further chromosome breakage syndrome. *J Med Genet* 1995; 32: 301-5.

5. Butler MG, Hall BD, Maclean RN, Lozzio CB. Do some patients with Seckel syndrome have hematological problems and/or chromosome breakage? *Am J Med Genet* 1987; 27: 645-9.
6. Rooney DE, Czepulkowski BH. *Human cytogenetics: a practical approach*. 1st ed. Oxford: IRL Press Ltd; 1986.
7. Goodship J, Gill H, Carter J, Jackson A, Splitt M, Wright M. Autozygosity mapping of a Seckel syndrome locus to chromosome 3q22.1-q24. *Eur J Hum Genet* 2001; 9: 753-7.
8. Casper AM, Durkin SG, Arlt MF, Glover TW. Chromosomal instability at common fragile sites in Seckel syndrome. *Am J Hum Genet* 2004; 75: 654-60.
9. Silengo M, Del Monaco A, Linari A, Lala R. Low birth-weight, microcephalic malformation syndrome in a 46,XX girl and her 46,XY sister with agonadism: third report of the Kennerknecht syndrome or autosomal recessive Seckel-like syndrome with previously undescribed genital anomalies. *Am J Med Genet* 2001; 101: 275-8.
10. Sugio Y, Tsukahara M, Kajii T. Two Japanese cases with microcephalic primordial dwarfism: classical Seckel syndrome and osteodysplastic primordial dwarfism type II. *Jpn J Hum Genet* 1993; 38: 209-17.
11. Bobabilla-Morales L, Corona-Rivera A, Corona-Rivera JR, Buenrostro C, Garcia-Cobian TA, Corona-Rivera E et al. Chromosome instability induced in vitro with mitomycin C in five Seckel syndrome patients. *Am J Med Genet* 2003; 123: 148-52.
12. Syrrou M, Georgiou I, Paschopoulos M, Lolis D. Seckel syndrome in a family with three affected children and hematological manifestations associated with chromosome instability. *Genet Couns* 1995; 6: 37-41.
13. Borglum AD, Balslev T, Haagerup A, Birkebaek N, Binderup H, Kruse TA et al. A new locus for Seckel syndrome on chromosome 18p11.31-q11.2. *Eur J Hum Genet* 2001; 9: 753-7.
14. Kilinc MO, Ninis VN, Ugur SA, Tuysuz B, Seven M, Balci S et al. Is the novel SCKL3 at 14q23 the predominant Seckel locus? *Eur J Hum Genet* 2003; 11: 851-7.
15. O'Driscoll M, Ruiz-Perez VL, Woods CG, Jeggo PA, Goodship JA. A splicing mutation affecting expression of ataxia-telangiectasia and Rad3-related protein (ATR) results in Seckel syndrome. *Nat Genet* 2003; 33: 497-501.