

Münacettin CEVİZ
Necip BECİT
Bilgehan ERKUT
Hikmet KOÇAK

New Replacement of a Thrombosed Mitral Valve via Right Anterolateral Thoracotomy in a Patient with Coronary Artery By-Pass Graft and Functioning Internal Mammary Artery Graft

Abstract: A 49-year-old male, who had undergone mitral valve replacement with mechanical cardiac valve and coronary arterial by-pass grafting six years previously, was admitted to our hospital with acute dyspnea. Transesophageal echocardiography revealed that one of the leaflets of the prosthetic valve was entirely immobilized in the closed position, and an immobile soft tissue mass was detected on the ventricular side of the obstructed leaflet. We performed re-replacement using a 29-mm mechanical prosthetic St. Jude valve under deep hypothermic circulatory arrest via right atrial thoracotomy. Postoperative course was uneventful, and the patient was discharged with oral anticoagulant therapy on day 7 postoperatively.

Key Words: Valvular heart diseases, thrombosed mechanical mitral valve, right thoracotomy, deep hypothermic circulatory arrest

Department of Cardiovascular Surgery,
Faculty of Medicine,
Atatürk University,
Erzurum - TURKEY

Internal Mamarian Arteri Fonksiyone Koroner Arter Bypass Greft Yapılan Bir Hastada Sağ Antero-Lateral Torakotomi ile Tromboze Mitral Kapağın Yeniden Replasmanı

Özet: 6 yıl önce mekanik mitral kapak replasmanı ve koroner arter bypass greft yapılan 49 yaşındaki erkek hasta kliniğimize akut dispne şikayeti ile yatırıldı. Transözefageal ekokardiyografide prostetik kapağın lifletlerinden birinin immobil olduğu tespit edildi. Hastaya sağ atrial torakotomi ile derin hipotermik sirkulatuar arrest altında 29 mm St. Jude mekanik mitral kapak ile yeniden replasman yapıldı. Postoperatif takip olaysız seyretti. Hasta postoperatif 7. günde oral antikoagulan tedavi ile taburcu edildi.

Anahtar Sözcükler: Kalp kapak hastalığı, tromboze mekanik mitral kapak, sağ torakotomi, derin hipotermik sirkulatuar arrest

Received: May 18, 2007
Accepted: November 15, 2007

Introduction

Reoperative mitral surgery via sternotomy may be associated with significant complications, including excessive blood loss and injuries to the heart, great vessels and patent coronary artery grafts. Right thoracotomy is an alternative route and offers the advantage of a fresh surgical field in the context of redo surgery. This approach to mitral valve reoperation minimizes dissection of adhesions, avoids injury to the right ventricle, and prevents damage to arterial and venous coronary by-pass grafts (1).

We describe successful surgery for a thrombosed Sorin Bicarbon mitral valve 6 years following initial mitral valve replacement (MVR) and coronary arterial by-pass grafting (CABG) due to unsatisfactory anticoagulation therapy.

Case Report

A 49-year-old male was admitted to our hospital with acute dyspnea. He had undergone MVR and CABG (left internal mammary artery (LIMA)-left anterior

Correspondence

Bilgehan ERKUT
Atatürk Bulvarı, Eda Apartmanı
Palandoken Tıp Merkezi Üstü
Kat: 3, No: 3
25080 Erzurum – TURKEY

bilgehanerkut@yahoo.com

descending (LAD) artery, aorta-right coronary artery and aorta-circumflex artery with saphenous vein) 6 years previously. Transesophageal echocardiography (TEE) revealed that one of the leaflets of the prosthetic valve was entirely immobilized in the closed position, and an immobile soft tissue mass was detected on the ventricular side of the obstructed leaflet, together with an elevated mean mitral valve pressure gradient and no mitral regurgitation (Figure 1). Angiography revealed that all grafts were patent. We planned surgery under deep hypothermic circulatory arrest (DHCA) because the

patient had patent coronary grafts and especially in situ LIMA. The right anterolateral thoracotomy was created through the fourth inter-space. Arterial inflow was provided by cannulation of the right femoral artery. Venous cannulae were advanced through the right atrium into the superior and inferior vena cava. A coronary sinus cardioplegia catheter was inserted for retrograde cardioplegia. DHCA was established on full flow and with a 16 °C rectal temperature. Cold oxygenated (4 °C) hyperkalemic (30 mmol/L) blood cardioplegia was used for myocardial protection. Cerebral protection during

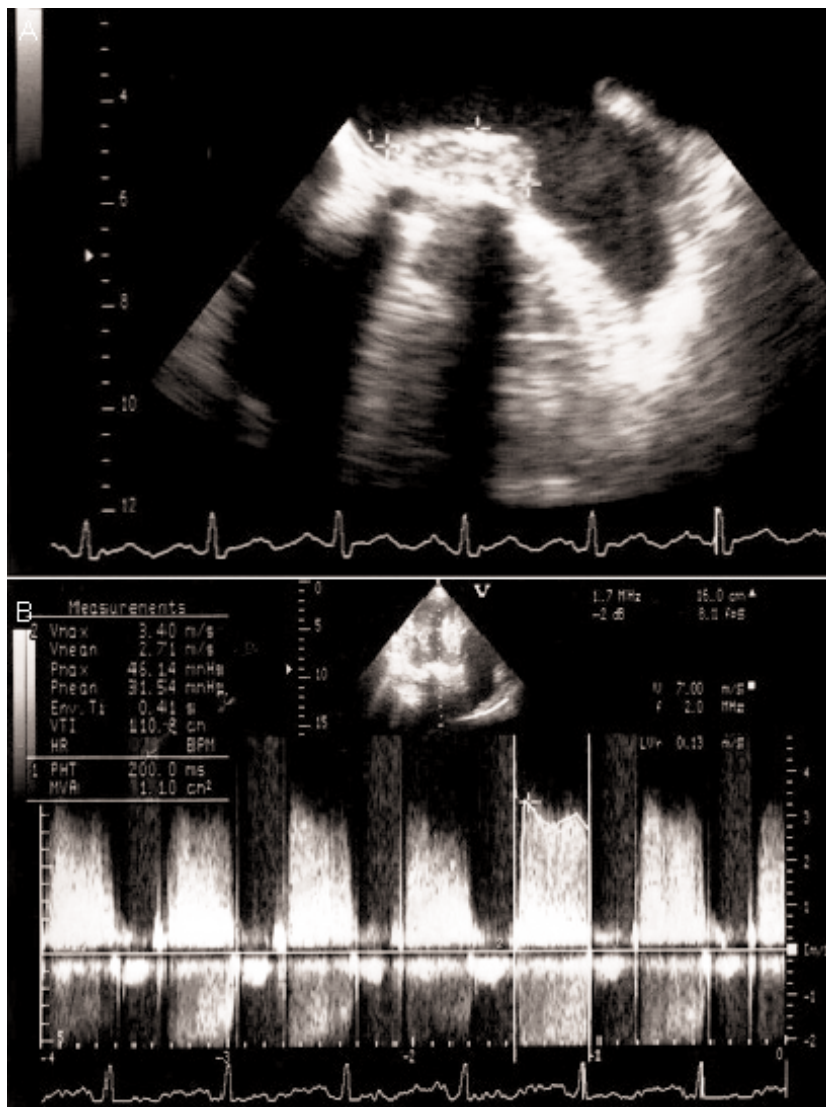


Figure 1. Transesophageal echocardiography revealed prosthetic valve thrombus and elevated mean mitral valve pressure gradient.

surgery was obtained with deep hypothermia (11 °C to 16 °C) and retrograde cerebral perfusion was established through cannulation of the superior vena cava. Left atriotomy was performed. The posterior leaflet of the Sorin Bicarbon valve was obstructed in the closed position with old and fresh thrombi. After total resection, we performed re-replacement with a 29-mm mechanical prosthetic St. Jude medical valve using the separate suture technique. To help eliminate possible air emboli, CO₂ was flooded into the operation field. The DHCA time was 58 minutes and total cardiopulmonary by-pass duration was 112 minutes. Postoperative course was uneventful, and the patient was discharged with oral anticoagulant therapy on day 7 postoperatively.

Discussion

Redo mitral valve surgery after previous CABG presents a challenging problem for the cardiac surgeon. Injury to patent CABG, especially IMA grafts, during re-operation via a redo sternotomy may be fatal. A reliable alternative technique is essential in order to minimize potential injury to IMA grafts in patients with CABG with functioning IMA for redo operations such as mitral valve surgery.

Revisional valve surgery is more complex than primary surgery and is consequently associated with higher mortality and morbidity (2). Re-operative median sternotomy has known risks, including injury to or embolism from prior grafts, sternal dehiscence, phrenic nerve injury, excessive hemorrhage, and inadvertent cardiac injury leading to morbidity and mortality (3). A right anterolateral thoracotomy approach has been used previously in mitral valve re-operations and has well-established benefits (4-6). It has been suggested that this approach is time-saving, safer for emergency procedures on thrombosed or acutely malfunctioning mitral valves and helpful in situations where difficult dissection of the heart would be anticipated or where patent IMA or saphenous vein grafts are present (4,5).

Anterolateral right thoracotomy affords easy access to the right atrium with minimal dissection, and minimizes the risk of injury to IMA grafts. Anterolateral right thoracotomy was used for mitral valve surgery

with DHCA in most patients with CABG in one study by Byrne et al. (5). There was no mortality in their patients, and the technique provided adequate myocardial protection and satisfactory access to the mitral valve for a wide range of replacement procedures. No neurological, peripheral vascular bleeding or wound complications occurred. The authors suggested that re-operative mitral valve surgery in the setting of functioning IMA grafts, even in the face of depressed left ventricle function, can be performed safely and with minimal morbidity (5).

Re-operative mitral surgery via sternotomy may be associated with significant complications, including excessive blood loss and injuries to the heart, great vessels and patent coronary artery grafts. Byrne et al. (6) compared right thoracotomy and direct re-sternotomy in such patients. Two LIMA-LAD graft injuries occurred in the re-sternotomy group compared with none in the right thoracotomy group (20% versus 0%, $P = 0.04$). Transfusion requirements were also greater in the redo sternotomy group (median 7 versus 2 packed red blood cell units, $P = 0.04$). These data suggest that right thoracotomy is associated with a lower incidence of LIMA-LAD graft injury, as well as reduced transfusion requirements for reoperative mitral valve surgery after CABG in the presence of patent LIMA-LAD grafts. Braxton et al. (7) showed that although by-pass time, operative time, intensive care unit stay, and 30-day survival rates were not significantly different between thoracotomy and re-sternotomy, there was a significant reduction in blood loss and blood transfused using the thoracotomy approach for reoperative mitral surgery. In other words, mitral valve re-replacement via right thoracotomy provides a limited requirement for pericardial dissection, avoids injury to the right ventricle, and prevents damage to arterial and venous coronary bypass grafts (1,8). In addition, this procedure reduced both the incidence of LIMA-LAD graft injury and transfusion requirements in patients with CABG with functioning IMA for redo operations in mitral valve surgery.

In conclusion, our experience shows that right thoracotomy with DHCA is a safe alternative in patients with patent LIMA and/or saphenous vein grafts for redo mitral valve surgery.

References

1. Holman WL, Goldberg SP, Early LJ, McGiffin DC, Kirklin JK, Cho DH et al. Right thoracotomy for mitral reoperation: analysis of technique and outcome. *Ann Thorac Surg* 2000; 70: 1970-3.
2. Antunes MJ. Techniques of valvular re-operation. *Eur J Cardiothorac Surg* 1992; 6 Suppl 1: S54-7; discussion S58.
3. Steimle CN, Bolling SF. Outcome of reoperative valve surgery via right thoracotomy. *Circulation* 1996; 94 (9 Suppl): II 126-8.
4. Praeger PI, Pooley RW, Moggio RA, Somberg ED, Sarabu MR, Reed GE. Simplified method for re-operation on the mitral valve. *Ann Thorac Surg* 1989; 48: 835-7.
5. Byrne JG, Aranki SF, Adams DH, Rizzo RJ, Couper GS, Cohn LH. Mitral valve surgery after previous CABG with functioning IMA grafts. *Ann Thorac Surg* 1999; 68: 2243-7.
6. Byrne JG, Karavas AN, Adams DH, Aklog L, Aranki SF, Filsoufi F et al. The preferred approach for mitral valve surgery after CABG: right thoracotomy, hypothermia and avoidance of LIMA-LAD graft. *J Heart Valve* 2001; 10: 584-90.
7. Braxton JH, Higgins RS, Schwann TA, Sanchez JA, Dewar ML, Kopf GS et al. Reoperative mitral valve surgery via right thoracotomy: decreased blood loss and improved hemodynamics. *J Heart Valve Dis* 1996; 5: 463.
8. Thompson MJ, Behranwala A, Campanella C, Walker WS, Cameron EW. Immediate and long-term results of mitral prosthetic replacement using a right thoracotomy beating heart technique. *Eur J Cardiothorac Surg* 2003; 24: 47-51.