

Intussusception due to Inflammatory Fibroid Polyp Located at Ileum: Report of Two Cases

Özgür KORKMAZ¹

Hatice Gülşen YILMAZ¹

Fahri YILMAZ²

Abstract: Inflammatory fibroid polyps are uncommon gastrointestinal tract lesions. The stomach and ileum are the most commonly affected sites. Clinical symptoms depend on the location and size of the lesion. Obstruction or intussusception is the most frequent initial symptom when an inflammatory fibroid polyp is located in the small intestine. We describe two cases of inflammatory fibroid polyps of the small intestine causing ileocecal and ileoileal intussusception.

Key Words: Inflammatory fibroid polyp, intussusception, small bowel

İleum Yerleşimli İnflamatuar Fibroid Polibe Bağlı Gelişen İnvajinasyon: İki Olgu Sunumu

Özet: İnflamatuar fibroid polip, gastrointestinal sistemin nadir görülen lezyonlarından biridir. Sıklıkla mide ve ileumda rastlanır. Klinik semptomlar lezyonun yerleşim ve büyüklüğüne bağlıdır. İnce barsak yerleşimli inflammatuar fibroid polipler sıklıkla obstrüksiyon ve invajinasyon ile bulgu verirler. Bu çalışma ile ince barsak yerleşimli inflammatuar polibe bağlı ileoçekal ve ileoileal invajinasyon tespit edilen iki olgu sunuldu.

Anahtar Sözcükler: İnflamatuar fibroid polip, invajinasyon, ince barsak

¹ Department of General Surgery,
Faculty of Medicine,
Dicle University,
Diyarbakır - TURKEY

² Department of Pathology,
Faculty of Medicine,
Abant İzzet Baysal University,
Bolu - TURKEY

Introduction

Inflammatory fibroid polyp (IFP) is a rare, localized, non-neoplastic lesion originating in the submucosa of the gastrointestinal tract. It is most common in the stomach (1); the small bowel is the second most common site of origin, where it usually presents as intussusception or obstruction. IFP can be found in all age groups, but peak incidence is between the sixth and seventh decades (2). Microscopically, it is a cellular proliferation possibly originating from the submucosa. It is composed of a fibrous and edematous stroma containing many variable-sized blood vessels and a diffuse inflammatory infiltrate, including eosinophils, plasma cells, lymphocytes, macrophages and mast cells (3).

We describe two cases of IFP of the small intestine causing ileocecal and ileoileal intussusception, respectively.

Received: January 30, 2007

Accepted: May 15, 2007

Case Reports

Case 1

A 30-year-old male was admitted to our hospital complaining of vomiting and diarrhea. Physical examination revealed tenderness of the right abdomen, with palpable mass. The white blood cell count was normal. Abdominal X-ray showed dilated small bowel segments. Sonography demonstrated a solid, mobile, homogeneous, echogenic mass surrounded by the typical mural layers of an invaginated ileum. Abdominal computerized tomography (CT) scan demonstrated a typical intussusception complex of a distal jejunal loop, due to a well-rounded, intraluminal, 50-mm soft tissue mass.

Correspondence

Özgür KORKMAZ

Department of General Surgery,
Faculty of Medicine,
Dicle University,
Diyarbakır - TURKEY

ozgur-korkmaz@hotmail.com

Obstruction in the small bowel was suspected, and exploratory laparotomy was performed revealing a solid mass partially obstructing the ileal lumen. Segmental resection of the obstructed ileal segment and ileocecal anastomosis were performed. Macroscopically, the resected ileal segment was 10x4x4 cm in diameter. After opening the lumen, a solid, cylindrical-shaped 3x2x2cm mass projecting into the lumen was found. The resected polyp had histologic findings of an IFP (Figure 1).

Case 2

A 60-year-old woman presented with acute abdominal pain and vomiting. Physical examination revealed rebound and tenderness at the left abdomen, with no palpable mass. She had hyperactive bowel sounds. Laboratory studies showed elevated white blood cell count (1300 mm³). Abdominal X-ray showed dilated small bowel segments. Sonography and abdominal tomography scan demonstrated dilated small bowel segments. Obstruction in the small bowel was suspected, and exploratory laparotomy was performed revealing an invagination completely obstructing the ileal lumen. Segmental resection of the obstructed ileal segment and end to end anastomosis were performed. Macroscopically, the resected ileal segment was 15x5x4.5 cm in diameter. After opening the lumen, a solid, cylindrical-shaped

4x2.5x2cm mass projecting into the lumen was found (Figure 2). The resected polyp had histologic findings of an IFP.

Discussion

Inflammatory fibroid polyp is a benign gastrointestinal tumor that appears grossly as a localized, submucosal, sessile polypoid mass, occasionally involving the entire thickness of the gastrointestinal tract wall. IFP was first described by Vanek (4) in 1949 as “gastric submucosal granuloma with eosinophilia”, and a variety of names, such as eosinophilic granuloma, hemangiopericytoma, polypoid fibroma, gastric fibroma with eosinophilic infiltration, eosinophilic gastroenteritis, polyp with eosinophilic granuloma and inflammatory pseudotumor, are synonymous for the same lesion (5). The stomach is the most commonly involved location, and most gastric lesions are located in the antrum along the lesser and greater curvatures (1). It occurs less frequently in the distal ileum and very rarely in the colon, jejunum, duodenum, and esophagus. IFP can be found in all age groups, but peak incidence is between the sixth and seventh decades (2). Since we report only two patients (older female, younger male), we cannot comment on age and gender distribution.

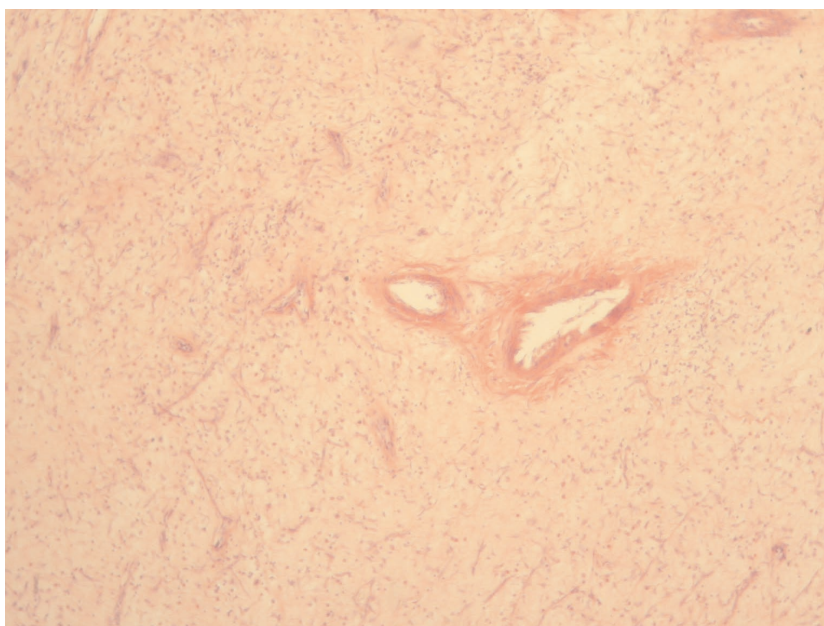


Figure 1. Histology reveals a fibrous polyp in the small intestine. Inflammatory cell infiltration in edematous, fibrous and vascular stroma of the polyp is seen.

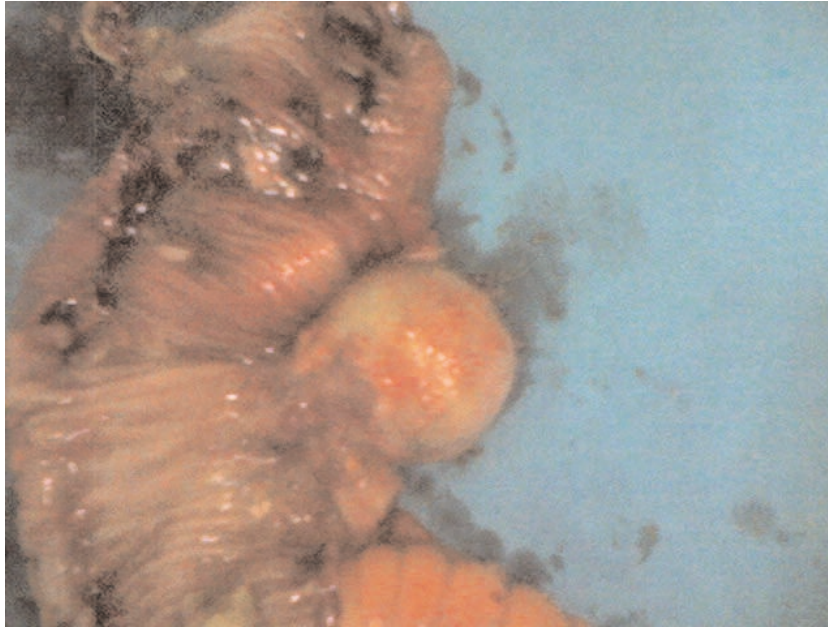


Figure 2. Intraoperative view of the ileal segment prepared for resection shows the IFP.

Macroscopically, it can be seen as a sessile or a pedunculated polypoid lesion. The lesion is composed of myofibroblasts, blood vessels, and various inflammatory cells, including eosinophils, lymphocytes, and plasma cells (6). While the IFP pathogenesis is unknown, development on an allergic basis, neural hyperplasia, and a form of granulation tissue have been suggested in the etiology (5).

Clinical symptoms depend on the location and size of the lesion. Bleeding, obstruction, prolapse, and intussusception are well-known complications of IFP. Obstruction or intussusception is the most frequent initial symptom when an IFP is located in the small intestine (7,8). Both of our patients had ileal IFP and underwent emergency surgery due to obstruction secondary to invagination. Their complaints included vomiting and abdominal distention.

Ultrasound has 100% sensitivity and 89% specificity in depicting the intussusception (8,9). Sonographically, ileal intussusception appears as concentric rings of alternating hypoechoic and hyperechoic layers with a central hyperechoic portion (9). On longitudinal scans, the

pseudokidney or hayfork sign is the typical appearance of intussusception. Intussusception can also be diagnosed by CT scan. In reported CT cases, a wall of intussusciens, a crescent of mesenteric fat, and the returning intussusceptum form three concentric layers (8). CT can also help exclude a lipoma (9). Both of our patients underwent ultrasound and in one of them it was diagnostic. One of our patients had tomography, and it was diagnostic.

The treatment of IFP has always been resection. Exploratory laparotomy is frequently recommended as treatment. The lesion seems to have no malignant potential. There have been two reported cases in the literature which showed recurrence after operation (10,11).

In summary, inflammatory fibroid polyps are uncommon gastrointestinal tract lesions. Obstruction or intussusception is the most frequent initial symptom when an inflammatory fibroid polyp is located in the small intestine. Surgical resection of the lesion for both diagnosis and treatment will be required in most cases.

References

1. Kim YI, Kim WH. Inflammatory fibroid polyps of gastrointestinal tract. Evolution of histologic patterns. *Am J Clin Pathol* 1988; 89: 721.
2. De La Plaza R, Picardo AL, Cuberes R, Jara A, Martinez-Penalver I, Villanueva MC et al. Inflammatory fibroid polyps of the large intestine. *Dig Dis Sci* 1999; 44: 1810–1816.
3. Fenoglio-Preiser CM. *Gastrointestinal pathology: an atlas and text*. 2nd ed. New York: Lippincott-Raven; 1998. pp. 449–50.
4. Vanek J. Gastric submucosal granuloma with eosinophilic infiltration. *Am J Pathol* 1949; 25: 397- 411.
5. Gönül İI, Erdem Ö, Atao?lu Ö. Inflammatory fibroid polyp of the ileum causing intussusception: a case report. *Turk J Gastroenterol* 2004; 15: 59–62.
6. Harned RK, Buck JL, Shekitka KM. Inflammatory fibroid polyps of the gastrointestinal tract: radiologic evaluation. *Radiology* 1992; 182: 863–866.
7. Johnstone JM, Morson BC. Inflammatory fibroid polyp of the gastrointestinal tract. *Histopathology* 1978; 2: 349–361.
8. Bays D, Anagnostopoulos GK, Katsaounos E, Filis P, Missas S. Inflammatory fibroid polyp of the small intestine causing intussusception: a report of two cases. *Dig Dis Sci* 2004; 49(10): 1677–1680.
9. Dicle O, Erbay G, Hacıyanlı M, Bora S. Inflammatory fibroid polyp presenting with intestinal invagination: sonographic and correlative imaging findings. *J Clin Ultrasound* 1999; 27: 89–91.
10. Anthony PP, Morris DS, Vowles KDJ. Multiple and recurrent inflammatory fibroid polyps in three generations of a Devon family: a new syndrome. *Gut* 1984; 25: 854–862.
11. McGreevy P, Doberneck RC, McLeay JM, Miller FA. Recurrent eosinophilic infiltrate (granuloma) of the ileum causing intussusception in a two-year-old child. *Surgery* 1967; 61: 280-284.